

Recurrent Hepatitis B in Liver Allograft Recipients

Differentiation Between Viral Hepatitis B and Rejection

A. JAKE DEMETRIS, MD, R. JAFFE, MBBCh,
D. G. SHEAHAN, MB, MSc,
J. BURNHAM, BA HT(ASCP), J. SPERO, MD,
S. IWATSUKI, MD, D. H. VAN THEIL, MD,
and T. E. STARZL, MD, PhD

From the Departments of Pathology, Surgery, and Medicine, University Health Center of Pittsburgh, Pittsburgh, Pennsylvania

The histologic findings in the original liver obtained from 9 liver allograft patients with active B virus hepatitis were compared with 28 posttransplant pathology specimens. All specimens were studied with the use of light and immunohistochemical microscopy in conjunction with pertinent clinical data. Eight of the 9 patients had chronic active hepatitis B (HB) with cirrhosis, prior to transplant, one of which had coexistent hepatocellular carcinoma. The ninth patient had fulminant hepatic necrosis secondary to acute HB prior to transplantation. In all of the patients with chronic HB prior to transplantation who survived more than 2 months after transplantation recurrent infection of the graft developed despite perioperative HB

immunoglobulin therapy. The patient with acute fulminant hepatitis B pretransplant has done well postoperatively and has evidence of HB virus immunity (positive anti-HBs) 15 months after transplantation. Examination of tissue specimens obtained during episodes of allograft dysfunction in these 9 patients indicate that pathologic alterations of active HB infection of the allograft are associated with a preferential lobular insult, whereas those occurring in rejection preferentially involve portal tract structures. Serologic data combined with biopsy histopathologic data are essential in distinguishing between the two quite different events. (*Am J Pathol* 1986, 125: 161-172)

HEPATIC allografts are susceptible to a wide variety of insults, which can produce considerable differential diagnostic difficulties for the surgical pathologist responsible for interpreting biopsy specimens obtained from such patients. One such problem is the separation of viral hepatitis from allograft rejection.^{1,2} This potential complication is encountered most commonly 1-2 months or more after transplantation.¹ Some viral infections of the transplanted liver such as cytomegalovirus (CMV) and herpes simplex virus (HSV) can be identified by their characteristic pathologic changes and/or immunoenzyme staining of the tissue specimen for viral antigens.^{1,3,4} On the basis of histopathologic observations alone, however, other viral hepatitises such as hepatitis A, B, and non-A non-B cannot be specifically diagnosed, although subtle histologic differences between these various types of hepatitis have been reported.⁵ However, with the combined use of immunoperoxidase stains and serologic studies for specific viral antigens, hepatitis B (HB) can be identified as the agent responsible for the hepatic injury seen in some of these cases.

It has been reported that B-virus carriers can develop recurrence of their original disease^{6,7} after liver transplantation. In one particularly well-studied case, the clinical evolution, serologic changes and histopathologic alterations caused by recurrent disease under influence of chronic immunosuppression were described.⁶ The present report is based on examination of the pathologic specimens obtained from an additional 9 liver transplant patients who were positive for hepatitis B surface antigen (HBsAg) by serologic testing at the time of transplantation. The purpose of the study was to 1) document the course of hepatitis B virus (HBV) infection in this unique group of patients during the post-transplant period and 2) attempt to identify characteristic histopathologic changes in posttransplant specimens of help in the separation of viral hepatitis, particularly type B, from allograft rejection.

Accepted for publication May 27, 1986.

Address reprint requests to A. Jake Demetris, Department of Pathology, University Health Center, Pittsburgh, PA 15213.

Materials and Methods

Patient Selection

Patients were selected for inclusion in this study on the basis of pre-transplant hepatitis serology which was positive for HBsAg. For all patients there was at least one posttransplant pathologic specimen available for review. These specimens included 22 biopsies, 3 failed allografts, and 3 autopsy specimens.

Histopathology

Tissue specimens were fixed in acid or neutral buffered formalin, embedded in paraffin, and routinely stained with hematoxylin and eosin (H&E), trichrome, and reticulin. The slides were reviewed retrospectively (Cases 1-6) and prospectively (Cases 7-9). Pathologic specimens are identified in the text according to the following designations: FG, failed allograft; AU, autopsy; LB 8.220A, liver biopsy from Patient 8, 220 days after transplant, (A) from the first graft. Final analysis of each case incorporated the clinical course, HB serologic studies, and immunoperoxidase staining for HB viral antigens.

Immunoperoxidase Staining for HBsAg and HBcAg

Surgical and autopsy specimens used for these studies were fixed as above and sectioned at four microns.

Sections were stained for hepatitis surface antigen utilizing the avidin-biotin-peroxidase complex method of Hsu.⁸ Goat antiserum specific for HBsAg (Dako Corporation, Santa Barbara, Calif) in a dilution of 1:1200 produced optimal staining. All procedures were carried out at room temperature. A 0.05% DAB (3',3'-diaminobenzidine) solution produced a dark brown color in positive-staining cells.

Tissue sections were stained for hepatitis B core antigen (HBcAg) by Sternberger's⁹ PAP technique (peroxidase-antiperoxidase). The hepatitis B core antiserum produced in rabbits was supplied by the Dako Corporation. The chromogen 3-amino-9-ethylcarbazole produced a bright brick-red color in positive staining nuclei of hepatocytes. Nonimmune serum substituted for the primary antibody, served as the negative control for each staining procedure and yielded no staining. Liver tissue from known seropositive cases of HB were used as the biologic positive-staining controls.

Clinicopathologic Correlation

The results of liver injury tests, HB serologic studies, and the details of immunosuppressive therapy for rejection, immunoprophylaxis for HBV, and clinical impressions were obtained from the patient chart and/or through personal communication with the attending physicians and surgeons.

Table 1—Demographic Data, Treatment Regimens, Duration of Disease, and HLA Typing

	Patient								
	1 R.H.	2 J.S.	3 P.W.C.	4 M.V.D.	5 J.L.	6 D.A.	7 A.C.	8 D.T.	9 A.C.
Age/sex	28/M	45/M	27/M	34/M	28/M	23/M	51/M	34/M	38/M
Pretransplant disease*	Cirrhosis CAH-B Alcohol abuse	Cirrhosis CAH-B	Cirrhosis CAH-B	Cirrhosis CAH-B	Fulminant Acute Hepatitis B	Cirrhosis CAH-B	Cirrhosis CAH-B Hepatoma	Cirrhosis CAH-B	Cirrhosis CAH-B
Pretransplant treatment	None	Azathioprine Steroids	Steroids	Steroids	None	Steroids	?	None	None
Duration of HB infection	4 years	6-7 years	8 years	>10 years	<3 weeks	>4 years	>5 years	?	14 years
HLA type									
Donor	A1 B49(21) DR; NA	A1, 24(9) B14, BW44 (12) DR; 4, 7	ND†	ND	A1, 2 B60, BW6 DR5, 6	A2, 31‡ B15, 151 DR 2, 5	ND	A28, 30‡ B57-BW4 DR 2, 8	A 2, 24 B7, 52, BW4, 6 DR 2, 6
Recipient	A1, 2 B17, 22 DR 2, 7	A1, 11 B8, 14 DR 6y	A26 (10) B51(5), 53 DR 3, 5	A2, 24 B40, BW6 DR4	A25(16) A32(18) B8 B14 DR 1, 3	A34, 36 B35 DR 5, 7	A24, 26 B35 DR 5, 7	A28- B13-BW4 DR 6, 7	A2, 24 B38, 27, BW4 DR 1, 2

* CAH-B, chronic-active hepatitis.

† ND, not done.

‡ First donor.

Table 2—Primary Disease Pathology and Immunotherapy for HBV

Patient	Primary disease	Immunoperoxidase staining pattern*		HBIG† therapy (total dose)
		HBs Ag	HBe Ag	
1 R.H.	Cirrhosis—active	HC‡ cytoplasm in 10% cells in isolated nodules	Negative	5 ml IM 1 day post-op (5 ml)
2 J.S.	Cirrhosis—active	Negative	Positive in occasional paraseptal HC nucleus	5 ml IM on 12th and 38th day post-op (10 ml)
3 P.W.C.	Cirrhosis—active	HC cytoplasm in 30% cells in isolated nodules	Negative	20 ml IM intraoperatively, immediately post-op, 1 month and 6 months post-op (80 ml)
4 M.V.D.	Cirrhosis—active	HC cytoplasm in 10% cells in isolated nodules	Negative	5 ml IM intraoperatively and immediately post-op (10 ml)
5 J.L.	Massive necrosis	Difficult to interpret because of necrosis	Difficult to interpret because of necrosis	100 ml IV intraoperatively during anhepatic state, immediately and 1 week post-op (300 ml)
6 D.A.	Cirrhosis—active	HC cytoplasm in occasional paraseptal cell	Negative	100 ml IV intraoperatively and immediately post-op (200 ml)
7 A.C.	Cirrhosis, hepatocellular carcinoma	HC cytoplasm in 30% cells distributed randomly	Positive in occasional HC nucleus	None
8 D.T.	Cirrhosis—active	HC cytoplasm in 10% cells in isolated nodules	Negative	100 ml IV intraoperatively during anhepatic state, after perfusion and immediately post-op (300 ml)
9 A.C.	Cirrhosis—active	HC cytoplasm in <10% cells distributed randomly	Negative	100 ml IV intraoperatively during anhepatic state, after perfusion and immediately post-op (300 ml)

* No staining of biliary epithelium seen for HBs Ag or HBe Ag in any case.

† HBIG, B immune globulin. IM, intramuscular. IV, intravenously.

‡ HC, hepatocellular.

Results

Patient Population and Pretransplant Disease

The patient demographic data, pretransplant treatment regimens, duration of disease, and HLA typing of both donor and recipient are shown in Table 1. The primary disease histopathology with immunoperoxidase staining for HB antigens are shown in Table 2.

Immunotherapy for HB

Eight of the 9 patients were treated with various doses of hepatitis B immunoglobulin (HBIG) in the peritransplant period. Details of the treatment regimen are shown in Table 2.

Posttransplant Analysis of Graft Dysfunction

Episodes of graft dysfunction occurred in all 9 patients after transplantation and were identified by elevated serum levels of liver enzymes and clinical symptoms. Biopsy specimens were obtained at the onset of

graft dysfunction in all 9 patients (see Table 3), and follow-up biopsies or failed grafts were obtained in most.

Episodes of graft dysfunction attributed to acute cellular rejection (LBs 3.14, 3.62, 4.42, 4.78, 5.40, and 5.50; FG 6.11, and LBs 8.7A and 8.26A) all occurred initially within the first 2 months after transplant (range, 11–42 days). Clinically, dysfunction was accompanied by lethargy, graft tenderness, and liver biochemical abnormalities. Histologically, all the specimens had pathologic alterations which were primarily based in the portal tracts. The morphologic manifestations of acute cellular rejection consisted of a portal expansion secondary to predominantly mononuclear but mixed inflammatory infiltrate consisting of large and small lymphocytes, plasma cells, macrophages, eosinophils, and neutrophils. The portal inflammatory cells were seen around, beneath, and within the portal venular endothelium and the biliary ductular epithelium. The endothelial and biliary epithelial cells showed nuclear enlargement and evidence of damage such as paranuclear vacuolation and cytoplasmic eosinophilia. The endothelial cells were at times lifted from the underlying connective tissue, and occasional disruption of the lumi-

Table 3—Graft Dysfunction

Patient	Liver enzymes*	Pathology specimen	Histopathology	IPEX Staining*			Diagnosis†	Treatment	Outcome
				HBsAg	HBcAg	HBsAg			
1 R.H.	TB 3.7	LB 1.125	Lobule—disarray, ballooning, necrosis inflammation	Negative	Positive in 20% HC nuclei distri- bution ran- domly.	Recurrent Hepatitis B	Increased steroids	Little change in LFTs; developed sepsis, pan- creatitis and expired	
	ALT 2060 AST 1780 GGTP 226	AU 1.150	Portal—moderate chronic inflammation, focal ductular vacuolation, piecemeal necrosis complete coagulative necrosis	Did not interpret	Did not interpret	Coagulative necrosis	—	—	
2 J.S.	TB 4.5	LB 2.295	Lobule—disarray, bridging necrosis, inflammation	NA	>40% of HC nuclei positive, some cytoplas- mic staining	Recurrent Hepatitis B	Increased Steroids	Little change in LFTs; developed sepsis, dis- seminated herpes and expired	
	ALT 85 AST 90 AP 75	AU 2.450	Portal—moderate periportal inflammation without ductular or vascular damage, piecemeal necrosis Lobule—mild regenerative activity Portal—fibrosis with early cirrhosis and duct preservation	20% HC cytoplasm in para- septal cells	Positive in 60% HC nuclei in para- septal cells	Early cirrho- sis second- ary to HB	—	—	
3 P.W.C.	TB 10.0	LB 3.14	Lobule—centrilobular ballooning, cholestasis	Negative	Negative	Harvesting injury, early mild rejection	Increased steroids	Improved LFTs	
	AP 31 GGTP 75 ALT 112 AST 60		Portal—mild chronic inflammation with focal duct damage	Negative	Negative	Moderate cellular rejection	Increased steroids	Improvement of LFTs; patient discharged	
4 M.V.D.	TB 1.0	LB 3.62	Lobule—normal	Negative	Negative	Recurrent HB ? mild rejection	Steroid bolus followed by major reduction in immunosuppression	Liver function abnormalities resolved; patient discharged	
	AP 95 GGTP 158 ALT 214 AST 88		Portal—moderate mixed inflammation with prominent vascular and ductular damage	ND	Positive in 45% (HC) nuclei	Harvesting injury	None	Improved graft function	
4 M.V.D.	TB 8.3	LB 3.246	Lobule—disarray, inflammation, ballooning and necrosis, cholestasis	Negative	Negative	Mild cellular rejection, partially treated	Increased steroids	Improvement of LFTs; patient discharged; subsequently developed serologic marker (HBeAg) of active infection	
	AP 222 GGTP 411 AST 632		Portal—moderate inflammation no vascular damage, ductular vacuolization, piecemeal necrosis	Negative	Negative	Increased steroids	Increased steroids	Slight improvement of LFTs	
4 M.V.D.	NA	LB 4.3	Lobule—centrilobular coagulative necrosis Portal—mild ductular proliferation	Negative	Negative	Increased steroids	Increased steroids	Slight improvement of LFTs	
	TB 7.2	LB 4.42	Lobule—mild regeneration cholestasis Portal—moderate inflammation with promi- nent ductular and vascular injury	Negative	Negative	Increased steroids	Increased steroids	Slight improvement of LFTs	
4 M.V.D.	AP 390 GGTP 223 ALT 42 AST 25		Lobule—cholestasis Portal—mild inflammation with continuing ductular and vascular damage	Negative	Negative	Increased steroids	Increased steroids	Slight improvement of LFTs	
	TB 9.1	LB 4.78	Lobule—cholestasis Portal—mild inflammation with continuing ductular and vascular damage	Negative	Negative	Increased steroids	Increased steroids	Slight improvement of LFTs	
4 M.V.D.	AP 378 GGTP 600 ALT 158 AST 95		Lobule—cholestasis Portal—mild inflammation with continuing ductular and vascular damage	Negative	Negative	Increased steroids	Increased steroids	Slight improvement of LFTs	
			Lobule—cholestasis Portal—mild inflammation with continuing ductular and vascular damage	Negative	Negative	Increased steroids	Increased steroids	Slight improvement of LFTs	

Case	Lab	Time	Findings	HB	HC	HBsAg	HBcAb	HBsAb	Transplant	Outcome
5 J.L.	TB	6.8	Lobule—mild cholestasis	Negative	Negative				None	See follow-up biopsy
	AP	51	Portal—mild inflammation with focal ductular and vascular damage							
	GGTP	254								
	ALT	41								
	AST	41								
6 D.A.	TB	3.7	Lobule—cholestasis	Negative	Negative				OKT3 ^{ll}	Dramatic improvement in LFTs; patient discharged; has evidence of HBV immunity
	AP	198	Portal—moderate inflammation with prominent duct and vascular injury							
	GGTP	407								
	ALT	21								
	AST	50								
7 A.C.	TB	—	Lobule—prominent coagulative necrosis with periportal predominance	Negative	Negative				Retransplantation	See next specimen
	AP	—	Portal—mild acute inflammation, mild duct proliferation							
	GGTP	—								
	ALT	—								
	AST	—								
8 D.T.	TB	1.1	Lobule—coagulative necrosis	Negative	Negative				—	—
	AP	43	Portal—moderate inflammation with ductular and vascular injury							
	GGTP	76	Other—Hepatic artery thrombosis, fungal abscess							
	ALT	153								
	AST	63								
9 A.C.	TB	1.1	Lobule—Disarray, mild inflammation, prominent single cell necrosis	20% HC	20% HC				None	Little change in LFTs; patient discharged. Developed recurrent and metastatic carcinoma and expired
	AP	43	Portal—Very mild inflammation, no vascular or duct damage							
	GGTP	134								
	ALT	348								
	AST	214								
10 D.T.	TB	12.9	Lobule—central vein inflammation, cholestasis	Negative	Negative				Increased steroids	Improved LFTs
	AP	57	Portal—inflammation, vascular and duct damage, cholestasis							
	GGTP	134								
	ALT	348								
	AST	214								
11 D.T.	TB	5.1	Lobule—cholestasis	Negative	Negative				Increased steroids	Improved LFTs; patient discharged
	AP	256	Portal—edema with mild inflammation, endothelial and biliary epithelial cell hypertrophy							
	GGTP	689								
	ALT	152								
	AST	69								
12 D.A.	TB	10.6	Lobule—disarray, inflammation with hepatocyte necrosis	Focal HC	Focal HC				Decreased steroids	Fulminant necrosis (see next specimen)
	AP	46	Portal—mild inflammation without duct damage							
	GGTP	142								
	ALT	1673								
	AST	1817								
13 D.A.	TB	—	Lobule—diffuse necrosis, architectural distortion	>30% HC	>30% HC				Retransplantation	—
	AP	—	Portal—intact, prominent periportal regenerative activity							

Table 3—Continued

Patient	Liver enzymes*	Pathology specimen	Histopathology	IPEX Staining*			Treatment	Outcome	
				HBSAg	HBCAg	Diagnosis†			
TB	14.2	LB 8.6B,	<i>Lobule</i> —mild ballooning <i>Portal</i> —mild ductular proliferation, no inflammation	Negative	Focal cytoplasmic and nuclear positivity in LB 8.29B	Harvesting injury	None	Improved LFTs; patient discharged	
	AP	113							8.17B,
	GGTP	220							8.29B,
	ALT	160							
	AST	63							
9 A.C.	12.2	LB 8.89B	Identical to LB 8.220A	Positive in >80% HC cytoplasm with surface membrane accentuation	Positive in >80% HC nuclei and cytoplasm with surface membrane accentuation	Recurrent HB	None	Patient expired; no autopsy	
	AP	159							
	GGTP	195							
	ALT	271							
	AST	168							
9 A.C.	10.5	LB 9.6	<i>Lobule</i> —mild centrilobular ballooning, cholestasis <i>Portal</i> —Normal	Negative	Negative	Harvesting injury, cholestasis	None	Gradual improvement in LFTs; patient discharged	
	AP	55							and 9.18
	GGTP	70							
	ALT	228							
	ALT	518							
TB	11.4	LB 9.195	<i>Lobule</i> —prominent single cell necrosis with mild lobular inflammation <i>Portal</i> —no inflammation	Prominent surface membrane staining	Positive in 40% HC nuclei with some cytoplasmic staining	Recurrent HB	None	Self-limited resolution of graft dysfunction (see next specimen)	
	AP	82							
	GGTP	47							
	ALT	1627							
	AST	1667							
TB	11.4	LB 9.223	<i>Lobule</i> —mild lobular regenerative changes, no inflammation <i>Portal</i> —normal	Positive in occasional cytoplasm Kupffer cells positive	Same as LB 9.195 except for increased cytoplasmic staining	HBV infection without prominent dis-ease activity	None	Patient discharged	
	AP	143							
	GGTP	260							
	ALT	22							
	AST	27							

* TB, total bilirubin (nl <1.0 mg/dl); AP, alkaline phosphatase (nl <110 IU); GGTP, gamma glutamyl transpeptidase (nl <50 IU), ALT, alanine aminotransferase (nl <40 IU).
 † IPEX, immunoperoxidase.
 ‡ Diagnoses are listed in order of perceived importance.
 § Liver function tests.
 || Orthoclone anti OKT3 monoclonal antibodies (Ortho pharmaceuticals, Raritan, NJ).

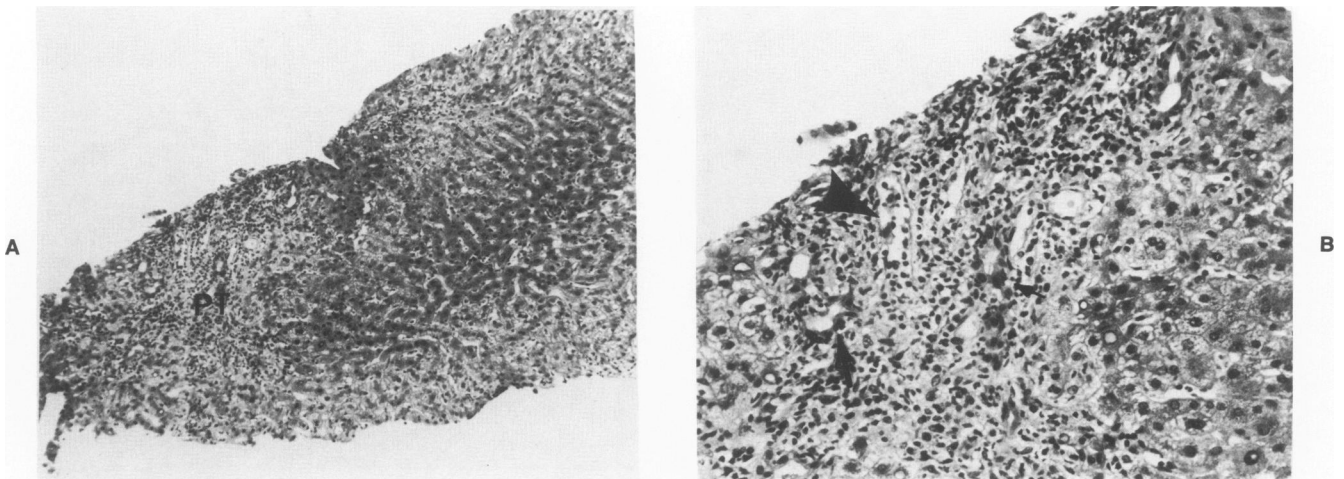


Figure 1A—Patient 5, LB 550 showing a prominent portal tract infiltrate with portal edema and a relative lack of lobular changes. (H&E, $\times 125$) **B**—Higher-power magnification of the above section showing inflammatory cell infiltration and damage of bile ductules (arrows) and venous endothelium (arrowhead). (H&E, $\times 315$)

nal integrity of the bile ductules was present. The limiting plate was generally intact, but occasionally “spill-over” of the infiltrate into the periphery of the lobule associated with periportal hepatocyte necrosis was seen. Lobular changes were generally minimal and consisted of centrilobular cholestasis and occasional central vein changes similar to those described in the portal veins. A representative example of the changes seen with acute cellular rejection is shown in Figure 1. Stains for HB antigens were negative in these specimens except for faint staining for HBsAg seen in the plasma within the blood vessels. All of the episodes diagnosed as acute cellular rejection had a partial or complete response to antirejection therapy, as evidenced by improvement in liver enzyme levels.

Episodes of graft dysfunction attributed to recurrent HB (LB 1.125, 2.295, AU 2.450, 3.246, 7.105, 8.220A, 8.89B, 9.195, and 9.223) all initially occurred more than 8 weeks after transplant (range, 89–295 days) (Table 3). Clinically, dysfunction was accompanied by malaise, nausea, jaundice, and elevated liver enzymes (most frequently ALT and AST). Histologically, all the specimens in which dysfunction was due to HB had in common the presence of pathologic lobular alterations with minimal evidence of inflammatory cell damage to portal venular endothelium or biliary epithelium. Lobular morphologic alterations in LB 1.125, 2.295, 3.246, 8.220A, and 8.89B consisted of prominent disarray, inflammation, ballooning, and random hepatocellular acidophilic necrosis. A moderate degree of portal inflammation was present in LB 1.125, 2.295, and 3.246, along with focal biliary epithelial cell vacuolation and stratification. However, disruption of the luminal integrity of the ductules was not seen. Also, the portal tract

changes were much less prominent than those seen during episodes of acute cellular rejection. Piecemeal necrosis was also observed in these specimens. Lobular alterations in LB 7.105 and 9.195 were limited to moderate disarray and conspicuous individual hepatocyte necrosis with minimal lobular and portal inflammation. Examples of the histopathologic findings in recurrent HB are illustrated in Figures 2 and 3. Serum and tissue specimens from all the patients obtained at the time of graft dysfunction secondary to HB demonstrated reoccurrence of detectable levels of viral antigens (see Tables 3 and 4).

The earliest histologic evidence of recurrent HB infection was the presence of HBcAg in LB 8.29B in the cytoplasm of two or three hepatocytes and in one hepatocellular nucleus. Graft pathology, however, was not seen in this patient until 60 days later (LB 8.89B).

Episodes of recurrent HB were treated with increased immunosuppression in Patients 1 and 2, because the initial pathologic changes were interpreted as rejection. At that time, immunoperoxidase staining was not done, nor were serologic studies taken into account. Both patients died of sepsis, which may or may not have been related to HB. Immunosuppression therapy in the remaining patients was either reduced or unchanged after the diagnosis of HB, which resulted in self-limited resolution of acute graft dysfunction (Patients 3 and 9) without viral clearing, maintenance of low-grade chronic disease activity (Patients 4 and 7), or acute fulminant HB requiring retransplantation (Patient 8A).

Interestingly, in follow-up specimens from Patients 2 and 9 (AU 2.450 and LB 9.223) there were minimal pathologic changes but marked expression of tissue viral antigens.

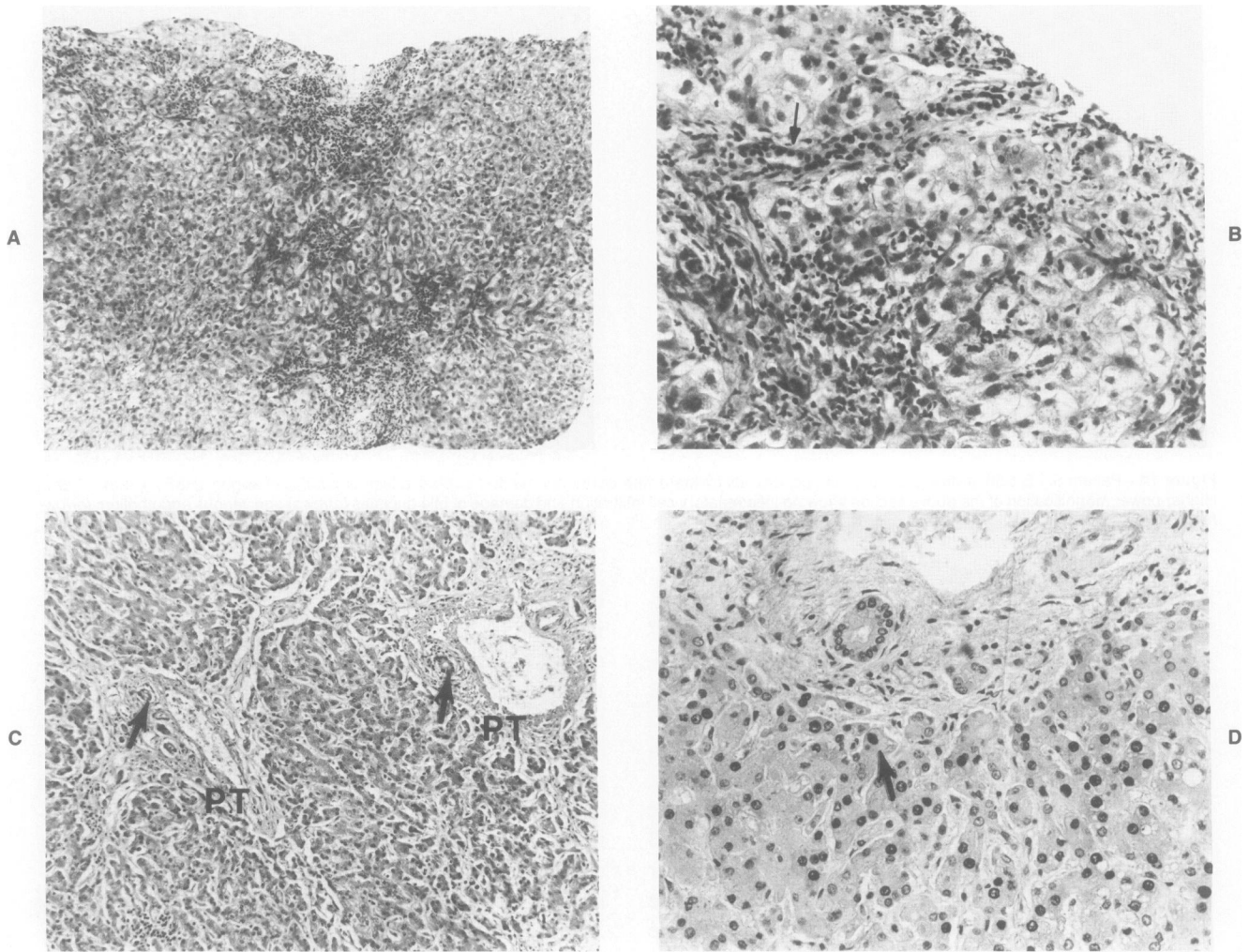


Figure 2A—Patient 2, LB 2.295 demonstrating marked lobular disarray, hepatocellular ballooning and extension of the inflammation into the lobule. (H&E, $\times 125$) **B**—Higher-power magnification of the above section showing extension of the infiltrate into the lobule surrounding ballooned hepatocytes and intact bile ductule (*arrow*). (H&E, $\times 315$) **C**—AU 2.450. Note the lack of inflammation and of lobular changes. However, there is portal fibrosis with early bridging between the portal tracts and intact bile ductules (*arrowhead*). (H&E, $\times 125$) **D**—Higher-power magnification of **C** demonstrating findings identical to those outlined in **C** and expression of the HBcAg in many hepatocellular nuclei (*arrow*) as described by Gudat.²³ (HBcAg immunoperoxidase with hematoxylin counterstain, $\times 315$)

Discussion

Though the histologic appearance of HBV hepatitis may be varied, the usual picture in the acute stage is one of lobular disarray, hepatocyte ballooning, and focal necrosis, accompanied by a lymphohistiocytic lobular and portal tract infiltrate.⁵ Focal inflammatory bile ductular and vascular endothelial infiltration and damage may be present but usually are not prominent features of the condition.^{5,10,11}

Portal inflammation is the hallmark of chronic hepatitis B. In spite of the location of the inflammatory infiltrate in CAHB, associated destruction of the portal tract structures is usually not prominent. Instead, the presence of inflammatory cells with destruction of hepatocytes at the edge of the limiting plate is the rele-

vant feature. Furthermore, a histologic picture of loss of ductules, similar to that seen in primary biliary cirrhosis or the end stages of a rejected liver,^{1,12} has not been reported as a consequence of type B viral hepatitis⁵ and was not seen in any of the cirrhotic primary resection specimens in this study.

The histopathologic observations in HBV disease can be related to what is known about the virus. Specifically, the HBV is an enveloped partially doubled stranded DNA virus with a rather selective tissue tropism for hepatocytes which has been linked to the presence of polyalbumin receptors on the hepatocyte.¹³ The mechanisms involved in the production of clinically important hepatic disease by this virus are not well understood. Most studies agree that the HBV is not cytopathic.¹³⁻¹⁶ Likewise, most of the circumstantial evidence collected from

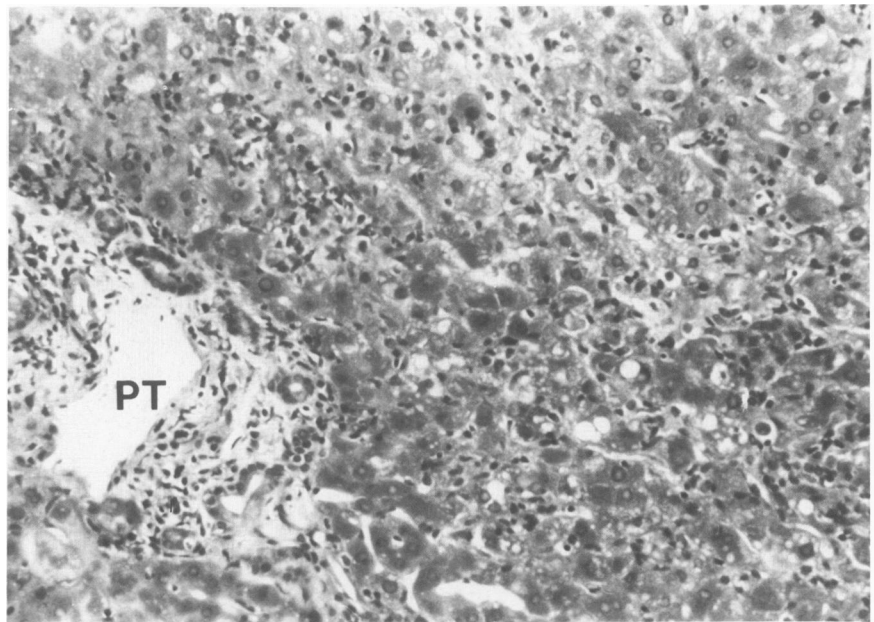
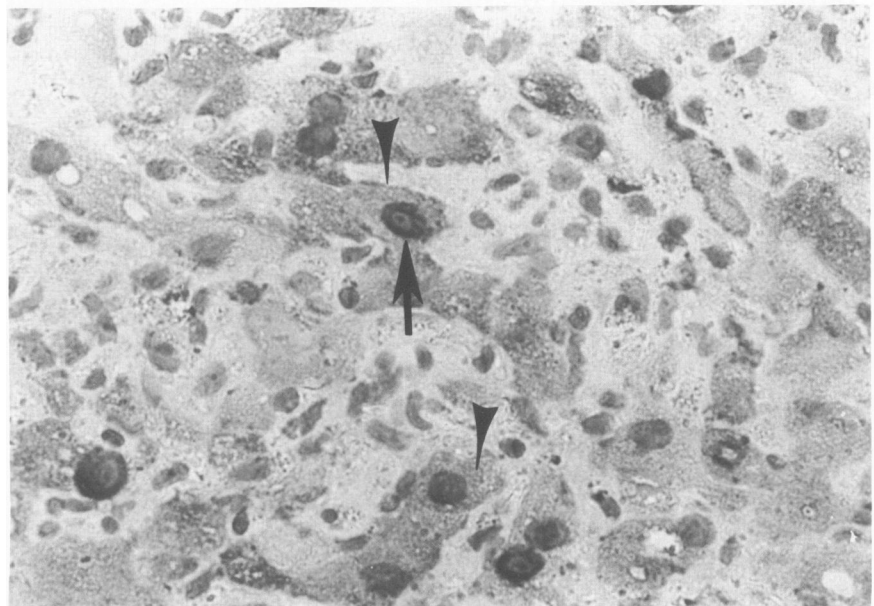


Figure 3A—Patient 8, LB 8.220A showing marked lobular inflammation, disarray, and hepatocellular necrosis. (H&E, $\times 200$)
B—Higher-power magnification of **A** showing lobular inflammation with expression of HBcAg in the nucleus (*arrow*) and cytoplasm (*arrowhead*) of the hepatocytes. (Immunoperoxidase staining for HBcAg, $\times 500$)



patient studies suggests that cell-mediated immune mechanisms are primarily responsible for the cell lysis and the viral clearing that occur during infection.¹³⁻¹⁸ Based on the present understanding of HBV disease, the hepatocyte appears to be the primary target of virus infection and therefore the focus of subsequent cellular-mediated cytolysis. Thus, the immune status of the host plays an important role in the type and spectrum of liver disease produced as a consequence of the viral infection.

The histopathologic findings in the biopsy specimens

obtained from the patients in this study who were diagnosed as having active HB virus infection as the primary pathologic process responsible for their graft dysfunction are consistent with the above concepts. The presence of lobular disarray with hepatocellular ballooning and individual cell necrosis in addition to a portal and/or lobular inflammatory infiltrate of variable intensity without prominent vascular or bile ductular damage reflect the reappearance of HBeAg in the serum and HBcAg in hepatocellular nuclei (markers of active viral replication).

Table 4—Sequential Serologic Studies

1	R.H. (2/12/82)*	<i>Pre-Tx</i>	2/24/82	3/30/82	6/21/82		
	HBsAg	Pos 162.02	Pos 29.01	Pos 12.27	Pos 101.63		
	Anti HBs	Neg	Pos 4.02†	*Neg	Neg		
	Anti HBc	Pos	Pos	Pos	Pos		
	HBeAg	Neg	Neg	Neg	Pos 23.57†		
	Anti HBe	Pos	Pos	Pos	Neg†		
	Anti-Delta	Pos	ND	ND	Pos		
2	J.S. (7/23/81)	<i>Pre-Tx</i>	8/24/81	4/2/82	9/23/82		
	HBsAg	Pos 130.8	Neg†	*Pos 167.8	Pos 128.89		
	Anti HBs	Neg	Pos 23.44†	Neg	Neg		
	Anti HBc	Pos	Pos	Pos	Pos		
	HBeAg	Pos 3.27	ND	Pos	Pos 31.47		
	Anti HBe	Neg	Neg	Neg	Neg		
	Anti-Delta	Neg	ND	Neg	ND		
3	P.W.C. (12/23/83)	<i>Pre-Tx</i>	5/10/84	6/18/84	8/17/84		
	HBsAG	Pos 226.67	Neg†	Pos 182.11†	Pos 222.72		
	Anti HBs	Neg	Pos 182.11†	Neg†	Pos 11.58†		
	Anti HBc	Pos	Pos	Pos	Pos		
	HBeAg	Pos	ND	Pos 7.96†	Pos 8.05		
	Anti HBe	Neg	ND	Neg	Neg		
	Anti-Delta	Neg	ND	Neg	ND		
4	M.V.D. (2/20/82)	<i>Pre-Tx</i>	3/2/82	3/8/82	3/18/82	6/28/82	
	HBsAg	Pos 183.37	Neg†	Neg	Pos 3.24†	Pos 203.62	
	Anti HBs	Neg	Pos 3.94†	Neg	Neg	Neg	
	Anti HBc	Pos	Pos	Pos	Pos	Pos	
	HBeAg	Pos 11.47	ND	ND	Neg†	Pos†	
	Anti HBe	Neg	ND	Neg	Neg	Neg	
	Anti-Delta	Neg	ND	ND	Neg	ND	
5	J.L. (11/28/84)	<i>Pre-Tx</i>	12/3/84	1/7/85			
	HBsAg	Pos 185.88	Pos 212.39	Neg†			
	Anti HBs	Pos 3.19	Pos 75.88†	Pos 357.16			
	Anti HBc	Pos	Pos	Pos			
	HBeAg	Neg	Neg	ND			
	Anti HBe	Neg	Pos†	ND			
	Anti-Delta	Neg	ND	ND			
6	D.A. (5/26/84)	<i>Pre-Tx</i>	6/4/84	6/13/84			
	HBsAG	Pos 235.82	Pos 11.20	Neg†			
	Anti HBs	Neg	Pos 12.76	Pos 118.01			
	Anti HBc	Pos	Pos	Pos			
	HBeAg	Neg	Neg	ND			
	Anti HBe	Pos	Pos	ND			
	Anti-Delta	Pos	Pos	ND			
7	A.C. (11/15/84)	<i>Pre-Tx</i>	11/23/84	3/18/85			
	HBsAg	Pos 209.29	Pos 228.73	Pos 125.68			
	Anti HBs	Neg	Neg	Neg			
	Anti HBc	Pos	Pos	Pos			
	HBeAg	Pos	Neg†	Pos 14.05†			
	Anti HBe	Neg	Pos†	Neg†			
	Anti-Delta	Neg	ND	Neg			
8	D.T. (5/11/85)	<i>Pre-Tx</i>	6/19/85	12/20/85	1/8/86	2/5/86	3/13/86
	HBsAg	Pos 253.01	Neg	Pos 143.67†	Pos 190.51	Pos 156.80	Pos 177.41
	Anti HBs	Neg	Pos 248.06	Neg†	Neg	Pos 2.8 †	Neg†
	Anti HBc	Pos	Pos	Pos	Pos	Pos	Pos
	HBeAg	Pos 3.52	ND	Pos 16.30	Pos 26.57	Pos 5.41	Pos 22.81
	Anti HBe	Pos	ND	Neg	Neg	Neg	Neg
	Anti-Delta	Neg	ND	Neg	Neg	Neg	Neg
9	A.C. (5/30/85)	<i>Pre-Tx</i>	6/28/85	1/16/86	2/11/86		
	HBsAg	Pos 171.14	Neg†	Pos 118.61†	Pos 179.35		
	Anti HBs	Neg	Pos	Neg	Neg		
	Anti HBc	Pos	Pos	Pos	Pos		
	HBeAg	Neg	ND	Neg	Neg		
	Anti HB	Pos	ND	Pos	Pos		
	Anti-Delta	Pos	ND	Pos	ND		

* Patient and date of transplantation.

† Denotes change from previous determination.

ND, not done.

Immunohistochemical staining used to detect the presence of viral antigens within the liver tissue, while extremely helpful, may not be essential,¹⁹ because active HBV disease may be seen in the absence of detectable HB surface and core antigen expression in tissue.

In contrast to the situation occurring in active HBV infection, the histologic appearance of liver rejection in patients on immunosuppressive therapy suggests that constituents of the portal tract are the preferential targets of immune destruction occurring as part of the rejection process.^{1,2,12,20-23} These targets include portal tract connective tissue dendritic, venular endothelial, and biliary ductular epithelial cells, all of which may be related to the localization and expression of major histocompatibility complex (MHC) antigens^{20,24,25} and to the functional anatomy of the liver. Though focal periportal and pericentral vein hepatocyte damage can be seen as a part of rejection, prominent extension of the lymphohistiocytic infiltrate into the hepatic lobule with ballooning, disarray, and marked individual hepatocyte necrosis has not been a prominent feature of rejection in immunosuppressed patients in this or several other reported series of liver allografts.^{1,2,21-23} The findings in biopsy specimens from patients during episodes of acute rejection in this study are consistent with these concepts and are more specific for rejection. Also, in failed liver allografts removed secondary to long-standing rejection, it is not uncommon to find a near total absence of bile ductules and advanced portal fibrosis but with relative preservation of the hepatocytes and only a modest portal inflammatory infiltrate.^{1,12}

The validity of the argument that separation of graft dysfunction secondary to recurrent hepatitis B from acute cellular rejection is possible was confirmed by the events which followed each respective diagnosis. Graft dysfunction secondary to rejection responded clinically and biochemically to increased immunosuppression. Graft dysfunction secondary to hepatitis B resulted in self-limited resolution of acute dysfunction, maintenance of chronic disease activity, or fulminant failure, without alteration in immunosuppressive therapy. The syndrome of viral HB, therefore, is not dissimilar to that seen in non-liver allograft patients. However, no instance of viral antigen clearing was seen after recurrent infection in the posttransplant period despite apparent self-limited dysfunction in some cases.

Other interesting observations made during the review of these cases include the following:

1. In all patients transplanted with HBsAg-positive CAH, whether HBeAg or anti-delta agent positive or not, recurrent infection developed after more than 3 months. The exception to this statement is the patient whose original disease was fulminant hepatic necrosis

secondary to acute HB. He has apparently cleared the virus and is now immune to infection.

2. Recurrent active HBV hepatitis (disease) was not thought to be responsible for allograft dysfunction at time periods earlier than 2 months after transplantation, despite an earlier serologic reappearance of HBsAg in the serum.

3. Early posttransplant graft dysfunction occurring at any time less than 2 months after OLTx, was likely to be due to allograft rejection rather than active HB.

It has been suggested that HB is a "mild disease" in immunocompromised hosts.²⁶ However, this study shows that at least in some patients, although they are immunosuppressed, HB does appear to cause progressive and severe liver damage, as evidenced by the increase in liver enzymes coincident with the reappearance of serum and tissue viral antigens and the histologic appearance of recurrent CAH and cirrhosis. Similar observations have been made by Parfrey's group²⁷ in renal transplant recipients who had chronic active HB.

The clinical, serologic, and pathologic findings in this group of patients are quite similar to those reported by Corman et al⁶ in the previously well-documented case of recurrent HB in a liver allograft patient. Like that earlier case report, this report also emphasizes the similarity between recurrent hepatitis in liver allograft patients and that seen in posttransfusion HB, the presence of liver graft damage albeit different from the original disease due to the B virus even though the patient is immunosuppressed and the histopathologic findings of a preferential lobular or hepatocellular insult.

References

1. Demetris AJ, Lasky S, VanTheil D, Starzl TE, Dekker A: Pathology of transplantation: A review of 62 adult allograft recipients immunosuppressed with cyclosporine/steroid regimen. *Am J Pathol* 1985, 118:151-161
2. Porter KA: Pathology of liver transplantation. *Transplant Rev* 1969, 2:129-170
3. Eron L, Kosinski K, Hirsch MS: Hepatitis in an adult caused by herpes simplex virus type 1. *Gastroenterology* 1976, 71:500-504
4. Ten Napel CHH, Houthoff HJ, The TH: Cytomegalovirus hepatitis in normal and immune compromised hosts. *Liver* 1984, 4:184-194
5. Koff RS, Galambos J: Viral hepatitis, Diseases of the Liver. Edited by L Schiff. 5th edition. Philadelphia, J. B. Lippincott, 1982, pp 507-528
6. Corman JL, Putman CW, Iwatsuki S, Redeker AG, Porter KA, Peters RL, Schroter G, Starzl TE: Liver allograft: Its uses in chronic active hepatitis with macronodular cirrhosis, hepatitis B surface antigen. *Arch Surg* 1979, 114:75-78
7. Starzl TE, Koep LJ, Halgrimson CG, Hood J, Schroter GPJ, Porter KA, Weil R III: Fifteen years of clinical liver transplantation. *Gastroenterology* 1979, 77:375-388

8. Hsu SM, Raine L, Fanger H: The use of avidin-biotin-peroxidase complex (ABC) in immunoperoxidase techniques: A comparison between ABC and unlabeled antibody (PAP) procedures. *J Histochem Cytochem* 1981, 29:577-580
9. Sternberger LA, Hardy PH, Cuculis JJ, Meyer HG: The unlabeled antibody-enzyme method of immunohistochemistry: Preparation and properties of soluble antigen-antibody complex horseradish peroxidase-antiperoxidase and its use in identification of spirochetes. *J Histochem Cytochem* 1970, 18:315
10. Poulson H, Christoffersen P: Abnormal bile duct epithelium in chronic aggressive hepatitis and cirrhosis: A review or morphology and clinical, biochemical and immunologic features. *Hum Pathol* 1972, 3:217-225
11. Review by an International Group: Histopathology of the intrahepatic biliary tree. *Liver* 1983, 3:161-175
12. Portman B, Neuberger JM, Williams R: Intrahepatic bile duct lesions, *Liver Transplantation: The Cambridge/Kings College Experience*. Edited by RY Calne. New York, Grune & Stratton, 1983, pp 279-297
13. Gerber MA, Thung SN: Biology of disease: Molecule and cellular pathology of hepatitis B. *Lab Invest* 1985, 52:572-590
14. Mondelli M, Naumov N, Eddleston ALWF: The immunopathogenesis of liver cell damage in chronic hepatitis B virus infection, *Advances in Hepatitis Research*. Edited by FV Chisari. New York, Masson USA, 1984, pp 144-151
15. Yamada G, Feinberg LE, Nakane PK: Hepatitis B: Cytologic localization of virus antigens and the role of the immune response. *Hum Pathol* 1978, 9:93-109
16. Alberti A, Trevisan A, Fattovich G, Realdi G: The role of hepatitis B virus replication and hepatocyte membrane expression in the pathogenesis of HBV-related hepatic damage,¹⁴ 1984, pp 134-143
17. Vento S, Hegarty JE, Alberti A, O'Brian CJ, Alexander GJM, Eddleston ALWF, Williams R: T lymphocyte sensitization to HBe Ag and T-cell-mediated unresponsiveness to HBs Ag in hepatitis B virus-related chronic liver disease. *Hepatology* 1985, 5:192-197
18. Shafritz DA, Hadziyannis SJ: Hepatitis B virus DNA in liver and serum, viral antigens and antibodies, virus replication, and liver disease activity in patients with persistent hepatitis B virus infection, *Advances in Hepatitis Research*. Edited by Francis B Chisari. New York, Masson, 1984, pp 80-90
19. Huang SH, Neurath AR: Immunohistologic demonstration of hepatitis B viral antigens in liver with reference to its significance in liver injury. *Lab Invest* 1979, 40:1-17
20. Demetris AJ, Lasky S, VanTheil DH, Starzl TE, Whiteside T: Induction of DR/Ia antigens in human liver allografts: An immunocytochemical and clinicopathologic analysis of twenty failed grafts. *Transplantation* 1985, 40:504-509
21. Snover DC, Sibley RK, Freese DK, Sharp HL, Bloomer JR, Narjarian JS, Ascher NL: Orthotopic liver transplantation: A pathologic study of 63 serial liver biopsies from 17 patients with specific reference to the diagnostic features and natural history of rejection. *Hepatology* 1984, 4:1212-1222
22. Wight DGD: Pathology of rejection, *Liver Transplantation: The Cambridge/Kings College Experience*. Edited by RY Calne. New York, Grune & Stratton, 1983, pp 247-277
23. Fennell RH, Shikes RH, Vierling JM: Relationship of posttransplant hepatobiliary disease to bile duct damage occurring in the liver allograft. *Hepatology* 1983, 3:84-89
24. Daar AS, Fuggle SV, Fabre JW, Ting A, Morris PJ: The detailed distribution of HLA-A, B, C antigens in normal human organs. *Transplantation* 1984, 38:287-292
25. Daar AS, Fuggle SV, Fabre JW, Ting A, Morris PJ: The detailed distribution of MHC class II antigens in normal human organs. *Transplantation* 1984, 38:293-298
26. Gudat F, Bianchi L, Sonnabend W, Thiel G, Aenishaenslin W, Stadler GA: Pattern of core and surface expression in liver tissue reflects state of specific immune response in hepatitis B. *Lab Invest* 1975, 32:1-9
27. Parfrey PS, Forbes RDC, Hutchinson TA, Kenick S, Farge D, Dauphinee WD, Seely JF, Guttman RD: The impact of renal transplantation on the course of hepatitis B liver disease. *Transplantation* 1985, 39:610-615

Acknowledgment

We would like to thank Brenda Jones for preparation of the manuscript.