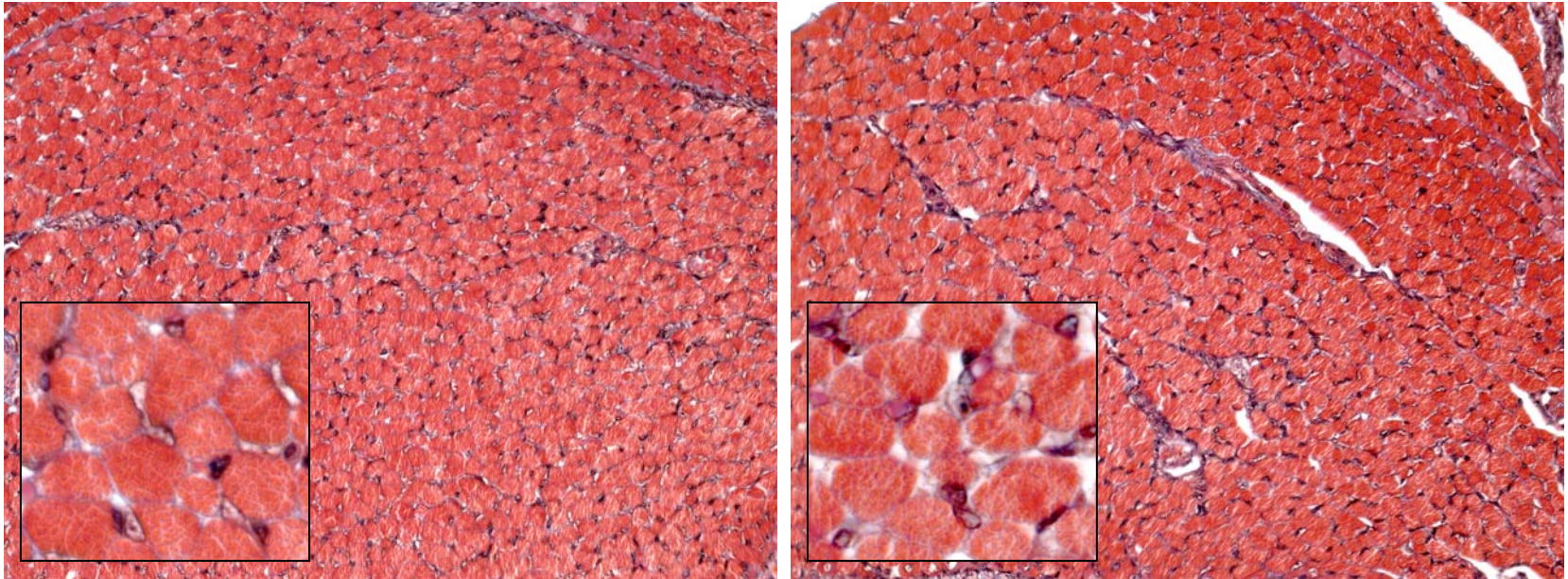


Supplementary Figure

knockout

wild type



Pathological analysis of skeletal muscle. Skeletal muscle from affected and wild type, 10 day old mice was excised, prepared for staining, stained with Masson's Trichrome solution and photographed as described in Materials and Methods. 20X magnification and inset 100X magnification.