

primary siderosis was largely made on histological grounds. The extent and activity of the cirrhotic process appeared to be out of keeping with the degree of siderosis present. In J C, for instance, the histological sections showed considerable cellular infiltration and liver cell necrosis, indicating an actively progressing lesion, yet there was a relatively minor amount of iron present. In occasional cases of secondary siderosis the degree of iron overload can approach that seen in idiopathic hæmochromatosis, but even in these there may be evidence from previous biopsies that the cirrhosis preceded the iron deposition (Sabesin & Thomas 1964).

A real problem arises when liver biopsy is impossible owing to a prolonged prothrombin time or a low platelet count, and in these patients some other way of assessing iron overload has to be used. Several workers have attempted to assess body iron stores by measuring urinary iron excretion after a parenteral injection of a 500–2,000 mg dose of the iron chelating agent desferrioxamine. A varying proportion of the iron in ferrioxamine formed as a result of chelation is, however, re-utilized for hæmoglobin synthesis so that measurement of the amount of iron excreted underestimates the amount formed in the body by chelation. Fielding (1965) therefore developed a technique in which a marker dose of ^{59}Fe -labelled ferrioxamine is given at the same time as the desferrioxamine. From the amount of ferrioxamine excreted in the urine which is estimated chemically and the proportion of the radioactive dose that appears there it is possible to calculate the total amount of ferrioxamine formed in the body by chelation. This value, known as the F_v , is a measure of the total chelatable iron stores.

Our results using this technique are shown in Fig 2. The range of values in control subjects is fairly wide. Only one of the patients with alcoholic cirrhosis had an increased F_v though there were 10 patients in this group with siderosis on liver biopsy. In idiopathic hæmochromatosis very high values were observed both in the untreated and in the partially treated patients. After completion of venesection therapy values were lowered. In one of the 5 patients with infective hepatitis the F_v was increased although liver biopsy showed no siderosis. This may be due to the effect of hæmolysis for there is evidence that iron newly released by hæmoglobin breakdown is more readily chelatable than that present as hæmosiderin or ferritin in the tissue stores (Fielding 1965). Recently Barry (1967, personal communication) has developed a similar isotope technique using the iron chelating agent calcium diethylene triamine penta-acetic acid, which may have a greater affinity for iron in the stores. The use of these tests deserves further study.

REFERENCES

- Callender S T & Malpas J S (1963) *Brit. med. J.* ii, 1516
 Charlton R W, Jacobs P, Seftel H & Bothwell T H (1964) *Brit. med. J.* ii, 1427
 Fielding J (1965) *J. clin. Path.* 18, 88
 Grace N D & Balint J A (1966) *Amer. J. dig. Dis.* 11, 351
 Kimber C, Deller D J, Ibbotson R N & Lander H (1965) *Quart. J. Med.* 34, 33
 MacDonald R A (1964) *Hemochromatosis and Hemosiderosis*. Springfield, Ill.
 Sabesin S M & Thomas L B (1964) *Gastroenterology* 46, 477
 Schaefer J W, Amick C J, Oikawa Y & Schiff L (1962) *Gastroenterology* 42, 181
 Scheuer P J, Williams R & Muir A R (1962) *J. Path. Bact.* 84, 53
 Smith M D & Pannaciuoli I M (1958) *Brit. J. Haemat.* 4, 428
 Smith P M, Studley F & Williams R (1967) *Lancet* i, 133
 Williams R, Williams H S, Scheuer P J, Pitcher C S, Loizeau E & Sherlock S (1967) *Quart. J. Med.* 36, 151

Dr Peter J Scheuer

(Department of Pathology,
 Royal Free Hospital, London)

Primary Biliary Cirrhosis

Among cases of chronic obstructive jaundice there is a minority in which no block can be demonstrated either in the extrahepatic bile ducts or in their major intrahepatic tributaries. These are not all examples of primary biliary cirrhosis. Other causes of chronic intrahepatic cholestasis include nodular cirrhosis, drug sensitivity, ulcerative colitis and Hodgkin's disease. Primary biliary cirrhosis does not merely represent the exclusion of these, but forms a distinctive pathological entity.

The disease is typically one of middle-aged women. Men are occasionally affected. The presenting symptom in most cases is itching. This is followed by jaundice, and skin pigmentation and xanthomas may develop. As in other forms of chronic obstructive jaundice there may be steatorrhæa and osteoporosis. The liver is enlarged and initially smooth to palpation. In a proportion of patients the spleen is also palpable. Portal hypertension and liver cell failure may develop late in the course of the disease. Primary biliary cirrhosis is a fatal condition, the mean survival from the onset of symptoms being of the order of five to six years (Sherlock 1959).

Biochemical changes in the earlier stages of the disease are typical of cholestatic jaundice. Serum bilirubin levels are moderately and, occasionally, greatly raised. Serum alkaline phosphatase is usually much increased but serum 5'-nucleotidase rises proportionately higher, to about twice the phosphatase level (Hobbs 1967, personal communication). The serum cholesterol may reach levels of over 1,000 mg/100 ml. There is little

evidence of liver cell dysfunction. As the disease progresses, however, moderate increases in transaminase levels are not unusual, and reflect liver cell breakdown.

In recent years interest has been aroused in immunological aspects of the disease. A number of different antibodies can be demonstrated in the sera of patients. Paronetto *et al.* (1964) found antiductular antibodies, rheumatoid factor and antibodies against nuclear material in the sera of patients with the disease, and were able to identify γ_1 M globulin in hepatic mesenchymal cells. Antinuclear factors were found in 19 of 41 patients investigated by Doniach *et al.* (1966) and antibodies against thyroid and smooth muscle were also described. None of these antibodies is sufficiently specific to primary biliary cirrhosis to be of diagnostic value. However, the great majority of patients with the disease have in their serum an antibody against mitochondria, detectable by immunofluorescence (Walker *et al.* 1965, Doniach *et al.* 1966, Goudie *et al.* 1966). This antibody is present in almost every case and is rarely found in large duct biliary obstruction, the chief differential diagnosis. It is usually detected by its binding to the mitochondria of human kidney cells, but the choice of organ is not critical. High titres are obtained in diseases other than primary biliary cirrhosis, including cryptogenic cirrhosis, active chronic hepatitis and diseases of organs other than the liver. Preliminary investigations of the specificity of the reaction suggest that some of the positive results in diseases other than primary biliary cirrhosis are due to the presence of other antibodies and it is hoped that further work will improve this already strikingly helpful test (Doniach 1967, personal communication).

From the pathologist's point of view the alternative name for primary biliary cirrhosis, chronic nonsuppurative destructive cholangitis (Rubin *et al.* 1965), accurately describes the basic lesion and has the further merit of avoiding the term 'cirrhosis'. The latter is misleading since nodular cirrhosis only develops in a proportion of cases late in the course of the disease. There is indeed a striking change in the pathology as the disease progresses to its termination. Four stages to be considered (Rubin 1963) are the florid duct lesion, the stage of ductular proliferation, the stage of scarring and finally nodular cirrhosis. In many instances these stages are distinct but there may be considerable overlap.

Stage 1: The florid duct lesion (Fig 1): This is the most characteristic pathological component. The ducts first involved are the septal and larger interlobular ducts. Around these there are dense aggregates of lymphocytes and plasma cells, sometimes with a germinal centre. The lesion is

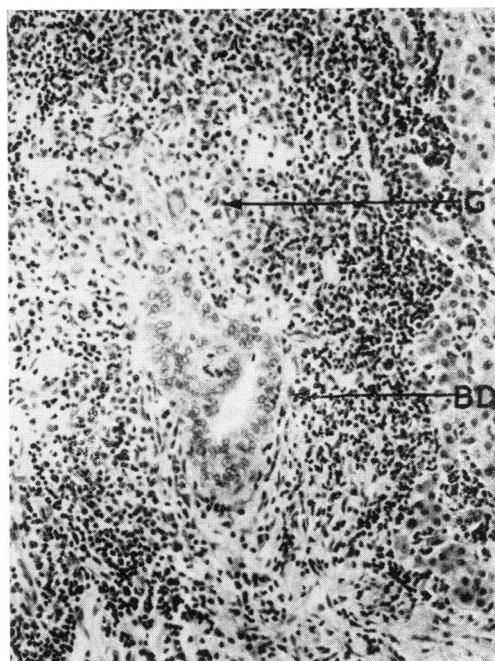


Fig 1 *Stage 1 lesion. A bile duct (BD) is damaged and surrounded by lymphocytes and plasma cells. Next to the duct there is a small granuloma (G) with a multinucleated giant cell. Hematoxylin and eosin $\times 80$*

patchy and other ducts appear normal or are surrounded by concentric layers of fibrous tissue. The duct epithelium in the affected areas is irregular and frank necrosis or rupture may be seen. The remainder of the portal tissue in which the damaged ducts lie is normal and the limiting plate of the parenchyma is usually intact. Within the lobules there are scattered mononuclear cells with basophilic cytoplasm, and there may be evidence of diffuse regeneration in the form of liver cell plates more than one cell thick. Cholestasis is usually absent at this stage, and its absence in a patient with obstructive jaundice is itself in favour of the diagnosis. It is presumed that in this instance the rise in serum bilirubin is due to regurgitation of bile through damaged ducts, rather than to a raised intrabiliary pressure with its consequent bile thrombus formation.

In the smaller portal tracts there is a nonspecific cellular infiltration, but although the smaller interlobular ducts are also eventually destroyed the striking peribiliary lesions are not evident. Since these are usually the only portal tracts in percutaneous needle biopsies, wedge biopsy is with few exceptions necessary for a definitive pathological diagnosis.

A noteworthy feature in the earlier stages of the disease is the presence of granulomas. These are usually close to the damaged ducts, often within

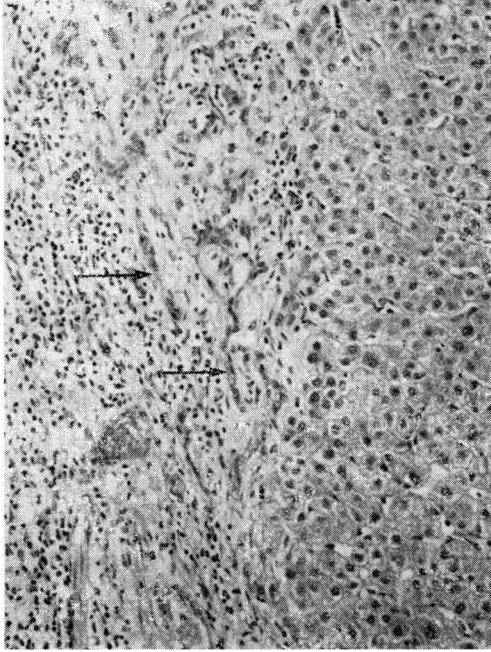


Fig 2 Stage 2. There is proliferation of ductules (arrows) set in young fibrous tissue. H & E $\times 80$

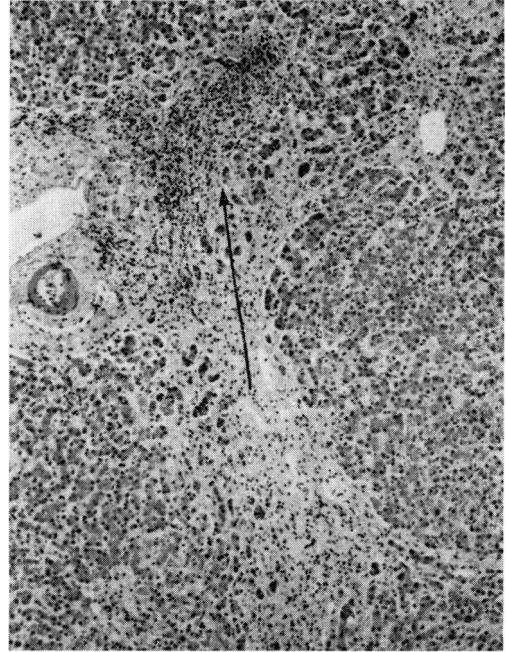


Fig 3 Stage 3. Dense fibrous tissue has formed. Ducts have been destroyed but a loose lymphoid aggregate (arrow) remains. H & E $\times 32$

the lymphoid aggregates. They may be poorly defined collections of histiocytes or well-formed sarcoid-like nodules. The granulomas, as well as the peribiliary cellular aggregates, are thought to be a reaction to irritant and possibly antigenic glycoprotein derived from the damaged duct epithelium (Rubin *et al.* 1965). Less often granulomas are found elsewhere in the liver or even in other parts of the body.

Although the lesions described are those of an early stage of the disease they are sometimes seen in biopsies taken years after the onset of symptoms.

Stage 2: Ductular proliferation (Fig 2): All portal tracts are now involved and the lesion is therefore seen in most needle biopsies. At the same time, however, the appearances have become less specific and less easy to diagnose with certainty. They may mimic those of large duct biliary obstruction. In Stage 2 the portal tracts are expanded by young cellular connective tissue in which there are ductules. Ducts are scanty. An inflammatory infiltrate includes both mononuclear cells and neutrophils. Lymphoid aggregates and occasionally granulomas are present but have become less distinct. Collections of foamy macrophages may be seen. At the junction of fibrous tissue and parenchyma there is mild piecemeal necrosis; here liver cells are swollen and pale-staining and are interspersed with inflamma-

tory cells. Bile is sometimes seen in this region. Lobular structure is still intact.

Stage 3: Scarring (Fig 3): The inflammation of Stage 2 subsides, leaving scars in which few ductules or inflammatory cells remain. Some of the scars curve so as to suggest incipient nodule formation but true regeneration nodules are absent and lobular architecture is preserved. Ducts are now very scanty, but their former sites are marked by poorly delimited collections of lymphocytes. The obliteration of the intrahepatic biliary tree leads to increasing cholestasis, characteristically most prominent in the part of the parenchyma nearest to the scars.

Some patients die at this stage, before true nodular cirrhosis has developed. The pathological appearances at autopsy are less specific than in early stages of the disease, but the diagnosis is suggested by the extent of bile duct loss. Baggenstoss *et al.* (1964) found the mean number of ducts per portal area to be reduced to one-quarter of the normal figure. In cases of secondary biliary cirrhosis there was no reduction in the number of ducts.

Stage 4: Nodular cirrhosis (Fig 4): Finally, as fibrous tissue encroaches extensively on the hepatic parenchyma and nodular regeneration develops, the appearances becomes those of an 'end-stage' liver. This, together with failure to appreciate the distinctive stages of primary

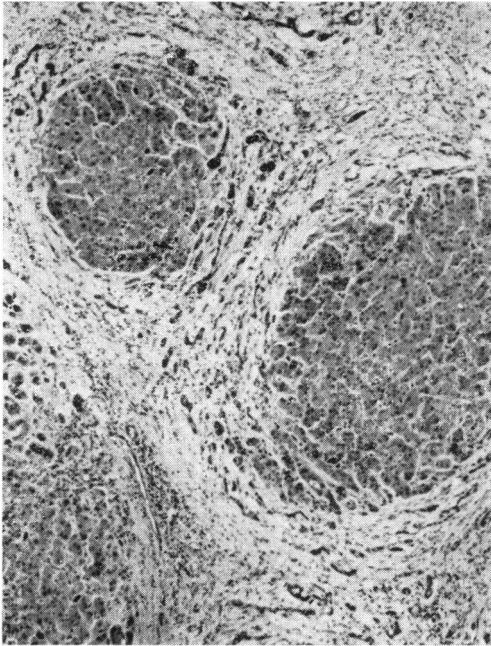


Fig 4 Stage 4. There are regeneration nodules and broad fibrous septa. H & E $\times 32$

biliary cirrhosis, has led to doubts as to the specificity of the disease process. Even in the cirrhotic stage, however, reduction in the number of ducts may enable a tentative retrospective diagnosis to be made.

Primary biliary cirrhosis, then, must be regarded as a pathological entity. It is by no means certain that it represents a single aetiology. Whilst some cases of the disease have been ascribed to drugs (Foulk *et al.* 1964) no agent has been shown to account for a substantial proportion of cases. The occasional finding of somewhat similar bile duct lesions in other diseases, including large duct biliary obstruction, strengthens the impression that primary biliary cirrhosis represents a pathogenetic mechanism initiated by a variety of factors.

REFERENCES

- Baggenstoss A H, Foulk W T, Butt H R & Bahn R C (1964) *Amer. J. clin. Path.* 42, 259
 Doniach D, Roitt I M, Walker J G & Sherlock S (1966) *Clin. exp. Immunol.* 1, 237
 Foulk W T, Baggenstoss A H & Butt H R (1964) *Gastroenterology* 47, 354
 Goudie R B, MacSween R N M & Goldberg D M (1966) *J. Clin. Path.* 19, 527
 Paronetto F, Schaffner F & Popper H (1964) *New Engl. J. Med.* 271, 1123
 Rubin E (1963) *Gastroenterology* 45, 400
 Rubin E, Schaffner F & Popper H (1965) *Amer. J. Path.* 46, 387
 Sherlock S (1959) *Gastroenterology* 37, 574
 Walker J G, Doniach D, Roitt I M & Sherlock S (1965) *Lancet* i, 827

Dr M N Berry¹

(Royal Postgraduate Medical School, London)

The Liver and Lactic Acidosis

Lactic acidosis is a condition in which abnormal amounts of lactate accumulate in the blood. As Tranquada *et al.* (1966) have stressed, the definition of lactic acidosis remains arbitrary. At the pH of body tissues and blood, lactic acid is completely dissociated and the production of lactate is accompanied by an equivalent formation of hydrogen ion. Thus any significant elevation of the blood lactate indicates that a substantial production of hydrogen ion has also taken place. It therefore seems reasonable to call the condition in which a high blood lactate persists 'lactic acidosis', regardless of resultant pH or bicarbonate levels. Tranquada *et al.* (1966) take an arterial or venous level of >7 mM as indicating lactic acidosis. They point out that this level represents a severe accumulation of lactate and is associated with a very high mortality when it occurs more than transiently. The steady-state level of lactate in arterial blood of the normal resting subject is about 1mM (Huckabee 1961a). (Note: Throughout this paper the term 'lactate' refers to the naturally occurring L-lactate isomer).

Since Huckabee (1961b) published his series of 9 fatal cases of lactic acidosis, much interest has been aroused in this condition. Tranquada (1964) reviewed the literature and collected 70 cases. Since then his own group have described their own series of 46 cases (Tranquada *et al.* 1966).

Many suggestions have been put forward as to why lactic acid accumulates in these patients, but no definite conclusions have been reached. In this paper a possible explanation will be advanced, based on current knowledge of the quantitative aspects of lactate metabolism.

The abnormal accumulation of any metabolite in the blood is evidence that the rate of its production has exceeded the rate of its disposal. In the normal human subject, the only tissue cells which are known consistently to produce lactic acid are the erythrocytes. It has been estimated that these cells produce about 25g lactate per day (Krebs 1964). Skeletal muscle is probably the other major source of lactic acid in the normal subject, but moderate steady-state exercise does not lead to accumulation of lactate in the blood (Bock *et al.* 1932). There is usually a sharp rise in blood lactate when exercise commences, but it has been demonstrated that men can work at up to two-thirds of their maximum metabolic rate without further increase in blood lactate levels

¹Present address: Division of Clinical Pathology, University of California, San Francisco Medical Center, San Francisco, California 94122, USA