

# Subendocardial Ischemic Myocardial Lesions Associated With Severe Coronary Atherosclerosis

Jack C. Geer, MD, Charles A. Crago, DMD, William C. Little, MD,  
Lloyd L. Gardner, MD, and Sanford P. Bishop, DVM, PhD

Morphologic changes in the subendocardial myocardium that appeared to be caused by severe, chronic subendocardial ischemia were studied in patients with fatal ischemic heart disease admitted to the Specialized Center of Research for Ischemic Heart Disease at the University of Alabama in Birmingham in the period 1970-1977. Thirteen patients were selected for this report on the basis that they had the lesions in the subendocardial myocardium we believe to have been caused by subendocardial ischemia and had no evidence of acute or remote myocardial infarction or other conditions that may have contributed to their terminal illness or death. Clinical findings were unstable angina, congestive heart failure, usually no increase in plasma enzymes indicative of myocardial damage, and electrocardiographic changes consistent with subendocardial ischemia. All 13 patients had 75% or greater stenosis of the three major coronary arteries; none had acute thrombotic or embolic coronary artery occlusion. The left ventricle in all cases was hypertrophied. The subendocardial myocardium showed circumferential pallor, hyperemia, or focal fibrosis without perceptible loss of volume in papillary muscles or trabeculae carneae. Microscopically, acute lesions showed one to two layers of preserved myofibers adjacent to the endocardium, vacuolar change in the deeper fibers, and focal areas of coagulation necrosis of variable size in the myocardium external to the fibers with vacuolar change. Coagulation necrosis was extensive in some cases and usually was not associated with infiltration of neutrophils. The repair reaction involved removal of necrotic sarcoplasm by mononuclear phagocytes, resulting in a reticular-appearing tissue without evidence of stromal collapse. Granulation tissue was not seen. Collagen fibers appeared to be deposited within the area of previous sarcolemmal sheaths. The distribution and morphology of subendocardial myocardial lesions associated with severe coronary atherosclerosis are distinctive and can be distinguished from myocardial necrosis or fibrosis associated with acute total occlusion of a coronary artery. (*Am J Pathol* 1980, 98:663-680)

IN THE COURSE OF MORPHOLOGIC STUDY of hearts from patients dying in the Specialized Center for Research for Ischemic Heart Disease at the University of Alabama in Birmingham we observed lesions in the subendocardial myocardium that differed grossly and microscopically from acute or healed myocardial infarcts associated with acute cor-

---

From the Departments of Pathology and Medicine, University of Alabama Medical Center, Birmingham, Alabama.

Supported in part by Specialized Center of Research for Ischemic Heart Disease Contract 5POHL17667-04, Program Project Grant HL-11310, Clinical Research Unit Grant MO-RR000-13, and the General Clinical Research Centers Program Division of Research Resources, National Heart and Lung Institute.

Accepted for publication September 25, 1979.

Address reprint requests to Jack C. Geer, MD, Professor and Chairman, Department of Pathology, University of Alabama in Birmingham, University Station, Birmingham, AL 35294.

onary artery occlusion. This observation prompted us to review autopsy cases from the Center to study further myocardial lesions that appeared to be due to chronic subendocardial ischemia. This report records the morphology of lesions in the subendocardial myocardium associated with severe coronary atherosclerosis. The lesions are characterized by layers or zones of subendocardial myofiber vacuolar change and coagulation necrosis with subsequent phagocytic removal of necrotic sarcoplasm and replacement fibrosis.

### Materials and Methods

Cases for this study were derived from admissions to the Specialized Center of Research for Myocardial Infarction autopsied in the period 1970–1977. The basis for admission to the Center was symptoms of myocardial ischemia or infarction. Patients were followed with serial electrocardiograms (ECG) and determination of plasma lactic acid dehydrogenase (LDH), glutamic-oxalacetic transaminase (GOT), and creatine kinase (CK) at intervals of 8 or 12 hours. Hemodynamic monitoring was done when indicated.

Autopsies were performed from 4 to 24 hours after death. Coronary arteries were cannulated through the aortic ostia. The coronaries were perfused with normal saline for 15–30 minutes, followed by 10% neutral buffered formalin at a pressure of 90–100 mm Hg for 30 minutes. The coronary arteries were then washed with saline, and a modified Schlesinger<sup>1</sup> mass consisting of gelatin and barium (Micropaque, E.I. Dupont de Nemours Co., Inc., Wilmington, Del) was injected into them. Radiographs were made of the whole heart, the ventricles were sectioned horizontally at 1-cm intervals to the base of the heart, and the slices were radiographed and photographed.

Coronary arteries were sectioned transversely at 3-mm intervals, and a map was drawn indicating location and grossly estimated degree of stenosis. Maximal areas of stenosis were examined microscopically to determine the degree of stenosis and the presence or absence of lesion complications such as plaque rupture, thrombosis, or hemorrhage. Tissues for histologic study were taken from all gross lesions and representative areas of normal-appearing septum, right ventricle, and anterior, lateral, and posterior walls of the left ventricle. Tissues for histology were embedded in paraffin, sectioned at 6  $\mu$ , and stained routinely with hematoxylin and eosin and either the Goldner trichrome or Gomori aldehyde fuchsin-trichrome. In selected cases sections were stained with the periodic acid-Schiff (PAS) method with and without diastase digestion, von Kossa, or Alcian blue-PAS. Formalin fixed frozen sections were stained with oil red O for fat in selected cases.

A total of 105 cases was identified as having ischemic heart disease by the criteria of 1) recent or healed myocardial infarction and/or 2) one or more major coronary arteries with 75% or more lumen obstruction. Healed myocardial infarction was defined as a myocardial replacement scar 8 cu cm or greater in size.<sup>2</sup> Recent myocardial infarction, defined as coagulation necrosis of the myocardium with inflammatory cellular or reparative reaction as described by others,<sup>3–5</sup> was present in 33 cases. There was thrombotic occlusion in the coronary artery to the area of infarction in 29 (88%). The lesions of subendocardial ischemia we describe in this report were found in 46 of the 105 cases (44%). From these 46 cases we selected 13 for clinicopathologic correlation by excluding other disease conditions that may have contributed to the terminal illness and death. The excluded conditions were acute or healed myocardial infarction, valvular heart disease, chronic obstructive pulmonary disease, postoperative status, pulmonary embolism, or cancer.

## Results

Table 1 summarizes clinical findings for the 13 patients with subendocardial ischemic lesions. All had anginal chest pain, and in 9 the duration of anginal symptoms was more than one year. In all cases the anginal pattern had become more severe prior to hospital admission, either occurring at rest or for more prolonged periods than had been experienced previously. Most patients had symptoms of congestive heart failure with pulmonary venous congestion evident in the chest radiograph in 11 of the 13 cases.

Two cases (11 and 12) had plasma enzyme evidence of myocardial infarction. Most of the remaining cases had mild elevations of GOT, LDH, and/or CK, but isoenzyme determinations were not consistent with myocardial origin. Patient 11 had severe anginal pain two weeks prior to death associated with enzyme changes of myocardial necrosis. The ECG was consistent with an acute anterior transmural infarction with ST elevation and the development of Q-waves in leads V1-V4. There was no evidence of an acute or healing transmural infarct at autopsy. Patient 12 did not have ECG evidence of infarction; there was an intraventricular conduction delay initially with a subsequent left bundle branch block.

Two patients (4 and 10) had ECG changes consistent with healed inferior myocardial infarction. Patient 4 at autopsy demonstrated focal small (less than 5 mm) areas of subendocardial fibrosis that were most evident in the anterior and posterior free wall of the left ventricle (Figure 1). Patient 10 at autopsy had marked concentric left-ventricular hypertrophy with many focal small areas of subendocardial fibrosis in the free wall of the left ventricle and interventricular septum. Neither case had a discrete scar that approached the size limit for healed myocardial infarction defined by Schwartz and Mitchell.<sup>2</sup>

The most common ECG pattern was ST and T wave changes consistent with subendocardial ischemia or infarction<sup>6</sup> (Table 1). Left bundle branch block was present or developed in 5 cases.

The clinical cause for death was refractory ventricular arrhythmia or shock. More than half of the patients decompensated abruptly, with adequate blood pressure having been documented within 30 minutes of death. Two patients had shock for more than 6 hours prior to death.

A summary of anatomic findings for the 13 cases is presented in Table 2. All 13 cases had severe stenosing lesions in the three major coronary arteries. Microscopic examination showed no acute changes in the coronary lesions such as plaque hemorrhage or acute thrombosis. Case 6 had an organizing mural thrombus in the left anterior descending branch.

Table 1—Summary of Clinical Data

Case	Age	Sex	Duration of angina	Hyper-tension	DM*	CHF†	Pulmonary artery pressure (mm Hg)	Duration of shock terminally (BP <90 mm Hg systolic)	Electrocardiogram	Enzymes‡
1	71	F	3 yrs	+	+	+	42/16	14 hrs	LBBB	-
2	70	M	2 yrs	0	0	+	45/30	1 hr	LBBB	-
3	59	M	15 yrs	0	0	+	—	<1/2 hr	Anterior T wave inversion	-
4	65	M	7 yrs	+	0	+	60/30	<1/2 hr	New LBBB	-
5	63	M	6 mos	+	0	+	36/30	6 hrs	Old inferior myocardial infarct	-
6	69	M	1 yr	0	+	+	—	<15 mins	LVI, † ST depression, T-wave inversion, transient Q waves in inferior leads	-
7	65	M	9 yrs	+	0	+	40/30	5 hrs	LVI †	-
8	64	M	3 mos	0	0	-	—	<1/2 hr	ST depression and T-wave inversion	-
9	69	M	10 yrs	+	+	-	—	<1/2 hr	ST depression and T-wave inversion	-
10	59	F	3 yrs	+	+	+	LVEDP§ = 35	<1/2 hr	Old inferior myocardial infarct, ST depressio., New Q waves and ST elevation in leads V1-V4	-
11	57	M	2 wks	+	0	+	—	<1/2 hr	LBBB	+
12	76	F	15 yrs	0	+	+	49/30	9 hrs	LBBB	+
13	66	F	1 mo	+	+	+	—	<1/2 hr	LBBB	-

\* DM = diabetes mellitus.

† CHF = congestive heart failure.

‡ Elevated lactic acid dehydrogenase (LDH) or creatine kinase (CK) cardiac fraction isoenzymes.

§ LVEDP = left ventricular end diastolic pressure.

|| LBBB = left bundle branch block.

†† LVH = left ventricular hypertrophy.

Table 2—Summary of Pathologic Data

Case	Vacuolar change	Necrosis	Fibrosis	Heart weight (g)	% Coronary obstruction†
1	++*	With PMN† +++	++	450	LC, 75; LAD, 75; LCC, 75; RC, 90
2	+	+	+++	700	RC, 100; LC, 100; LAD, 95
3	+	0	++	450	LAD, 80; LCC, 100; RC, 90
4	+	+	++	650	95, LAD, RC, LC
5	+	+++	+	400	LAD, 75; LCC, 80; RC, 90 (recanalized thrombus)
6	+	0	++	460	LAD, 90 organizing mural thrombus RC, 95; LCC, 100
7	++	+++	+	470	LAD, 80; LCC, 75; RC, 100
8	+++	++	+	440	LC, 10; RC, 80
9	++	0	++	510	LAD, 90; LCC, 100; RC, 100
10	+	0	++	350	LAD, 95; LCC, 75; RC, 95
11	++	++	++	410	100; LC (ostium); 90, RC (ostium)
12	++	Scant PMN +++	+	364	LAD, 75; LCC, 75; RC, 100
13	+++	++	+	550	LAD, 75; LCC, 100; RC, 75

\* Histologic semiquantitation of vacuolar change, necrosis, or fibrosis. + focal small lesions, not extensive; ++ focal moderately large lesions, present in many sections; +++ focal large lesions, present in nearly all sections.

† PMN = neutrophilic leukocyte reaction.

‡ LC = left main coronary; RC = right coronary, LAD = left anterior descending coronary; LCC = left circumflex coronary; 100% obstruction is a recanalized thrombus.

The left ventricle was hypertrophied in all cases. Gross lesions when present usually were circumferential and subendocardial in the left ventricle but were not uniform in appearance (Figures 1 and 2). The gross appearance of the left ventricle varied with the predominant type of lesion found microscopically. Hearts in which the predominant histologic lesion was subendocardial myofiber vacuolar change either appeared normal to the unaided eye or showed pallor in the subendocardial region with an opaque appearance and yellow-tan color. Fixation appeared to accentuate the lesion; however, gross changes in the myocardium were difficult to distinguish from fixation artifacts and required microscopic confirmation. Lesions characterized histologically by focal but extensive coagulation necrosis in the subendocardial myocardium appeared on gross examination either deep red (hyperemic) or very pale and opaque, with a tan color. Predominantly fibrous lesions in the subendocardium appeared as slightly depressed irregular patches of gelatinous-appearing gray or hyperemic tissue in sharp contrast to pale or normal-appearing surrounding myocardium.

The volume of papillary muscles and trabeculae carneae appeared normal in hearts with subendocardial ischemic necrosis (Figures 1 and 2). On gross examination, lesions in the free wall of the left ventricle appeared to involve the inner third of the wall. Histologically, the lesions were subendocardial and did not extend into the circumferentially oriented myofibers of the mid-mural myocardium.

Microscopically, there typically was a band of one or two well-preserved myofibers beneath the endocardium in papillary muscles or trabeculae carneae external to which myofibers in acute lesions showed sarcoplasmic vacuolar change and focal areas of coagulation necrosis (Figures 3-5). The extent of vacuolar change was variable, involving nearly all fibers in the subendocardium in some cases (Figure 3) but most commonly was evident in six to ten layers of myofibers external to the preserved fibers immediately adjacent to the endocardium (Figures 4 and 5).

The sarcoplasmic vacuolar lesion was characterized by the presence of clear vacuoles in the cytoplasm, displacing myofibrils. Fibers showing the least vacuolar change, presumably the earliest lesion, had small clear vacuoles in the sarcoplasm, enlarging the fiber slightly and apparently displacing myofibrils toward the sarcolemma (Figure 4). The vacuoles increased in size and number, apparently coalesced, and the myofibrils were limited to a thin rim beneath the sarcolemma. The most severely affected cells had a distinct sarcolemma, no visible organelles within the cytoplasm, and a central or slightly eccentric nucleus. The nucleus in the fibers with extensive vacuolation was irregular in contour, with chromatin

clumping at the nuclear membrane. An inflammatory cell response was not seen with the vacuolar change. Histochemical stains showed glycogen in the vacuolated fibers. Lipid and von Kossa stains were negative.

Coagulation necrosis of myofibers was seen in the central portion of trabeculae carneae or papillary muscles and varied in extent from a few fibers to large areas extending to the circumferentially oriented myofibers in the mid-mural myocardium (Figures 3 and 5). The necrotic fibers displayed increased eosinophilia of the sarcoplasm, usually with partially preserved cross-striations. Trichrome stains showed altered sarcoplasmic staining with a change from the normal orange fibers to red-orange with the Goldner stain and from normal red to light red or slate color with the Gomori stain. Nuclei in the necrotic fibers disappeared by karyolysis. Nuclear pyknosis was not seen. Contraction band necrosis was seen infrequently in myofibers at the periphery of areas of coagulation necrosis. Neutrophilic infiltration in areas of necrotic muscle seldom was observed but when present appeared to be in the center of the mass of necrotic fibers, with none in the peripheral area (Figures 5 and 6). Small arteries in the papillary muscles or trabeculae carneae coursing through areas of necrotic fibers typically were surrounded by one or more layers of normal or vacuolated myofibers (Figures 3, 5, and 7). Coagulation necrosis always was associated with vacuolar change in adjacent myofibers; however, vacuolar change was seen without necrosis (Table 2).

Necrotic sarcoplasm was removed by mononuclear macrophages. Phagocytes were found in the early stages of repair at the periphery of the necrotic tissue. Macrophage activity proceeded toward the center of the lesion. Healing lesions did not show granular basophilic interstitial tissue in the center of the lesion indicative of necrosis of neutrophils. Scattered interstitial erythrocytes were present in necrotic lesions, but marked hemorrhage was uncommon.

Removal of necrotic sarcoplasm by phagocytes left a reticular-appearing tissue with apparently intact microvasculature and no evidence of tissue collapse (Figure 8). Proliferation of capillaries and fibroblasts (granulation tissue) was not seen during the healing process. Collagen fibers appeared to be deposited in the space previously occupied by sarcoplasm, imparting an appearance of bundles of collagen separated by vascular spaces (Figures 9 and 10). Myofibers showing vacuolar change or appearing essentially normal surrounded arteries in the areas of developing fibrosis (Figures 8 and 9).

The healed lesion, subendocardial fibrosis, characteristically showed either vacuolated or normal-appearing myofibers adjacent to the endocardium. Tortuous, wide endothelial lined vessels often were present in

the fibrous tissue (Figure 9). These vessels were identified as arterial because they often contained barium injectant, which was not observed to pass through capillaries into venules in these hearts. The collagen fibers in the scar typically were arranged in bundles, simulating the appearance of myofibers (Figure 10). There was little or no perceptible loss of volume in the trabeculae carneae or papillary muscles associated with fibrosis.

Intramural coronary arteries and veins in these 13 cases were examined for intimal and medial lesions. All hearts showed infrequent arterial lesions in the form of medial thickening, medial fibrosis, or focal intimal hyperplasia. None of the cases had intramural arterial lesions that were sufficiently extensive or severe to suggest a role for such in causing reduced blood flow.

### Discussion

The cases we are reporting to illustrate the lesions of subendocardial ischemia represent two stages of selection. First, the patients had to have a clinical picture suggesting myocardial infarction in order to be admitted to the Center and had to have disease of such severity as to cause death. The second stage of selection was anatomic. Cases were selected that showed the lesion being described with no evidence of either myocardial infarction (recent or remote) or other conditions that may have contributed directly to the terminal illness and death. This selection increases the likelihood that the clinical features of the cases are related to the lesions in the subendocardial myocardium but does not allow us to determine the full clinical spectrum associated with these lesions, their incidence, or their occurrence in other clinical settings. We can say that in the entire group of cases with myocardial infarction or severe coronary heart disease (105 cases) the lesions of subendocardial ischemia were common; 46 cases (44%) had the lesions.

The clinical features and gross anatomic appearance of acute myocardial infarction have been well described.<sup>6,4-11</sup> The microscopic features of the subendocardial lesions we propose as characteristic of chronic subendocardial ischemia have been described,<sup>3,7-10</sup> but their association in the subendocardial myocardium as a distinctive lesion associated with chronic ischemia has not been recognized. The lesions of chronic subendocardial ischemia are subendocardial vacuolar change in myofibers often with foci of coagulation necrosis in the deeper musculature. The necrotic fibers seldom elicit a neutrophilic leukocyte response, and when such is present it is in the center of the focus of necrotic fibers. Necrotic fibers are removed by mononuclear macrophages, leaving a reticular appearing stroma in which collagen fibers appear to be deposited within the



residual sarcolemmal sheaths. There is no perceptible loss of tissue volume with scarring. Scars are permeated by small arteries surrounded by normal or vacuolated myofibers.

The pathogenesis of vacuolar degeneration in the myocardium is unknown. There is, however, ample evidence to indicate ischemia as a major cause for vacuolar degeneration. Myofiber lesions resembling, if not identical to, those in the human heart have been produced experimentally by maintaining rats in a low oxygen tension atmosphere for various periods of time.<sup>12,13</sup> Vacuolar degeneration in human hearts has been described with ischemic heart disease and referred to as myocytolysis<sup>3,14</sup> or colliquative myocytolysis.<sup>15</sup> We prefer not to use these terms, because they are neither descriptive nor etiologic. The content of the vacuolated fibers is not known, but the negative lipid stain in the present study and the electron-microscopic studies of similar experimental lesions suggest the principal constituent is water. Previous studies<sup>3,12-15</sup> and the present one provide no data with regard to reversibility, or the lack of it, of the vacuolated myofibers. In the present study, the observation of vacuolated fibers in areas of subendocardial fibrosis suggests that the vacuolar change has either persisted over the period of time required for fibrosis to develop or has reversed and subsequently recurred.

Coagulation necrosis with partial preservation of cross-striations is a well-known lesion due to ischemia.<sup>5,6,15</sup> The principal morphologic difference between the coagulation necrosis we are describing with chronic subendocardial ischemia and that seen with myocardial infarction associated with complete occlusion of a major coronary artery is the neutrophil response. Coagulation necrosis with chronic subendocardial ischemia usually was not associated with a neutrophil response. It is unlikely that the majority of lesions observed were too acute for a neutrophil response, since most showed near complete loss of myofiber nuclei by karyolysis, indicating necrosis of 24-72 hours' duration, at which time a neutrophil response should be prominent.<sup>4,5,15</sup> That a neutrophil response was present and disappeared due to necrosis of the cells does not seem likely, since we did not observe the diffuse basophilia in the tissue that remains following neutrophil necrosis. The reason for the usual absence of a neutrophil response is unknown. It is apparent that necrotic myofibers alone are not sufficient to evoke a neutrophil response.

A neutrophil response with coagulation necrosis of myofibers associated with chronic subendocardial ischemia when observed differed in localization from that with myocardial infarction associated with complete coronary artery occlusion. The neutrophil response in cases of subendocardial ischemia was in the center of the area of coagulation necrosis,

whereas with myocardial infarction neutrophil accumulation is diffuse in small lesions and at the periphery of large lesions.<sup>3</sup> The reason for the central localization of the neutrophil response in cases of subendocardial ischemia is unknown.

Phagocytic removal of necrotic myofibers in cases of subendocardial ischemia appears similar to that seen with acute myocardial infarction. With subendocardial ischemia we have not seen collapse of the stroma following phagocytic removal of the necrotic sarcoplasm. The subsequent scar is composed of fascicles of collagen that appear to have been deposited in the residual sarcolemmal sheaths. Granulation tissue has not been observed. The cellular origin of the collagen fibers is not known. The normal tissue volume and fascicular display of the collagen superficially simulating the appearance of myofibers contrast with a scar of myocardial infarction, where loss of tissue volume is readily evident and the scar is composed of a dense mass of parallel arrayed collagen fibers imparting a hyaline appearance.<sup>4,16</sup> The scar resulting from chronic subendocardial ischemia also differs from that of infarction in that it typically is permeated by small arteries sheathed by viable myofibers or myofibers exhibiting vacuolar degeneration, and the scar contains tortuous, wide vascular channels. By contrast, the scar resulting from myocardial infarction is poorly vascularized.

Contrary to previous reports,<sup>6,7-11,17</sup> we do not refer to the lesions associated with subendocardial ischemia as myocardial infarction, implying death of tissue due to a rapidly developing reduction in blood flow. We propose that with a chronic reduction in blood flow, due in these cases to severe three-vessel coronary heart disease, degeneration and necrosis of myofibers develops focally and repeatedly in the most distal part of the coronary circulation, the subendocardial myocardium. These lesions are the result of an imbalance between myocardial oxygen demand and coronary blood flow. With severe coronary atherosclerosis it would appear impossible to effect the increased blood flow needed to meet myocardial oxygen requirements in conditions associated with a positive chronotropic and inotropic response. Oxygen demand and diffusion into the myocardium also may be modified by diseases such as hypertension and diabetes mellitus associated with myocardial hypertrophy. These conditions were common in the cases being reported, as was congestive heart failure. Congestive failure with reduced cardiac output and, thus, reduced coronary blood flow would be expected to potentiate the subendocardial lesions. We suspect a vicious circle initiated by reduced coronary blood flow due to atherosclerosis, causing congestive failure, which in turn further decreased coronary blood flow, resulting in cardiogenic shock or an ischemia-induced arrhythmia.

Studies reported by others suggest that subendocardial lesions due to ischemia are detectable during life. A diffuse cardiac uptake of technetium-99m stannous pyrophosphate ( $^{99m}\text{Tc-PYP}$ ), which localizes in damaged myocardium, has been reported to occur in one-third of a series of cases of unstable angina.<sup>18</sup> Myofiber vacuolar change, coagulation necrosis, and fibrosis have been found in patients with a diffuse uptake of  $^{99m}\text{Tc-PYP}$  prior to death.<sup>19,20</sup> These observations suggest that the  $^{99m}\text{Tc-PYP}$  cardiac scan may provide a clinical means for recognizing subendocardial ischemia, and the lesions may be present in a significant number of patients with unstable angina.

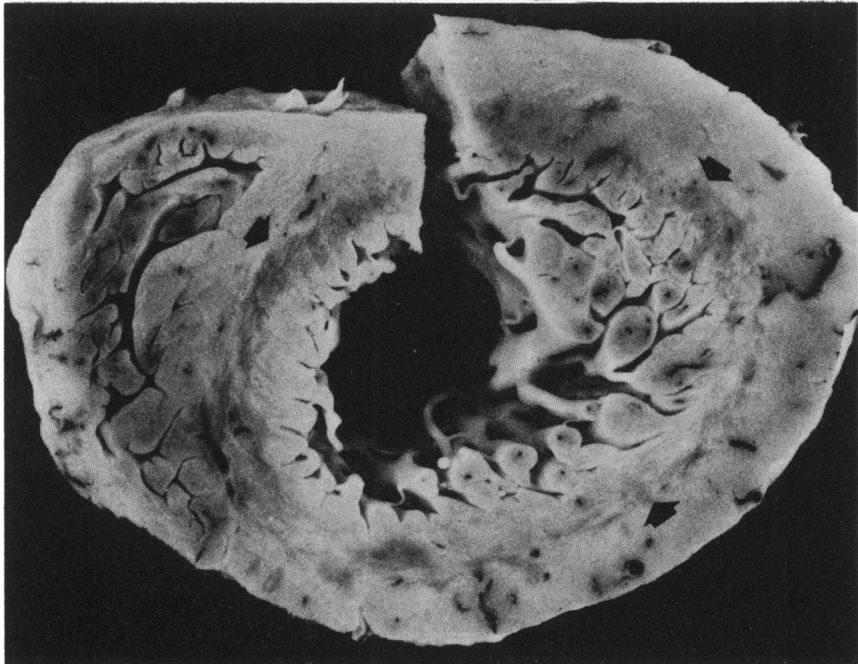
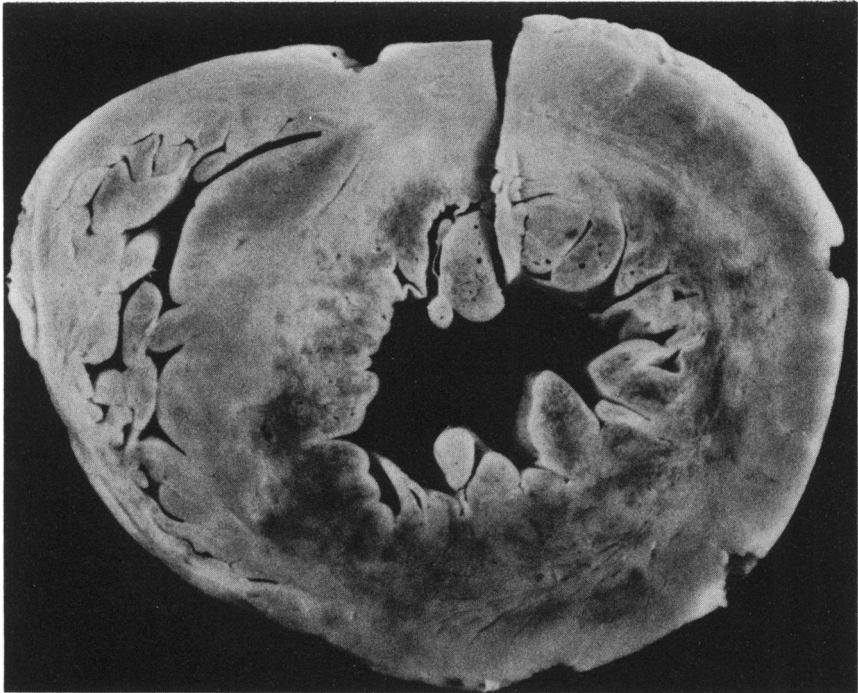The present study suggests that cardiac enzymes seldom are increased in the blood plasma as the lesions evolve. Eleven of the 13 patients studied did not have ECG nor enzyme evidence of myocardial infarction and would be clinically classified as unstable angina. The lack of elevated levels of cardiac enzymes in the plasma suggests the subendocardial myocardial lesions evolved slowly in these patients without producing a large myocardial enzyme leak at any one time.

Morphologic degenerative and necrotic lesions in the myocardium with severe three-vessel coronary heart disease were seen only in the subendocardial area. It is probable that these patients had global cardiac ischemia with morphologically evident lesions only in the most distal portion of the coronary circulation. It is hoped that anatomic recognition of this lesion will provoke interest in this form of chronic coronary heart disease.

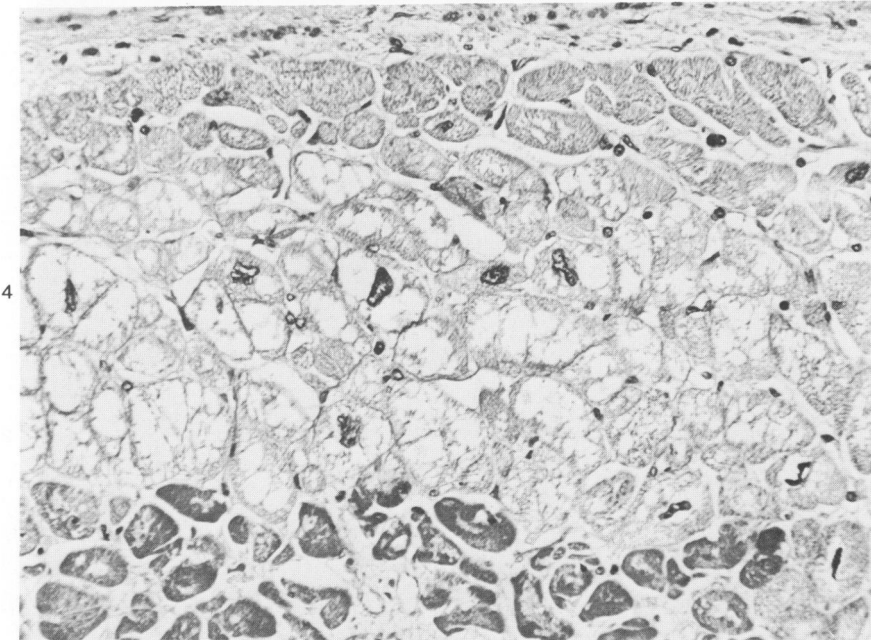
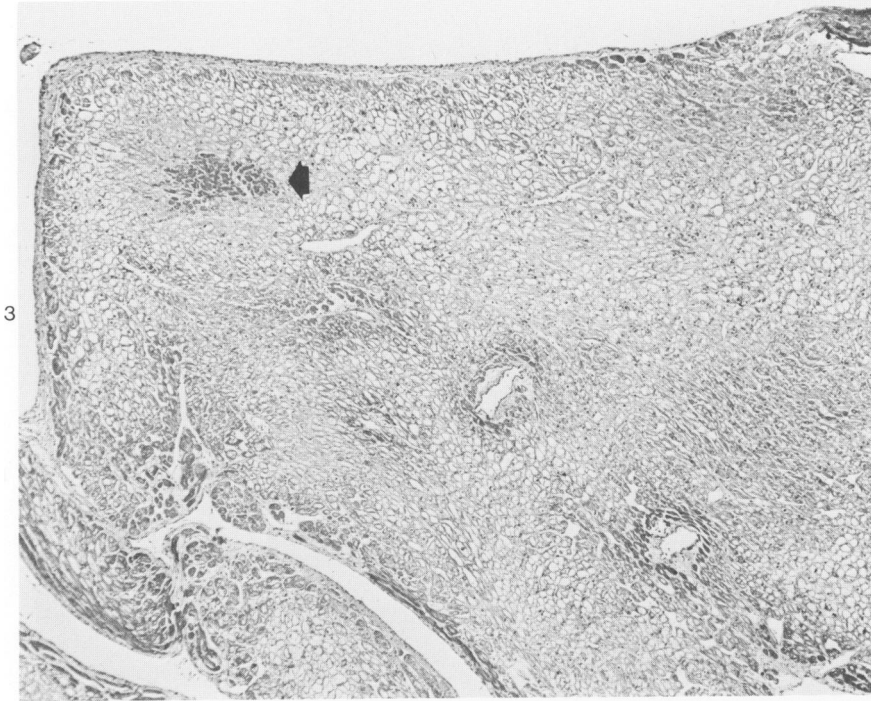
## References

1. Schlesinger MJ: An injection plus dissection study of coronary artery occlusions and anastomoses. *Am Heart J* 1938, 15:528-568
2. Schwartz CJ, Mitchell JRA: The relation between myocardial lesions and coronary artery disease: I. An unselected necropsy study. *Br Heart J* 1962, 24:761-786
3. Schlesinger MJ, Reiner L: Focal myocytolysis of the heart. *Am J Pathol* 1955, 31:443-459
4. Mallory GK, White PD, Salcedo-Salgar J: The speed of healing of myocardial infarction: A study of the pathologic anatomy in seventy-two cases. *Am Heart J* 1939, 18:647-671
5. Lodge-Patch I: The ageing of cardiac infarcts, and its influence on cardiac rupture. *Br Heart J* 1951, 13:37-42
6. Levine HD, Ford RV: Subendocardial infarction: Report of six cases and critical survey of the literature. *Circulation* 1950, 1:246-263
7. Roesler H, Soloff LA: Report of a case of left ventricular failure with unusual anatomical changes in the myocardium. *Ann Intern Med* 1935, 9:477-487
8. Friedberg CK, Horn H: Acute myocardial infarction not due to coronary artery occlusion. *JAMA* 1939, 112:1675-1679
9. Horn H, Field LE, Dack S, Master AM: Acute coronary insufficiency: Pathological and physiological aspects: An analysis of twenty-five cases of subendocardial necrosis. *Am Heart J* 1950, 40:63-80

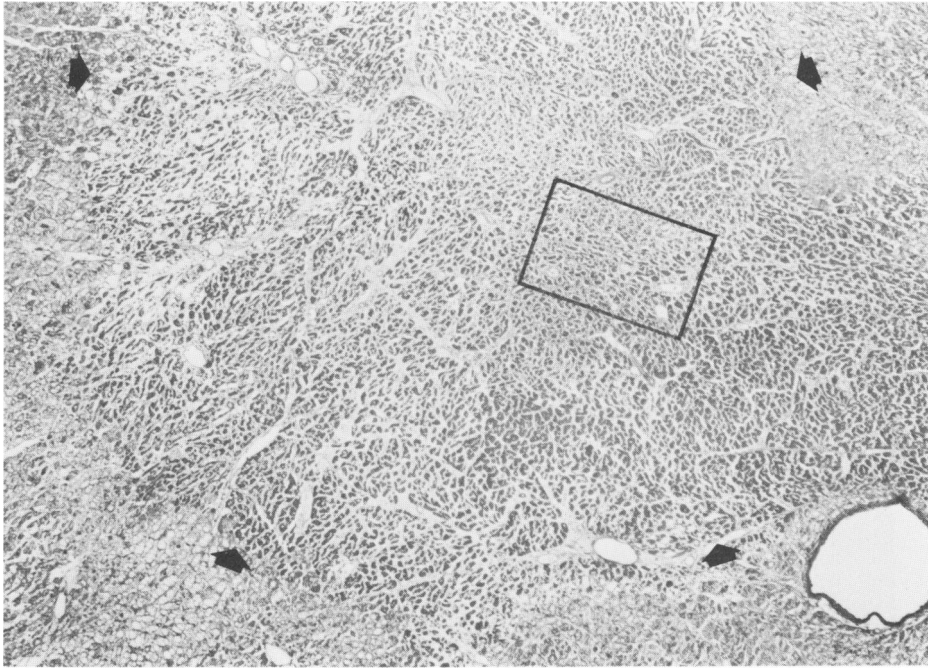
10. Sugiura M, Okada R, Iizuka H: A clinicopathological study on the subendocardial infarction in the aged. *Jpn Heart J* 1969, 10:203-217
11. Bouch DC, Montgomery GL: Cardiac lesions in fatal cases of recent myocardial ischaemia from a coronary care unit. *Br Heart J* 1970, 32:795-803
12. Hasper B: Ultramikroskopische Herzmuskelveränderungen nach weiderholter Hypoxie. *Beitr Pathol Anat* 1964, 130:321-351
13. Sulkin NM, Sulkin DF: An electron microscopic study of the effects of chronic hypoxia on cardiac muscle, hepatic, and autonomic ganglion cells. *Lab Invest* 1965, 14:1523-1546
14. Connor RCR: Focal myocytolysis and fuchsinophilic degeneration of the myocardium of patients dying with various brain lesions. *Ann NY Acad Sci* 1969, 156:261-270
15. Baroldi G: Different types of myocardial necrosis in coronary heart disease: A pathophysiologic review of their functional significance. *Am Heart J* 1975, 89:742-752
16. Heggveit HA: Morphological alterations in the ischaemic heart. *Cardiology* 1971/72, 56:284-290
17. Brand FR, Brown AL Jr, Berge KG: Histology of papillary muscles of the left ventricle in myocardial infarction. *Am Heart J* 1969, 77:26-32
18. Donsky MS, Curry GC, Parkey RW, Meyer SL, Bonte FJ, Platt MR, Willerson JT: Unstable angina pectoris: Clinical, angiographic, and myocardial scintigraphic observations. *Br Heart J* 1976, 38:257-263
19. Buja LM, Poliner LR, Parkey RW, Pulido JI, Hutcheson D, Platt MR, Mills LJ, Bonte FJ, Willerson JT: Clinicopathologic study of persistently positive technetium-99m stannous pyrophosphate myocardial scintigrams and myocytolytic degeneration after myocardial infarction. *Circulation* 1977, 56:1016-1023
20. Poliner LR, Buja LM, Parkey RW, Bonte FJ, Wilterson JT: Clinicopathologic findings in 52 patients studied by technetium-99m stannous pyrophosphate myocardial scintigraphy. *Circulation* 1979, 59:257-267



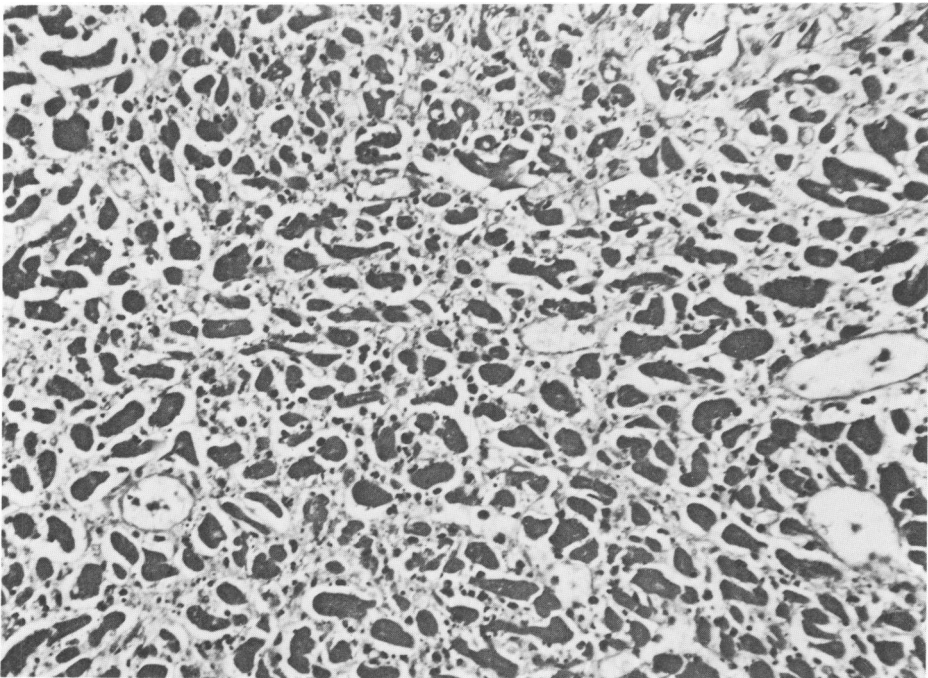
**Figure 1**—Case 4. The subendocardial myocardium of the left ventricle has multiple areas with a hemorrhagic (*dark*) appearance which are most prominent in the anterior septum (*bottom*) and anterior and lateral free walls (*right*). The nonhemorrhagic areas in the left ventricle show marked pallor. There is no evidence of healed infarction. ( $\times 0.9$ ) **Figure 2**—Case 3. There is a circumferential subendocardial zone in the left ventricle that is slightly depressed (*arrows*) from the adjacent mid-mural myocardium and has focal, small dark areas of hyperemia. The circumferential lesion is not uniform in appearance. The hyperemic appearance is due to the rich vasculature of the scar tissue. ( $\times 1$ )



**Figure 3**—Case 13. Horizontal section of left ventricle showing trabeculae carneae with extensive vacuolar cytoplasmic change in the myofibers and a focal area of coagulation necrosis (arrow). In several areas adjacent to the endocardium and small arteries in the myocardium, the myofibers are darker in appearance and under higher magnification are more normal in appearance than the vacuolated fibers in the central portion of the trabecula. Compare the extent of vacuolar change and coagulation necrosis in this micrograph with that in Figure 5. Fibers with vacuolar change in this micrograph are similar to those seen under higher magnification in Figure 4. (H&E,  $\times 70$ ) **Figure 4**—Case 12. Endocardium (top) appears normal. One to two layers of fibers beneath the endocardium appear normal or show mild vacuolar change. Myofibers in the middle of the micrograph show marked vacuolar change. Nuclei of vacuolated fibers are enlarged, irregular in shape, and show chromatin clumping at the nuclear membrane. There is peripheral displacement of myofilaments by sarcoplasmic vacuoles. The dark fibers at the bottom of the micrograph exhibit coagulation necrosis with loss of nuclei and intense cytoplasmic staining with eosin. (H&E,  $\times 420$ )

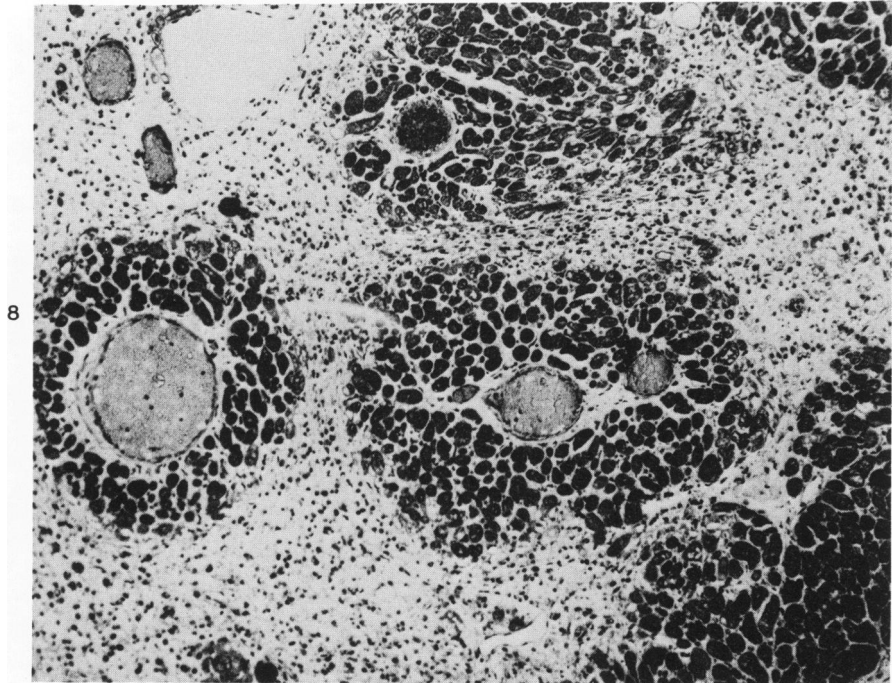
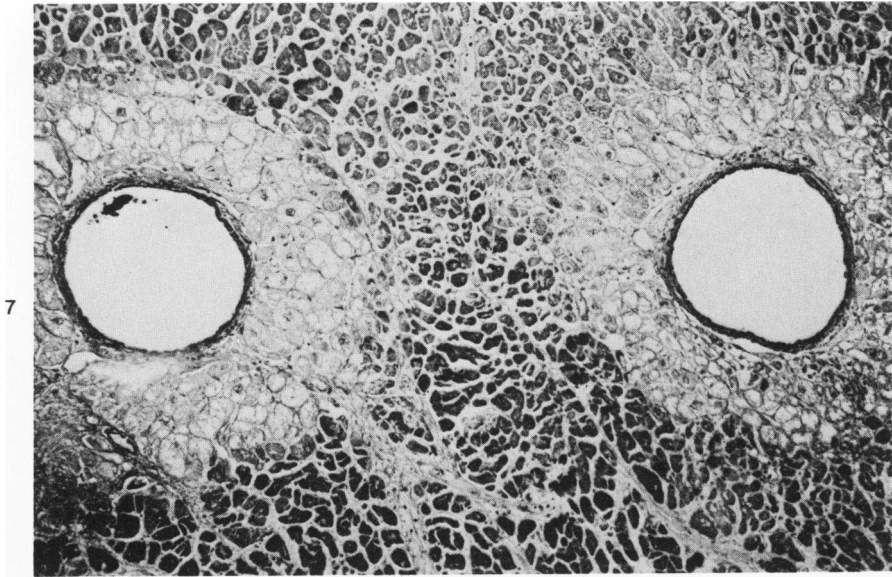


5



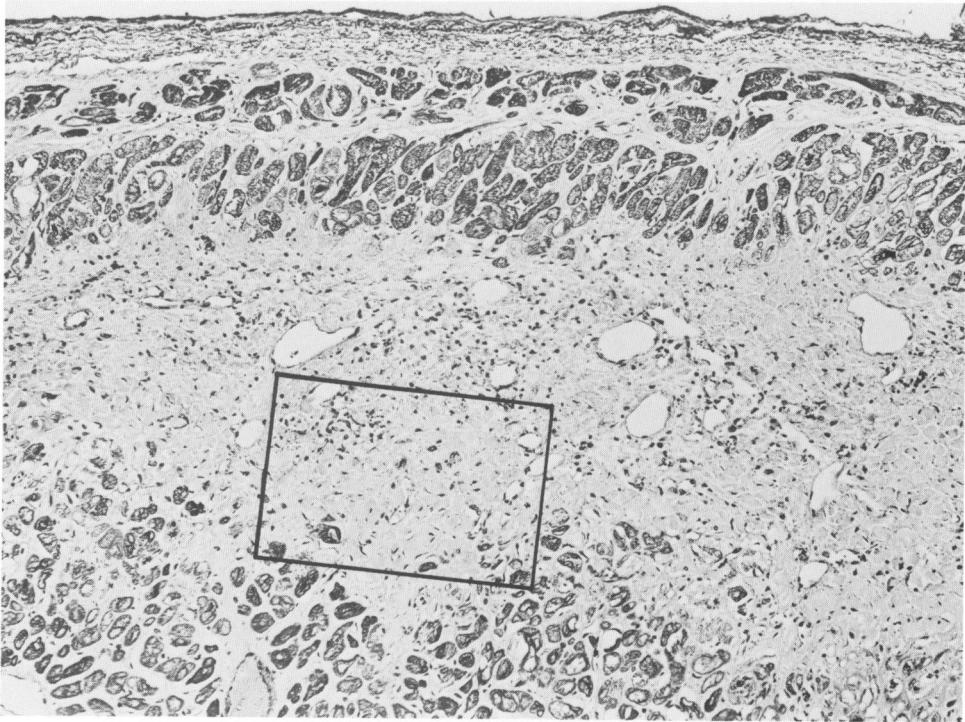
6

**Figure 5**—Case 12. Low magnification of trabeculae carneae of the left ventricle; endocardium is at the *extreme left* of the micrograph. There is extensive coagulation necrosis of myofibers in the central portion of the trabecula, outlined by *arrows*. The necrotic fibers exhibit marked eosinophilia (*dark*) with an apparently widened interstitial space (edema?) and a focus near the center of the necrotic myocardium (*box*) infiltrated with neutrophils. Neutrophilic infiltration is difficult to appreciate at this magnification and is illustrated in Figure 6 at higher magnification. Myofibers near the endocardium and in the region of the artery at the lower right show vacuolar change. Vacuolar change also is evident in fibers at the upper right of the micrograph that are near another myocardial artery outside the micrograph. (H&E,  $\times 55$ ) **Figure 6**—Case 12. Higher magnification of area of neutrophilic infiltration indicated by the box in Figure 5. There are numerous neutrophils between the necrotic myofibers. The interstitial space is widened, apparently due to edema. The myofibers exhibit hyper-eosinophilia (*dark*) and loss of nuclei. (H&E,  $\times 420$ )

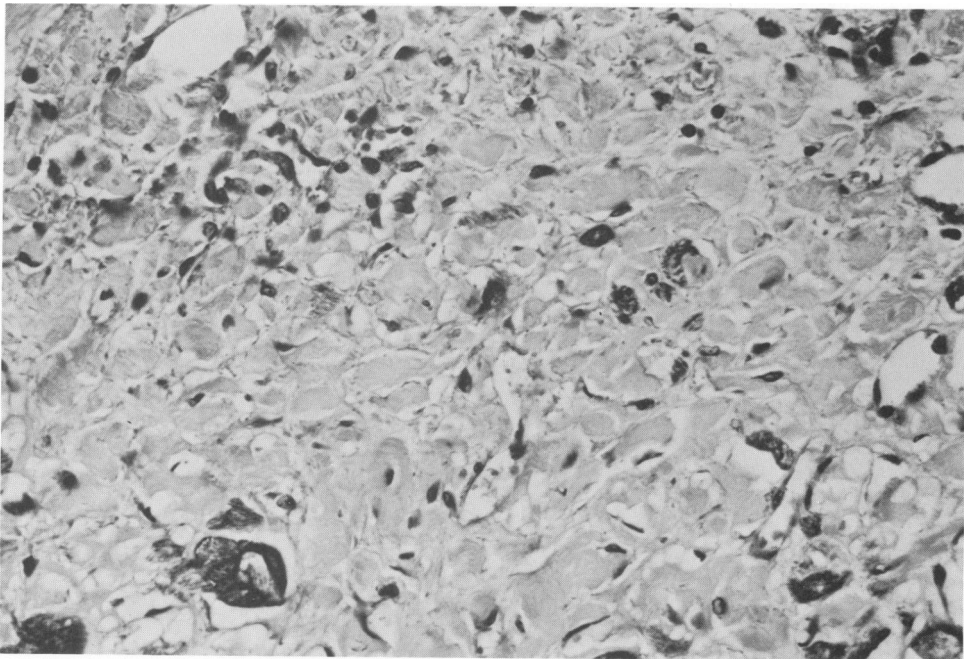


**Figure 7**—Case 12. Subendocardial myocardium. Two small myocardial arteries are surrounded by myofibers with marked vacuolar change in the sarcoplasm. The surrounding myocardium shows coagulation necrosis, with fibers exhibiting loss of nuclei and a slate-blue color in contrast to the normal deep red. There is no neutrophil infiltration. (Aldehyde fuchsin–Gomori trichrome,  $\times 170$ ) **Figure 8**—Case 11. Subendocardial myocardium exhibiting nearly complete removal of necrotic myofibers by mononuclear phagocytes (small dark cells in space between arteries sheathed by viable, dark, myofibers), leaving a reticular-appearing tissue that does not show appreciable loss of volume. Penetrating myocardial arteries are surrounded by well-preserved myofibers that stain dark due to the trichrome stain. Myofibers at the junction of the area with the reticular appearance often are vacuolated. Material in the arteries is barium injectant. (Goldner trichrome,  $\times 170$ )





9



10

**Figure 9**—Case 11. Endocardium is at the top of the micrograph. There is a band-like zone of sub-endocardial myocardial replacement fibrosis in the center of the micrograph. Myofibers near the endocardium and deeper in the myocardium at the bottom of the micrograph show rather extensive vacuolar change. The area in the box is illustrated at higher magnification in Figure 10. (Aldehyde fuchsin-Gomori trichrome,  $\times 170$ ) **Figure 10**—Case 11. Area in the box in Figure 9 is illustrated at high magnification. Collagen fibers appear in large bundles, or fascicles, in what appears to be the space previously occupied by myofilaments. (Aldehyde fuchsin-Gomori trichrome,  $\times 420$ )

*[End of Article]*