

The Connective Tissue Component of the Caprine Arthritis–Encephalitis Syndrome

Timothy B. Crawford, DVM, PhD, D. Scott Adams, DVM, PhD,
R. D. Sande, DVM, PhD, J. R. Gorham, DVM, PhD,
and J. B. Henson, DVM, PhD

The gross and microscopic connective tissue lesions in 12 goats with caprine arthritis–encephalitis (CAE) are described, including those from which a virus (CAEV) was isolated. Lesions were most often associated with synovial-lined structures, including joints, tendon sheaths, and bursae, and were typified by synovial cell proliferation, subsynovial mononuclear cell infiltration, the presence of fibrin, fibrinous concretions, necrosis, and mineralization. Extrasynovial lesions were located in kidneys, vessels, and brain. The inflammatory infiltrates in these organs were predominantly mononuclear. Amyloid was also found in liver, spleen, and kidney. Microbiologic techniques failed to demonstrate any bacteria, mycoplasma, or chlamydia in the lesions. (*Am J Pathol* 1980, 100:443–454)

A PREVIOUSLY UNRECOGNIZED DISEASE syndrome in domestic goats, caprine arthritis–encephalitis (CAE), has been reported. It has important economic implications for the goat industry and potential usefulness as a biomedical model for chronic disease research. CAE is a multi-organ-system disease caused by a recently isolated retrovirus and primarily affects the central nervous system (CNS) and connective tissues.^{1–3} The CNS component, described in previous papers, is seen primarily in young goats as an acute demyelinating encephalomyelitis, with lesions reminiscent of postinfectious encephalitis of man and visna of sheep. Generally speaking, the connective tissue form of CAE presents clinically as chronic arthritis, particularly of peripheral joints. Wasting of arthritic animals is common, and occasionally CNS signs develop as well. The details of the clinical and epizootiologic aspects will be presented in a later publication. The present communication describes the gross and microscopic pathologic features of the chronic connective tissue lesions from which caprine arthritis–encephalitis virus (CAEV) was originally isolated.

Materials and Methods

Animals

The herd of purebred Toggenberg dairy goats used as the source herd for the previous report on the CNS component of CAE² also served as the index herd for the present study.

From the Departments of Veterinary Microbiology and Pathology and Veterinary Clinical Medicine and Surgery, College of Veterinary Medicine, Washington State University, and the Science and Education Administration, US Department of Agriculture, Pullman, Washington.

Supported by the Kroc Foundation, NIH grant AM 18801 and NIH Training Grant GM 07160.

Accepted for publication March 13, 1980.

Address reprint requests to D. Scott Adams, DVM, PhD, Department of Veterinary Microbiology and Pathology, Washington State University, Pullman, WA 99164.

In addition to leukoencephalomyelitis, arthritis was common in the herd, with a high incidence of lameness, "big knees" (enlarged carpi), and wasting among adults. A group of arthritic goats was assembled for experimental purposes at Washington State University (WSU) through acquisitions from the index herd and other herds throughout Washington and Idaho. Breeds represented included Toggenberg, Nubian, Alpine, Saanen, LaMancha, and crossbreeds. In 1978 the experimental group at WSU numbered approximately 60 adults, about half of which had some degree of clinical arthritis.

Pathologic Studies

Pathologic studies were performed on 12 representative goats that died of or were killed *in extremis* from advanced connective tissue disease, its complications, or other, apparently unrelated, causes. Tissues were taken at necropsy, formalin-fixed, paraffin-embedded, sectioned, and stained with hematoxylin and eosin. Selected tissues were fixed in absolute ethanol to stain for urates. Special stains included DeGalantha's stain for urates, von Kossa's stain for calcium salts, crystal violet for amyloid, and periodic acid-Schiff (PAS) for carbohydrate.

Virus Isolation

Virus was first isolated by explantation of synovial membrane¹ from CAE-affected animals and later by inoculating cultures of fetal synovial membrane cells with medium from the primary explants. Briefly, 0.5–1-mm fragments of carpal and tarsal synovial membrane or periventricular brain tissue were cultured in plastic flasks with a small amount of Dulbecco's modified minimum essential medium and 20% fetal calf serum. When cellular outgrowth was accomplished, the tissue fragments were shaken loose and discarded. The primary cultures were passed at 7–10-day intervals and carried for 2–3 months while observed for cytopathic effect. If fetal synovial membrane cultures (explanted in the same manner) were employed, they were passed three to four times after inoculation with medium from explants of CAE-affected goats.

Microbiology

Samples of synovial fluid and tissue were examined for bacteria in blood agar, thioglycollate broth, and beef heart infusion agar. Samples were examined for mycoplasma on a variety of semisolid and fluid media. Attempts were made to isolate chlamydia by inoculating the yolk sacs of 7-day embryonated eggs. Three serial blind passages were made before samples were judged negative.

Results

Morphologic Changes

The severity of pathologic lesions varied considerably from goat to goat, but in general, was proportional to the duration of disease (and therefore to the age of the goat). This, however, was not uniformly true; because of the variable progression rate, some goats affected only 2 or 3 years had more severe lesions than others affected for 6 or 7 years. Rather than a description of individual cases, the following is a compendium of the major lesions found at necropsy in the 12 arthritic goats ranging from 3 to 9 years of age (Table 1).

Table 1—History, Clinical Signs, Lesions, and Viral Isolation in 12 Adult Goats With Advanced Arthritis of CAE

Goat	Sex	Years affected	Clinical signs*		Age at death (years)	Lesions†		Virus isolation‡
			CT	CNS		CT	CNS	
68-1	F	7	+++	—	9	+++	±	ND
68-2	F	6	++	—	8	++	+	ND
73-1	F	6	++	+	8	++	+	ND
74-35	F	4	++	—	7	+++	—	ND
74-39	F	6	+++	—	8	+++	+	ND
74-40	F	6	++	—	7	+++	+	ND
75-5	M	6	++	—	8	++	—	+
75-22	F	2	+++	—	3	+++	—	ND
75-63	M	4	+++	—	6	+++	—	+
75-70	F	3	+	—	6	+	—	ND
76-3	F	5	+++	—	6	+++	±	ND
76-86	M	2	++	+++	3 1/2	++	+++	++

* Clinical signs—CT (Connective tissue): +, soft tissue swelling around peripheral joints with mild lameness; ++, additional swelling, fibrous connective tissue thickening of joint capsules and bursae, rough hair coat, weight loss, radiologically evident arthritis and mineralization of soft tissue; +++, increased severity of the foregoing with joint deformities, very difficult ambulation, and recumbence. CNS (Central nervous system): —, nothing evident; +, mild but unusual dorsal head and eye movements ("star gazing"); +++, quadraparesis, tremors, convulsions, and unconsciousness.

† Lesions—CT: +, mildly thickened joint capsules, increased synovial fluid, hyperplastic synovial membranes infiltrated with mononuclear cells; ++, the foregoing with fibrin deposition on synovial membrane surfaces, "rice bodies," synovial fluid discoloration, mineralization of synovial structures, and considerable thickening of joint capsules; +++ increased severity with joint deformation, often a decrease in synovial fluid, cartilagenous and bony deformation and extraarticular lesions in kidneys, vessels, heart, and skeletal muscles. CNS: —, nothing discernible grossly or microscopically; ±, some vessels in periventricular areas with a few mononuclear cells around them; +, definite perivascular cuffs in periventricular areas; +++, heavy perivascular cuffs, large segments of brain and spinal cord malacia with destruction of myelin and numerous histocytic-microglia cells.

‡ ND, Not done; +, CAE virus isolated from synovial membrane; ++, virus isolated from both synovial membrane and brain.

Gross Pathology

Emaciation, exfoliation of the skin, and rough or abnormally long hair coats were regular features of advanced disease. Disuse and gait abnormalities often resulted in overgrown, distorted hooves. The basic lesions were apparently associated with joints and other synovial-lined structures. Carpal and, to a lesser extent, tarsal, stifle, and fetlock joints were most often grossly enlarged (Figure 1). The subcutis around the carpal joints and joint capsules were markedly thickened. Active inflammation was accompanied by distension of joint capsules, tendon sheaths, and bursae,

with excessive, discolored synovial fluid. Elongated, enlarged, and reddened synovial villi protruded into the joint space. Fibrin tags were common in the synovial fluid and often adhered to the surface of both synovial membrane and articular cartilage. Small, soft, free-floating pieces of fibrin or synovial membrane fragments were common in the synovial fluid. Invasion of cartilaginous surfaces by hyperplastic synovial tissue was occasionally seen. As a rule, however, articular cartilage remained intact until the later degenerative stages, when it developed a ground-glass appearance and erosions often appeared.

Degenerative changes appeared first in the periarticular collagenous tissues and later in joint capsules, tendons, tendon sheaths, bursae, and, in very severe cases, in the kidneys, skeletal muscles, and major arteries. Ill-defined pale areas of degeneration in the tissues progressed to frank necrosis and mineralization of the necrotic debris. Extensive deposits of white, crumbly or semifluid material, which by atomic absorption spectrometry were consistent with calcium salts, were associated with advanced lesions (Figures 2 and 3). Fluid, mineralized material occasionally extended from capsular or periarticular lesions into the joint space. Long-standing cases of severe disease sometimes exhibited axial or lateral deviation of the limb, joint deformation, tendon rupture, or collapse of osseous structures. Severely involved joints that were in prolonged disuse often lost freedom of motion through tendon contracture and fibrous ankylosis.

Large (0.25–1.5 cm) fibrinous concretions frequently filled severely enlarged and distended atlantal and supraspinous bursae (Figure 4) and tendon sheaths. Degenerative changes in the kidney were found in a few advanced cases, and necrotic areas were often visible on the capsular surface. Occasional degeneration of skeletal muscle fibers appeared as yellow or white streaks in the muscle belly. Mineralized, 1–3-cm plaques and nodules of uncertain origin were often present in the mesentery, omentum, and mediastinum. Associated with the terminal event in 2 of the 12 goats was a fibrinopurulent pleuritis and pericarditis with no visible site of entry for an infective agent.

Histopathology

Consistent with the gross lesions, the most striking histologic lesions were associated with synovial-lined structures. Generalized synovitis was characterized by proliferation of synovial lining cells, fibrin deposition on the synovial surfaces, and subsynovial infiltration of mononuclear inflammatory cells. Enlarged synovial villi that were covered by large hyperplastic synovial lining cells and heavy infiltration by inflammatory cells were prominent features of active cases (Figures 5, 6, and 8). Collagenous

tissues in joint capsules, periarticular areas, tendons, tendon sheaths, ligaments, and bursae contained variable-sized foci of "fibrinoid" necrosis (Figure 7) undergoing mineralization (Figure 9). The mineralized material stained positive for calcium salts (dark brown or black) with von Kossa's stain, but showed no evidence of birefringence with polarizing microscopy. Lymphocyte and plasma cell accumulations were prominent around blood vessels and adjacent to areas of necrosis. In very active cases, the lymphoid infiltrates tended toward nodule formation (Figure 6). The temporal relationship between the necrosis and the inflammation was not clear; each occasionally occurred independently in the same section. Multinucleate giant cells with peripheral nuclei were sometimes present among the inflammatory infiltrates around necrotic tissue. Fibrous encapsulation of the necrotic debris was minimal. Active cases of moderate duration were generally characterized by marked inflammation. In long-standing, advanced cases, lesions were more degenerative than inflammatory in character. By DeGalantha's stain, these tissues were negative for urates.

The kidneys of 3 severe cases contained areas of degeneration and necrosis in the cortex and medulla, surrounded by dense accumulations of lymphocytes and plasma cells. Amyloid was deposited in the spleen, hepatic sinusoids, and renal glomeruli of two of the more long-standing cases. Focal necrosis and mineralization of skeletal muscle were present in one goat (68-1), most prominently in the quadriceps and biceps femoris muscles. In many of the major arteries of another goat (74-39), the subintima and inner portions of the media were massively calcified. This lesion was apparently preceded by an inflammatory phase, since the intima and media of a number of medium to large arteries had mononuclear infiltrations and mural necrosis.

Lesions of leukoencephalitis were found in an appreciable proportion (5/12) of goats with advanced connective tissue disease (Table 1). They were generally few in number, located predominantly in periventricular areas, and characterized by perivascular mononuclear infiltrates similar to those in young goats² (Figure 10). Occasional cases of severe, fatal CNS disease in adult goats were accompanied by more destructive and widespread lesions (Table 1, 76-86).

Virology

Caprine arthritis-encephalitis virus was isolated from the three goats in which an attempt was made (Table 1). The cytopathic effect consisted of multinucleate syncytial cell formation, which required several weeks to months to develop in primary explants. When supernatants from these ex-

plants were used to infect fetal synovial cultures, cytopathic effect usually occurred within a few days or after the first pass.

Microbiology

Despite many attempts, neither bacteria nor mycoplasma could be isolated from synovial fluid, synovial membrane, periarticular tissue, mesenteric lymph node, or spleen. Inoculation of synovial fluid and synovial membrane suspensions into eggs for isolation of chlamydia were also unsuccessful.

Discussion

The evidence strongly indicates that this syndrome is a viral disease. No bacteria, mycoplasma, or chlamydia have been isolated in many attempts, and no antibody against common mycoplasmal or chlamydial pathogens has been found.² The virus isolate from Goat 75-63 (Table 1) was inoculated into SPF goat kids, and proliferative synovitis, typical of that described in the present communication, was reproduced within 7 weeks.¹ From early pathogenetic studies it appears the synovitis induced by this virus continues to increase even in the absence of immunofluorescence-detectable viral proteins.⁴ Biochemical analysis of the isolates indicates that the virus is of the retrovirus class related antigenically to visna and progressive pneumonia viruses of sheep. It does not appear to be endogenous, but horizontally transmitted from mother to kid, apparently at an early age.^{1,2,4}

A disease exhibiting connective tissue changes with a pathologic and radiographic appearance similar to that of CAE has been described in goats in Switzerland.⁵ The cause was considered to be genetic, with interaction of undefined environmental factors causing the observed unusual phenotypic penetrance. No CNS disease or attempts at transmission were reported. This disease may have been CAE.

Chronic arthritis with lymphoid and plasma cell infiltration and periarticular calcification was described in Saanen goats in Japan.^{6,7} The syndrome could reportedly be reproduced by injection of several bacteria following preconditioning of the animals with corticosteroids. A cautious interpretation of the etiology in these studies is warranted until more data are available.

A transmissible disease characterized by granulomatous encephalitis, chronic polyarthritis, and ocular lesions has been described to occur in goats.⁸ The etiologic agent was not determined. In contrast, the CNS lesions of CAE have a different distribution, connective tissue changes are more widespread and severe, and ocular involvement is not seen.

Arthritis characterized by chronic, diffuse synovitis with synovial cell proliferation and lymphocyte and plasma cell infiltration is a classic pathologic finding in several rheumatic diseases of humans.^{9,10} This kind of inflammation typifies CAEV-induced synovitis as well, and taken into context with the persistent nature of CAEV, makes consideration of retroviruses as a pathogen in chronic arthritides particularly interesting. It is important, however, to recognize that pathologic responses and pathways with different causes often lead to common morphologic lesions. This appears to be especially true with the type of synovitis mentioned above; several natural¹¹⁻¹³ and experimental^{14,15} animal arthritides with a wide variety of causes characteristically develop a similar synovitis.

Perhaps as important as the synovitis from a comparative standpoint were the other lesions we observed, some of which are commonly seen in rheumatic diseases. One lesion, which is particularly worthy of note because we saw it so often, was soft tissue mineralization, characteristically in and around synovial structures and occasionally in vessels and muscle. Mineralization of soft tissue has been reported in several rheumatic diseases of humans: dermatomyositis,¹⁶ scleroderma,¹⁷ and mixed connective tissue disease.¹⁸ Other findings we observed in CAE that have been reported to occur in rheumatic diseases were arteritis, pericarditis and pleuritis, foreign body giant cells, deposition of amyloid,⁹ and non-suppurative interstitial nephritis.¹⁹ These morphologic similarities may suggest that there are mechanistic or even etiologic similarities as well. It is hoped that further dissection of the mechanisms by which this retrovirus infection causes chronic inflammatory and degenerative disease in goats will benefit our understanding of chronic disease in mankind.

References

1. Crawford TB, Adams DS, Cheevers WP, Cork LC: Chronic arthritis in goats caused by a retrovirus. *Science* 1980, 207:997-999
2. Cork LC, Hadlow WJ, Crawford TB, Gorham JR, Piper RC: Infectious leukoencephalomyelitis of young goats. *J Infect Dis* 1974, 129:134-141
3. Cork LC, Hadlow WJ, Gorham JR, Piper RC, Crawford TB: Pathology of viral leukoencephalomyelitis of goats. *Acta Neuropathol (Berl)* 1974, 29:281-292
4. Adams DS, Crawford TB, Klevjer-Anderson P: A pathogenetic study of the early connective tissue lesions of viral caprine arthritis-encephalitis. *Am J Pathol* 1980, 99:257-278
5. Stunzi VH, Buchi HF, LeRoy HL, Leemann W: Endemische Arthritis chronica bei Ziegen. *Schweiz Arch Tierheilkd* 1964, 106:778-788
6. Motoi Y, Iizuka M, Nakagawa M, Azuma R: Arthritis of goats induced by sensitization with adaptive hormones. *Natl Inst Anim Health Q (Tokyo)* 1972, 12:222-229
7. Nakagawa M, Motoi Y, Iizuka M, Azuma R: Histopathology of enzootic chronic polyarthritis of goats in Japan. *Natl Inst Anim Health Q (Tokyo)* 1971, 11:191-200

8. Stavrou D, Deuschländer N, Dahme E: Granulomatous encephalomyelitis in goats. *J Comp Pathol* 1969, 79:393-396
9. Sokoloff L: Pathology of rheumatoid arthritis and allied disorders, *Arthritis and Allied Conditions*. Edited by DJ McCarty. Philadelphia, Lea & Febiger, 1979, pp 429-448
10. Gardner DL: Pathology of rheumatoid arthritis, *Copeman's Textbook of the Rheumatic Diseases*. Edited by JT Scott. Churchill Livingstone, New York, 1978, pp 273-317
11. Sikes D: A comparison of rheumatoid-like arthritis in swine and rheumatoid arthritis in man. *Ann NY Acad Sci* 1958, 70:717-725
12. Ennis RS, Dalgard D, Willerson JT, Barden JA, Decker JL: *Mycoplasma hyorhinis* swine arthritis: II. Morphologic features. *Arthritis Rheum* 1971, 14:202-211
13. Newton CD, Lipowitz AJ, Halliwell RE, Allen HL, Biery DN, Schumacher HR: Rheumatoid arthritis in dogs. *J Am Vet Med Assoc* 1976, 168:113-121
14. Tanabe S, Ochi T: Experimental chronic polyarthritis in mice. *Biken J* 1978, 21:73-76
15. Goldlust MB, Rich LC, Brown WR: Immune synovitis in rabbits: Effects of differing schedules for intra-articular challenge with antigen. *Am J Pathol* 1978, 91:329-344
16. Ansell BM: Dermatomyositis and polymyositis, *Copeman's Textbook of Rheumatic Diseases*. Edited by J.T. Scott. New York, Churchill Livingstone, 1978, pp 923-936
17. Brandt KD, Krey PR: Chalky joint effusion: The result of massive synovial deposition of calcium apatite in progressive systemic sclerosis. *Arthritis Rheum* 1977, 20:792-796
18. Ramos-Niembro F, Alarcón-Segovia D, Hernández-Ortiz J: Articular manifestations of mixed connective tissue disease. *Arthritis Rheum* 1979, 22:43-51
19. Shearn MA: Sjögren's syndrome. *Med Clin North Am* 1977, 61:271-282

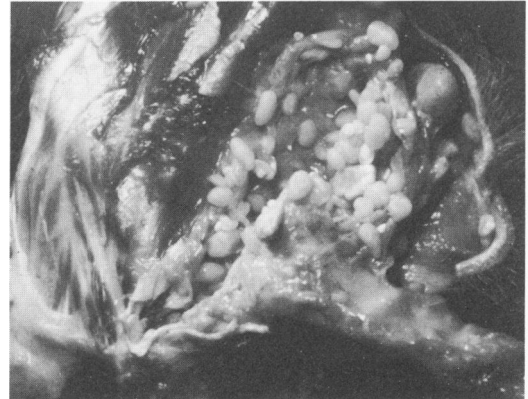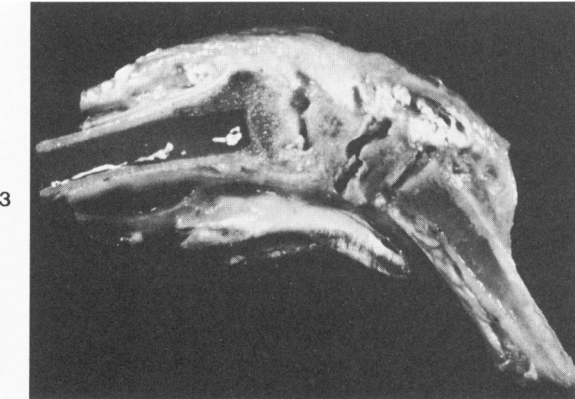
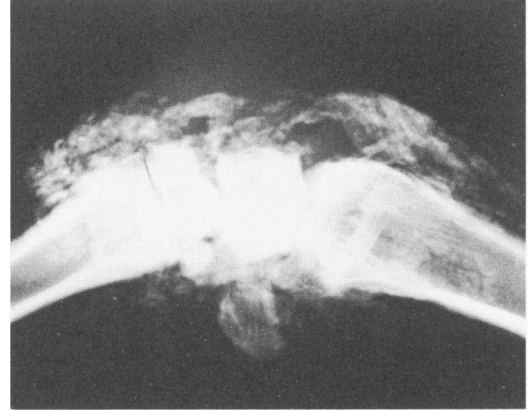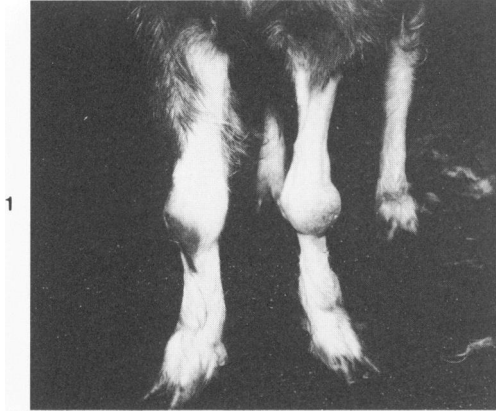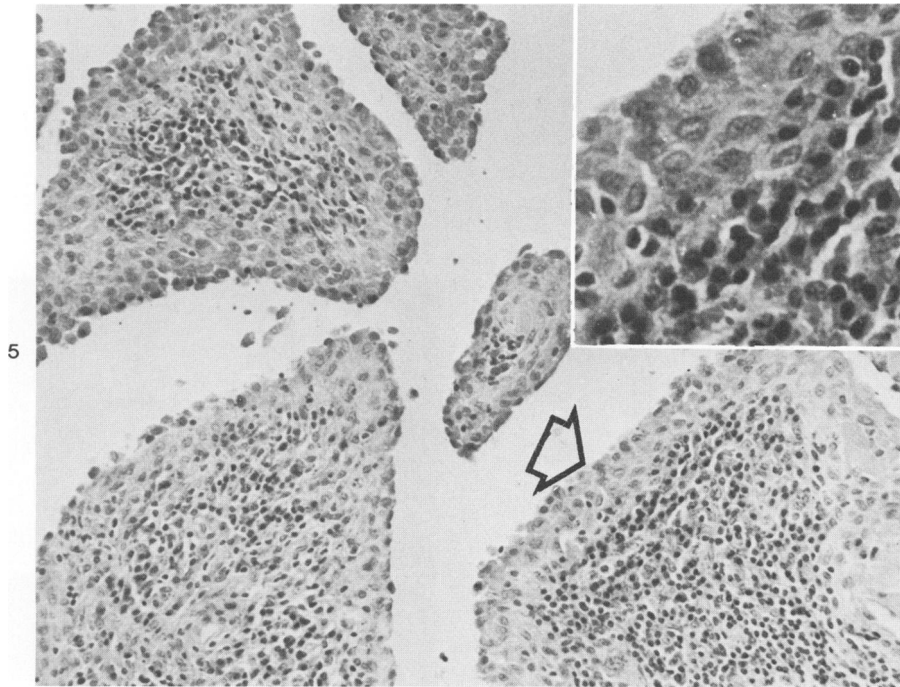
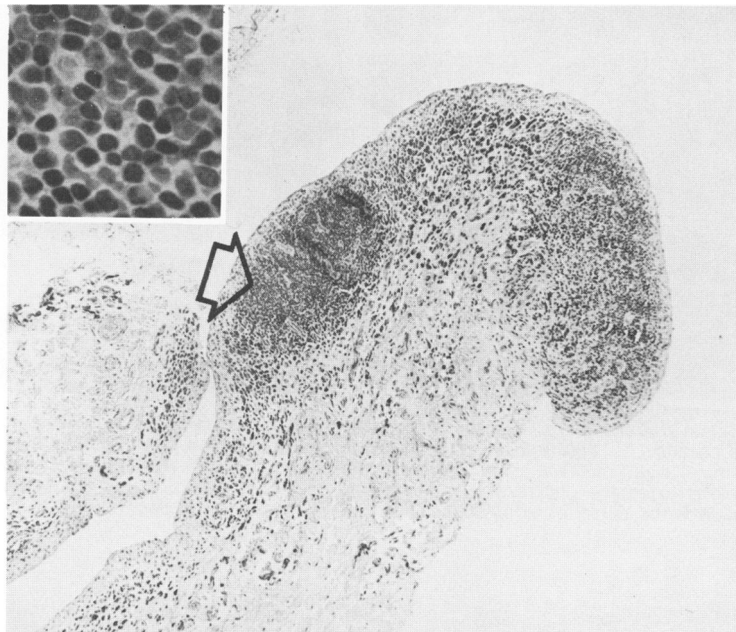


Figure 1—Goat 68-1 at 7 years of age, arthritis of 5-years duration. Carpal joints markedly enlarged and rotated outward below the carpus. **Figure 2**—Radiographic appearance of carpus of Goat 68-1 at 9 years of age. Large deposits of mineralized material in the periarticular area. **Figure 3**—Sagittal section of the carpus of Goat 68-1. There are extensive deposits of white chalky calcified debris in the thickened periarticular tissue. **Figure 4**—Atlantal bursa of Goat 68-1. There are round fibrinous concretions in the grossly enlarged bursa.

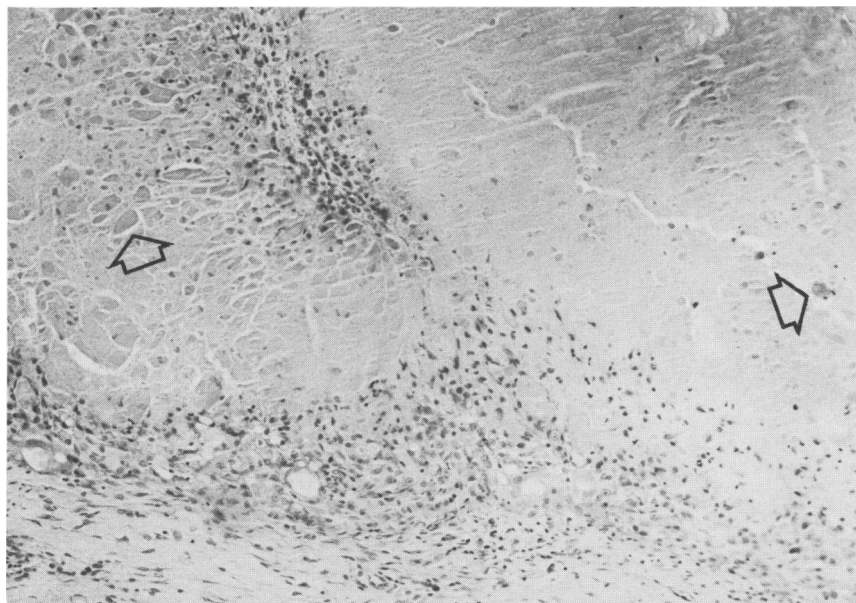


5

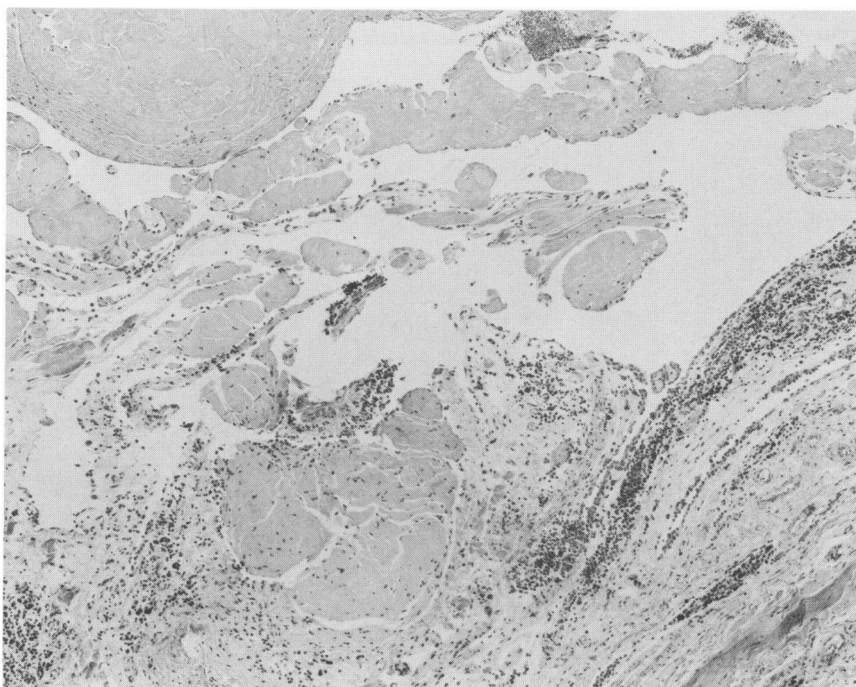


6

Figure 5—Synovial membrane from carpus of Goat 74-40, showing proliferation of synovial lining cells and subsynovial infiltration by lymphocytes, plasma cells, and macrophages. Arrow points to area shown at higher magnification in inset. (H&E, $\times 160$; inset, $\times 460$) **Figure 6**—Synovial villus with a focal lymphocyte accumulation resembling a lymphoid follicle. Arrow points to area shown at higher magnification in inset. (H&E, $\times 50$; inset, $\times 500$)



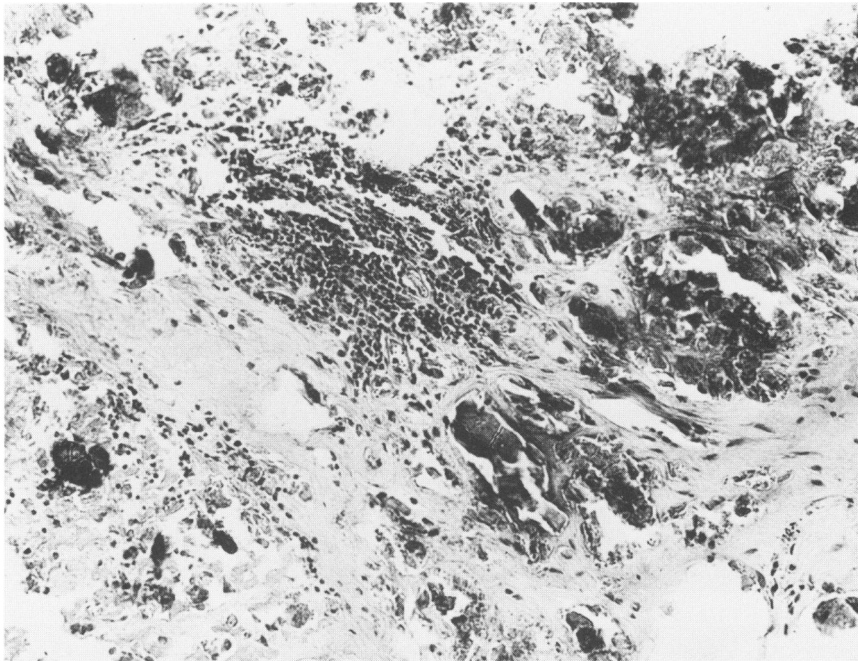
7



8

Figure 7—Subsynovial joint capsule of Goat 76-86 with extensive necrosis surrounded by mononuclear inflammatory cells. Early mineralization is evident (arrows). (H&E, $\times 100$) **Figure 8**—A section of a joint from Goat 74-39 that contained extensive fibrin deposits adherent to the synovial membrane and numerous fibrinous concretions. The masses of fibrin are largely covered by synovial cells. (H&E, $\times 60$)

9



10

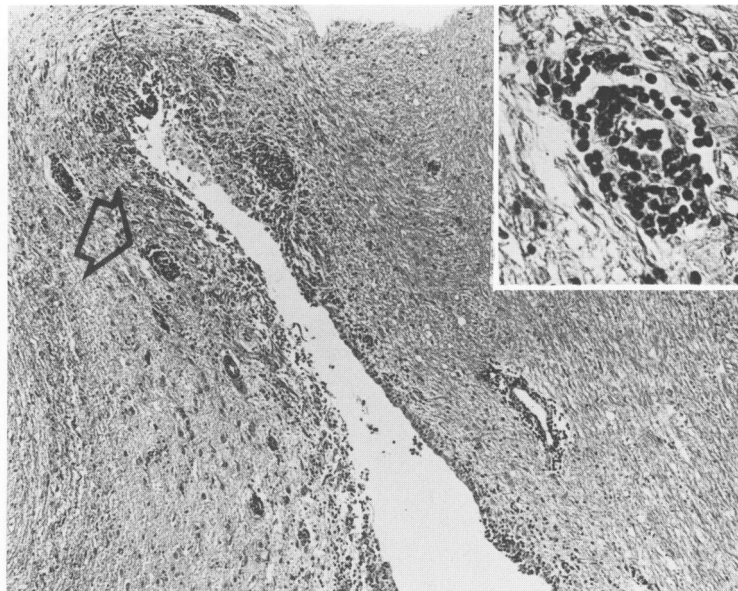


Figure 9—Periarticular connective tissue of a goat with arthritis of CAE. Extensive necrosis, foci of mineralization, and an infiltrate of inflammatory cells. (H&E, $\times 160$)
Figure 10—Histologic lesions of chronic encephalitis in the brain of a goat, 74-40, that had severe connective tissue disease. Perivascular infiltrates (arrow) around vessels near the lateral ventricle. Higher magnification (inset) shows the lymphoid character of the infiltrate. (H&E, $\times 55$; inset, $\times 250$)