

The Pathogenesis of Experimentally Induced *Trypanosoma brucei* Infection in the Dog

I. Tissue and Organ Damage

W. I. MORRISON, PhD, MAX MURRAY, MRCPATH,
P. D. SAYER, BVMS, and J. M. PRESTON, PhD

From the International Laboratory for Research on Animal Diseases
(ILRAD), Nairobi, Kenya

Inoculation of dogs with *Trypanosoma brucei* produced an acute fatal disease similar to that seen following natural infection. The disease was characterised by high levels of parasitaemia, moderately severe anemia, and marked changes in the lymphoid system. Extravascular invasion by large numbers of trypanosomes was widespread throughout the body and was accompanied by severe tissue damage. Tissue invasion by trypanosomes was associated with marked cellular infiltration involving lymphoid cells and plasma cells followed by macrophages and polymorphonuclear leukocytes. Associated with these reactions, severe cellular degeneration and focal necrosis occurred. While these changes were

widespread and were found in the majority of tissues examined, consistently severe lesions were found in the heart, eyes and central nervous system. In many organs, lymphatic vessels were distended with fluid, trypanosomes, and a cell population similar to that in the surrounding tissue; fibrin deposition and thrombus formation was sometimes observed within the lymphatic lumens. Thrombosis was also found in the blood vessels of the pampiniform plexus, the venous plexus of the ovary, and branches of the renal vein. A severe necrotizing vasculitis affecting only the coronary vessels was a prominent feature in some animals. (Am J Pathol 1981, 102:168-181)

INFECTION with the African trypanosomes can result in severe disease in a wide range of domestic animal species.¹ Because of its economic importance, most attention has, so far, been focused on the disease in livestock. However, other species such as the dog may not only suffer from disease but also perhaps constitute a reservoir of infection for other animals and man. It has been shown that dogs are susceptible to infection with a number of the species of African trypanosomes, including the *Trypanosoma brucei* group (*T brucei*, *T rhodesiense*, and *T gambiense*), *T evansi*, and *T congolense*.¹ However, there is little published information on the incidence either of natural infection or disease in dogs in endemic areas of trypanosomiasis. Recent studies in Kenya have shown that severe disease associated with either *T brucei* or *T congolense* infection frequently results following the introduction of fully susceptible dogs into areas infested by the tsetse fly.² As part of an experimental study to define in detail the disease syndromes produced by these trypanosome species, we have examined the sequential pathologic changes in a group of dogs experimentally infected with *T brucei*.

Challenge of dogs with bloodstream forms of *T brucei* resulted in an acute fatal disease characterized by high levels of parasitemia, extravascular invasion by large numbers of trypanosomes in many tissues, moderately severe anemia, and marked reactivity in the lymphoid organs. The present paper describes the tissue lesions that develop in association with extravascular trypanosomes. The nature of the proliferative response in the lymphoid system has been described in a separate paper.³

Material and Methods

Animals

Fifteen cross-bred dogs of mixed sexes, 1.5-3 years of age and weighing 14-24 kg were used for the

This is ILRAD Publication No. 130.

Accepted for publication July 30, 1980.

Address reprint requests to W. I. Morrison, International Laboratory for Research on Animal Diseases (ILRAD), P.O. Box 30709, Nairobi, Kenya.

study. These animals had been reared from birth in the University of Nairobi Small Animal Clinic. They were screened clinically, hematologically, and parasitologically on 4 occasions at weekly intervals immediately prior to the experiment to ensure that they were in good health and free from intercurrent infections.

Experimental Design

Eleven dogs were infected by intravenous inoculation with 10^3 motile organisms of *T. brucei* (stock TREU 667). The remaining 4 dogs were maintained as uninfected controls. All animals were subjected to daily clinical, parasitological and hematologic examination. Two infected dogs were killed for histopathologic examination on Day 8 after inoculation, and a further 3 animals were killed on Day 16; the remaining 6 infected dogs were allowed to progress to the terminal stages of the disease, ie, Days 21–25, at which time histopathologic examination was carried out following euthanasia.

Parasitologic Techniques

Jugular blood samples were examined for the presence of trypanosomes by the darkground buffy coat technique.⁴ The degree of anemia was estimated by packed red cell volume percent (PCV).

Histopathologic Techniques

Prior to postmortem examination, each animal was exsanguinated under general anesthesia induced by sodium pentobarbitone. Representative pieces of tissue from all organs were fixed in neutral-buffered 10% formalin and postfixed in mercuric chloride-formal.

Tissue blocks were embedded in paraffin wax and sections cut at $6\ \mu$ and stained with Mayer's hematoxylin and eosin. Selected sections were also stained with Martius scarlet blue and Gordon and Sweets's reticulin stain.

Results

Parasitologic and Clinical Findings

Trypanosomes were first detected in the blood on Day 5 after inoculation. The parasitemia rose to high levels on Days 6 and 7, followed by a drop to scarcely detectable levels on Days 9 and 10. Thereafter, the levels rose again and remained high until death occurred. Associated with the development of parasitemia, there was a significant drop in PCV, which was

progressive until death, when levels were 50% of pre-infection values (Figure 1). The anemia was normochromic.

The detailed clinical findings in these infected dogs are the subject of a separate communication and herein are only summarized. Clinical signs of illness were first detected on Day 6, at which time all infected dogs were pyrexic. Thereafter, the degree of pyrexia closely paralleled levels of detectable parasitemia; temperatures became as high as 41 C. From the seventh day onwards, the spleen was palpably enlarged. Enlargement of superficial lymph nodes was detected on Day 8, and by Day 14 lymph nodes were 4–5 times the size of controls. Severe ocular changes were found in all animals, starting as a mild ocular discharge on Day 8, followed by limbal corneal opacity and marked hypopyon and hyphema. Gross subcutaneous edema was found in all animals from Day 14 onward. On palpation, evidence of skeletal muscle pain was elicited, and the testicles were found to be swollen and painful. An increase in pulse rate was detected during the second week of infection and during the third week reached values of 160/minute. From Day 20 onward, the pulse became slow and of poor volume; in addition, at this time cardiac arrhythmias and occasional systolic murmurs were detected. Neurologic changes, consisting of unexpected aggression and unexplained barking, together with ataxia and trembling, were observed sporadically from Day 6 onward. Convulsions were occasionally observed during the 3 days prior to death. Pallor of the mucosae, reflecting the development of anemia, was seen from Day 14 onward.

Gross Pathologic Findings

With the exception of enlargement of the spleen and lymph nodes, no obvious abnormalities were found in the dogs examined on Day 8 of infection. However, in animals necropsied after this, marked changes were found in a wide range of tissues, being particularly severe in dogs examined in the terminal stages of the disease. There was subcutaneous edema of varying extent and severity; in some animals this was confined to the face and limbs, while in others extensive edema of the scrotum, prepuce, sternum, and ventral abdomen was also found. The peritoneal, pericardial, and thoracic cavities contained a marked excess of straw-colored fluid, which in the pericardium was commonly blood-stained and contained deposits of fibrin.

The organs that appeared to be most severely affected were the heart and eyes. The heart was very pale, globular in shape due to dilation of the ventri-

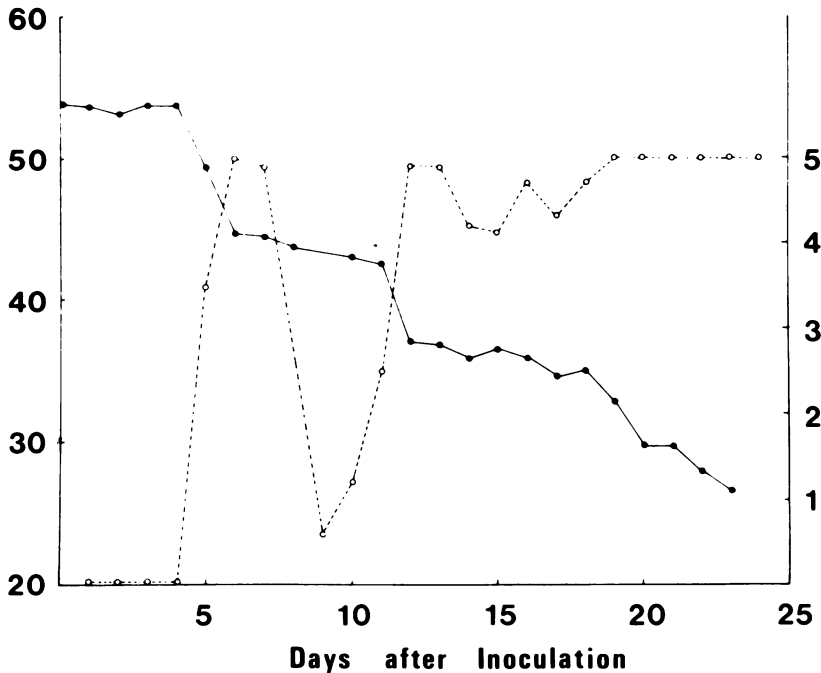


Figure 1—Mean daily parasitemia and packed red cell volume (%) in a group of dogs experimentally infected with *T. brucei*. Measurement of parasitemia utilized a scoring system of 1 to 5 as described in Murray et al⁴; with this method the lower limit of detection is approximately 2.5×10^3 /ml, while a score of 5 represents a parasitemia in excess of 5×10^3 /ml. ●—●, packed cell volume; ○---○, parasitemia.

cles, and there was marked edema of the pericardial fat. In addition, there was extensive petechial and ecchymotic hemorrhage throughout the myocardium of both the atria and ventricles, giving the heart a rather mottled, pale hemorrhagic appearance. The epicardial surface was often granular and sometimes showed adhering tags of fibrin. Severe ocular changes consisting of hypopyon, hyphema, and varying degrees of peripheral corneal opacity were found in both eyes of all dogs examined on Days 21–25. The opaque contents of the anterior chamber often appeared to be coagulated into a large clump, which sometimes totally occluded the pupil.

Edema and petechial hemorrhage were commonly found in a number of other tissues, including skeletal

muscles, where lesions were most readily seen in the diaphragm, kidneys, and testicles, involving particularly the pampiniform plexus. In addition, the liver was swollen, pale, and congested, and irregular pale areas were often observed in the cortices of the kidneys. In terminal cases, small amounts of black, discolored blood were found on the mucosa of the stomach, small intestine, and anterior colon, although no discrete bleeding foci were found.

Histologic Findings

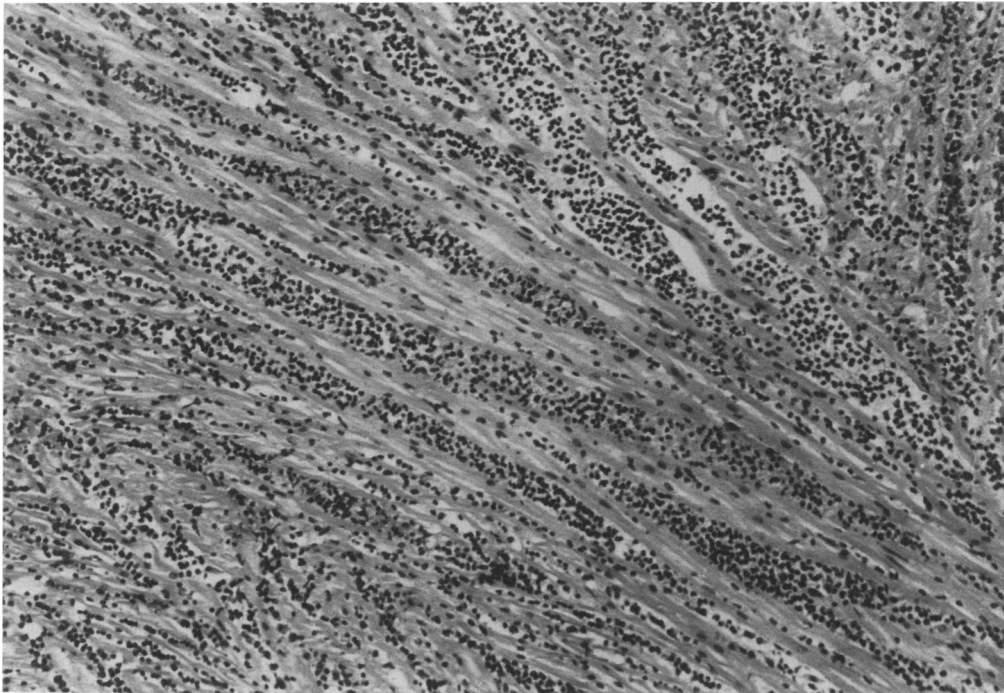
General Features

On Day 8 of infection the only significant finding was the presence of small focal accumulations of lymphocytes and plasma cells in the heart, choroid plexus, and anterior uveal tract of the eye. However, from Day 16 onwards there was a progressive increase in the number of trypanosomes and of the degree of the accompanying cellular infiltrate in a wide range of tissues. In addition, samples of fluid from the peritoneal, thoracic, and pericardial cavities, subcutaneous edema fluid, synovial fluid, cerebrospinal fluid, and aqueous humor examined from dogs necropsied on Days 21–25 were all found to contain numerous trypanosomes. Invasion of tissue by the trypanosomes was associated with a varying degree of cellular infiltration and tissue cell degeneration and death.

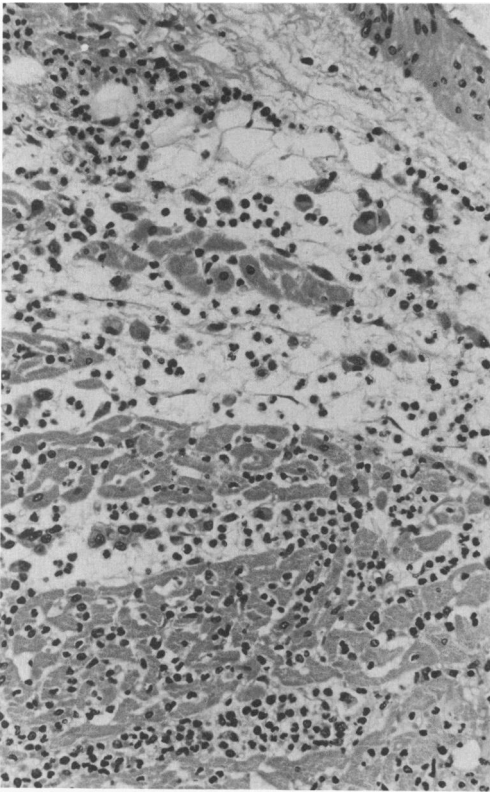
In the early stages of development of the lesions

Table 1—Distribution and Severity of Lesions Found in Dogs Infected With *Trypanosoma brucei*

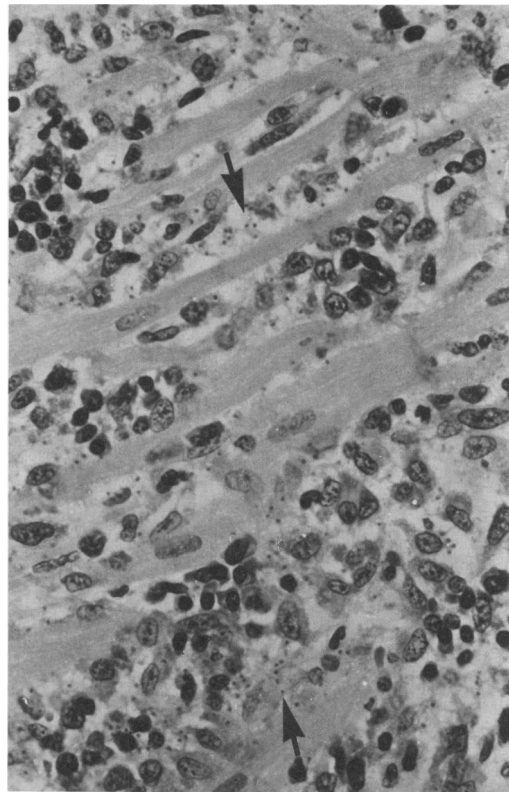
	Presence of trypanosomes extra-vascularly	Cellular infiltration	Cellular degeneration and necrosis
Heart	++++	++++	+++
Eyes	++++	++++	++
Choroid plexus	++++	++++	+
Brain and meninges	+	++	—
Pituitary gland	++++	+++	++
Genital tract	+++	+++	++
Kidney and bladder	+++	+++	++
Skin and subcutis	++	++	+
Skeletal muscle	++	++	+
Nasal mucosa	+++	+++	++
Gastrointestinal tract	++	++	+
Liver	+	++	+



2



3



4

Figure 2—Ventricle of dog examined on Day 24 of infection. There is diffuse cellular infiltration, resulting in separation and distortion of the myocardial fibers. (H&E, $\times 80$) **Figure 3**—Atrium of a dog examined on Day 23 of infection. There is marked interstitial edema and swelling and degeneration of the myocardial fibers, accompanied by a cellular infiltrate containing numerous polymorphonuclear leukocytes and macrophages. (H&E, $\times 290$) **Figure 4**—Ventricle of a dog examined on Day 24 of infection. Numerous plasma cells, macrophages, and trypanosomal nuclei (arrow) can be seen between the myocardial fibers. (H&E, $\times 350$)

the cellular infiltrate was composed mainly of lymphocytes and plasma cells with only a few macrophages; however, as lesions became more severe and were associated with cell death, increased numbers of macrophages and polymorphonuclear leukocytes were found. In different sites within the same tissue any one of these cell types predominated. In most tissues the blood vessel walls were swollen, and there was expansion of the perivascular spaces; however, vasculitis associated with necrosis of the vessel walls was found only in the heart. In many organs the lymphatics were distended and contained trypanosomes and a cell population similar to that found in the surrounding tissues. In some of these lymphatics the cells were enmeshed in a network of fibrin that appeared to occlude the lumen. Thrombus formation was occasionally observed in the blood vessels of the pampiniform plexus, in the venous plexus of the ovary, and in branches of the renal vein.

In the terminal stages of the disease, lesions were found in virtually every tissue examined, although some organs were more severely affected than others (Table 1). In view of this widespread involvement, it is impossible in the present paper to catalogue in detail all of the histologic changes found. Therefore, the present description focuses on the changes found in the heart, eyes, and central nervous system, includ-

ing the pituitary gland, in which severe lesions were consistently observed.

The Heart

By Day 16 of infection, trypanosomes were observed extravascularly in the myocardium, and in association there was a focal cellular infiltrate involving mainly lymphocytes and plasma cells with occasional foci of macrophages and polymorphonuclear leukocytes. These changes affected the atria to a greater extent than the ventricles and were most marked in subepicardial and perivascular locations.

A severe myocarditis was found in all dogs examined in the terminal stages of the disease and involved the entire myocardium, including the atrioventricular valves. There was focal hemorrhage, edema, and separation of the myocardial muscle fibers. Large numbers of trypanosomes were scattered diffusely throughout the myocardium, and numerous foci of myocardial cell degeneration and necrosis were found. These changes were associated with a marked cellular infiltrate composed of lymphocytes, plasma cells, and many macrophages and polymorphonuclear leukocytes (Figures 2-4). Myocardial necrosis was particularly severe beneath the epicardium, and in most cases there were areas of epicarditis characterized by

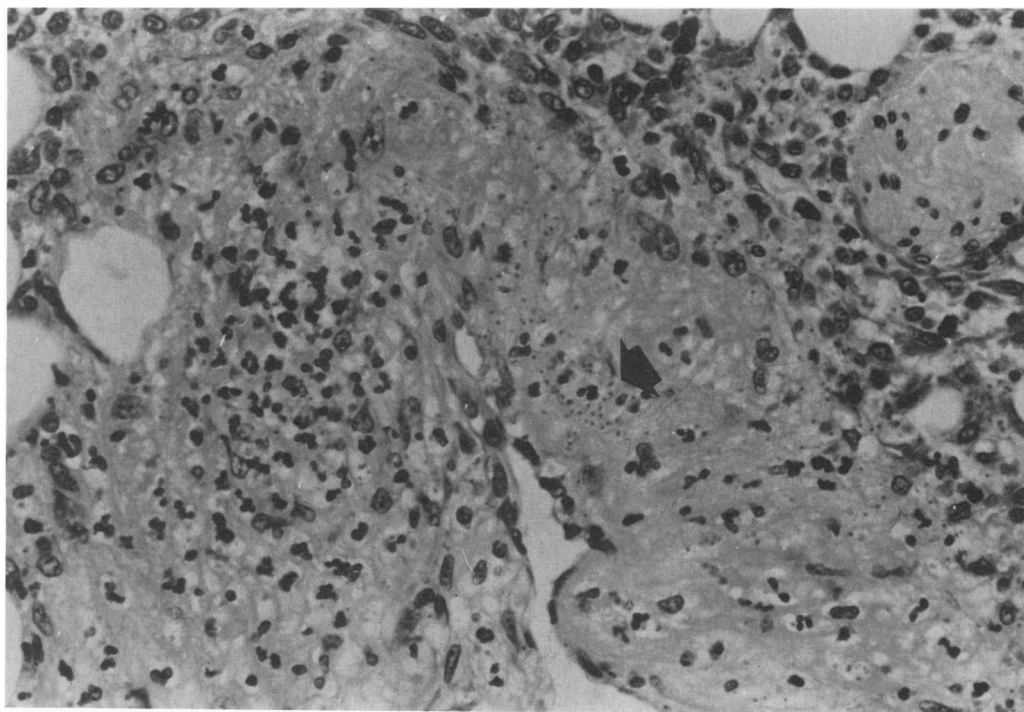
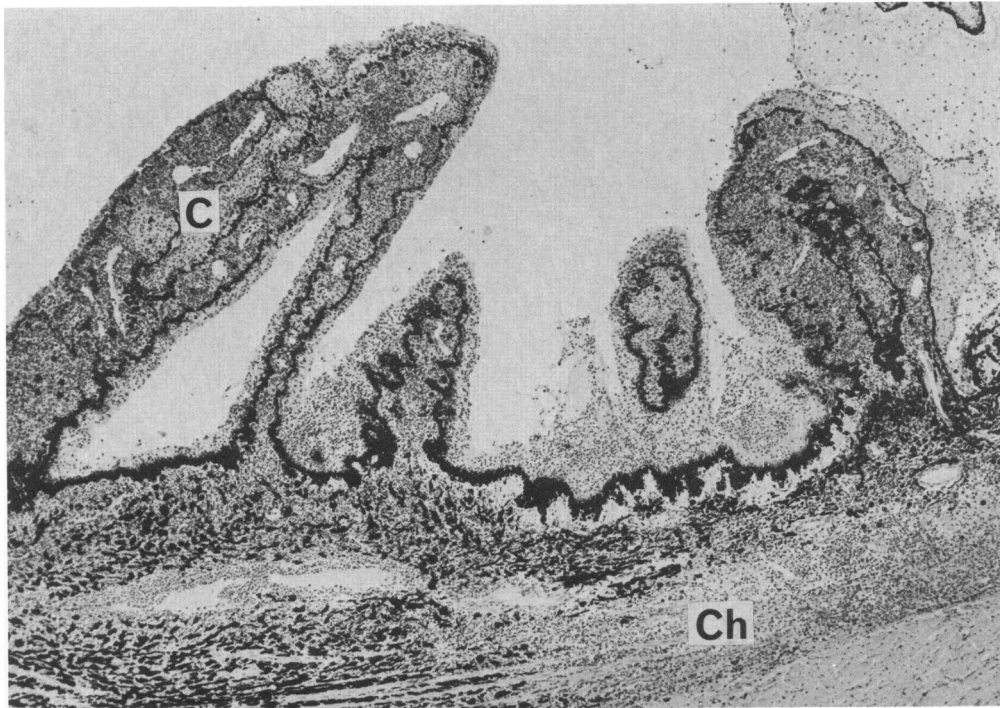
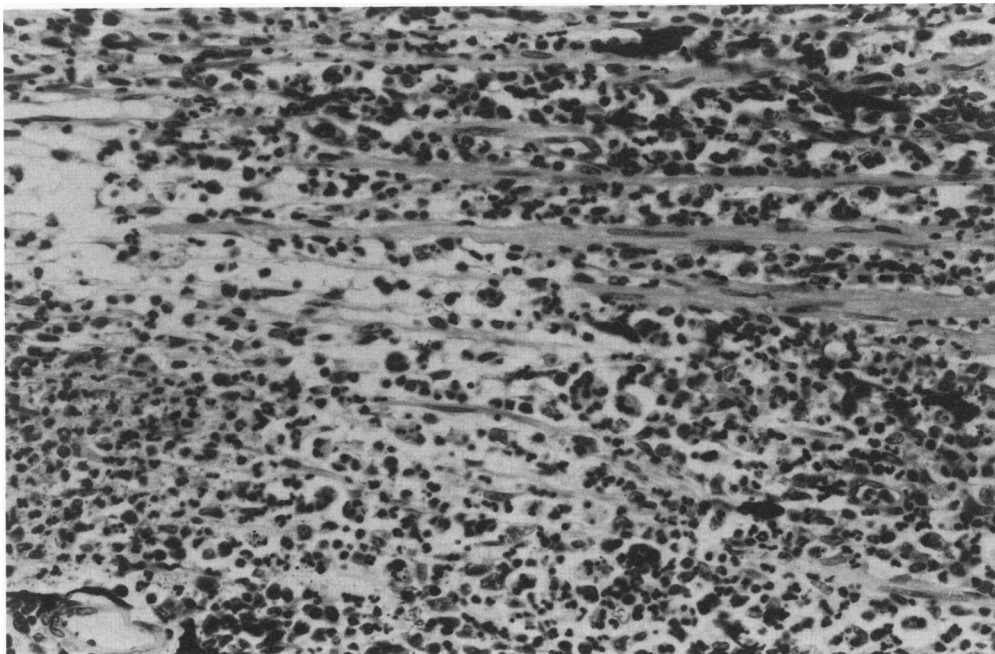


Figure 5—Coronary artery of a dog examined on Day 25 of infection. There is diffuse necrosis of the vessel wall, with infiltration of polymorphonuclear leukocytes. Clusters of trypanosomes (arrow) can also be seen. (H&E, $\times 310$)



6



7

Figure 6—Eye of a dog examined on Day 21 of infection. There is diffuse cellular infiltration into the choroid (*ch*) and ciliary body (*c*), resulting in marked swelling of the latter. There is also cellular infiltration into the posterior chamber. (H&E, $\times 40$) **Figure 7**—Eye of a dog examined on Day 21 of infection, showing part of the choroid layer. There is interstitial edema and a copious cellular infiltrate containing numerous polymorphonuclear leukocytes. (H&E, $\times 250$)

exudation of fibrin and polymorphonuclear leukocytes on the surface of the heart. Distended lymphatics were commonly encountered beneath the epicardium; these contained numerous macrophages, polymorphonuclear leukocytes, necrotic cell debris, and trypanosomes, all of which sometimes appeared to be

trapped within a thrombus in the lumen of the lymphatic. An additional finding in 3 animals was a severe necrotizing vasculitis affecting arteries and veins lying beneath the epicardium. In these vessels, there was diffuse necrosis of the muscular layer, which was invaded by large numbers of trypanosomes accompa-

nied by a cell infiltrate composed almost entirely of polymorphonuclear leukocytes (Figure 5).

The Eyes

In animals examined on Day 16 of infection, trypanosomes were found extravascularly in the iris, ciliary body, and adjacent choroid of the eye. This was associated with a cellular infiltrate containing numerous lymphocytes and plasma cells and in some areas macrophages and polymorphonuclear leukocytes. There was also a fibrinous exudate into the anterior chamber of the eye; this contained erythrocytes, trypanosomes, and a mixed cellular infiltrate similar to that found in the iris.

In the terminal stages of the disease, there was an intense uveitis affecting the entire uveal tract with edema, hemorrhage, large numbers of trypanosomes, and a mixed cellular infiltrate containing many macrophages and polymorphonuclear leukocytes (Figures 6–8). This resulted in marked swelling of the ciliary body processes and the iris and, in the most severely affected cases, foci of necrosis within the ciliary body and adjacent choroid. In addition,

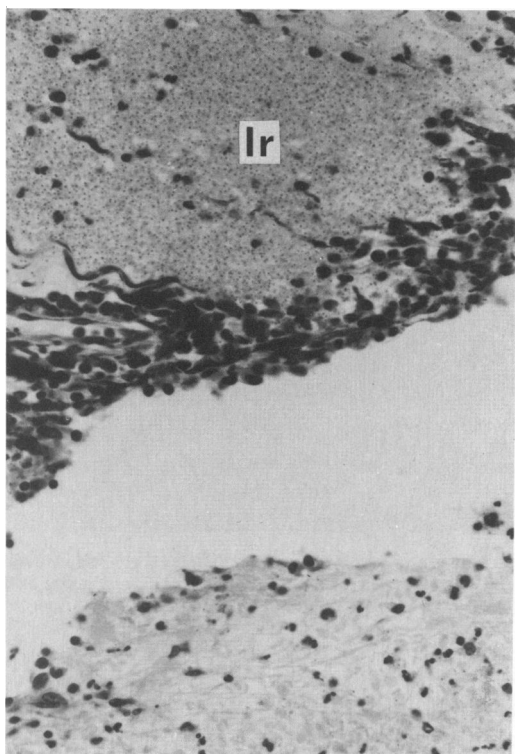


Figure 8—Eye of a dog examined on Day 22 of infection, showing part of the iris and anterior chamber. The iris (*Ir*) is distended with large numbers of trypanosomes; and there is a fibrinous exudate containing a mixture of nucleated cells, erythrocytes, and trypanosomes in the anterior chamber. (H&E, $\times 300$)

the fibrinous exudation into the eye was much more severe than on Day 16 and involved both the anterior and posterior chambers (Figure 8). The exudate, which was composed of a mixture of fibrin, erythrocytes, trypanosomes, and a mixed cell infiltrate, containing predominantly polymorphonuclear leukocytes, was observed as large fibrinous clumps, which were sometimes adherent to the ciliary body processes or lens in the posterior chamber or the anterior surface of the iris in the anterior chamber.

From Day 16 onwards in all animals, small numbers of trypanosomes and a mixed cellular infiltrate containing numerous macrophages were found beneath the conjunctival membrane at the level of the cornea-scleral junction. In addition, foci of lymphocytes, plasma cells, and polymorphonuclear leukocytes, with occasional trypanosomes, were present in the peripheral cornea and were associated with vascularization at these sites. In 2 dogs the cellular infiltration was diffuse throughout the cornea. Similar cellular foci were also found around blood vessels in the sclera.

Outside the eyeball, the surrounding connective tissue contained trypanosomes and a mixed cellular infiltrate; in addition, there was often a severe myositis of the ocular muscles.

The Central Nervous System

Although lesions were scattered throughout the central nervous system, the choroid plexus and pituitary gland were particularly severely affected. At Day 16, trypanosomes, accompanied by foci of lymphocytes and plasma cells and occasional polymorphonuclear leukocytes, were found in the choroid plexus. In all of the animals examined on Days 21–25 the choroid plexus was markedly swollen due to edema and the presence of massive numbers of trypanosomes and a mixed cellular infiltrate (Figures 9 and 10). In some areas, the plasma cell was the common cell type, whereas, at other sites either polymorphonuclear leukocytes or macrophages predominated. Occasional foci of hemorrhage and necrosis were present in areas where the polymorphonuclear cell infiltrate was particularly intense. Elsewhere in the brain, varying numbers of lymphocytes and plasma cells were found in the lumen of blood vessels both in the meninges and within the neuropil. In the latter site, small foci of lymphocytes and plasma cells were located perivascularly. The same cell types were found in greater numbers around the vessels in the meninges. Foci of macrophages and polymorphonuclear leukocytes were also present extravascularly in the meninges, and in some animals trypanosomes

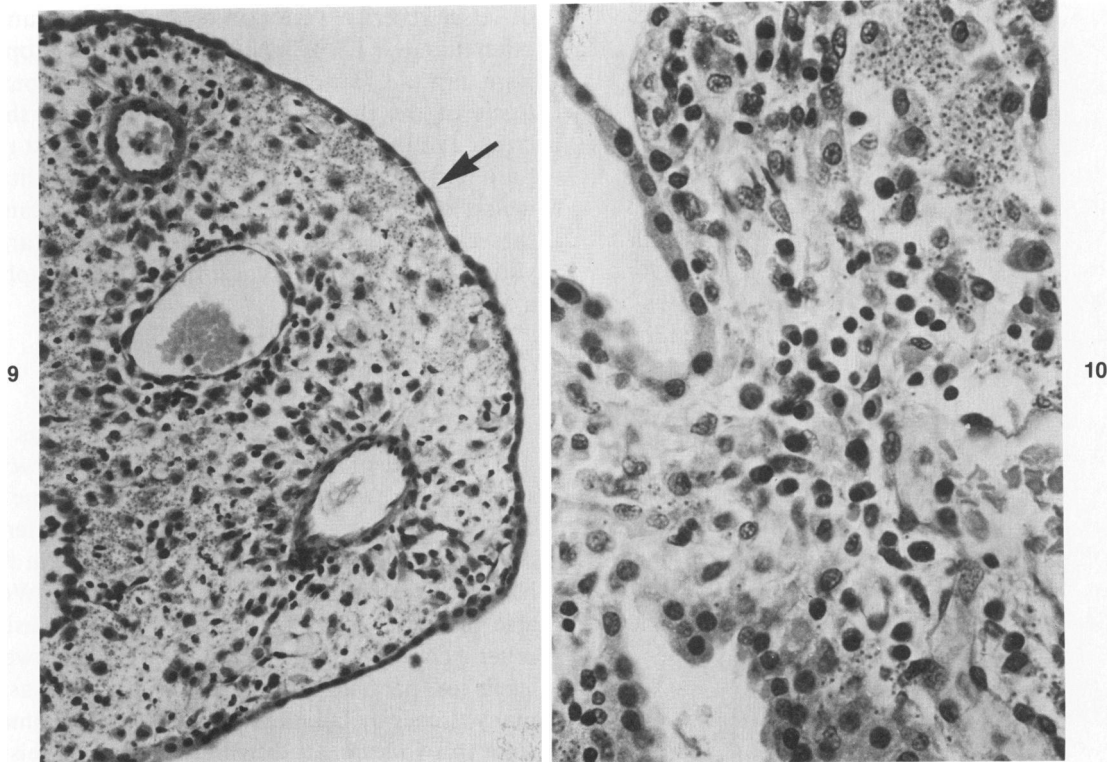


Figure 9—Choroid plexus of a dog examined on Day 24 of infection. The interstitium is markedly distended with edema, trypanosomes, and a cellular infiltrate containing numerous macrophages. This has resulted in flattening of the ependymal lining (*arrow*) and separation of the latter from the plexus vessels. (H&E, $\times 180$) **Figure 10**—Choroid plexus of a dog examined on Day 23 of infection. Numerous plasma cells, macrophages, and trypanosomes are present in the interstitium of the plexus. (H&E, $\times 350$)

were found. Occasional discrete foci of perivascular hemorrhage were found within the brain tissue.

There were severe lesions in the pituitary gland of all dogs examined from Day 16 onward (Figures 11–13). Both the anterior and posterior pituitary were invaded by large numbers of trypanosomes. This was associated with a cellular infiltrate of lymphocytes and plasma cells in both parts of the pituitary gland; these cells were concentrated mainly around blood vessels but were also found more diffusely elsewhere. In all cases, varying numbers of polymorphonuclear leukocytes and macrophages were also present, the former cell type being particularly abundant in some animals. In some cases, there was hemorrhage into the anterior pituitary and focal necrosis involving the anterior and/or posterior part of the gland (Figure 13). The intense perivascular cell infiltrate along with edema appeared to result in swelling of the pituitary and cause separation of the endocrine cells and nerve fibers from blood vessels in the anterior and posterior pituitary, respectively. In one animal, the cleft (or remnant of Rathke's pouch) between the anterior and posterior pituitary was distended with edema fluid containing a mixed-cell infiltrate composed pre-

dominantly of polymorphonuclear leukocytes and macrophages and a few trypanosomes.

Other Tissues

The urogenital tract was consistently involved. There was marked trypanosomal and cellular infiltration into the bladder wall and renal interstitium (Figure 15), the latter being associated with focal tubular necrosis; no obvious changes were found in the glomeruli. In male dogs, there was an orchitis (Figure 14) in which the connective tissue around the vessels of the pampiniform plexus was usually most severely infiltrated. There was also involvement of the ovaries and uterine wall in female dogs.

In terminal cases, the gastrointestinal tract was severely affected. Trypanosomes were found in the lamina propria both of the stomach and the intestines, although they were particularly numerous just beneath the superficial gastric epithelium (Figure 16). Their presence was associated with an increase in content of lymphocytes and plasma cells in the lamina propria, which in the small intestine sometimes resulted in thickening of the villi; necrosis of the tips

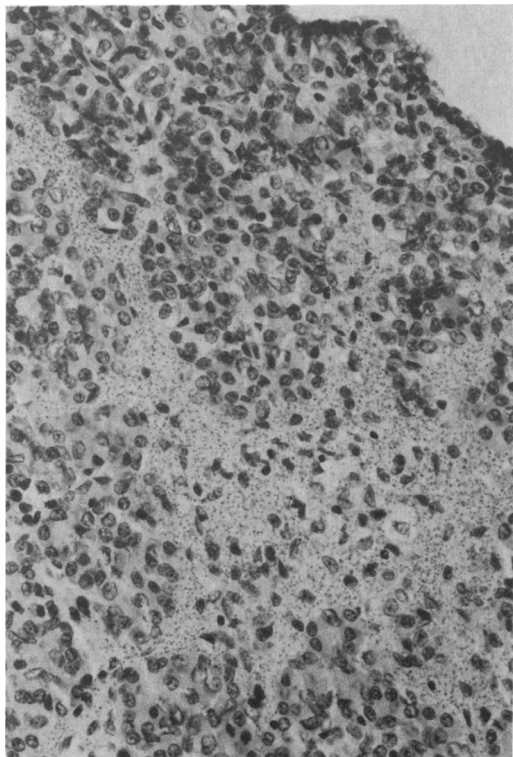


Figure 11—Anterior pituitary gland of a dog examined on Day 25 of infection. Large numbers of trypanosomes are present within the endocrine tissue. (H&E, $\times 160$)

of the intestinal villi was seen occasionally (Figure 17). There was also trypanosomal invasion and cellular infiltration into the submucosal connective tissue (Figure 18); this was always more pronounced in the stomach than in the intestine and in the former often involved the muscular layers.

In all dogs examined in the terminal stages of the disease there was pronounced venous congestion of the liver. The hepatic sinusoids were markedly distended so that the cords of hepatocytes took on an accentuated linear arrangement. Foci of lymphocytes and plasma cells were found around the portal vessels and scattered through the hepatic sinusoids; variable numbers of polymorphonuclear leukocytes and trypanosomes were also present in the sinusoids. There was a marked increase in the number of Kupffer cells in the sinusoids; these cells had abundant cytoplasm, which was often vacuolated and sometimes contained phagocytosed erythrocytes. In some dogs, foci of fatty degeneration were found in close proximity to the hepatic veins; in these areas there was swelling and disorganization of the hepatocytes with occasional cell death and mitosis of hepatocytes.

In addition to those tissues listed in Table 1, lesions

of lesser severity were also observed in a number of other tissues. These included the lungs, esophagus, joint capsule, bone marrow, interlobular connective tissue of the thymus, interacinar septa of the pancreas, and the adrenal glands. It is of interest that the only endocrine organ, apart from the pituitary, in which lesions were found was the adrenal gland, and these were much less severe than in the pituitary, consisting only of small focal infiltrates of lymphocytes and plasma cells.

Discussion

In the present study, inoculation of dogs with a small number of bloodstream forms of *T brucei* consistently resulted in an acute disease syndrome invariably leading to death in the fourth week after infection. A similar time course for the disease in the dog has been reported by other workers.^{5,6} We have also produced a similar disease syndrome using another isolate of *T brucei*.⁷ Infected dogs showed high levels of parasitemia and widespread invasion of many tissues by large numbers of trypanosomes. Despite this widespread distribution, the organisms appeared to have some predilection for certain tissues. The reasons for this are unclear, although the organisms were commonly observed in large numbers in connective tissue within highly vascularized areas such as choroid plexus, pampiniform plexus, nasal mucosa, and the anterior uveal tract of the eye. The presence of extravascular trypanosomes was accompanied by marked cellular infiltration and edema, resulting in swelling and disruption of tissues and varying degrees of cell death and degeneration. The severity of these changes was in general related to the number of organisms found within the tissues. Some of the tissues involved, in particular the heart, central nervous system, skeletal muscle, and pituitary gland, have also been shown to be severely damaged in other species infected with *T brucei* (rat⁸; rabbit⁹; man¹⁰; cattle^{12,13}; sheep^{14,15}; horse¹⁶; donkey¹⁷).

Most of the clinical observations made during the course of the disease may be directly attributed to the extravascular invasion by the trypanosomes and resultant tissue lesions. Such lesions in the skin gave rise to severe edema; in the skeletal muscles and in the testicles there was obvious pain on palpation. In the eyes there was partial or complete blindness due to hypopyon and hyphema. Similarly, the various nervous signs might easily be attributable to the lesions observed in the choroid plexus and meninges. During the last few days prior to death, there was clinical evidence of congestive heart failure; at nec-

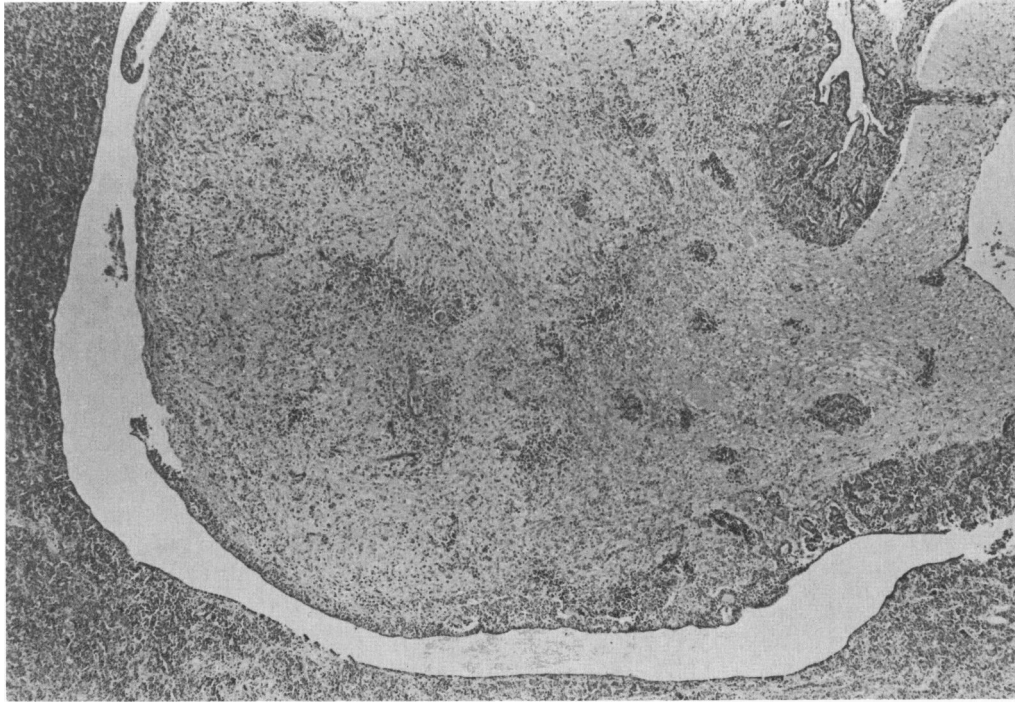


Figure 12—Posterior pituitary gland of a dog examined on Day 24 of infection. There is a diffuse perivascular cell infiltrate (H&E, $\times 50$)

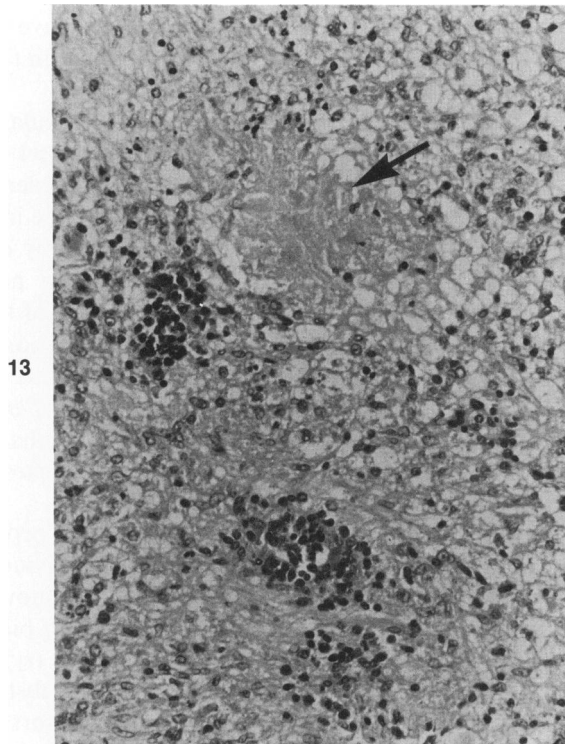


Figure 13—Posterior pituitary gland of a dog examined on Day 24 of infection, showing an area of necrosis (*arrow*). (H&E, $\times 200$)

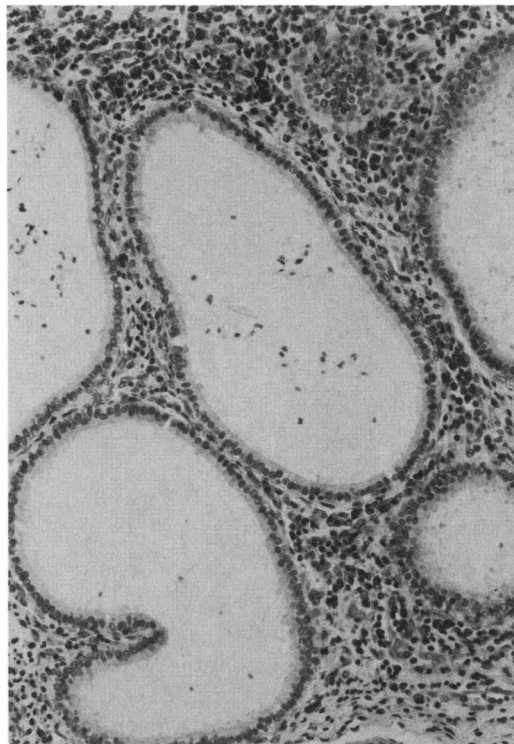


Figure 14—Epididymus of a dog examined on Day 22 of infection showing an interstitial cellular infiltrate consisting mainly of lymphocytes and plasma cells. (H&E, $\times 150$).

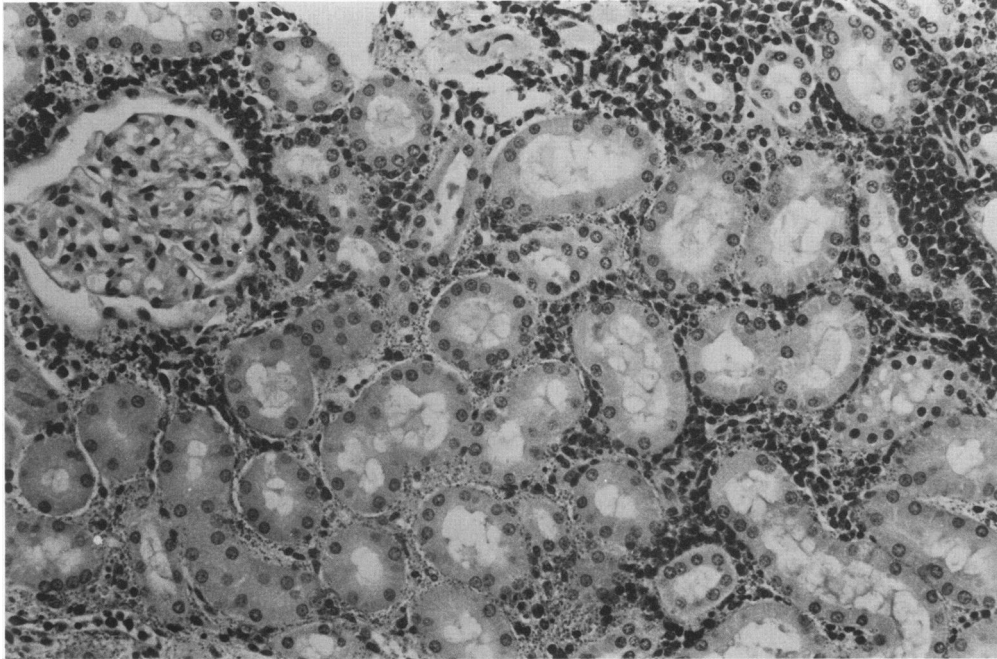


Figure 15—Kidney of a dog examined on Day 23 of infection. Numerous trypanosomes accompanied by a cellular infiltrate of lymphocytes and plasma cells are present in the renal interstitium. A normal glomerulus can be seen. (H&E, $\times 150$)

ropsy the findings of a heart which was globular in shape due to dilation of the ventricles along with marked venous congestion of the liver were also indicative of congestive heart failure. Although there was no clinical evidence of endocrine dysfunction, the severe lesions found in both the anterior and posterior pituitary are likely to have given rise to hormonal abnormalities. Similarly, the changes found in the testicles and ovaries almost certainly had a deleterious effect on gametogenesis. Such changes, however, are likely to be of greater clinical significance in more longstanding infections. Severe pituitary lesions have been described in sheep experimentally infected with *T brucei*,¹⁸ while in human sleeping sickness various reproductive disorders and myxomatous changes have been attributed to endocrine dysfunction.¹⁹

A number of mechanisms are likely to be involved in the generation of the tissue lesions in animals infected with *T brucei*. Firstly, the degree of interstitial edema and cellular infiltration in many tissues caused marked physical disruption, which must have affected the normal physiologic functioning of the tissues involved. For example, swelling of the choroid plexus resulting in separation of the vessels of the plexus from the ependymal lining must have affected its specialized secretory function. Similarly, in the eye, severe lesions in the choroid, iris, and ciliary body almost certainly affected the fluid balance with-

in the eye, and indeed some animals suffered from a transient glaucoma. In the heart, separation of myocardial fibers from Purkinje fibers may have interfered with the conducting system, resulting in the arrhythmias recorded.

There was evidence of an increase in vascular permeability as judged by swelling of blood vessel walls, expansion of the perivascular spaces, and edema of the tissues. These changes were probably due in part to a local inflammatory response initiated by extravascular trypanosomes. Increased vascular permeability may also be related to elevated levels of kinins or other vasoactive amines in the circulation; increased levels of kinins have been reported to occur in laboratory animals and cattle infected with *T brucei*, and there is evidence to suggest that this results from an interaction of circulating immune complexes with the Hageman factor.²⁰

The role of the trypanosome *per se* or its products in initiating vascular permeability and tissue cell damage must also be considered. There are now several reports which describe the generation of biologically active substances by dead or dying trypanosomes (reviewed in Tizard et al²¹). These substances include permeability and inflammatory factors demonstrated in *T gambiense*²² and in *T congolense*.²³ In addition, it has been shown that purified variant surface antigen can activate complement and induce increased vascular permeability,²⁴ while activation of

complement has also been demonstrated with extracts of *T congolense*.²⁵ There is evidence that various trypanosomal factors may contribute directly to cell damage and death. Several groups of workers have demonstrated that the main pathogenic African trypanosomes generate hemolysin(s)²⁶⁻²⁸ and that these factors are also cytotoxic for nucleated cells.²⁹ However, the relevance of these substances *in vivo* remains to be determined. Studies in neonatal and sublethally irradiated mice have shown that when these animals are infected with *T brucei* large numbers of organisms are present in the tissues, but there is only a scanty cellular infiltrate and virtually no tissue cell degeneration or death.³⁰ These findings suggest that live trypanosomes by themselves are not responsible for severe tissue injury. However, it is possible that large numbers of dead or dying organisms may release substances capable of initiating tissue damage.

In view of the presence of numerous lymphocytes and plasma cells along with large numbers of trypanosomes in the tissues, it is likely that hypersensitivity reactions involving trypanosomal antigens contribute to the tissue damage. Evidence to support this contention has come from recent work carried out in mice infected with *T brucei*.³⁰ Galvao-Castro et al³⁰ showed that myocardial lesions, similar to those found in the dogs in the present study, were associ-

ated with deposition of immunoglobulin and trypanosomal antigen between the muscle fibers, as detected by immunofluorescence. On the basis of a comparison of these lesions in immunologically competent and incompetent mice and on transfer of cells or serum, these authors proposed that the mechanisms of tissue damage probably involved the local formation of trypanosomal antigen-antibody complexes within the tissues. The antibodies involved may enter the tissues from the circulation or be produced locally by plasma cells which are present in the cellular infiltrates.

Numerous macrophages and polymorphonuclear leukocytes were found in the tissues of infected dogs. Accumulation of macrophages within such a cellular reaction possibly results from release of lymphokines from lymphocytes within the reaction. With regard to the polymorphonuclear leukocytes, it is known that products of activation of complement by immune complexes may attract large numbers of these cells into sites of inflammation. In this respect, it is of note that there was a severe necrotizing vasculitis of the coronary vessels in which polymorphonuclear leukocytes were the predominant cell type. The similarity of these lesions to an Arthus reaction and the observation of trypanosomes within the vessel walls suggest that the lesion may have arisen due to local formation of immune complexes within the vessel

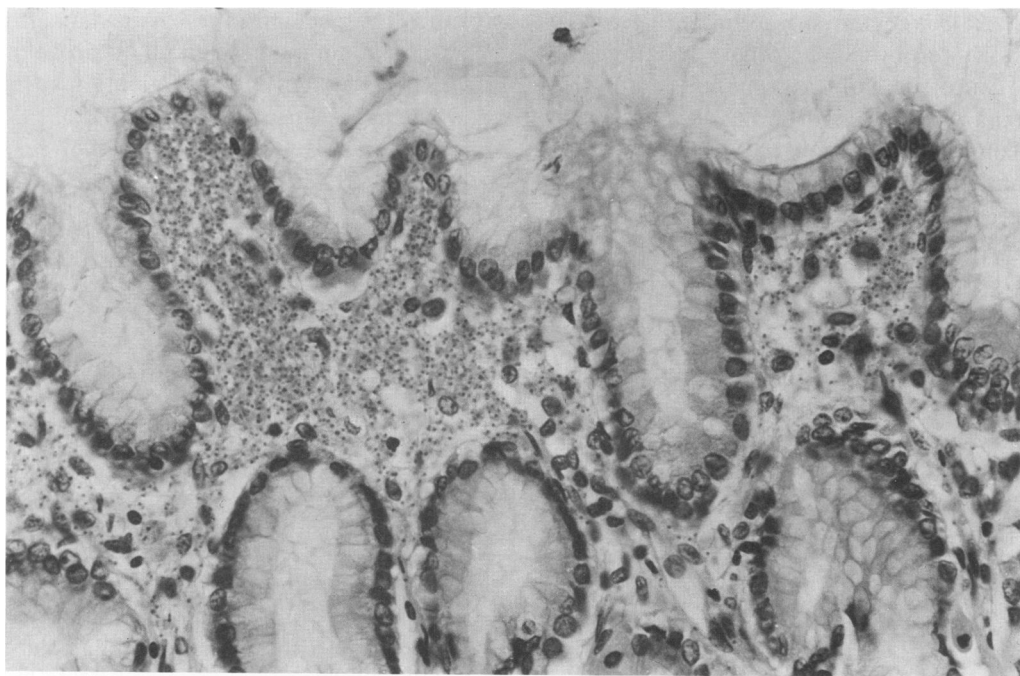

Figure 16—Pyloric region of stomach of a dog examined on Day 25 of infection. Numerous trypanosomes are present in the lamina propria immediately beneath the superficial gastric epithelium. (H&E, $\times 250$)

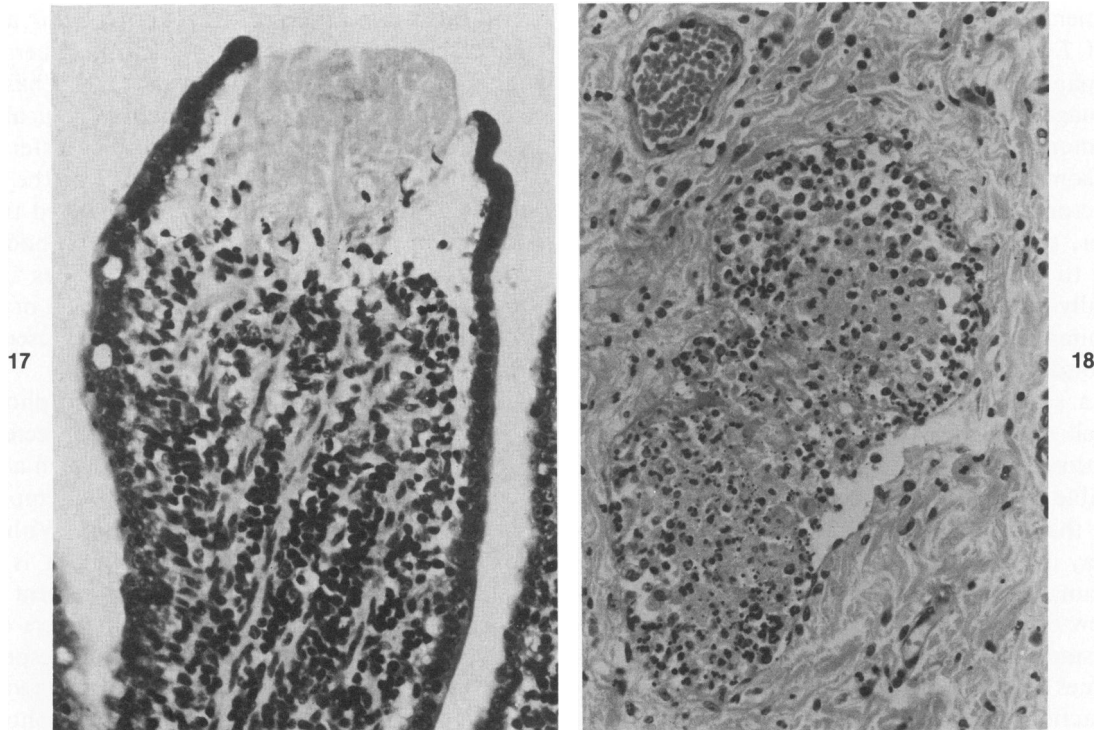


Figure 17—Small intestine of dog examined on Day 23 of infection, showing necrosis of the tip of a villus. There is also an increase in the content of lymphocytes in the lamina propria. (H&E, $\times 280$) **Figure 18**—Stomach of dog examined on Day 21 of infection, showing a lymphatic in the submucosa. The lumen of the lymphatic is distended and contains a mixture of fibrin and both viable and dying cells. (H&E, $\times 200$)

walls. Both macrophages and polymorphonuclear leukocytes are capable of phagocytosing immune complexes. Release of lysosomal enzymes from polymorphonuclear leukocytes can occur during phagocytosis or in response to other inflammatory stimuli.³¹⁻³³ Since much of the tissue cell damage was found in areas where polymorphonuclear leukocytes were abundant, it is likely that the release of cytolytic enzymes contributed to the development of the lesions. Numerous macrophages and polymorphonuclear leukocytes were also present within afferent lymphatics and in the sinuses of the lymph nodes; furthermore, by immunofluorescence, immunoglobulin, presumably in the form of immune complexes, was detected within the cytoplasm of macrophages in the lymph nodes.³ In addition, there was extensive deposition of fibrin within the efferent lymphatics and the subcapsular sinuses of the nodes. These findings again point to the possibility that there is triggering of a series of reactions involving immune complexes, polymorphonuclear leukocytes, complement, Hageman factor, and the coagulation system.

In our experience, the tissue lesions in dogs are the most severe that we have observed during infection with *T. brucei* in any of the species of domestic or laboratory animals, with tissues such as the heart, the

central nervous system, including the pituitary gland, eyes, and reproductive organs being consistently affected. Thus, the dog offers an excellent opportunity to study the mechanisms of tissue damage induced by *Trypanozoon* parasites and might prove to be a valuable model system in the evaluation of current and new chemotherapeutic compounds.

References

1. Losos GJ, Ikede BO: Review of the pathology of diseases in domestic and laboratory animals caused by *Trypanosoma congolense*, *T. vivax*, *T. brucei*, *T. rhodesiense* and *T. gambiense*. *Vet Pathol* 1972 9(Suppl): 1-71
2. Sayer PD: Manuscript in preparation
3. Morrison WI, Murray, Sayer PD, Preston JM: The pathogenesis of experimentally induced *Trypanosoma brucei* infection in the dog: II. Changes in the lymphoid organs. *Am J Pathol* 1981, 102:182-194
4. Murray M, Murray PK, McIntyre WIM: An improved parasitological technique for the diagnosis of African trypanosomiasis. *Trans R Soc Trop Med Hyg* 1977, 71: 325-326
5. Mönckeberg JG, Simons HCR: Zur pathologischen Anatomie der experimentellen Nagana bei Hunden. *Z Hyg Infektr* 1918, 87:77-118
6. Mwambu PM: The symptomatology of experimental *Trypanosoma brucei* species infection in dogs as observed at E.A.T.R.O. Proceedings of the International Scientific Council for Trypanosomiasis Research and

- Control, 15th Meeting. The Gambia, 1977, pp 427-440
7. Sayer PD: Unpublished observations
 8. Murray M, Murray PK, Jennings FW, Fisher EW, Urquhart GM: The pathology of *Trypanosoma brucei* infection in the rat. *Res Vet Sci* 1974, 16:77-84
 9. Van den Ingh TS, van Dijk JE: Pathology of chronic *Trypanosoma brucei* infection in the rabbit. *Zentralbl Veterinaermed [B]* 1975, 22:729-736
 10. Mott FW: Histological observations on the changes in the nervous system in trypanosome infections especially sleeping sickness and their relation to syphilitic lesions of the nervous system. *Arch Neurol* 1907, 3:581-646
 11. Koten JW, de Raadt P: Myocarditis in *Trypanosoma rhodesiense* infections. *Trans Soc Trop Med Hyg* 1969, 63:485-489
 12. Ikede BO, Losos GJ: Pathological changes in cattle infected with *Trypanosoma brucei*. *Vet Pathol* 1972, 9:272-277
 13. Moulton JE, Sollod AE: Clinical serologic and pathologic changes in calves with experimentally induced *Trypanosoma brucei* infection. *Am J Vet Res* 1976, 37:791-802
 14. Ikede BO, Losos GJ: Pathology of the disease in sheep produced experimentally by *Trypanosoma brucei*. *Vet Pathol* 1972, 9:278-289
 15. Ikede BO: Ocular lesions in sheep infected with *Trypanosoma brucei*. *J Comp Path* 1974, 84:203-213
 16. McCully RM, Neitz WO: Clinopathological study on experimental *Trypanosoma brucei* infections in horses: Part 2. Histopathological findings in the nervous system and other organs of treated and untreated horses reacting to nagana. *Onderstepoort J Vet Res* 1971, 38:141-176
 17. Ikede BO, Akpokodje JU, Hill DH, Ajidagba PO: Clinical haematological and pathological studies in donkeys experimentally infected with *Trypanosoma brucei*. *Trop Anim Health Prod* 1977, 9:93-98
 18. Ikede BO, Losos GJ: Pathogenesis of *Trypanosoma brucei* infection in sheep: III. Hypophysial and other endocrine lesions. *J Comp Path* 1975, 85:37-44
 19. Apted FIC: Clinical manifestations and diagnosis of sleeping sickness, The African Trypanosomiasis. Edited by HW Mulligan. London, Allen and Unwin, 1970, pp 661-683
 20. Boreham PFL, Wright IG: The release of pharmacologically active substances in parasitic infections. *Prog Med Chem* 1976, 13:159-204
 21. Tizard I, Nielsen KH, Seed JR, Hall JE: Biologically active products from African trypanosomes. *Microbiol Rev* 1978, 42:661-681
 22. Seed JR: *Trypanosoma gambiense* and *T. lewisi*: Increased vascular permeability and skin lesions in rabbits. *Exp Parasitol* 1969, 26:214-223
 23. Tizard IR, Holmes WL: The release of soluble vasoactive material from *Trypanosoma congolense* in intraperitoneal diffusion chambers. *Trans R Soc Trop Med Hyg* 1977, 71:52-55
 24. Musoke AJ, Barbet AF: Activation of complement by variant-specific surface antigen of *Trypanosoma brucei*. *Nature* 1977, 270:438-440
 25. Nielsen K, Sheppard J: Activation of complement by trypanosomes. *Experientia* 1977, 33:769-770
 26. Huan CN, Webb L, Lambert PH, Miescher PA: Pathogenesis of the anaemia in African trypanosomiasis: Characterization and purification of a hemolytic factor. *Schweiz Med Wochenschr* 1975, 105:1582-1583
 27. Tizard IR, Holmes WL, York DA, Mellors A: The generation and identification of the hemolysin of *Trypanosoma congolense*. *Experientia* 1977, 33:901-902
 28. Murray M, Huan CN, Lambert PH, Gerber H: The anaemia of African trypanosomiasis: Demonstration of a hemolytic factor. *Proceedings of the International Scientific Council for Trypanosomiasis Research and Control. The Gambia, 1977*, pp 460-469
 29. Tizard IR, Holmes WL: The generation of toxic activity from *Trypanosoma congolense*. *Experientia* 1976, 32:1533-1534
 30. Galvao-Castro B, Hochmann A, Lambert PH: The role of the host immune response in the development of tissue lesions associated with African Trypanosomiasis in mice. *Clin Exp Immunol* 1978, 33:12-24
 31. Henson PM: Interaction of cells with immune complexes: Adherence, release of constituents, and tissue injury. *J Exp Med* 1971, 134:114-135s
 32. Weissmann G, Zurier RB, Speiler PJ, Goldstein IM: Mechanisms of lysosomal enzyme release from leukocytes exposed to immune complexes and other particles. *J Exp Med* 1971, 134:149s-165s
 33. Becker EL: Some interrelations of neutrophil chemotaxis, lysosomal enzyme secretion, and phagocytosis as revealed by synthetic peptides. *Am J Pathol* 1976, 85:385-394

Acknowledgments

We wish to thank Professor G. M. O. Maloiy, Dean of the Faculty of Veterinary Medicine, University of Nairobi, and Dr. I. E. Muriithi, Director of Veterinary Services, Kenya, for providing facilities which enabled the work to be carried out. Thanks are also due to Mr. D. L. Bovell and Mr. J. Kamau for expert technical assistance.