

Isoantigens A, B and H in Benign and Malignant Lesions of Breast

Raj K. Gupta, MD, FCAP and Rudy Schuster, BSc, RT

Eighty-five specimens of breast tissue were grouped and investigated by the technic of mixed cell agglutination reaction (MCAR) for studying isoantigens A, B and H (O). MCAR was found to be strongly positive at the epithelium of acini in all the 25 subjects with benign lesions (10 fibroadenomas, 10 cystic mastitis and 5 gynecomastias). On the other hand, all the subjects with diagnosis of primary carcinomas in breast (45 subjects) and their metastases (15 subjects) were found to be uniformly negative for any agglutination reaction. In view of these findings, it seemed that the isoantigens in primary and metastatic malignancies of breast are always lost, while in the benign lesions isoantigens are always present. Although the exact mechanism is not understood, it seems that, in malignancies with a glandular differentiation, some differences exist when these are compared to malignancies with a squamous differentiation. The various possibilities are discussed in the light of previous studies (*Am J Pathol* 72:253-260, 1973).

IN A RECENT INVESTIGATION,¹ we used the mixed cell agglutination reaction (MCAR) to study isoantigens A, B and H (O) in normal and diseased prostates. Previous studies of Davidsohn and others showed the usefulness of the MCAR in studying carcinoma of oral cavity pharynx, larynx, esophagus, lung, stomach, pancreas, cervix and urinary bladder.²⁻⁹ According to Davidsohn, the technic of MCAR or specific red cell adherence is capable of detecting isoantigens A, B and H in a variety of formalin-fixed tissues even after many years have elapsed.² Previous studies of prostate tissue in this laboratory support this view. We felt that a further investigation using the MCAR procedure might be of use in a comparative evaluation of changes in common benign and malignant lesions of the human breast. Specifically, our aim was to observe whether the presence or loss of isoantigens in breast tissues in any way differed when compared with the results of studies in other tissues.¹⁻⁹

From the Departments of Pathology, The St. Catharines General Hospital, St. Catharines, Ontario, Canada and School of Medicine, The State University of New York at Buffalo, Buffalo, NY.

Accepted for publication Apr 10, 1973.

Address reprint requests to Dr. Raj K. Gupta, Department of Pathology, St. Catharines General Hospital, St. Catharines, Ontario, Canada.

Material and Methods

Breast tissues were obtained from surgical specimens from a total of 85 subjects. An histologic diagnosis of primary carcinoma was made in 45 subjects. Ten subjects were diagnosed as having metastatic carcinoma in regional lymph nodes and 5 subjects as having distant metastases in bones, liver and distant lymph nodes. Twenty-five subjects had benign lesions of the breast: 10 with a histologic diagnosis of fibroadenoma, 10 with cystic mastitis and 5 with gynecomastia.

Five-micron sections from all breasts were cut from formalin-fixed and embedded material and mounted on clean glass slides. Human antisera, anti-A and anti-B, with an average agglutination titer of 512 were used. This represented satisfactory levels for use in the MCAR procedure.^{1,10}

An *Ulex europaeus* extract with an agglutination titer of about 2000 was used as a source of O agglutinin. Details of the method of preparation for this extract have been previously described by us and Davidsohn.^{1,10}

The indicator system included erythrocytes of group A1, B, A1B and O. These were washed three times in Tris (hydroxymethyl)-buffered isotonic saline at pH 7.4, and a 1% suspension was made in the same buffered saline. The MCAR was performed in all breast tissues by standard procedures, the details of which have been published previously.^{10,1} The breast tissue on slides in the petri dishes was examined, after incubation with the appropriate indicator cells, under the low power (10 ×) of a Leitz microscope through the thickness of the slide with the tissue section remaining on the lower surface. Pertinent photomicrographs were taken with a Leitz microscope equipped with a Leicaflex camera using a Panatomic X Kodak black and white film.

The following served as positive controls: a) erythrocytes in the lumina of blood vessels and endothelial cells lining blood vessels.¹⁻⁴ and b) squamous epithelium of cervix, normally known to contain isoantigens A, B and H.³

Results

MCAR in Benign Lesions of Breast

In this series, a total of 25 subjects were studied. The MCAR was found to be strongly positive at the hyperplastic epithelial lining of the tortuous, elongate and rounded acini in all the 10 subjects with fibroadenomas. (Figures 1 and 2). Five subjects with gynecomastia showed a similar but somewhat less pronounced agglutination reaction at the lining epithelium of acini; the reaction was interpreted as patchy in 50% of the glands and strong in the remaining acini. All cases of chronic cystic mastitis gave a strong to occasional patchy agglutination of RBCs around the epithelial lining in relation to the cystic glands. The breast acini in surrounding normal tissue away from the area of pathologic change were found to show a strong patchy reaction at the epithelium of the breast acini in all 25 subjects.

The stroma of breast tissue in all the 25 subjects was found to be negative, except for an occasional streak-like positivity of agglutinated

RBCs in the lumen of vessels (mostly capillaries). These served as internal controls in all the subjects of this group.

MCAR in Primary and Metastatic Carcinomas of Breast

The 45 subjects with primary carcinomas and the 15 subjects with metastatic carcinomas of breast differed significantly when compared to the subjects with benign lesions. In all 60 cases, the areas involved by the primary and metastatic tumor were found to be uniformly negative for MCAR. (Figures 3-8). In the stroma separating the groups of tumor cells and in fields away from the tumor, the same sections showed negative MCAR, except for the positive agglutination reaction in vessels (mostly capillaries) serving as internal controls. The breast acinar lobules away from tumor were occasionally preserved, while in some areas changes of cystic mastitis were present. In these areas the MCAR showed strong to patchy reaction as described in subjects with benign lesions.

Discussion

The results of this study showing negative MCAR in subjects with carcinomas of breast seem to be identical with the findings of other workers.¹⁻⁸ It is known that the MCAR in benign lesions and normal tissues of their origin is positive.¹⁻⁴ The present study in benign breast lesions and surrounding breast tissue seems to be in full agreement with these views.¹⁻⁴ Our results are consistent with the observation that the serologic reactivity of A, B and O (H) group substances show a sudden decrease in malignant tumors of breast and their metastasis, while in benign tumors of breast and in normal tissues the reactivity is retained, indicating presence of isoantigens. Therefore, a close relationship between loss of cellular A, B and H isoantigens in malignancy appears very likely.

Two main points emerge from this study. The first is that no isoantigens are found in primary and metastatic carcinomas of breast. The other is that isoantigens are always present in benign tumors and surrounding breast tissue. These findings, therefore, suggest that such a loss may be a general feature of breast malignancies. There are several possible mechanisms to explain the sudden loss of isoantigens in carcinomas of breast. In malignancies of gastrointestinal and ovarian origin, the group-specific isoantigens are suggested to be secretion product of the cells forming the tumor,^{5,6} while in other malignancies the isoantigens are believed to be an intrinsic component of

the cells of their origin.²⁻⁴ In these examples, the loss of isoantigens is probably related to destruction of isoantigens during the process of transformation to carcinoma. It may be possible that the cells in carcinomas are not able to store or produce the isoantigens. Alternatively, Davidsohn suggests that, in squamous cell carcinomas of cervix and lungs, a possible immunologic dedifferentiation may be the factor, and the degree of anaplasia in a tumor may be the basis of the occasional positive and negative MCAR in the same tumor.^{3,4} In these instances, Davidsohn has shown similar reactions in metastatic carcinomas in regional lymph nodes (for example, bronchogenic carcinomas) especially when the lymph node was in direct contiguity to the bronchus.⁴ The same author also suggests that, in squamous cell carcinomas of cervix, the loss of isoantigens may be an early indicator of the cellular changes in the tumor which are prerequisites of metastasis. This conclusion is based on the comparison of the differing findings in reversible lesions and borderline lesions of cervix and squamous cell malignancies in the cervix.³ Whatever may be the case, a fact which appears apparent in all the studies is that, in a large variety of malignancies and their metastasis, isoantigens are either reduced or negligible or are almost always totally lost.¹⁻⁸

In summarizing, we feel that, although the exact reason for the total isoantigen loss in our series of cases of primary and metastatic carcinomas is not known, it appears conceivable that, in tumors with malignant glandular differentiation, some differences exist when compared to squamous cell carcinomas. One of these differences appears to be the greater loss of isoantigens in glandular malignancies. In our opinion, this appears to be due to a total loss of cellular secretions due to destruction and/or masking of the antigens during the process of malignant transformation. We also think that the isoantigen loss in breast carcinomas is comparable to that in malignancies of prostate, gastrointestinal and ovarian origin. In these the loss of isoantigens has been shown to be of a similar magnitude to that described in the present study.^{1,5,6} Since in some cases metastases are more prone to develop in the short period of time after the initial discovery of the tumor, it may also be that, in malignant tumors with glandular differentiation, the loss of isoantigens may be an early indicator of metastasis. One such malignancy appears to be in the prostate and its metastasis, recently studied by us, in which we have shown a total loss of isoantigens in comparison to subjects with benign prostatic hyperplasia and normal prostates at different

ages.¹ The present study of benign and malignant breast tissue and metastatic lesions in regional lymph nodes and distant organs furnishes another example of a malignancy which appears to belong to a similar category of tumor that is probably more prone to metastasis because of the loss of isoantigens, which may be indicative of the property to metastasize. Certainly, careful followup is needed of more subjects with similar tumors with malignant glandular differentiation. Comparison of tumors with malignant glandular differentiation to carcinomas with squamous and nonepithelial differentiation is needed to clarify this view; with this in mind, we are now studying carcinomas of endometrium and a variety of benign and malignant brain tumors.

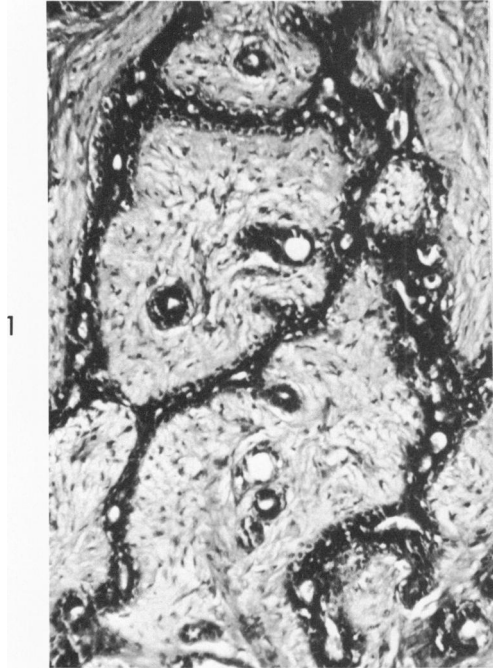References

1. Gupta RK, Schuster R, Christian WD: Loss of isoantigens A, B and H in Prostate. *Am J Pathol* 70:439-448, 1973
2. Kovarik S, Davidsohn I, Stejskal R: ABO antigens in cancer: detection with mixed cell agglutination reaction. *Arch Pathol* 86:12-21, 1968
3. Davidsohn I, Kovarik S, Ni Ly: Isoantigens A, B and H in benign and malignant lesions of cervix. *Arch Pathol* 87:306-14, 1969
4. Davidsohn I, Ni LY: Loss of isoantigens in carcinomas of lung. *Am J Pathol* 57:307-34, 1969
5. Davidsohn I, Kovarik S, Lee CH: ABO substances in gastrointestinal carcinoma. *Arch Pathol* 81:381-90, 1966
6. Davidsohn I, Kovarik S, Stejskal R: Ovarian cancer: immunologic aspects, influence on prognosis and treatment, UICC Monograph Series, Vol 11, Ovarian Cancer, Berlin, Springer Verlag, 1968, pp 105-121
7. Eklund AE, Gullbring B, Lagerlof B: Blood group specific substances in human gastric carcinoma: a study using fluorescent antibody technique. *Acta Pathol Microbiol Scand* 59:447-455, 1963
8. Davidsohn I, Stejskal R, Lill P: The loss of isoantigens ABandH in carcinomas of urinary bladder. Abstract presented at the Sixty-seventh meeting of the International Academy of Pathology, Washington DC, March 1973
9. Davidsohn I, Stejskal R, Lill P: Cancer detection tests: Commission of continuing medical education workshop of ASCP. Chicago Ill Dec. 1972
10. Davidsohn I: Technique of mixed cell agglutination reaction as revised May 1971 (Personal communication)

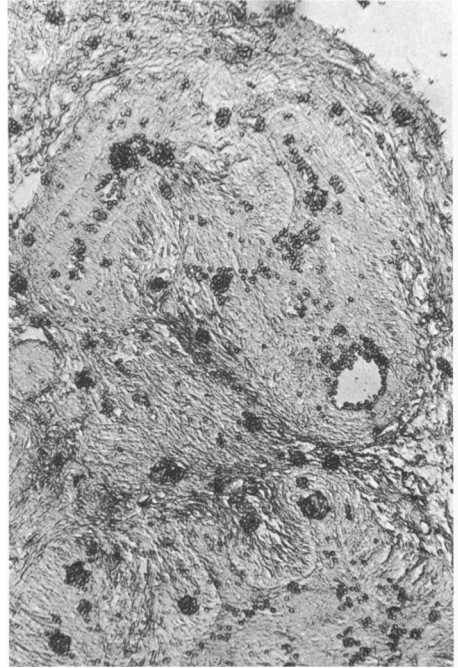
Acknowledgment

The authors gratefully acknowledge the typing and secretarial assistance of Mrs. Wanda Lanthier.

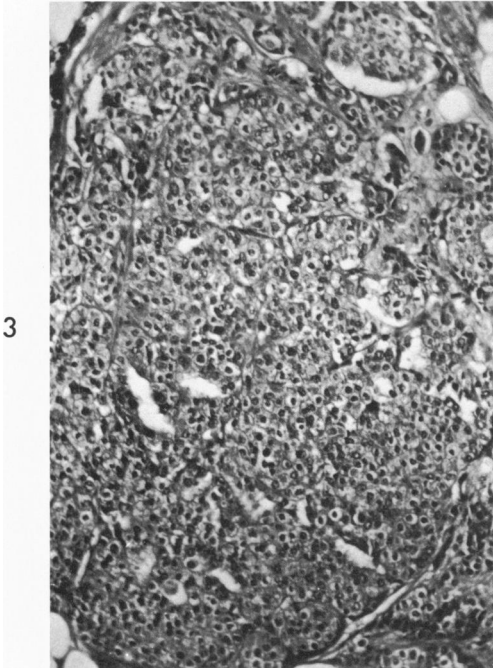
[Illustrations follow]



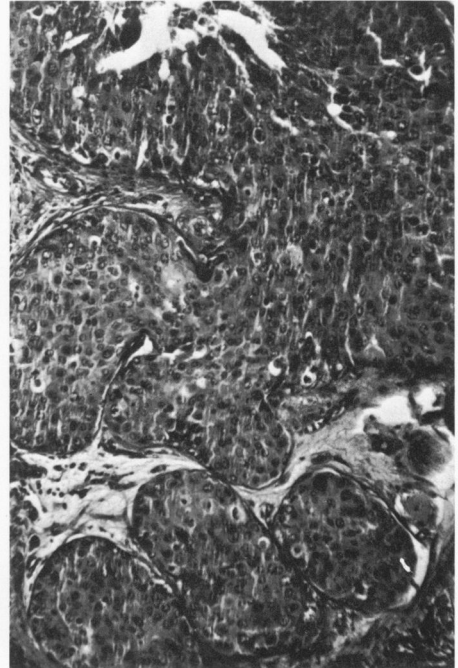
1



2

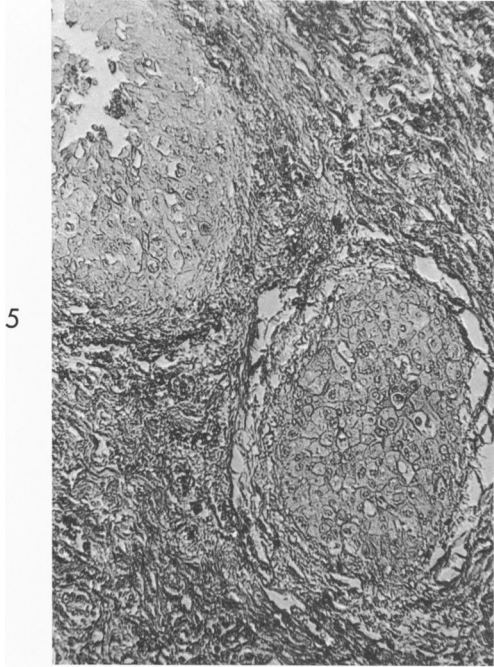


3

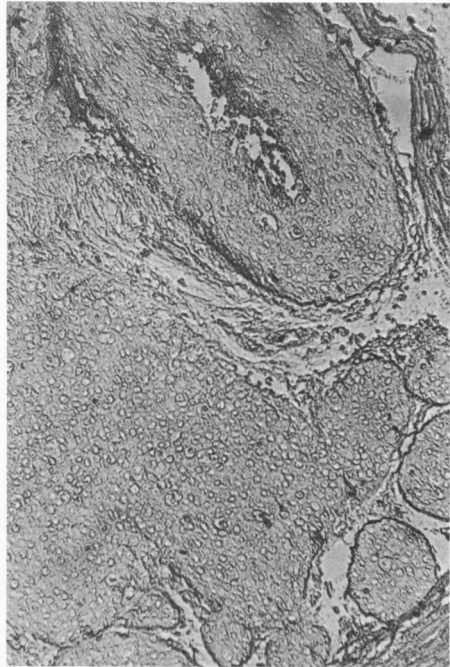


4

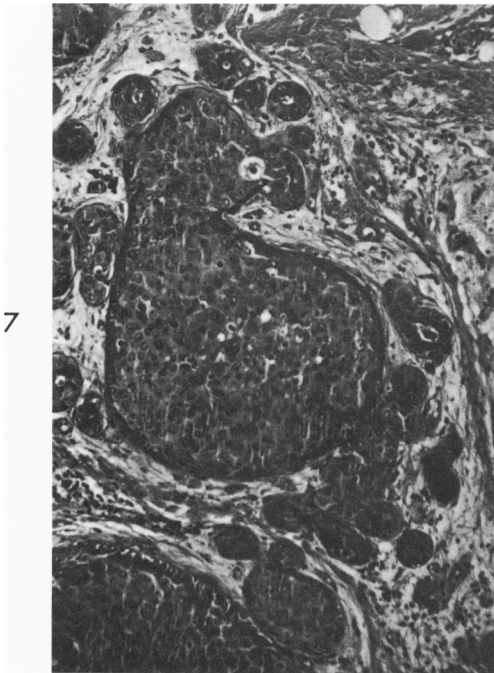
Fig 1—Microscopic features of a subject with fibroadenoma of breast, belonging to group B (H & E, X 250). **Fig 2**—Tissue from the above subject, showing strongly positive MCAR at the epithelium of acini and negative reaction in stroma (X 250). **Figs 3 and 4**—Two subjects with primary carcinoma of breast, belonging to group AB and O, showing microscopic features of the tumors (H & E, X 250).



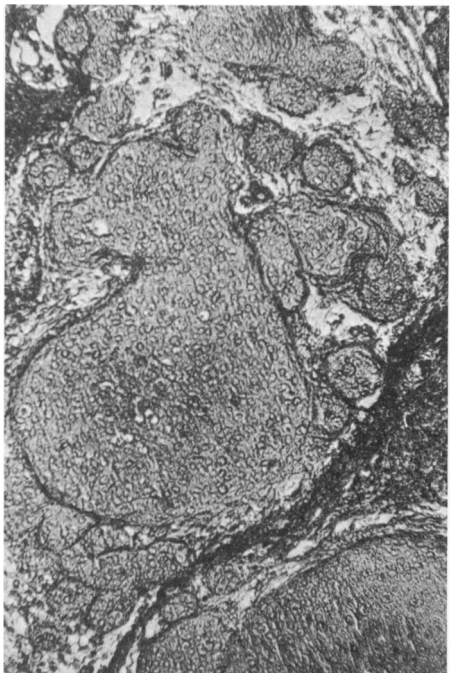
5



6



7



8

Figs 5 and 6—The above two subjects in Figures 3 and 4 showing negative MCAR in areas of malignant change ($\times 250$). **Fig 7**—Microscopic features of a subject with metastatic breast carcinoma in a regional lymph node, belonging to group A (H & E, $\times 250$). **Fig 8**—The above subject, showing negative MCAR in the areas of tumor metastasis ($\times 250$).