

Adhesion molecule expression *in vivo* on extraocular muscles (EOM) in thyroid-associated ophthalmopathy (TAO)

A. PAPPA*†, V. CALDER†, P. FELLO* & S. LIGHTMAN*† *Moorfields Eye Hospital NHS Trust and †Department of Clinical Ophthalmology, Institute of Ophthalmology, London, UK

(Accepted for publication 14 January 1997)

SUMMARY

TAO is an autoimmune condition characterized by mononuclear cell infiltration of the extraocular muscles (EOM) and/or the orbital fat/connective tissue with associated deposition of glycosaminoglycans (GAG) in the interstitial spaces. In this study, the presence and distribution of the vascular adhesion molecules intercellular adhesion molecule-1 (ICAM-1), endothelial-leucocyte adhesion molecule-1 (ELAM-1), vascular cell adhesion molecule-1 (VCAM-1) and the leucocyte integrins CD11a/CD18, CD11b/CD18, CD11c/CD18 were investigated. Nineteen EOM biopsies were collected from 17 patients with early ($n = 6$) and late ($n = 13$) TAO as well as from 12 non-TAO control patients. Consecutive cryostat sections of these biopsies were immunostained with MoAbs to the above-mentioned molecules and haematoxylin and eosin. Primary antibody binding was visualized using an avidin-biotin system. In early untreated TAO specimens, the interstitial and perimysial connective tissue surrounding EOM fibres and numerous mononuclear cells stained strongly for ICAM-1. In contrast, the vascular endothelial cells (ulex lectin-positive) stained strongly for ELAM-1 (E-selectin), VCAM-1 as well as ICAM-1. In late disease, the same distribution of immunoreactivity for ICAM-1, ELAM-1 and VCAM-1 was observed, but with significantly lower staining. The leucocyte integrins (CD11a, CD11b, CD11c) were again expressed at significantly higher levels in early TAO specimens compared with late TAO specimens and were minimal or absent in the EOM biopsies harvested from control patients. In conclusion, increased expression of adhesion molecules studied correlated with early active disease and was reduced in later stages.

Keywords autoimmunity adhesion molecules immunohistochemistry flow cytometry thyroid-associated ophthalmopathy

INTRODUCTION

TAO is a disfiguring and potentially sight-threatening disease for which current therapy is limited to addressing the complications of the disease, which include optic nerve compression with possible loss of vision, exposure keratitis, and impairment of eye movements due to EOM inflammatory involvement [1]. No effective means of prevention are known. Since no animal model exists for TAO, studies on the pathogenesis of the disease have to date relied on clinical material, particularly blood samples from patients affected by TAO.

The strong association between TAO and autoimmune thyroid disease (ATD) suggests that these two conditions share a common autoimmune pathogenesis. TAO is associated with Graves' disease (GD) in about 90% of patients [2–6], the remaining 10% of TAO patients having Hashimoto's thyroiditis or a subclinical form of thyroid autoimmunity in roughly equal numbers. However, the

exact relationship between GD and TAO is unclear, with the course of ophthalmopathy being independent from that of the thyroid disease and being largely unaffected by its treatment [7]. EOM are the major site of the autoimmune inflammatory process in TAO, although orbital fat/connective tissue is also involved. The few histopathological studies of involved EOM that have been performed to date reported patchy lymphocytic infiltration of muscle [8–10] with deposition of glycosaminoglycans (GAG) [8,9,11–14], particularly hyaluronan [15], by activated fibroblasts in the interstitial spaces.

The binding of leucocytes to endothelial cells is an essential initial step in the inflammatory response; it promotes leucocyte trafficking and is mediated by adhesion molecules. Adhesion molecules are three main families: immunoglobulin supergenes (including chemoattractants), selectins and integrins. Among the immunoglobulin supergene group which bind integrins, the intercellular adhesion molecule-1 (ICAM-1) facilitates leucocyte interactions with a variety of different cell types [16], and the vascular cell adhesion molecule-1 (VCAM-1) promotes lymphocyte adhesion to endothelial cells [17,18]. Of the selectin family,

Correspondence: Professor Susan Lightman, Department of Clinical Ophthalmology, Moorfields Eye Hospital, City Road, London, EC1V 2PD, UK.

Table 1. Early, active TAO patient characteristics

Patient no.	Age/sex	Duration of TAO*	Class at time of biopsy†	Treatment
1	54/F	6	4(4b)	None
2	39/F	6	4(4b, 2b)‡	R, S (prior to biopsy)
3	42/F	4	4(4b)	None
4	29/M	3	4(4b, 2b)	None
5	51/F	5	4(4b)	None
6	52/M	6	4(4b, 2b)	R, S (prior to biopsy)

* Expressed as the time elapsed since diagnosis.

† Class according to modified NO SPECS classification [25].

‡ Class prior to biopsy: 6(6a, 4b, 2b).

R, Orbital radiotherapy; S, steroids.

E-selectin, previously known as endothelial-leucocyte adhesion molecule-1 (ELAM-1) [19,20], mediates selective recruitment of a subset of memory T cells [21,22]. The leucocyte integrin family [23] comprises three $\alpha\beta$ heterodimeric membrane glycoproteins with a common β subunit, designated CD18. The α subunits of each of the three members, lymphocyte function-associated antigen-1 (LFA-1), macrophage antigen-1 (Mac-1) and p150,95, are designated CD11a, b and c, respectively. CD11a/CD18 binds to ICAM-1 and ICAM-2, CD11b/CD18 binds to a variety of ligands including ICAM-1 and C3bi, CD11c/CD18 binds to C3bi, and hence play a critical part in the immune and inflammatory responses of leucocytes.

The one previous study of *in situ* expression of selectin and immunoglobulin superfamily type adhesion molecules in TAO has utilized retroocular connective tissue specimens obtained from three patients with severe TAO undergoing orbital decompression surgery [24], as EOM tissue is not excised during the course of orbital decompression surgery for TAO. However, in the same study EOM tissue was obtained at autopsy, from one patient with severe TAO, and a strong ICAM-1 immunoreactivity was detected on the perimysial tissue but not on the EOM themselves [24].

To provide further information on the expression of adhesion molecules in TAO we have taken biopsies of affected EOM from two groups of TAO patients. The first group consisted of patients with early, active TAO, and the second of patients with late, inactive TAO. The pattern of adhesion molecules ICAM-1, E-selectin, VCAM as well as that of the leucocyte integrins CD11a/CD18, CD11b/CD18, and CD11c/CD18 was assessed by means of immunohistochemistry.

PATIENTS AND METHODS

Patients

EOM biopsies were obtained from two patient groups with TAO. All patients were biochemically euthyroid at the time of biopsy and class 4 according to modified NO SPECS classification [25]. Informed consent and Ethical Committee approval was obtained for both patient groups. The biopsies were obtained from the belly of the muscle (10–12 mm from the insertion), the muscle sheath having been dissected off, and without prior application of any diathermy.

Early TAO. Six biopsies were taken under local anaesthesia from six patients with early disease not undergoing corrective strabismus surgery (see Table 1). Patient nos 2 and 6 still showed evidence of active orbital inflammation despite having had treatment with radiotherapy followed by steroids. No complications were encountered during this procedure and none of these patients developed ocular motility problems as a result of their biopsy.

Late TAO. Thirteen biopsies were collected from 11 late, inactive TAO patients (see Table 2). Patient nos 8 and 9 were euthyroid from the onset of TAO and at the time of biopsy. Specimens were taken during the course of corrective strabismus surgery for tight EOM, which were restricting normal ocular movements.

Controls. Twelve normal-appearing EOM biopsies obtained during routine non-thyroid related strabismus surgery (seven males, five females; age 24–55 years) served as controls.

Immunohistochemical studies

All EOM specimens were embedded in optimal cutting temperature (OCT) embedding medium, snap-frozen in liquid nitrogen and

Table 2. Late, inactive TAO patient characteristics

Patient no.	Age/sex	Duration of TAO*	Class prior to biopsy†	Class at time of biopsy†	Treatment
7	47/M	9 years		4(4b)	None
8	52/M	10 months		4(4b, 2b)	R (prior to biopsy)
9	66/M	9 years		4(4b)	S (prior to biopsy)
10	55/F	20 months		4(4b)	None
11	40/M	17 months		4(4b)	None
12	57/F	10 months		4(4b, 2b)	None
13	69/F	12 months	6(6a, 4b)	4(4b)	R (prior to biopsy)
14	67/M	40 months	6(6a, 4b)	4(4b)	R, S (prior to biopsy)
15	60/F	30 months		4(4b)	R, S (prior to biopsy)
16	61/M	40 months		4(4b)	S (prior to biopsy)
17	56/M	27 months	6(6a, 4b)	4(4b)	R, S (prior to biopsy)

* Expressed as the time elapsed since diagnosis.

† Class according to modified NO SPECS classification [25].

R, Orbital radiotherapy; S, steroids.

stored at -70°C until use. Transverse cryostat sections ($5\ \mu\text{m}$) were mounted on 3-amino propyl tri-ethoxy silane (APES; Sigma, Poole, UK)-coated slides. Consecutive cryostat sections were immunostained with MoAbs to the studied adhesion molecules and haematoxylin and eosin (H-E). Primary antibody binding was visualized using an avidin-biotin system. All antibodies (anti-ICAM-1, anti-ELAM-1, anti-VCAM-1, anti-CD11a, anti-CD11b, anti-CD11c) were obtained from R&D Systems Europe (Abingdon, UK), except ulex lectin (Sigma) and UCHL1 (Dako, High Wycombe, UK).

Slides were thawed at room temperature and air-dried for 30 min. Before immunohistochemical staining, sections were fixed in cold acetone (4°C) for 5 min and washed in PBS pH 7.4 for another 15 min. Immunoperoxidase staining was performed using the Vector ABC Kit (PK-4002; Vector Labs, Peterborough, UK) with a few modifications. Non-specific antibody uptake was blocked using normal horse serum for 20 min, followed by incubation with a primary MoAb for 30 min in a humidified chamber at room temperature. After a wash in PBS for 10 min, the secondary biotinylated horse anti-mouse antibody was applied for 30 min. Endogenous peroxidase activity was suppressed by incubating sections in 0.3% H_2O_2 in 50% methanol for 20 min. After a further wash in PBS for 10 min, sections were incubated with a preformed avidin and biotinylated horseradish peroxidase macromolecular complex for 45 min. The peroxidase reaction was then developed with the chromogenic substrate amino-ethyl-carbazole (AEC; Sigma). The substrate was filtered and 30% hydrogen peroxide (Sigma) was added to a final concentration of 0.03% H_2O_2 . Sections were developed for 2–5 min, washed in distilled water, and counterstained in Mayer's haematoxylin for 30 s. Finally, sections were washed in cold tap water for 5 min, mounted with aqueous-based glycerol gelatine medium (Dako). The primary antibody was omitted to provide a negative control, and palatine tonsil tissue sections from tonsillectomies were used to confirm optimal staining concentration for antibodies used. Positively stained cells or vessels were counted per $\times 400$ microscope field and the mean result from at least nine fields was calculated.

Statistical analysis

Student's *t*-test was carried out on the immunohistochemistry data with SPSS software, and $P < 0.05$ was considered significant in the comparisons between control and disease samples.

RESULTS

Immunohistochemistry

Normal EOM. Normal appearing EOM biopsies from non-TAO patients showed that a maximum of 3% of the vessels stained faintly with ICAM-1, 2% with VCAM-1, and 1% very faintly with E-selectin (by comparison with ulex lectin). Very few T cells were found in control specimens, and those present expressed minimal levels of the integrins studied (Table 3).

Early TAO. Strong ICAM-1 immunoreactivity was detected in the interstitial and perimysial connective tissue that surrounds EOM fibres. In addition to its expression in connective tissue cells, prominent ICAM-1 immunoreactivity was also detected in numerous mononuclear cells and in ulex lectin-positive vascular endothelial cells (Figs 1 and 2). There was marked up-regulation of ICAM-1 (89%, $P < 0.001$) and E-selectin (83%, $P < 0.001$) as well as VCAM-1 (85%, $P < 0.001$) (Table 3) (Fig. 3). In counting CD11a^+ , CD11b^+ , CD11c^+ cells it was observed that CD11a (Fig. 4) was significantly up-regulated (72%, $P < 0.001$), as well as CD11b (46%, $P < 0.001$) and CD11c (32%, $P < 0.001$). EOM fibres themselves did not demonstrate ICAM-1 immunoreactivity. In both early and late TAO EOM specimens, faint VCAM-1 immunoreactivity was also detected in occasional connective tissue cells that did not show any ulex lectin immunoreactivity.

Late TAO. Although the distribution of adhesion molecules was the same in both early and late TAO specimens, there was a striking difference in the levels of expression of these molecules. In spite of the fact that the endothelial markers in the early TAO specimens reached close to maximal levels of expression, in the late TAO specimens only 25–40% of ulex lectin-positive vessels expressed ICAM-1, ELAM-1 or VCAM-1 (Table 3). Correspondingly, lower levels of the counterpart ligands for ICAM-1 were observed on the infiltrating T cells in late TAO specimens (Table 3).

DISCUSSION

TAO is an autoimmune condition characterized by mononuclear cell infiltration of the EOM and/or the orbital fat/connective tissue with associated deposition of GAG in the interstitial spaces. The accumulation of GAG, along with the attendant tissue oedema, leads to the clinical manifestations of TAO [15]. Adhesion molecules are important receptors for a variety of interactions

Table 3. Mean percent vessel/cell counts ($\times 400$ field) of positive vessel/cells in the EOM of early and late TAO and control specimens

Specimens		Percent positive vessels				Percent positive cells			
		Ulex lectin	ICAM-1	ELAM-1	VCAM-1	CD3	CD11a	CD11b	CD11c
Early TAO ($n = 6$)	Mean % count	100.00	89.00***	83.17***	84.83***	100.00	72.00***	46.50***	32.00***
	\pm s.e.m.	0.00	1.26	2.89	1.51	0.00	4.39	2.86	2.57
Late TAO ($n = 13$)	Mean % count	100.00	42.23***	24.62***	29.23***	100.00	36.69***	24.15***	10.23***
	\pm s.e.m.	0.00	3.52	3.62	3.93	0.00	4.51	2.41	1.91
Normal EOM ($n = 12$)	Mean % count	100.00	2.83	1.92	0.92	100.00	5.42	4.33	0.00
	\pm s.e.m.	0.00	0.47	0.42	0.42	0.00	3.87	2.96	0.00

*** ($P < 0.001$).

Statistical analysis refers to comparisons between samples from TAO and normal EOM using the same antibody.

ICAM-1, Intercellular adhesion molecule-1; ELAM-1, endothelial-leucocyte adhesion molecule-1; VCAM-1, vascular cell adhesion molecule-1.

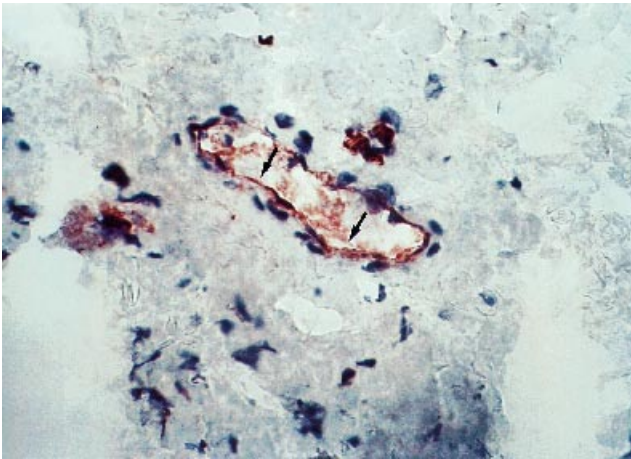


Fig. 1. Light micrograph of EOM tissue from a strabismus control patient. Immunoperoxidase staining for ulex lectin on a cryostat section. Positive staining of capillary endothelium is seen as a brown precipitate (arrows). ($\times 476$.)

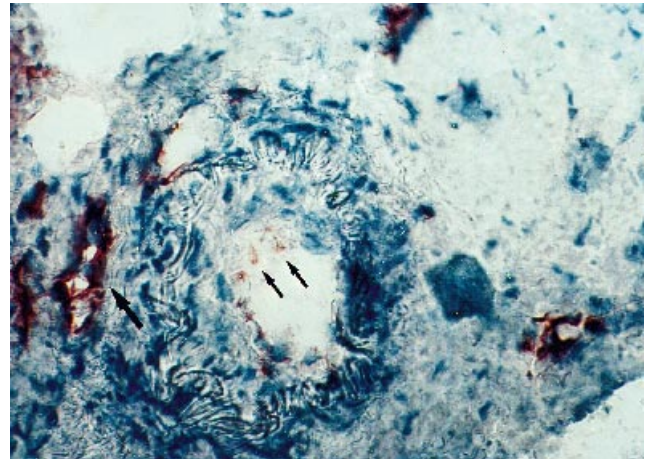


Fig. 3. Light micrograph of immunoperoxidase staining for endothelial-leucocyte adhesion molecule-1 (ELAM-1) (E-selectin) on a cryostat section of EOM tissue from a patient with TAO. There is positive staining of the vascular endothelium (arrows). ($\times 476$.)

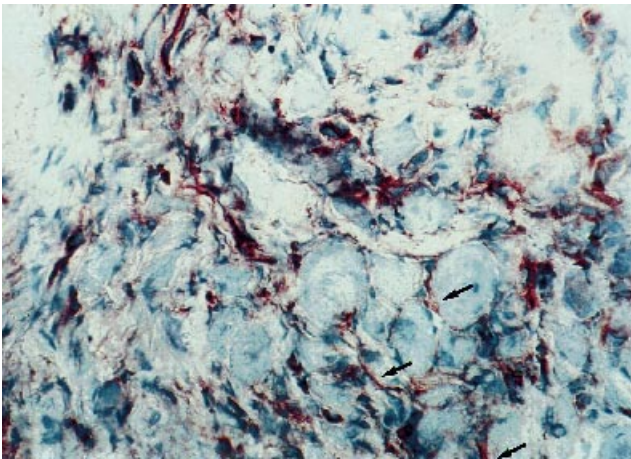


Fig. 2. Light micrograph of immunoperoxidase staining for intercellular adhesion molecule-1 (ICAM-1) on a cryostat section of EOM tissue from a patient with TAO. There is irregular staining of the endomysium of individual muscle fibres (arrows) seen as a brown precipitate. ($\times 476$.)

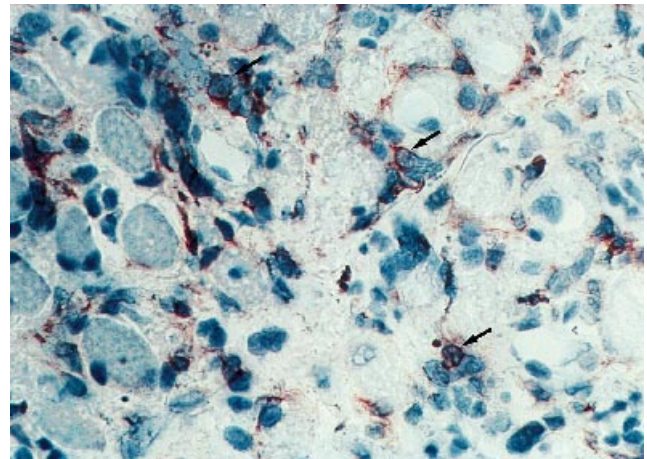


Fig. 4. Light micrograph of immunoperoxidase staining for CD11a on a transversely cut cryostat section of extraocular muscle from a TAO patient. Several mononuclear cells show positive staining of their cytoplasmic membranes (arrows). ($\times 476$.)

between immunocompetent cells, connective tissue cells and extracellular matrix components [26]. Adhesion of circulating leucocytes to the blood vessel wall is an essential component of acute and chronic events in various organ-specific autoimmune diseases [27,28].

This study demonstrated, by immunohistochemistry, that ICAM-1, ELAM-1, VCAM-1, and the leucocyte integrins (CD11a/CD18, CD11b/CD18, CD11c/CD18) were minimal or absent in normal appearing EOM biopsies harvested from control patients. In contrast, in early, untreated TAO specimens, strong ICAM-1 immunoreactivity was observed in the interstitial and perimysial connective tissue surrounding EOM fibres, in numerous mononuclear cells, and in ulex lectin-positive vascular endothelial cells. Also, immunoreactivity for ELAM-1 and VCAM-1 was detected at high levels in ulex lectin-positive blood vessels in the early TAO specimens studied. However, immunoreactivity for the same vascular adhesion molecules in late TAO specimens only reached levels of 25–40% of ulex lectin-positive vessels, although

the distribution of these adhesion molecules was the same in both early and late TAO specimens. Concerning the leucocyte integrins (CD11a/CD18, CD11b/CD18, CD11c/CD18), again significantly higher levels of expression were detected in the early TAO specimens compared with late TAO specimens.

EOM fibres themselves were spared any immunoreactivity for the adhesion molecules studied, suggesting that it is the extracellular matrix component of the EOM which is involved in the inflammatory process. The lack of staining on the EOM fibres is in agreement with preliminary observations by Heufelder & Bahn [24] on EOM tissue from one patient with severe TAO. In conclusion, the immunohistochemistry results suggest a strong correlation between increased expression of adhesion molecules and disease activity.

Heufelder & Bahn have demonstrated previously that interferon-gamma (IFN- γ), tumour necrosis factor-alpha (TNF- α) and IL-1 α are capable of inducing the expression of functionally active ICAM-1 in cultured retroocular fibroblasts [29]. Also, the

same group have demonstrated that immunoreactivity for IFN- γ , TNF- α and IL-1 α can be detected in vascular endothelium and connective tissue of retroocular tissue biopsies obtained from patients with severe Graves' ophthalmopathy, but not in retroocular tissue from normal individuals [30]. Recently, we have shown that EOM-derived T cell lines from TAO patients are capable of producing a panel of cytokines, including IFN- γ , TNF- β and transforming growth factor-beta (TGF- β) (Pappa *et al.*, 1996, submitted). It is thus possible that certain cytokines, present in the EOM vasculature microenvironment, are involved in the activation of vascular adhesion molecules such as ICAM-1, ELAM-1 and VCAM-1, and facilitate the recruitment and access of certain immunocompetent cells to the EOM in TAO.

These results are of clinical interest, and at least some of these adhesion molecules may indeed identify a potential target for future therapeutic intervention. Given the currently increasing understanding of the way these various receptors and their counter-receptors work together *in vivo* in regulating the normal physiology of EOM, and the way they contribute to the pathogenesis of TAO, the challenge now is to discover ways of inhibiting *in vivo* these interactions in a monospecific, non-toxic way. The use of soluble forms of these receptors or their counter-receptors to control the disease process, as well as the use of multivalent ligand constructs as antagonists of the endothelial adhesion molecules, are currently being explored.

ACKNOWLEDGMENTS

We are grateful to Mr John Lee for providing three of the non-TAO extraocular muscle (EOM) specimens, and to Mr John Wright for providing two of the TAO EOM samples for the immunohistochemical part of the study. Also, to Professor Valerie Lund for providing the palatine tonsillectomy tissues and to Dr Colin Dayan for his stimulating discussions and interest in our work. This work was supported by the Royal National Institute for the Blind (A.P.), and the Thyroid Eye Disease Charitable Trust (A.P.), to whom we are also grateful.

REFERENCES

- Fells P. Thyroid-associated eye disease: clinical management. *Lancet* 1991; **338**:9–32.
- Jacobson DH, Gorman CA. Endocrine ophthalmopathy: current ideas concerning etiology, pathogenesis, and treatment. *Endocr Rev* 1984; **5**:200–20.
- Wall JR, Salvi M, Bernard NF, Boucher A, Haegert D. Thyroid-associated ophthalmopathy—a model for the association of organ-specific autoimmune disorders. *Immunol Today* 1991; **12**:150–3.
- Weetman AP. Thyroid-associated eye disease: pathophysiology. *Lancet* 1991; **338**:25–28.
- Bahn RS, Heufelder AE. Pathogenesis of Graves' ophthalmopathy. *N Engl J Med* 1993; **329**:1468–75.
- Perros P, Kendall-Taylor P. Thyroid-associated ophthalmopathy: pathogenesis and clinical management. *Baillieres Clin Endocrinol Metab* 1995; **9**:115–35.
- Sridama V, De Groot LJ. Treatment of Graves' disease and the course of ophthalmopathy. *Am J Med* 1989; **87**:70–73.
- Hufnagel TJ, Hickey WF, Cobbs NH, Jakobiec FA, Iwamoto T, Eagle RC. Immunohistochemical and ultrastructural studies on the exenterated orbital tissues of a patient with Graves' disease. *Ophthalmology* 1984; **91**:1411–9.
- Weetman AP, Cohen S, Gatter KC, Fells P, Shine B. Immunohistochemical analysis of the retrobulbar tissues in Graves' ophthalmopathy. *Clin Exp Immunol* 1989; **75**:222–7.
- Hiromatsu Y, Tanaka K, Ishisaka N *et al.* Human histocompatibility leukocyte antigen-DR and heat shock protein-70 expression in eye muscle tissue in thyroid-associated ophthalmopathy. *J Clin Endocrinol Metab* 1995; **80**:685–91.
- Kroll AJ, Kuwabara T. Dysthyroid ocular myopathy: anatomy, histology, and electron microscopy. *Arch Ophthalmol* 1966; **76**:244–57.
- Riley FC. Orbital pathology in Graves' disease. *Mayo Clin Proc* 1972; **47**:975–9.
- Tallstedt L, Norberg R. Immunohistochemical staining of normal and Graves' extraocular muscle. *Invest Ophthalmol Vis Sci* 1988; **29**:175–84.
- Campbell RJ. Immunology of Graves' ophthalmopathy: retrobulbar histology and histochemistry. *Acta Endocrinol (Copenh)* 1989; **121** (Suppl. 2):9–16.
- Smith TJ, Bahn RS, Gorman CA. Connective tissue, glycosaminoglycans, and diseases of the thyroid. *Endocr Rev* 1989; **10**:366–91.
- Makgoba MW, Sanders ME, Shaw S. The CD2-LFA-3 and LFA-1-ICAM-1 pathways: relevance to T-cell recognition. *Immunol Today* 1989; **10**:417–22.
- Osborn L, Hession C, Tizard R. Direct expression cloning of vascular cell adhesion molecule 1, a cytokine-induced endothelial protein that binds to lymphocytes. *Cell* 1989; **59**:1203–8.
- Carlos TM, Schwartz BR, Kovach NL. Vascular cell adhesion molecule-1 mediates lymphocyte adherence to cytokine-activated cultured human endothelial cells. *Blood* 1990; **76**:965–9.
- Bevilacqua MP, Pober JS, Mendrick DL. Identification of an inducible endothelial-leukocyte adhesion molecule. *Proc Natl Acad Sci USA* 1987; **84**:9238–42.
- Bevilacqua MP, Stengelin S, Gimbrone MAJ. Endothelial leukocyte adhesion molecule 1: an inducible receptor for neutrophils related to complement regulatory proteins and lectins. *Science* 1989; **243**:1160–5.
- Picker LJ, Kishimoto TK, Smith CW. ELAM-1 is an adhesion molecule for skin-homing T cells. *Nature* 1991; **349**:796–9.
- Shimizu Y, Shaw S, Graber N. Activation-independent binding of human memory T cells to adhesion molecule ELAM-1. *Nature* 1991; **349**:799–802.
- Yong K, Khwaja A. Leucocyte cellular adhesion molecules. *Blood Reviews* 1990; **4**:211–25.
- Heufelder AE, Bahn RS. Elevated expression *in situ* of selectin and immunoglobulin superfamily type adhesion molecules in retroocular connective tissues from patients with Graves' ophthalmopathy. *Clin Exp Immunol* 1993; **91**:381–9.
- Werner SC. Modification of the classification of the eye changes of Graves' disease: recommendations of the Ad Hoc Committee of the American Thyroid Association. *J Clin Endocrinol Metab* 1977; **44**:203–4.
- Springer TA. Adhesion receptors of the immune system. *Nature* 1990; **346**:425–34.
- Frenette PS, Wagner DD. Adhesion molecules—Part I. *N Engl J Med* 1996; **334**:1526–9.
- Frenette PS, Wagner DD. Adhesion molecules—Part II: blood vessels and blood cells. *N Engl J Med* 1996; **335**:43–45.
- Heufelder AE, Bahn RS. Modulation of intercellular adhesion molecule-1 (ICAM-1) by cytokines and Graves' IgGs in cultured Graves' retroocular fibroblasts. *Eur J Clin Invest* 1992; **22**:529–37.
- Heufelder AE, Bahn RS. Detection and localization of cytokine immunoreactivity in retro-ocular connective tissue in Graves' ophthalmopathy. *Eur J Clin Invest* 1993; **23**:10–17.