

ANIMAL MODEL
OF
HUMAN DISEASE

Breast Cancer

Animal Model: Canine Mammary
Neoplasia

Contributed by: J. D. Strandberg, DVM, PhD, Division of Laboratory Animal Medicine and Department of Pathology, The Johns Hopkins University School of Medicine, Baltimore, MD 21205; and D. G. Goodman, VMD, Comparative Pathology Section, Bldg 28-A, Rm 103, National Institutes of Health, Bethesda, MD 20014.

Carcinoma of the breast is one of the most prevalent types of human neoplasia. The cause, nature and control of breast cancer have been studied in human subjects insofar as possible, but many experimental procedures are impossible to perform in man. Thus, the viral mammary neoplasms of inbred strains of rodents have been used extensively in etiologic, pathogenetic and therapeutic studies. The primary disadvantage of these murine models is that they differ from the human disease in three major respects: a) the rodents are highly inbred, genetically uniform populations; b) the tumors are pathologically different from those seen in man and c) viral particles are present in the tumors. In contrast, mammary tumors occurring spontaneously in the general dog population represent a more appropriate model of human breast neoplasia.

Veterinarians have long recognized that mammary tumors are among the most common canine neoplasms, and a number of these have been studied epidemiologically or pathologically.¹⁻³ These studies have shown many features in which mammary neoplasia of the dog bears strong resemblance to that of man.^{4, 5}

The incidence of naturally occurring breast tumors in the dog is two or three times greater than the level reported in human populations.^{5, 6} The peak reported incidence in man is in the 50 to 58 year age group; in dogs the highest incidence is observed in animals which are 8 to 11 years old, a comparable age group.¹⁻⁵ Sex distribution is very similar in both man and dogs. Breast cancer is almost entirely a disease of females; cases in both human and canine males are reported, but these are rare

Publication sponsored by the Registry of Comparative Pathology of the Armed Forces Institute of Pathology and supported by Public Health Service Grant RR 00301 from the Division of Research Resources, US Department of Health, Education and Welfare, under the auspices of Universities Associated for Research and Education in Pathology, Inc.

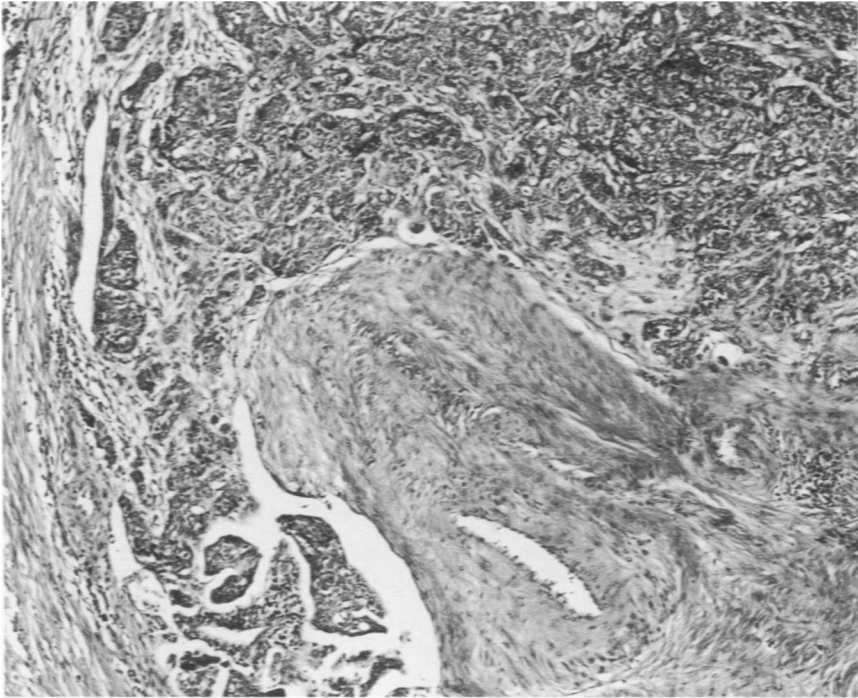


Fig 1—Infiltrating adenocarcinoma of duct origin in a canine mammary gland. Clumps of neoplastic cells are present in lymphatic spaces. Tumors of this type are relatively common (H&E, $\times 80$).

events.^{3, 5-6} The importance of the role of the sex hormones in mammary neoplasia is further indicated in the dog. In animals oophorectomized before puberty the risk of cancer is 0.5% that of intact females.³ Later castration is less effective in preventing the disease.^{1, 6, 9} In humans there is some evidence that early oophorectomy also decreases the risk of breast cancer.⁵ It has been found that nulliparous women have a significantly higher incidence of breast cancer than do their multiparous counterparts.^{7, 8} Similarly in dogs, a higher incidence has been reported in nulliparous bitches and in animals which have had few litters compared to bitches which have whelped large numbers of litters. These intact but unbred bitches also have a variety of other reproductive disorders including irregular estrous cycles, cystic hyperplasia of the endometrium and pyometra.^{1, 3, 9} A major deficiency of most epidemiologic studies of canine mammary tumors is lack of differentiation of various mammary lesions, even to the point of distinguishing benign from malignant lesions.

The pathologic study of canine mammary lesions has in many respects followed that of human breast disease. After considerable study and controversy, surgical pathologists have arrived at widely accepted classification systems for human breast lesions, and in most instances

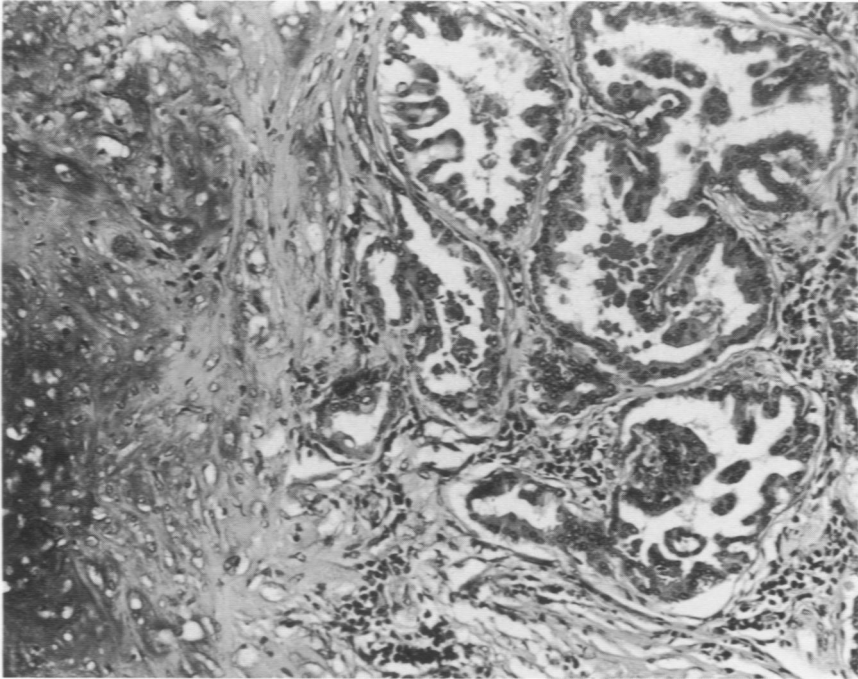


Fig 2—Mixed tumor of the canine mammary gland. The micrograph contains areas of proliferating epithelial and stromal elements including cartilage ($\times 165$).

histologic criteria have prognostic significance.^{7,8} Several pathologic studies of canine mammary tumors have been published, and several classification systems have been proposed,¹⁻³ but there is still variability in nomenclature used by veterinary pathologists.

Histologically benign lesions have been found in dog mammary tissue; these are morphologically very similar to those recognized commonly in the human breast.^{1-3,10} In man, such lesions are correlated with an increased incidence of breast cancer.^{7,8} No such study has been reported in dogs.

Most malignant human breast lesions are infiltrating carcinomas of the duct system.^{7,8} Several histologic patterns are recognized and associated with clinical behavior and prognosis. The dog also has infiltrating malignant epithelial neoplasms of duct origin which are histologically very similar to those in man (Figure 1). Several studies have shown that approximately 40% of all canine mammary tumors are adenocarcinomas;^{1,4} thus the incidence is at least equivalent to that in the human population. Lobular carcinoma and lobular carcinoma *in situ* are reported to occur as 10% of all canine carcinomas.³ This figure also corresponds to human incidence. These malignant epithelial breast neoplasms in the dog thus represent a close model of human breast

cancer in morphology, behavior and incidence.

The great similarity between the two species has been obscured by the presence of another type of proliferative canine breast lesion, the mixed tumors (Figure 2). Although mixed tumors of the breast are reported in man, they are rare occurrences. In contrast, approximately 50% of the total breast lesions reported in dogs are benign and malignant mixed mammary tumors. The nature of these tumors and the source of the myxoid, chondroid and osteoid elements present within them has caused considerable speculation. Recently it has been shown that they arise from myoepithelial cells.¹¹ The malignant potential of canine mixed tumors is probably low, and those which do metastasize most commonly do so as carcinomas. Other neoplastic mammary lesions also occur in dogs; as in man, sarcomas of the breast are uncommon lesions.

Availability

In conclusion, the naturally occurring carcinomas of the canine mammary gland are important models of human breast cancer. These models are readily available from the general dog population, are epidemiologically and pathologically similar to their human counterparts, and lend themselves to a variety of experimental manipulations.

References

1. Bloom F: The genitourinary system, with clinical considerations, Pathology of the Dog and Cat. Evanston, Ill, American Veterinary Publications, Inc, 1954, pp 413-443
2. Cotchin E: Mammary neoplasia of the bitch. *J Comp Pathol* 68:1-22, 1958
3. Moulton JE, Taylor DON, Dorn CR, Andersen AC: Canine mammary tumors. *Pathol Vet* 7:289-320, 1970
4. Prier JE, Brodey RS: Canine neoplasia: a prototype for human cancer study. *Bull WHO* 29:331-344, 1963
5. Schneider R: Comparison of age, sex, and incidence rates in human and canine breast cancer. *Cancer* 26:419-426, 1970
6. Dorn CR, Taylor DON, Schneider R, Hibbard HH, Klauber MR: Survey of animal neoplasms of Alameda and Contra Costa Counties, California. II. Cancer morbidity in dogs and cats from Alameda County. *J Natl Cancer Inst* 40:307-318, 1968
7. Kuzma JK: Breast, Pathology, Sixth edition. Edited by WD Anderson, St. Louis, The C.V. Mosby Company, 1971, pp 1578-1605
8. McDivitt RW, Stewart FW, Berg JW: Tumors of the Breast, Fascicle, 2, Washington, DC, Armed Forces Institute of Pathology, 1968
9. Andersen AC: Parameters of mammary gland tumors in aging beagles. *J Am Vet Med Assoc* 147: 1653-1654, 1965
10. Cameron AM, Faulkin LJ Jr: Hyperplastic and inflammatory nodules in the canine mammary gland. *J Natl Cancer Inst* 47: 1277-1287, 1971
11. Pulley LT: Ultrastructural and histochemical demonstration of myoepithelium in mixed tumors of the canine mammary gland. *Am J Vet Res* 34:1513-1522, 1973