

GLOMERULAR CHANGES IN ARTERIOSCLEROTIC CONTRACTION OF THE KIDNEY *

PAUL KIMMELSTIEL, M.D.

(From the Pathological Laboratory of the Boston City Hospital, Boston, Mass.)

In the course of systematic investigations on arteriosclerotic contraction of the kidney, I have paid special attention to the changes in the basement membrane of the glomerulus and its capsule.

The following communication is confined to degenerative changes and is not concerned with inflammatory processes. Furthermore, those degenerative changes that are due directly to lesions of the vas afferens are not considered. The method of glomerular destruction associated with hyaline or fatty degeneration of the vas afferens — whether due to obstruction of the blood stream or to immediate encroachment upon the glomerular capillaries — is so well known that my investigations could not possibly add anything new. It appears that less attention has been paid to degenerative changes not associated with visible disease of the vas afferens, in spite of their far greater frequency. The reason, apparently, is that the earlier stages of glomerular atrophy become conspicuous only with special stains. The Lee-Brown stain has proved quite adequate for this purpose and is simple in practice.

Two different forms of glomerular degeneration can be distinguished, a primary and a secondary. Both forms can lead to the same terminal destruction.

PRIMARY (SENILE) DEGENERATION

Axial Increase of Connective Tissue

The primary form consists of a thickening of the connective tissue framework of the glomerular tuft. When the basement membrane and the connective tissue are demonstrated by the Lee-Brown stain, the delicate subepithelial membrane stands out sharply delineated and is not thickened. The central axis of the glomerular lobule, on

* Received for publication December 18, 1934.

the other hand, is more marked, stains a deep blue and shows a blurred outline. Even under low power the lobulation of the glomerulus is accentuated by this broadening of the axial supporting tissue (Fig. 1). The fact that on cross-section the delicate basement membrane can be distinguished clearly from the thickened axis, on which it lies tangentially, proves definitely the separate existence of the latter as a mass of intercapillary connective tissue.

The presence of such a structure has long been denied, but the result of research in normal anatomy leaves no doubt that the glomerular tuft contains fibrillary nucleated connective tissue between the capillaries, in addition to the epithelial cells, the endothelial cells, and the basement membrane (Zimmermann, von Möllendorff and Borst).

In minor degrees of thickening this intercapillary connective tissue shows a fine fibrillary structure, but later becomes homogeneous and hyaline. The broadest masses of hyaline connective tissue are always found in the intraglomerular portion of the hilum. The other glomerular components (epithelium, endothelium and basement membrane) are quite normal. In the overwhelming majority of cases the vasa afferentia and precapillaries likewise are unaffected.

Since such a great number of glomeruli show the changes described above in otherwise normal kidneys, one might be inclined to regard this picture as a variation of the normal. There are, however, great variations of intensity and extent of this process in different kidneys. The degree of thickening and number of altered glomeruli both obviously increase with age. Although some arteriosclerotic and normal kidneys in old subjects show no thickening of the axial connective tissue, this feature was entirely absent in a control series of twenty individuals under 20 years of age. It proved impossible by counting those glomeruli to show any parallelism with any type of vascular change or with high blood pressure, which might possibly exist. Likewise, no relation can apparently be established to passive congestion of the kidney.

Although severe and extensive axial thickening was observed in 2 cases where the individuals were 32 and 45 years of age, nevertheless its greater frequency in older subjects is undoubted. This points to the conclusion that the change described cannot be regarded as a variation of the normal but is an expression of the aging process in the glomerulus.

Since MacCallum in a recent paper pays attention especially to the change of intercapillary connective tissue and states that the main group of such cases occurs in association with cardiac hypertrophy and arterial hypertension, I shall go more into detail in regard to this point.

It is true that the process of thickening of the wall of the vasa afferentia very often tends to enter into the glomerular tufts and that in these cases the secondary degeneration of the glomeruli is due to an increase in intercapillary connective tissue, which in later stages compresses the capillaries. However, it must be emphasized that the causal connection is confined purely to the arteriosclerosis. The relation between arterial hypertension and arteriolar sclerosis still is a question. The object of this paper is to stress the fact that the "axial thickening" is a far more common finding and may very well occur independently of changes in the arterioles. When comparing this change with the heart weight, I found among 46 cases in which I enumerated the glomeruli with thickened connective tissue: (a) 6 cases of severe thickening with a heart weight under 400 gm.; 3 cases of severe thickening with a heart weight over 430 gm.; (b) on the other hand, 7 cases with a heart weight of more than 500 gm. had a degree of axial thickening ranging from zero to about half as much as in the cases of the first group.

It can be definitely stated, then, that this condition is independent of arterial hypertension and cardiac hypertrophy.

MacCallum speaks in these cases of a growth of the mesangium, but my histological examination never revealed any increase of nuclei unless there was an inflammatory process associated with the axial thickening. Because of this I cannot convince myself of an actual axial growth.

Considering the details of the process, one can state that the degeneration in question begins at the hilum where the capillaries branch, and progresses towards the periphery (Fig. 2). While the thickening is frequently confined to the region of the hilum, I have never seen peripheral broadening of the connective tissue in a glomerulus with a normal hilum.

In consequence of this process, collapse of the capillaries occasionally develops. In some rare instances this collapse is confined to one glomerular lobe, of which the axis is definitely thickened, while its subepithelial membrane is still unaffected. One might, then, justifi-

ably assume that the collapse and the axial thickening are closely related. In the later stage of hyalinization, which of course involves the basement membrane, it is impossible to make any such distinction.

It should be mentioned that the thickening of the intercapillary connective tissue can occur also in connection with other processes.

We not infrequently encounter cases in which the intercapillary change is so marked and so extensive that one might be inclined to look upon this disease of the kidney as a characteristic lesion. A later paper will be devoted to a closer study of these kidneys. The axial thickening may develop in amyloid degeneration or subsequent to inflammatory lesions and can be demonstrated in the glomerular destruction which follows primary thickening of the basement membrane. Instances of the latter, however, as we shall see later, are decidedly uncommon. Axial thickening has been mentioned several times in recent papers (MacCallum, Schürmann and MacMahon), although associated with other conditions. It must be emphasized, however, that this lesion in its pure form is exceedingly frequent and independent of changes in tubules and blood vessels; hence it has been termed "primary degeneration."

SECONDARY DEGENERATION

Thickening of the Basement Membrane

This description applies to glomeruli whose basement membrane is thickened (for the most part uniformly) and has a wrinkled appearance. The glomeruli are simplified in structure as a result of atrophy and for this reason are easily recognizable by special stains under low power. These lesions of the glomerulus have been described repeatedly and in excellent detail by McGregor. I shall therefore take her conclusions as a basis for the following considerations.

McGregor introduced the term "hypertensive glomeruli," assuming that a close connection exists between this form of glomerular disease and arterial hypertension. Her investigations failed, however, to shed any light on the pathogenesis of the glomerular lesions. A definite relation to arteriolar sclerosis could not be established, as partial or complete hyalinization of the vessels could be found only at some distance from the glomeruli they supplied. The author

herself was apparently not satisfied with the morphological relationship as the basis of the glomerular lesion.

I have tried to confirm the results that McGregor obtained by counting the hypertensive glomeruli. It can certainly be shown that the number of these "membrane-thickened" glomeruli is considerably increased in kidneys with severe arteriosclerosis. One should, however, regard quantitative observations on histological preparations with more skepticism. In enumerating the glomeruli it is impossible to avoid subjective errors which are present in the "birds-eye view" method of estimation. We are easily led thereby to form an impression with a false sense of certainty. Even if sections are taken from several parts of the kidney the method is still inaccurate owing to topographical variations.

Thus, counting every glomerulus throughout the section, I found a high percentage of so-called hypertensive glomeruli in simple, scarred, atrophic, senile kidneys without any relation to high blood pressure. The difference between McGregor's and my results might possibly be explained by the varying size of the scars in which the hypertensive glomeruli are crowded. I encountered cases in which the so-called hypertensive glomeruli could not be demonstrated anywhere else but in the vicinity of an old scar (Figs. 3 and 4). According to McGregor's own statement, she believes that this glomerular change depends on a circulatory damage. As we shall see later, I agree entirely with this point. I also believe that the thickening of the basement membrane is due to an ischemic process.

I encountered several cases of severe hypertension with moderate arteriosclerosis of the kidney in which only very few glomeruli with thickened basement membrane were present. As is well known, arterio- and arteriolosclerosis are frequently found in association with a previous history of hypertension. This, in my opinion, however, can be interpreted as a coincidental relationship rather than one of cause and effect. Inasmuch as I have found the distribution of the so-called hypertensive glomeruli to be a focal one related to vessel change, and therefore probably caused by ischemia, I prefer the term ischemic glomerulus for this type of change.

Two types of glomeruli with thickened basement membrane can be distinguished. The first is characterized by additional thickening of the capsular membrane with only slight widening of the capsular space, because of atrophy of the glomerular tuft itself. The second

shows definite dilatation of capsular space with no thickening of the capsular membrane. The combination of both these types is possible but the differentiation between them is necessary since the common occurrence of the pure form of either type strongly indicates their different histogenesis.

*Ischemic Atrophy of the Glomerulus with Thickening
of the Capsule*

The majority of the vasa afferentia of this type of glomerulus are normal, although partial hyalinization of the vessel wall may be encountered occasionally, but not constantly, some distance proximally. In view of the inconstance of this finding, it is most improbable that a direct relation exists between this type of glomerular lesion and degeneration of the arteriole or prearteriole. Furthermore, one can practically never recognize with certainty any associated thickening of the axial connective tissue.

It is obvious that the process from the beginning consists of the thickening of epithelial basement membrane, but the change is confined for the most part to the glomerulus and only exceptionally extends to the basement membrane of the tubules. This type of glomerular degeneration has often been noted on account of the associated thickening of the capsule, which is easily demonstrable by the common staining method hematoxylin-eosin and Van Gieson, (Tschistowitsch, Roth, Herxheimer, Fahr and Aschoff). The onset of the process is usually observed at the site of reflecture of the basement membrane of the capsule to the capillary tuft, but may sometimes be particularly marked at the pole opposite to the hilum (Fig. 5). The contributions in the literature are purely descriptive. The mode of development of this special form of glomerular atrophy is still in question.

On the negative side we can first state, contrary to the assumption of most authors, that in all these numerous cases capillary collapse is not the result of mechanical narrowing of the vas afferens. The vessel is intact and very frequently shows passive congestion with dilatation of the lumen (Fig. 6). This of course does not apply to the exceptions mentioned in the introduction.

Two modes of development are to be considered: (1) ascending, due to obstruction of excretion; and (2) primary circulatory damage of low degree.

We can exclude the first mode in the above glomerular degeneration since no dilatation of the capsular space or the corresponding tubules is present, and without this criteria such a conclusion would not be justified.

On the other hand, there is adequate evidence to support the second mode of development. Membrane-thickened glomeruli are aggregated in so-called incomplete infarcts (Fahr), that is, wedge-shaped areas where the glomeruli are crowded between atrophic tubules. Although in hematoxylin-eosin preparations the glomeruli frequently appear normal, the special stains show thickening of the basement membrane. At the apex of such wedge-shaped areas one can as a rule recognize the arteriosclerotic narrowed vessels.

The glomeruli with thickening of the basement membrane and capsule are almost invariably aggregated together, but even if they occur isolated the corresponding tubular apparatus is atrophic (Fig. 7). In a doubtful case, serial sections will reveal the association of the glomerular and tubular atrophy. The tubular basement membrane, however, is rarely thickened, and there is little more than a slight broadening of the loose interstitial connective tissue.

It is, therefore, desirable to discuss the relation of the tubular atrophy to the glomerular change. In the majority of the atrophic scars the obliteration of the glomerulus is considered to be primary, atrophy of the tubules occurring as a secondary process (Fahr, Aschoff, Loehlein, Stoerk, Jores and Herxheimer). Opinions differ, however, as to the mechanism. On the basis of Stoerk's assumption of a vascular unit, that is, of a tubular blood supply via the glomerulus, the tubular atrophy is of circulatory origin. Other authors (Jores, Herxheimer, and others) favor the hypothesis of a disuse atrophy. Aschoff's explanation of the tubular atrophy resulting from excretion of toxins by the glomerulus appears to be only a theoretical possibility.

Certain qualifications are made by Herxheimer and Fahr in special cases, since they pointed out the possibility of a combined atrophy depending on narrowing of the larger vessels, in which case tubular might precede glomerular atrophy.

It has only lately been emphasized by Staemmler that the above possibility is most frequent in arteriosclerotic contracted kidneys. The proof lies essentially in the fact that according to this author the glomeruli are fairly well preserved even when tubular atrophy is very

advanced. The special stains, however, reveal in such areas many glomeruli with a thickened basement membrane. The same holds for smaller areas which contain only a few nephrons.

It is not to be denied that a primary lesion of a vas afferens often enough leads to destruction of the glomerulus and subsequently to atrophy of the tubules. In view of the early changes in the glomerular basement membrane, one gets the impression that the significance of such processes in contraction of the kidney has been overrated. Hyalinization or fatty degeneration of the vas afferens, which in fact leads to narrowing of the lumen with subsequent damage of the glomerulus, in absence of sclerosis of the larger vessels, affords a rare exception. In this respect I disregard the frequent hyalinization of arterioles without change of their lumen. Thus, it is quite immaterial whether the tubules receive their blood supply via the glomeruli or directly (Elze and Dehoff). The essential point is that tubular atrophy is purely circulatory, as is evident from the sequence of events; atrophy of tubular epithelium and thickening of the capsule membrane can often be recognized before any change can be demonstrated in the glomerulus. Furthermore, the microscopic picture leaves no doubt that the process may encroach on the glomerulus from the capsule, especially at the hilum, without involving the vessel at all. It is striking how long the capillary epithelium is preserved.

The fact that the tubular epithelium is much more susceptible to nutritional disturbance than the glomerular capillary apparatus also makes this sequence of events most probable. It has recently been shown in a paper by Maatz that a relatively short constriction of the large renal vessels produces in the first place, and chiefly, tubular atrophy. I believe also that the same explanation applies to the "tubular kidney atrophy" which Baehr produced by injection of iodine, particularly as the vessels showed marked changes.

Finally, we must mention another possible mode of development of atrophic scars described by Fahr and later by Helpap; namely, ascending contraction due to primary sclerosis of the medulla. The histological resemblance of these cases to ascending pyelonephrotic contraction suggested this conception to Fahr. Definite proof, however, is difficult to obtain. Whether we assume with Fahr a collapse of the lower parts of the tubules, or whether we postulate pressure from without, we should expect to find stagnation of secretion with

subsequent ascending dilatation. This, however, usually does not occur.

On the other hand, we know that distention of the pelvis produces ischemia of the kidney. Hinman and Morison have given conclusive experimental illustrations of this. It appears, therefore, that the same mechanism which we postulate in incomplete infarctions might come into play in ascending infection or pyelonephrosis. The histological appearances are in fact extraordinarily similar. Histological differentiation is indeed possible only in the presence of a characteristic distribution of the inflammatory infiltration. The type of contraction is itself identical. Fahr's conception of ascending contraction following primary sclerosis of the medulla is only tenable if sclerosis of the large vessels can be excluded on the one hand, and urinary obstruction, on the other hand, is demonstrable.

Ascending Atrophy

This form of glomerular atrophy with thickening of the basement membrane not infrequently occurs in arteriosclerotic kidneys. Small and large cysts are present in the renal cortex, representing dilated capsular spaces, in which often only a residue of the glomerular tuft can be recognized. Although Beer in 1904 described in detail these small glomerular cysts and stated numerically that 31 per cent of all degenerating glomeruli underwent this cystic change, only scanty information about them is found in the text-books.

In my experience the process, though very frequent, seems to be less common than is claimed by Beer. This author did not take account of the fact that hyalinized glomeruli may disappear completely. This alone invalidates any method of comparative enumeration.

Staemmler and Masugi pointed out, and Moritz and Hayman furnished the experimental proof, that hyalinized glomeruli can disappear without leaving any trace. The basement membrane of the glomerulus in ascending atrophy is usually quite uniformly thickened and wrinkled, but in contrast to the findings in ischemic atrophy (Fig. 8) the capsule largely remains unaffected (Fig. 9). The vas afferens is almost invariably patent and the glomerulus shrinks more and more, although capillaries are wide open and filled with blood. Here, too, surprisingly enough, the epithelial cells are often well preserved to the end and not even flattened in every case. The excessive

dilatation of the capsular space which is filled with coagulum points to a primary obstruction to secretion.

In spite of careful examination, Beer could not find any actual occlusion at the outlet of the capsular space and therefore assumed that constricting bands of connective tissue might lead to obstruction some distance from the glomerulus. Indeed, if we follow these cysts in serial sections we observe that the dilatation need not be confined to the glomerular capsule but sometimes involves one or several loops of the convoluted tubules. Here, in fact, one often finds a band-like increase of connective tissue just where the dilated tubule ends, sometimes rather distant from the glomerulus, showing that passive stagnation of secretion might be verified histologically. I agree with Beer's statement that the picture is often so complicated that a single nephron cannot be traced, especially when, as is frequently the case, the glomerular cysts are grouped together. However, it is in this type of case that reticular, scarring fibrosis is seen to be the cause of stagnation (Fig. 10).

Aschoff's assumption that these cysts are due to a developmental abnormality is most improbable. They indeed resemble the dilatation of the capsular space, which is so frequently found, especially in the outer zone of the cortex of the kidney of young infants, and which undoubtedly is due to malformation. Aschoff believes that such cysts increase in size with age and become particularly visible when the kidney contracts in old age, or as a result of inflammation. This explains why they are relatively rare in kidneys of young individuals without arteriosclerosis and why they seem to be more common in old subjects. In such arteriosclerotic kidneys, however, we see the cysts in all stages of development and it is inconceivable that the capsular dilatation should be preserved from infancy to old age, especially as we know that many glomeruli become obliterated and disappear on account of this process in early childhood (Herxheimer).

Cystic degeneration of the glomeruli, which is beyond doubt caused by stagnation of excretion, frequently is due to scarring processes in the vicinity of the glomeruli. Furthermore, it is conceivable that in primary tubular atrophy the epithelial cells may obstruct the lumen. Cases in which the cysts are accompanied by a thickening of the capsule afford evidence of such a process actually taking place. For we have seen above that thickening of the capsule and atrophy of the tubular epithelial cells are associated together in ischemic

atrophy. This combined picture is frequently encountered in incomplete infarcts and scars (Fig. 11).

CONCLUSIONS

In arteriosclerotic kidneys the following degenerative changes can be recognized in the glomeruli:

1. Primary broadening and hyalinization of the intercapillary axial connective tissue. This very frequent change is interpreted as an aging phenomenon of the glomerulus and may lead to secondary damage to the glomerular capillaries.

2. Thickening of the basement membrane, which is always secondary, may be due to two different causes:

(A) Ischemic atrophy of the glomerulus which may result from:

- (a) Direct encroachment of hyalinization of the vas afferens upon the glomerulus leading to collapse and degeneration of all glomerular elements.

- (b) Narrowing of the larger vessels, producing slow circulatory atrophy of the tubules and glomeruli. This change, the most common in all forms of arteriosclerotic kidneys, is characterized by thickening of the capsule and basement membrane, frequently extending from the former to the latter. This thickening of the capsule is closely associated with atrophy of the tubular epithelium.

(B) Ascending atrophy. This is caused by obstruction of the corresponding tubules and is characterized by the thickening of the capillary basement membrane without thickening of the capsule and is associated with dilatation of the capsular space. This form usually is not observed in pyelogenic ascending contraction. The latter is interpreted mainly as an ischemic process, thereby explaining the fact that in this condition we so frequently encounter a high degree of capsular thickening (*vide* (A) (b)).

Tubular atrophy in arteriosclerotic kidneys is chiefly a circulatory one and essentially depends on changes in medium sized and larger vessels.

NOTE: The author wishes to express his gratitude to the Committee in Aid of Displaced Foreign Physicians and the Rockefeller Foundation for a grant which made possible the above investigation,

and is indebted to Dr. Frederic Parker, Jr., of the Mallory Institute of Pathology for research facilities and for his helpful advice and criticism.

REFERENCES

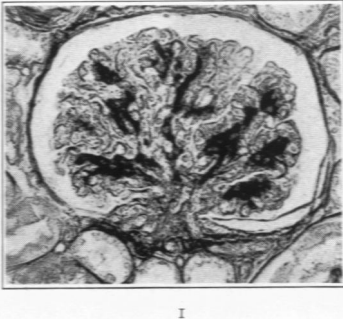
- Aschoff, L. Pathologische Anatomie. G. Fischer, Jena, 1928, Ed. 7, 2.
- Baehr, G. Über experimentelle Glomerulonephritis. *Beitr. z. path. Anat. u. z. allg. Pathol.*, 1912-13, 55, 545-574.
- Beer, E. The occurrence of cystic changes in the Malpighian bodies associated with atrophy of the glomerulus in chronic interstitial nephritis. *Am. J. M. Sc.*, 1904, 127, 611-622.
- Borst, J. G. G. Der Bau des normalen Glomerulus. *Ztschr. f. mikr.-anat. Forsch.*, 1931, 23, 455-483.
- Elze, and Dehoff, E. Über die arteriellen Zufüsse der Kapillaren in der Nierenrinde des Menschen. *Berl. klin. Wchnschr.*, 1919, 56, 213.
- Fahr, Th. Kreislaufstörungen der Niere. Handbuch der speziellen pathologischen Anatomie und Histologie, Henke, F., and Lubarsch, O. J. Springer, Berlin, 1925, 6, 149, 384.
- Helpap, K. Über aufsteigende Schrumpfnieren durch Sklerose des Nierenmarks. *Virchows Arch. f. path. Anat.*, 1933, 288, 383-392.
- Herxheimer, G. Niere und Hypertonie. *Verhandl. d. deutsch. path. Gesellsch.*, 1912, 15, 211.
- Herxheimer, G. Nierenstudien. I. Über die genuine arteriolosklerotische Schrumpfniere. *Beitr. z. path. Anat. u. z. allg. Pathol.*, 1917-18, 64, 297-346.
- Hinman, F., and Morison, D. M. An experimental study of the circulatory changes in hydronephrosis. *Tr. Am. A. Genito-Urin. Surgeons*, 1923, 16, 7-24.
- Jores, L. Über die Beziehungen der Schrumpfnieren zur Herzhypertrophie vom pathologisch-anatomischen Standpunkt. *Deutsches Arch. f. klin. Med.*, 1908, 94, 1-26.
- Jores, L. Warum schreiben wir der Sklerose der Nierenarteriolen eine Bedeutung für das Zustandekommen gewisser Formen von Schrumpfnieren zu? *Virchows Arch. f. path. Anat.*, 1916-17, 223, 233-242.
- Jores, L. Über den pathologischen Umbau von Organen (Metallaxie) und seine Bedeutung für die Auffassung von chronischer Krankheiten u.s.w. *Virchows Arch. f. path. Anat.*, 1916, 221, 14-38.
- Löhlein, M. Über Schrumpfnieren. *Beitr. z. path. Anat. u. z. allg. Pathol.*, 1917, 63, 570-632.
- Maatz, R. Experimentelle tubuläre Schrumpfniere durch vorübergehende Gefäßabklemmung. *Frankfurt. Ztschr. f. Path.*, 1934, 46, 438-445.
- MacCallum, W. G. Glomerular changes in nephritis. *Bull. Johns Hopkins Hosp.*, 1934, 55, 416-432.

- Masugi, M. Über die experimentelle Glomerulonephritis durch das spezifische Antinierenserum. *Beitr. z. path. Anat. u. z. allg. Pathol.*, 1934, **92**, 429-466.
- McGregor, L. Histological changes in the renal glomerulus in essential (primary) hypertension. *Am. J. Path.*, 1930, **6**, 347-366.
- Moritz, A. R., and Hayman, J. M., Jr. The disappearance of glomeruli in chronic kidney disease. *Am. J. Path.*, 1934, **10**, 505-517.
- Roth, E. Ueber Schrumpfnieren ohne Arteriosklerose. *Virchows Arch. f. path. Anat.*, 1907, **188**, 527-550.
- Schürmann, P., and MacMahon, H. E. Die Maligne Nephrosklerose, zugleich ein Beitrag zur Frage der Bedeutung der Blutgewebsschranke. *Virchows Arch. f. path. Anat.*, 1933, **291**, 47-218.
- Staemmler, M. Die Entstehung der arteriosklerotischen Schrumpfniere. *Beitr. z. path. Anat. u. z. allg. Pathol.*, 1930, **85**, 241-250.
- Stoerk, O. Beitrag zur Nierenpathologie. *Verhandl. d. deutsch. path. Gesellsch.*, 1912, **15**, 222-226.
- Tschistowitsch, Th. Die Verödung und hyaline Entartung der Malpighischen Körperchen der Niere. *Virchows Arch. f. path. Anat.*, 1903, **171**, 243-257.
- Von Möllendorff, W. Handbuch der mikroskopischen Anatomie des Menschen. J. Springer, Berlin, 1930, **7**, Pt. 1.
- Zimmermann, K. W. Über den Bau des Glomerulus der menschlichen Niere. *Ztschr. f. mikr.-anat. Forsch.*, 1929, **18**, 520-552.

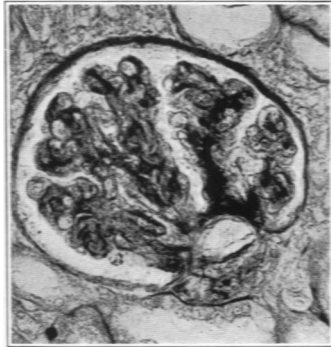DESCRIPTION OF PLATES

PLATE 65

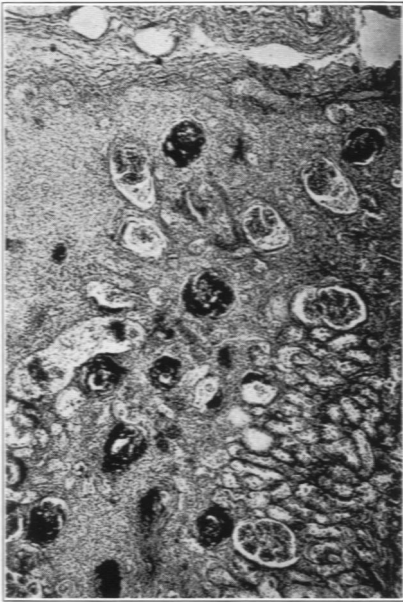
- FIG. 1. Accentuated connective tissue framework of the glomerulus "axial thickening."
- FIG. 2. "Axial thickening" progressing from hilum to periphery.
- FIG. 3. Old scar with hyalinized glomeruli and five so-called "hypertensive glomeruli."
- FIG. 4. Two "hypertensive glomeruli" of the same scar (Fig. 3) in high magnification.
- FIG. 5. Capsular thickening. Process encroaching upon basement membrane. Most of the basement membrane still delicate.
- FIG. 6. Same as Fig. 5. Vas afferens intact and congested.



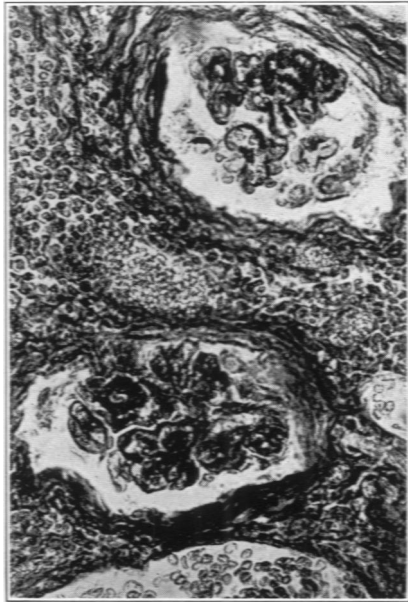1



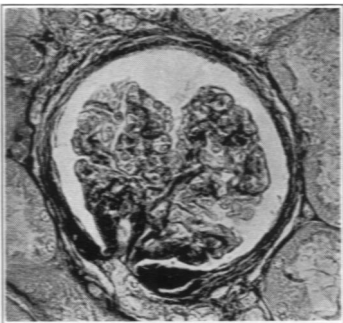
2



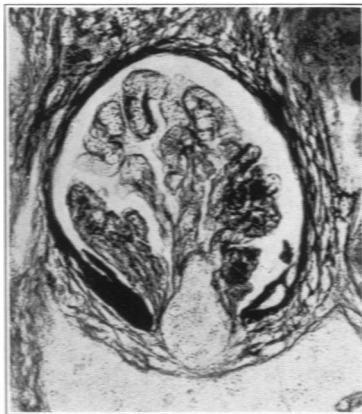3



4



5



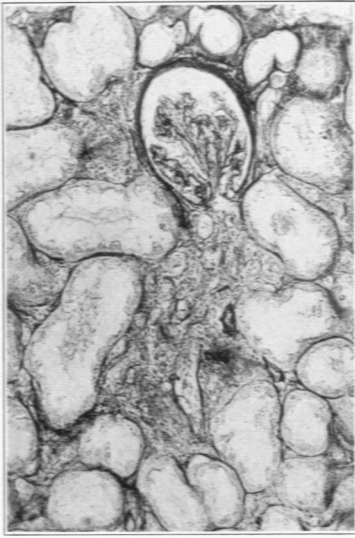
6

Kimmelstiel

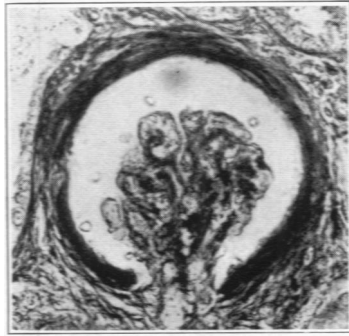Glomerular Changes in Arteriosclerotic Kidney

PLATE 66

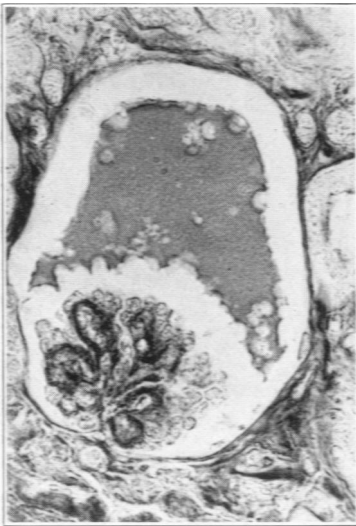
- FIG. 7. Capsular thickening associated with tubular atrophy (membrane of tubules delicate). Basement membrane of glomerulus only slightly thickened.
- FIG. 8. Glomerulus with thickened basement membrane. Widening of the capsular space due to atrophy of the glomerular tuft.
- FIG. 9. Glomerular cyst without capsular thickening.
- FIG. 10. Group of glomerular cysts (without thickening of the capsule). Scar tissue towards the medulla.
- FIG. 11. Scar with combined ascending and ischemic glomerular atrophy.



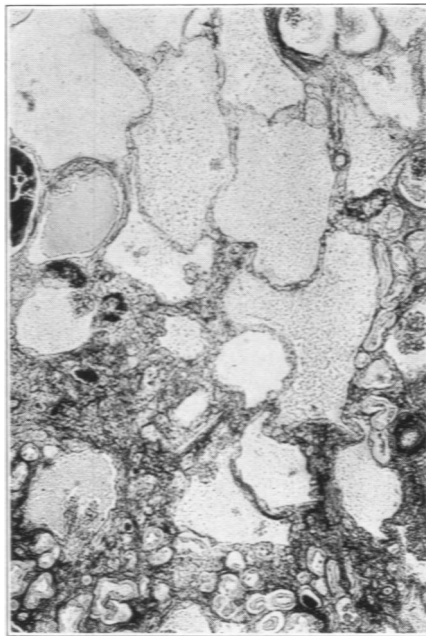
7



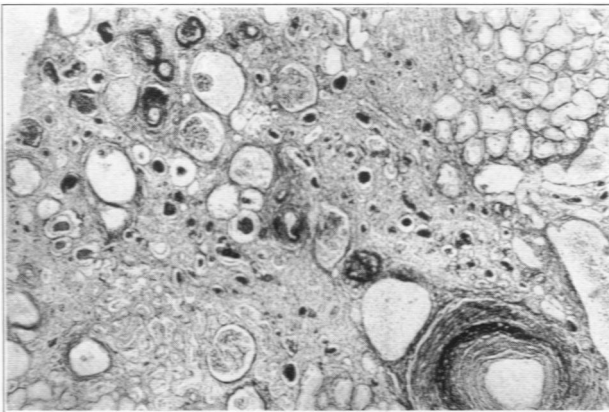
8



9



10



11