

EXPERIMENTAL GASTRIC EROSIONS FOLLOWING HYPOTHALAMIC LESIONS IN MONKEYS *

E. C. HOFF, Ph.D., AND D. SHEEHAN,† M.D.

(From the Laboratory of Physiology, Yale University School of Medicine,
New Haven, Conn.)

INTRODUCTION

Cushing,¹ in his Balfour Lecture, has directed attention to some neurogenic factors involved in acute ulceration of the gastro-intestinal tract. In a comprehensive review of the literature on the subject he points out that the weight of evidence indicates a causal relation between hypothalamic disturbance and certain gastro-intestinal lesions.

Although it had long been suspected that the central nervous system plays a part in the genesis of gastro-intestinal ulceration (Schiff,² and Brown-Séguard³), the experiments of two Russian investigators, Burdenko and Mogilnitzki,⁴ were among the first to provide direct evidence that hypothalamic injury might lead to haemorrhagic ulceration in the stomach and duodenum. Using a subtemporal approach they produced small lesions in the base of the brain immediately behind the infundibular stalk. Gastric haemorrhages and erosions, acute ulceration and occasionally perforation with peritonitis resulted and in some instances, in animals surviving the operation by several months, chronic cicatricial ulceration was found. They explained their results on the basis of a destruction of a vasomotor centre in the posterior hypothalamus and of a metabolic centre in the tuberal region.

Keller, Hare and d'Amour,⁵ in a long series of experiments on cats and dogs in which many and varied types of experimental lesions had been made in the upper brain stem, found that apart from 3 chronic midbrain animals in which erosions occurred in the stomach acute gastro-intestinal changes most commonly followed lesions that had been associated with haemorrhage into the cerebral ventricles, *i.e.* after a transverse section of the brain at the level of the chiasma.

* Received for publication March 26, 1935.

† Rockefeller Fellow.

Multiple erosions of the stomach were encountered in some of the cases after hypothalamic injury. They occurred most frequently in the body of the stomach, rarely in the pylorus, and were most numerous on the crests of the folds.

Watts and Fulton ⁶ have recently reported a series of experiments in monkeys in which localised hypothalamic injury was associated with acute gastro-intestinal changes. Of 17 animals with large hypothalamic lesions 4 developed gastric erosions, 1 died of a perforated duodenal ulcer and several showed mucosal haemorrhage. A careful examination of the gastro-intestinal tract in a control series of 63 animals revealed that gastric erosions were found in only 1 monkey without a hypothalamic injury, and this animal had received daily injections of ephedrin after a midthoracic transection of the spinal cord. Their observations did not permit any conclusions as to the relation between the destruction of any single group of hypothalamic nuclei and the pathological changes in the gastro-intestinal tract. They were inclined to the view that the erosions following lesions in the tuberal and supra-optic regions were due primarily to local ischaemia incident to hyperactivity of the sympathetic vasoconstrictor mechanism of the gut.

As the observations of Watts and Fulton ⁶ were based on relatively long term experiments, they suggested that further studies were needed with earlier sacrifice; the present experiments have been undertaken with this object specifically in view.

METHOD

This report is based on a study of 19 monkeys (11 capuchins, *Cebus fatuellus*, and 8 rhesus, *Macaca mulatta*) in each of which a small lesion was made in the hypothalamus. In order to provide an adequate control series a careful examination was made of the gastro-intestinal tract of all primates sacrificed in this laboratory for a period of 6 months. These (some 50 in all) had been subjected to various operative procedures, including occlusion of the pituitary stalk, spinal cord transection and ablation of certain cortical areas, frontal, premotor and occipital.

Operative Procedure

A subtemporal approach was used throughout this investigation. This method was selected in order to avoid damage to any part of the central nervous system, other than the hypothalamic region, as the animals were also being used for anatomical studies of nerve pathways. All operative procedures were carried out with full aseptic precautions and under sodium amytal anaesthesia.

A large unilateral bone flap extending across the midline was turned down in each case. With the head of the animal placed on its side the temporal lobe was gently retracted upwards from the base of the skull, thereby exposing the optic and oculomotor nerves and the infundibular stalk partially screened by the internal carotid artery. By means of a sharp hooked probe a small lesion was made in a selected part of the hypothalamus, either directly in the tuber cinereum or in the posterior hypothalamic region. An attempt was made to produce a bilateral lesion in every case. Little haemorrhage was encountered, though frequently a small amount of cerebrospinal fluid escaped from the puncture. The temporal lobe was allowed to slip back into position, the bone flap replaced and the wound closed.

During the elevation of the temporal lobe there was often a marked slowing of the heart rate. In the earlier experiments, in order to combat this effect, a small dose (0.3 to 0.5 cc.) of adrenalin was administered subcutaneously at this stage of the procedure, but this was dispensed with in later experiments.

Postoperative Study

Most of the animals survived 3 days and were sacrificed at the end of this period as it was particularly desirable in this investigation to observe the early appearances of any gastric lesions. Two of the animals were sacrificed at the end of 3 weeks and were utilised for Marchi studies. During the postoperative period careful observations were made of the general condition of the animal and the faeces and any vomitus were examined for blood.

At the time of sacrifice the animals were profoundly anaesthetised with ether. The stomach and intestines were isolated from the general circulation, removed and placed in physiological saline for immediate examination. The animal was then injected through the

abdominal aorta with 500 to 1000 cc. of 0.9 per cent saline until clear fluid flowed from the opened inferior vena cava. This was followed by 300 to 500 cc. 10 per cent chloral hydrate solution. The brain and spinal cord were removed at once and a complete autopsy performed.

Histological Technique

The hypothalamus and adjacent brain tissue were removed in one piece and placed in 75 per cent alcohol. Serial Nissl-stained sections were made of the entire block so that the precise localisation of the lesion could be ascertained in each case. The rest of the brain stem and sample blocks from the spinal cord were stained with Cajal's method of reduced silver nitrate impregnation (formula 6a) and serial sections made for examination of degenerated *bouton terminaux* (as described by Hoff ⁷). Any lesions found in the gastrointestinal tract were excised and fixed in neutral formalin solution and sections were stained with haemalum and eosin.

RESULTS

Postoperative Course

The animals showed striking individual variations in the general postoperative condition. Some made a rapid recovery so that within 24 hours their behaviour was apparently entirely normal. Many of the animals, on the other hand, were profoundly affected by the operation. They recovered slowly from the anaesthesia and sat hunched up in the cage with the head lowered between the upper limbs. These animals refused food and invariably their condition became progressively worse, death supervening in 1 to 3 days.

Subsequent histological examination of the base of the brain revealed nothing in the location or extent of the lesion that would account for the marked difference in postoperative recovery. Thus, in Experiment 7, in which serial sections of the hypothalamus showed a bilateral lesion that had destroyed the tuber cinereum, opened up the base of the third ventricle and had all but severed the infundibular stalk, the animal was active and feeding several hours after completion of the operation. It continued to improve so that on the following morning its general behaviour and activity were indistinguishable from those of an unoperated animal. Sacrifice 3

days after the operation revealed no abnormality in the gastro-intestinal tract. Contrasting remarkably with this case was the postoperative course in Experiment 5 in which the lesion in the hypothalamus was non-haemorrhagic and identical with that produced in Experiment 7. Yet the animal went steadily downhill and died within 24 hours of the operation. Autopsy in this case revealed multiple mucosal erosions in the body of the stomach. It would appear from our experiments that extensive gastro-intestinal lesions may alter very rapidly the postoperative course of these animals, quite apart from the nature of the hypothalamic lesion produced.

In only 1 case was haemorrhagic vomitus observed. In Experiment 11, which subsequently showed a destructive lesion in the dorsal part of the tuber cinereum, the animal remained prostrate for 24 hours after the operation. Twenty hours after the lesion had been made the monkey began to vomit a clear mucous fluid mixed with clots of coffee-coloured blood. During the next few hours the animal recovered slightly but continued to vomit blood at intervals, and death occurred within 48 hours of operation. At autopsy multiple haemorrhagic erosions were found in the body of the stomach.

A marked polydipsia following operation was observed in several instances but as the animals were being sacrificed at the end of 3 days no reliable measurements of the daily fluid intake and output were obtained.

Occurrence of Gastric Erosions

Three of the 19 animals died while the lesion was being made. Of the 16 that survived the operation 5 animals showed acute mucosal erosions in the stomach. Two of these survived a 3 day postoperative period, although exhibiting a marked disinclination to eat and a general sluggishness in movements. The remaining 3 of the group showing gastric erosions at autopsy died, 2 within 1 day and 1 in 2 days, each after a stormy postoperative course.

In all of the cases the erosions were confined to the body of the stomach, both the anterior and posterior wall. Sometimes the pyloric region was also involved but there was no evident predilection for this part, or for the lesser curvature of the stomach. The erosions were always multiple and haemorrhagic (Fig. 1) and there were often clots of dark blood intermingled with the gastric contents, definitely establishing the ante mortem nature of such lesions. Some

of the erosions were 5 mm. by 5 mm. and showed a punched-out appearance with slightly raised margins and a haemorrhagic base (Fig. 2), but all were evidently of very recent origin. Microscopical examination revealed that the lesions were all confined to the mucosa and in no case was the muscular layer involved. The histological picture was one of sharply localised destruction of the mucosa with haemorrhagic exudate and no evidence of thrombosis in the sub-mucosal vessels underlying the lesion.

In three of the five experiments in which gastric erosions were present the stomachs of the animals showed considerable dilatation and atony on opening the abdomen. In another animal, in which the lesion had involved the posterior hypothalamic region and yet showed no pathological changes in the gastro-intestinal tract, a similar condition of the stomach was observed at autopsy. This marked dilatation of the stomach might conceivably be attributed to sympathetic hyperactivity. However, we have since seen similar very dilated stomachs in several animals sacrificed after various kinds of cerebral but non-hypothalamic operations, and its significance is therefore not entirely clear.

In the control series of over 50 animals subjected to many types of non-hypothalamic cerebral lesions and sacrificed in this laboratory during the past 6 months, careful postmortem examination of the gastro-intestinal tracts has revealed only 1 case with gastric or duodenal ulceration. This animal was a young capuchin in which the right and left motor and premotor areas had been extirpated 5 months previously. Five weeks before autopsy a transection of the spinal cord at the sixth thoracic level had been performed and 12 days prior to sacrifice the left posterior quadrant of the spinal cord had been divided at the third cervical level. At autopsy the stomach showed three small haemorrhagic erosions, one close to the oesophageal orifice and two in the pyloric end. The contents of the stomach were mucous and mixed with small particles of black blood. The small and large intestine were normal.

This case, in which interruption of sympathetic or parasympathetic pathways from higher centres undoubtedly played a significant rôle in the development of the gastric erosions, stands out as an isolated example from a large series of monkeys that had been subjected to many and varied types of non-hypothalamic cerebral injury and revealed no gastro-intestinal pathology at autopsy. The

consistently negative findings in the long control series of experiments continued from Watts' and Fulton's investigation, lend greater significance to the association of gastro-intestinal lesions with injury to the hypothalamus or interruption of its descending autonomic pathways.

We were impressed at autopsy of primate material with the frequent finding in the large and small bowel, and in one instance in the mucosa of the stomach, of lesions of parasitic origin which often closely simulated chronic peptic ulceration, and it was sometimes necessary to resort to histological methods in order to differentiate the conditions. Tuberculous ulceration of the intestine was also encountered in several instances, but it would seem that true peptic ulceration is a very rare occurrence in normal monkeys.

Site of Lesions in the Hypothalamus

Serial sections showed that in most of the cases the lesions had been made in the tuber cinereum. In 3 cases the posterior hypothalamic region only had been damaged, and in 1 case the lesion had destroyed the supra-optic nucleus on one side. The pre-optic region was never involved.

Of the 5 animals showing well marked gastric erosions at autopsy, all showed lesions confined to the infundibulum or to the grey matter immediately dorsal to it, in which lie the nucleus hypothalamicus periventricularis (anterior and posterior) and nucleus hypothalamicus ventro-medialis* of Papez and Aronson.⁸ The nuclei tuberis lateralis were destroyed in all 5 cases, and in 2 animals there was considerable involvement of the pars tuberalis of the pituitary body, which in the monkey wraps round the base of the infundibular stalk and is in part embedded in the substance of the tuber cinereum. In none of the 5 cases did the lesion encroach upon the nucleus paraventricularis, nor was the nucleus mammillo-infundibularis (hypothalamicus lateralis of Papez and Aronson⁸) involved to any extent. In only 1 of the 5 was the track of the lesion haemorrhagic, and in all 5 cases the base of the third ventricle had been opened.

The precise localisation of the lesion in the 5 cases showing gastric erosions can be summarised briefly as follows.

* The ventral or "principal" nucleus of the tuber cinereum.

EXPERIMENT 4. *Operation January 19, 1934; Slow Postoperative Recovery; Disinclination to Eat; Sacrifice 3 Days Later; Three Small Ulcers in the Body of the Stomach*

Brain Lesion: In sections through the optic chiasma the supra-optic and paraventricular nuclei on each side contained many "shadow" cells, pale and partly disintegrating, and there was a fairly extensive gliosis present. In more caudally placed sections the oral part of the tuber cinereum appeared intact and there was no haemorrhage to be seen. At the point of origin of the infundibular stalk the base of the third ventricle was widely opened from below, the stalk apparently having been separated completely from the base of the brain by the injury. There was no evidence of haemorrhage anywhere. The track of the lesion could not be traced, owing to the destructive nature of the injury, but it appeared to have been uniformly bilateral and the tuber cinereum, including the nucleus tuberis on each side, had been completely destroyed. The posterior hypothalamic region and corpora mammillare were intact.

EXPERIMENT 5. *Operation January 26, 1934; Death on the Following Day; Multiple Gastric Erosions*

Brain Lesion: The track of the lesion could be seen entering the tuber cinereum from the right side, immediately rostral to the base of the infundibular stalk. There was very extensive destruction of the tuberal tissue at this point and the base of the third ventricle was opened. The lesion passed across to the opposite side, but was much more extensive on the right. There was no haemorrhage to be seen in any of the sections. The injury was confined to the nucleus tuberis and the grey matter in the floor of the third ventricle in the immediate vicinity of the tuber cinereum. The supra-optic, paraventricular and mammillo-infundibular nuclei were not involved and the posterior hypothalamic region was intact.

EXPERIMENT 9. *Operation February 5, 1934; Death on the Following Day; Large Dilated Stomach with Multiple Mucosal Erosions*

Brain Lesion: The track of a circumscribed haemorrhagic lesion could be traced, entering the lateral aspect of the tuber cinereum from the left side, just rostral to the commencement of the pituitary stalk. The base of the third ventricle was opened and there was

considerable damage to the right lateral wall. A clot of blood overlapping the optic chiasma extended backwards on each side of the infundibular stalk. There was also a small haemorrhage in the cavity of the third ventricle, around the lacerated right lateral wall. The damage was confined to the tuber cinereum bilaterally and involved the pars tuberalis of the hypophysis. The supra-optic, paraventricular and posterior hypothalamic nuclei were intact.

EXPERIMENT 11. *Operation February 8, 1934; Death Within 48 Hours; Dilated Atonic Stomach with Multiple Mucosal Erosions*

Brain Lesion: The lesion was very similar to that in Experiment 9, but had been placed more dorsally. The instrument had entered the hypothalamus on the right side above the tuber cinereum and had pierced the right lateral wall of the third ventricle without much involvement of the opposite side. There was considerable tissue destruction but no demonstrable haemorrhage along the track of the lesion. The grey matter in the floor of the third ventricle, comprising the nuclei hypothalamicus periventricularis et ventro-medialis, had been extensively destroyed but the origin of the pituitary stalk was relatively intact. The nucleus mammillo-infundibularis on the right side was damaged but the rest of the hypothalamic nuclei were uninvolved.

EXPERIMENT 15. *Operation February 26, 1934; Good Postoperative Recovery; Polydipsia and Disinclination to Eat; Sacrifice 3 Days Later; Multiple Haemorrhagic Erosions in the Body of the Stomach*

Brain Lesion: The lesion was entirely unilateral and confined to the oral parts of the tuberal region. The supra-optic nucleus and the nuclei hypothalamicus periventricularis et ventro-medialis on the left side had been damaged; there was no involvement of the mammillo-infundibular nucleus or the posterior hypothalamic region. No evidence of haemorrhage could be seen in any of the sections.

DISCUSSION

Positive evidence is brought forward here to show that in monkeys histologically verified lesions, *confined to the tuberal nuclei*, leaving all other hypothalamic nuclei intact, may lead to haematemeses and

multiple mucosal erosions in the body of the stomach. Several other cases with brain lesions, identical in localisation and extent, were unassociated with any recognisable gastro-intestinal pathology. It would appear that an irritative process caused by haemorrhage at the site of the hypothalamic injury is not a deciding factor in the production of gastric erosions, since such haemorrhage in the hypothalamus occurred in only 1 out of the 5 cases showing erosions, and since several cases with extensive haemorrhagic lesions revealed no evidences of pathology in the gastro-intestinal tract. In three experiments in this series with lesions confined to the posterior hypothalamic region, at autopsy no erosions were found in the stomach, but the cases are too few to warrant any statement regarding the relation of the posterior hypothalamic nuclei to gastric ulcer.

In the series of Watts and Fulton⁶ the injury in most cases involved the tuberal, supra-optic and paraventricular nuclei and, as in our series, no case of gastric erosions was encountered in association with posterior hypothalamic injury. In the experiments of Burdenko and Mogilnitzki⁴ the injury was made immediately behind the infundibular stalk, and in those of Keller, Hare and d'Amour⁵ at the level of the optic chiasma. The association of tuberal lesions with gastro-intestinal ulceration seems therefore established.

Two interpretations have been advanced in the consideration of the neurogenic factor in the genesis of experimental gastric ulcer, one based on a conception of sympathetic hyperactivity, the other explaining the phenomena on grounds of parasympathetic hyperactivity.

(1) *Sympathetic Hyperactivity*

The Peripheral Mechanism: According to this view the sequence of events which leads to the production of gastric ulceration is believed to be overactivity of the sympathetic vasoconstrictors, spasm of the terminal vessels in the submucosa of the gastro-intestinal tract, with the production of multiple areas of ischaemia in the mucosa and digestion of the necrosed tissue by the acid gastric secretions, leaving small punched-out erosions.

The Central Mechanism: In order to explain on the basis of this theory the association of erosions with hypothalamic injury, it is

necessary to consider either a "release" or an "irritation" of the sympathetic centres in the hypothalamus. The development of erosions within 24 hours of the brain injury can be interpreted equally well on the basis of an irritative or of a release mechanism, either of which can be assumed to exist immediately following the injury. It is, however, rather difficult to understand how the small lesions in the present series, which were confined to the tuberal nuclei, could have interrupted any great number of inhibitory fibres from higher centres.

(2) *Parasympathetic Overactivity*

The Peripheral Mechanism: Cushing¹ has summarised the possible mechanism by which hyperactivity of the parasympathetic apparatus may act in the production of gastric ulceration as follows: "Direct stimulation of the tuber or of its descending fibre tracts, or what theoretically amounts to the same thing, a functional release of the vagus from paralysis of the antagonistic sympathetic fibres, leads to hypersecretion, hyperchlorhydria, hypermotility and hypertonicity especially marked in the pyloric segment. By the spasmodic contractions of the musculature, possibly supplemented by accompanying local spasms of the terminal blood vessels, small areas of ischaemia or haemorrhagic infarction are produced, leaving the overlying mucosa exposed to the digestive effects of its own hyperacid juices."

The Central Mechanism: Hypothalamic lesions may lead to overactivity of the parasympathetic system either by direct destruction of the sympathetic centres, thus releasing the vagus from the antagonistic sympathetic activity, or by irritation of parasympathetic pathways in this part of the brain. Beattie and Sheehan⁹ showed that faradic stimulation of the anterior part of the hypothalamus in the fasting cat resulted in parasympathetic phenomena, *i.e.* in a rise of intragastric pressure which was followed by an increase of peristaltic movements of the stomach.

The lesions associated with gastric erosions in the present series of experiments were confined to the tuberal nuclei and it is difficult to see how they could have caused any marked destruction of the sympathetic centres which extend backwards into the posterior hypothalamic region. If the anterior hypothalamic region can be assumed tentatively as the location of parasympathetic discharge (Cushing,¹

Beattie¹⁰), then the evidence here is suggestive of an irritation of such parasympathetic pathways as the underlying mechanism, since all the lesions were small and superficial in extent. Functional localization in the hypothalamus is however not sufficiently clarified to warrant any final conclusion from the present study as to the exact mechanism involved. A study of the experimental production of gastric ulcer following *peripheral* nerve lesions shows that splanchnotomy is by far a more frequent cause than vagotomy (Cushing¹) although vagal section has led to acute ulceration in the stomach and duodenum in some cases (Ferguson¹¹).

We have attempted to throw more light on the question by a pharmacological approach to the problem. For this purpose monkeys (*Macaca mulatta*) have been subjected to repeated subcutaneous injections of (a) acetyl- β -methylcholine chloride in amounts of 25 to 50 mg. per kg. body weight, or (b) adrenalin 0.5 cc. of a 1:1000 solution per kg., or (c) adrenalin 1.5 cc. of a 1:1000 solution per kg., with atropine 20 mg. per kg., or (d) pituitrin (surgical) 1 to 3 cc. (The injections of pituitrin were given in view of Dodds, Noble and Smith's¹² recent findings in rabbits.) The doses were given in each experiment every 2 to 3 hours for periods of 3 to 7 days. In no case were there observed at autopsy any erosions of the gastric mucosa comparable to the results obtained from hypothalamic injury. Although these negative findings cannot be accepted as conclusive evidence, and the cases are too few in number, nevertheless they indicate that states of profound overactivity of the sympathetic or of the parasympathetic system may exist for comparatively prolonged periods without the appearance of gastric erosions.

In considering the neurogenic influences in the production of gastro-intestinal lesions it must not be lost sight of that a vasomotor disturbance is only one of many factors that undoubtedly plays an important rôle. The motility of the gastro-intestinal tract and the amount and nature of the digestive juices are under the direct influence of the central nervous system. The influence of the vagus nerve on gastro-intestinal motility is usually looked upon as due to an augmentation of peristalsis and an inhibition of sphincteric action, while the sympathetic innervation to the gut is considered to act in an antagonistic manner. McSwiney¹³ considers, however, that it is possible to postulate the presence of motor and inhibitory fibres to the stomach in both the vagus and sympathetic nerves, and

that the immediate effects of vagotomy and splanchnotomy are similar, namely retardation of function. It is highly probable therefore that there is no real fundamental opposition in the two views that have been advanced to account for the occurrence of gastrointestinal lesions of nervous origin, and that the explanation may lie in a complex imbalance between the sympathetic and parasympathetic systems.

SUMMARY AND CONCLUSIONS

1. In 16 monkeys, following hypothalamic injury, 5 animals showed multiple haemorrhagic erosions in the mucosa of the body of the stomach.

2. The animals showed striking individual variations in the general postoperative condition. Those with gastro-intestinal lesions showed a disinclination to eat, their condition became progressively worse, and in three experiments death supervened in 24 to 48 hours.

3. In all of the cases the erosions were confined to the stomach, none occurring in the duodenum. The erosions were multiple and haemorrhagic, entirely confined to the mucosa, and some showed a punched-out appearance.

4. In three of the five experiments in which gastric erosions were present the stomachs showed considerable dilatation and atony, suggestive but not conclusive evidence of sympathetic activity.

5. Histological examination of the hypothalamic injuries revealed that in all the animals showing gastric erosions at autopsy the lesions were small and confined to the tuberal nuclei. In only 1 of the 5 was the track of the injury haemorrhagic. Positive evidence is therefore advanced to show that histologically verified lesions, confined to the tuberal nuclei and leaving all other hypothalamic nuclei intact, may lead to haematemesis and multiple mucosal erosions in the body of the stomach.

6. In a control series of over 50 monkeys subjected to many and varied types of non-hypothalamic cerebral lesions careful autopsy examination of the gastro-intestinal tracts revealed only 1 case with gastric or duodenal ulceration, and this animal had been subjected to a bilateral motor and premotor extirpation 5 months prior to sacrifice and to transections of the spinal cord at the sixth thoracic and third cervical levels 5 weeks and 12 days (respectively) before autopsy. The consistently negative findings in the control experi-

ments would appear to lend greater significance to the association of gastro-intestinal lesions with injury to the hypothalamus or interruption of descending autonomic pathways.

REFERENCES

1. Cushing, H. Peptic ulcers and the interbrain. *Surg. Gynec. & Obst.*, 1932, **55**, 1-34.
2. Schiff, M. Leçons sur la physiologie de la digestion. Florence, Turin, Paris, Berlin. 1867, **2**, leçon, 35, 416-452.
3. Brown-Séquard, C. E. Des altérations qui surviennent dans la muqueuse de l'estomac, consécutivement aux lésions cérébrales. *Progrès méd.*, 1876, **4**, 136-137.
4. Burdenko, N., and Mogilnitzki, B. Zur Pathogenese einiger Formen des runden Magen-Darmgeschwürs. *Ztschr. f. d. ges. Neurol. u. Psychiat.*, 1926, **103**, 42-62.
5. Keller, A. D., Hare, W. K., and d'Amour, M. C. Ulceration in digestive tract following experimental lesions in brain-stem. *Proc. Soc. Exper. Biol. & Med.*, 1933, **30**, 772-775.
6. Watts, J. W., and Fulton, J. F. The effect of lesions of the hypothalamus upon the gastro-intestinal tract and heart in monkeys. *Ann. Surg.*, 1935, **101**, 363-372.
7. Hoff, E. C. Central nerve terminals in the mammalian spinal cord and their examination by experimental degeneration. *Proc. Roy. Soc. London*, 1932, Ser. B, **111**, 175-188.
8. Papez, J. W., and Aronson, L. R. Thalamic nuclei of *Pithecus (Macacus) rhesus*. *Arch. Neurol. & Psychiat.*, 1934, **32**, 1-26.
9. Beattie, J., and Sheehan, D. The effects of hypothalamic stimulation on gastric motility. *J. Physiol.*, 1934, **81**, 218-227.
10. Beattie, J. The relation of the tuber cinereum to gastric and cardiac functions. *Canad. M. A. J.*, 1932, **26**, 278.
11. Ferguson, J. Observations on the effects of vagotomy upon the gastric functions of the green monkey. 1935 (in press).
12. Dodds, E. C., Noble, R. L., and Smith, E. R. A gastric lesion produced by an extract of the pituitary gland. *Lancet*, 1934, **2**, 918-919.
13. McSwiney, A. Innervation of the stomach. *Physiol. Rev.*, 1931, **11**, 478-512.

DESCRIPTION OF PLATES

PLATE 113

FIG. 1. Drawing to show the naked eye appearance of the mucosal surface of the stomach when first opened. The erosions are multiple and haemorrhagic. (Experiment 9. Capuchin. Death within 24 hours after a hypothalamic lesion in the tuber cinereum.)

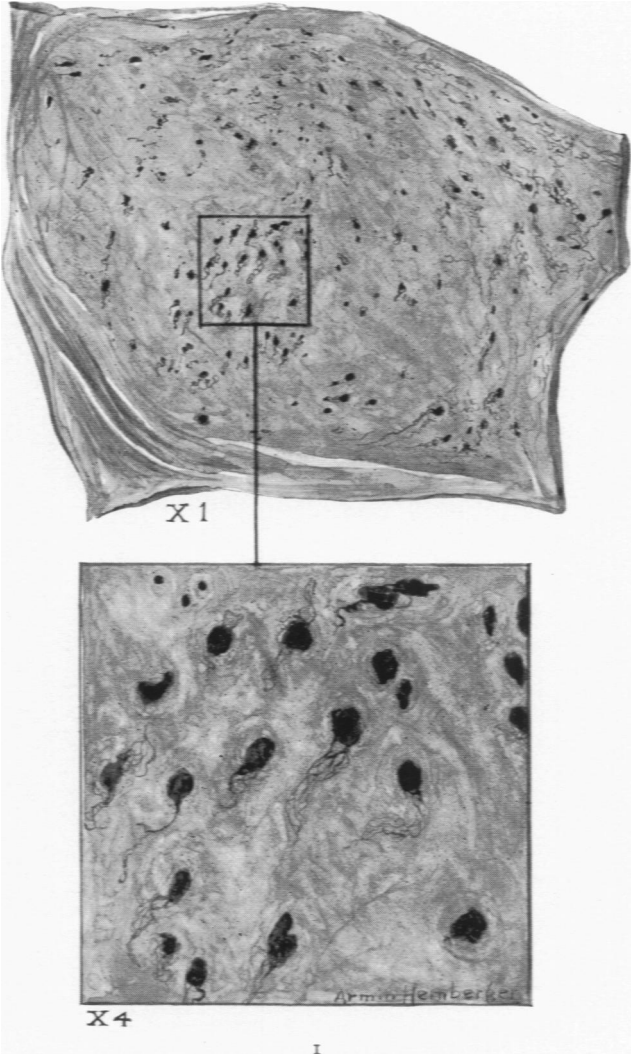


PLATE 114

FIG. 2. Drawing to show the punched-out appearance of the gastric erosions, the bases of which are haemorrhagic. All were of recent origin and occurred chiefly on the dorsal wall of the stomach, extending from the oesophageal opening to about 2 cm. from the gastroduodenal junction. (Experiment 5. Capuchin. Death within 24 hours after a hypothalamic lesion confined to the tuberal nuclei.)

