

## SULFATED MUCOPOLYSACCHARIDE IN FIBRINOID GLOMERULAR OCCLUSIONS OF THE GENERALIZED SHWARTZMAN REACTION

ROBERT G. HORN, M.D., AND S. S. SPICER, M.D.

*From the Laboratory of Experimental Pathology,  
National Institute of Arthritis and Metabolic Diseases,  
National Institutes of Health, Public Health Service,  
Bethesda, Md.*

The generalized Shwartzman reaction may be defined as a pathologic entity produced by sequential, appropriately spaced injections of bacterial endotoxin and characterized by fibrinoid occlusion of glomerular capillaries. Following the observation of Stetson and Good<sup>1</sup> that nitrogen mustard-induced leukopenia prevented the local Shwartzman reaction, Thomas and Good demonstrated that such a leukopenia also prevented the generalized Shwartzman reaction,<sup>2</sup> implicating the leukocyte in the pathogenesis of the fibrinoid deposits.

Thomas, Brunson and Smith<sup>3</sup> later observed that a small amount of any one of several synthetic acid polymers, given in association with a single injection of endotoxin, resulted in a lesion morphologically identical with that of the generalized Shwartzman reaction. The lesions produced by the combination of acid polymer and endotoxin occurred independently of leukocytes, and the acid polymer seemed to substitute for the uncertain but apparently necessary role of the leukocytes in the lesion produced by sequential injections of endotoxin. These observations led them to speculate that the leukocyte might provide in some way a substance with the properties of a large molecular weight acidic polymer which would then react with partially polymerized fibrinogen, leading to the production of an insoluble acid polymer-fibrinogen complex, the fibrinoid.<sup>4</sup> This hypothesis was perhaps weakened by the apparent lack of a well-defined physiologic counterpart of the hypothetical acid polymer.

Recent work in this laboratory<sup>5</sup> has provided evidence that azurophil granules of rabbit heterophil leukocytes contain a sulfated mucopolysaccharide, a substance which would presumably have the characteristics of a large molecular weight acidic polymer. The same granules also appeared to contain an arginine-rich basic protein which could be selectively stained by the acidic dye, Biebrich scarlet. It was further observed that during the periods of leukocytosis accompanying production of the generalized Shwartzman reaction such acid mucopoly-

saccharide-containing granules were greatly increased in circulating heterophil granulocytes.<sup>6</sup> The sulfated mucopolysaccharide in azurophil granules of heterophils circulating after endotoxin seemed to be the possible physiologic counterpart of the acidic substance postulated by Thomas and co-workers. This paper reports the results of histochemical, autoradiographic, and histologic studies which suggest that a sulfated mucopolysaccharide, possibly of leukocytic origin, is a component of the fibrinoid thrombi of the generalized Shwartzman reaction.

### MATERIAL AND METHODS

*Animals.* NIH stock albino rabbits of either sex, weighing approximately 1 kg were used.

*Endotoxin.* *Salmonella enteritidis* lipopolysaccharide, control #123497 (Difco Laboratories, Detroit, Mich.), was suspended in normal saline, 100  $\mu$ g per cc, shortly prior to injection. The generalized Shwartzman reaction was regularly produced in a majority of animals by the administration of sequential 1 cc endotoxin injections via the marginal ear vein at a 21-hour interval.

*Isotope.* S<sup>35</sup>-sulfate, carrier-free, obtained from Oak Ridge National Laboratories (Oak Ridge, Tenn.), was diluted in normal saline (1 mc in 1.0 or 2.0 cc). Intraperitoneal injections of 1 mc were given according to schedules described below. In some instances total plasma radioactivity was estimated in a gas flow proportional counter using standard techniques.

*Histologic and Histochemical Procedures.* Tissues from normal and endotoxin-treated animals were fixed 18 hours in 2 per cent calcium acetate, 10 per cent formalin, followed by dehydration, paraffin embedding and sectioning at 5  $\mu$ . Fibrin clots were prepared by the recalcification of both platelet-rich and platelet-poor plasma, obtained from oxalated cardiac blood of normal rabbits. A 4 per cent aqueous suspension of fibrinogen (bovine, fraction 1 from plasma, Armour Pharmaceutical Co., Kankakee, Ill.) was coagulated by the addition of a large excess of 10 per cent formalin. In each instance the coagulum was pelletized by centrifugation and subsequently processed as tissue for histochemical procedures. Periodic acid-Schiff (PAS), aldehyde fuchsin, high iron diamine and Biebrich scarlet staining was performed as described previously.<sup>6</sup>

Trypsin digestion involved incubation of deparaffinized sections for 1 to 6 hours at 37°C in a solution of 0.05 per cent trypsin (crystalline, lot #521569, Fisher Chemical Co., U.S.A.) in M/20 Na<sub>2</sub>HPO<sub>4</sub> at pH 8.8 to 9.0. Control sections were incubated in buffer alone, and control and digested sections were stained simultaneously.

Methylation of tissue sections, a procedure which hydrolyzes ester sulfate groups of sulfomucins, was performed as described elsewhere.<sup>7</sup>

*Autoradiography.* Autoradiographs of ethanol-fixed, aldehyde fuchsin-stained blood smears and PAS-stained tissue sections were prepared with AR-10 stripping film and processed as described previously.<sup>5</sup> Prestaining of the tissues allowed a direct comparison of silver grains in the overlying emulsion with the aldehyde fuchsin-positive leukocyte granules or with the PAS-reactive fibrinoid. Multiple autoradiographs of each specimen were prepared. Autoradiographs were evaluated blindly by one or both of us. No quantitation was attempted, but the estimated uptake in sites in question was graded from negligible to weak, moderate, or strongly positive.

### RESULTS

#### *Histochemical Findings*

The presence of a derivative of fibrinogen in the glomerular thrombi of the Shwartzman reaction has been well established,<sup>8</sup> but there is little

histochemical evidence concerning a possible acid mucopolysaccharide constituent in this material. However, it has been suggested that fibrinoid lesions of connective tissue in a variety of diseases may contain an acid mucopolysaccharide.<sup>9</sup> The relatively strong PAS-reactivity of glomerular fibrinoid is consistent with the presence of such an entity, but this method and others employed generally lack specificity for acid mucopolysaccharides.<sup>10</sup>

Two methods which have been extensively studied in this laboratory and found to be quite specific for acid mucopolysaccharides, especially sulfated mucosubstances, are the aldehyde fuchsin stain of Gomori<sup>11</sup> and the high iron diamine method.<sup>6,12</sup> In sections of Shwartzman reaction kidney fibrinoid exhibited insignificant or very weak staining with high iron diamine and weak to moderate staining with aldehyde fuchsin. The efficacy of these methods, however, probably depends largely on the presence of free acid groups, and the proximity of such acid groups to basic protein might obscure acid sites. Since it was hypothesized that the fibrinoid might be the product of a condensation of an acid mucopolysaccharide with altered fibrinogen,<sup>4</sup> a relatively basic protein, the possibility was considered that in this instance associated protein might be masking the affinity of the acid mucopolysaccharide for the stains. Therefore, trypsin digestion of tissue sections prior to staining was employed to hydrolyze the protein constituent of the fibrinoid. Comparison of tissue sections incubated in trypsin solution with sections incubated in buffer alone revealed that following proteolysis there was enhanced staining of fibrinoid by both the aldehyde fuchsin and the high iron diamine methods (Figs. 1 to 4). This enhancement was somewhat variable in extent and rate of development, but it was usually appreciable after 1 to 2 hours in trypsin and maximal after 3 to 4 hours. In contrast to the basophilia of the fibrinoid, fibrin clots obtained from normal animals and embedded in the same block with the Shwartzman reaction kidneys showed no significant initial basophilia and no enhanced affinity for aldehyde fuchsin following proteolysis. Coagulated bovine fibrinogen also failed to exhibit basophilia in similar experiments.

A moderately heavy non-specific staining of many tissues with aldehyde fuchsin may occur, particularly if the staining procedure is excessively prolonged. Following trypsin digestion this "background" staining was diminished. Moreover, the basophilia of sites known to contain sulfated mucopolysaccharide was either unimpaired or decreased, and, with the exception of the fibrinoid, no enhancement of aldehyde fuchsin staining was observed in tissues from a variety of sites.

Azurophil granules of infiltrating leukocytes in these formalin-fixed tissue sections were not stained by aldehyde fuchsin, but they were well stained by the high iron diamine method (Fig. 4). Both methods stain

the granules when ethanol-fixed blood smears are used<sup>6</sup>; the reason for the differing staining characteristics of the granules following formalin fixation is not known.

### *Autoradiographic Findings*

S<sup>35</sup>-sulfate is incorporated during the synthesis of sulfated mucopolysaccharides,<sup>13</sup> and the isotope may be localized in tissues by autoradiography. Since the histochemical methods indicated that sulfated mucopolysaccharide might be present in fibrinoid, tracer doses of S<sup>35</sup>-sulfate were administered at various times during production of the generalized Shwartzman reaction, and autoradiographs of kidney sections were prepared and examined for evidence of localization of the isotope in the fibrinoid. From the same animals autoradiographs of blood smears, taken 12 hours after the preparative endotoxin injection and 6 and 12 hours after the second endotoxin injection, were examined for uptake of S<sup>35</sup>-sulfate by azurophil granule-containing leukocytes. Evidence has been presented<sup>5,6</sup> that the isotope is incorporated by leukocytes into the acid mucopolysaccharide of the azurophil granule. Some of the present data concerning isotopic labeling of leukocytes has been reported previously.<sup>6</sup> The results of the experiments described below are summarized in Table I.

TABLE I  
CORRELATION OF S<sup>35</sup>-SULFATE LABELING OF AZUROPHIL GRANULE-CONTAINING LEUKOCYTES WITH LABELING OF FIBRINOID \*

Group	S <sup>35</sup> -Sulfate (1 mc) given	Heterophil label			Generalized Shwartzman reaction	Fibrinoid label
		After 1st endotoxin	After 2nd endotoxin			
		12 hrs	6 hrs	12 hrs		
1	4, 3, and 2 days before first endotoxin	3/3			2/3	0/2
2	With first endotoxin	0/13	11/13	11/11	10/13	10/10
3	With second endotoxin		1/9	7/9 †	6/9	4/6 †

\* Fraction indicates the number of positive results over the number of animals in which the determination was made.

† Uptake of isotope, when present in Group 3, was much lighter than in Group 2.

*Tracer Given Prior to Preparative Endotoxin.* Administration of 3 daily 1 mc doses of S<sup>35</sup>-sulfate, followed in 2 days by the initial, preparative endotoxin injection, resulted in heavy labeling of azurophil granule-containing leukocytes in the circulation during the initial post-endotoxin leukocytosis. In such animals, however, no appreciable label was evident in the fibrinoid glomerular thrombi which developed during the 24 hours

subsequent to the second or provocative endotoxin injection (Table I, Group 1). This preliminary experiment indicated that the sulfated mucopolysaccharide constituent of leukocytes appearing in the circulation after the first endotoxin injection was not incorporated in the glomerular fibrinoid.

With the long interval from isotope administration to sacrifice employed in this experiment, there was relatively heavy diffuse tissue uptake of isotope. Similar tissue uptake was also observed in normal rabbits sacrificed several days after such a schedule of isotope administration. The uptake at these times is not confined to sites known to contain sulfate esters. The nature of the incorporated isotope has not been determined, but heavy labeling of sulfhydryl-rich sites such as hair shafts suggests that some conversion of  $S^{35}$ -sulfate to sulfhydryl-containing amino acids may occur under these conditions.

*Tracer Given with Preparative Endotoxin.* Following administration of a single 1 mc dose of  $S^{35}$ -sulfate at the time of the preparative endotoxin injection, circulating leukocytes were unlabeled 12 hours after the initial endotoxin injection, but heterophils appearing in the circulation 6 and 12 hours after the provocative endotoxin injection were well labeled in most instances (Table I, Group 2). In all animals which developed renal lesions by the time of sacrifice, 12 hours after the second endotoxin, the fibrinoid thrombi appeared to contain incorporated isotope (Figs. 5 and 6). In addition, there was also mild to moderate diffuse tissue uptake which did not, however, obscure the distinct label present in association with fibrinoid in glomerular capillaries.

Many of these kidneys revealed a substantial granulocytic infiltrate. In the autoradiographs of tissue sections the infiltrating leukocytes also appeared heavily labeled with isotope. Although labeled granulocytes were often numerous in the area of the fibrinoid occlusions, as will be described in more detail below, the autoradiographic image over the fibrinoid could not be attributed to intimately associated granulocytes. Rather, it appeared that both the granulocytes and the fibrinoid were labeled. It should also be noted that, following the second endotoxin, labeled heterophils were present in animals with and without fibrinoid thrombi, indicating that the renal lesion was not necessary for the development of labeled azurophil granules.

*Tracer Given with the Provocative Endotoxin.* When a single 1 mc dose of  $S^{35}$ -sulfate was given at the time of the second endotoxin injection and the animals were sacrificed 12 hours later, the fibrinoid thrombi were significantly labeled in most of the animals (Table I, Group 3). In those cases in which the fibrinoid showed some uptake of isotope, however, the degree of labeling was much less than in comparable animals which re-

ceived the tracer with the initial endotoxin injection. Six hours after the provocative endotoxin injection, azurophil granule-containing leukocytes usually were not labeled, but by 12 hours substantial numbers of labeled leukocytes were present in most animals. Thus the labeling of the fibrinoid roughly paralleled labeling of heterophils also under these conditions.

*Nature of the Incorporated Isotope.* While these autoradiographic observations supported the hypothesis that a sulfated mucopolysaccharide was present in the fibrinoid, other possible explanations for the uptake of  $S^{35}$  by the fibrinoid were considered.

It was thought possible that the isotope in the glomerular occlusions was ionic sulfate and not ester sulfate of acid mucopolysaccharide. However, washing of deparaffinized sections in running tap water for 24 hours or soaking of such sections in several changes of solutions of unlabeled sodium sulfate, procedures which might be expected to remove ionic  $S^{35}$ -sulfate, did not increase the fibrinoid label.

Additional evidence that plasma ionic sulfate was not responsible for the fibrinoid label was obtained by assaying plasma radioactivity 6 and 12 hours following the second endotoxin injection, at the time when glomerular thrombosis was under way. Animals which received the tracer with the first endotoxin injection, with heavily labeled fibrinoid thrombi, had less than half the plasma radioactivity of those animals which received the same dose of tracer at the time of the second endotoxin injection, even though the latter group demonstrated far less labeling of glomerular occlusions. The lack of proportionality between plasma radioactivity and fibrinoid labeling further indicated that  $S^{35}$  in the fibrinoid was not attributable to a non-specific trapping of sulfate during the period of thrombosis.

Although uptake of  $S^{35}$ -sulfate is generally regarded to be a rather characteristic and selective feature of sulfated mucopolysaccharide,<sup>13</sup> it was considered possible that the fibrinoid label was due to uptake of sulfhydryl-containing amino acids which might have been synthesized *in vivo* from the inorganic sulfate. Incubation of tissue sections in acidified methanol at 60°C for 4 hours results in the hydrolysis of ester sulfate groups of mucopolysaccharides<sup>7</sup> but does not remove sulfhydryl sulfur. This methylation procedure was demonstrated to remove the  $S^{35}$  from the fibrinoid, as determined by subsequent autoradiography. It should also be noted that the methylation procedure also completely abolished the basophilia of the fibrinoid. Therefore, it appeared that the  $S^{35}$ -sulfate in the fibrinoid glomerular occlusions was ester sulfate—presumably occurring as a constituent of the sulfated mucopolysaccharide, the presence of which was suggested by histochemical procedures.

*$S^{35}$ -Sulfate Uptake by Platelets.* The previously cited histochemical

and autoradiographic data indicated that sulfated mucopolysaccharide is a constituent of glomerular fibrinoid of the generalized Shwartzman reaction. The results were consistent with the hypothesized origin of this material from circulating leukocytes. However, another possible source of the sulfated mucopolysaccharide was considered to be platelets, since, on the basis of biochemical, histochemical, and autoradiographic evidence, they are believed to contain such a constituent,<sup>14,5</sup> and since they are functionally associated with thrombotic phenomena. Therefore, platelet pellets were prepared from cardiac blood obtained at the time of sacrifice of 6 rabbits which had received S<sup>35</sup>-sulfate with the first endotoxin injection, the experimental condition which was associated with maximal labeling of fibrinoid. The platelet concentrate was fixed in formalin and embedded in paraffin alongside the kidney tissue from the same animals. Autoradiographs of these tissues exhibited significant labeling of platelets, in addition to the labeling of fibrinoid described earlier. Similar, although substantially lighter uptake was observed in platelet pellets obtained from animals which had received the isotope with the second endotoxin. The platelet-associated sulfate resisted removal by washing but was removed by methylation, indicating that it was in the form of ester sulfate. Thus, under experimental conditions in which S<sup>35</sup>-sulfate was incorporated into fibrinoid thrombi and circulating heterophil leukocytes with azurophil granules, platelet sulfated mucopolysaccharide was also labeled, and on the basis of this autoradiographic data neither the heterophil granulocyte nor the platelet could be ruled out as a possible source of the presumptive sulfated mucopolysaccharide found in the fibrinoid thrombi.

#### *Granulocytes in Glomeruli Accompanying Fibrinoid Deposition*

Since the histochemical and autoradiographic data described above suggested that the heterophil granulocytes could possibly provide sulfated mucopolysaccharide for incorporation into fibrinoid, it was of interest to determine whether azurophil granule-containing leukocytes were present in glomeruli shortly after the provocative endotoxin injection, at a time when clot formation was under way. Therefore, rabbits were sacrificed at intervals of 1, 2, 4 and 6 hours after a provocative endotoxin injection, and their kidneys were compared with those of untreated rabbits. Even at these short intervals 4 of the 15 animals which received the provocative endotoxin injection showed gross and microscopic evidence of cortical necrosis (Table II). The kidneys of these rabbits contained numerous leukocytes, but they were excluded from consideration in the observations presented, since it was felt that the intraglomerular leukocytes in these instances might be attributable to an inflammatory infiltrate in response to tissue necrosis.

Initial examination of hematoxylin and eosin and PAS-stained sections of the grossly normal kidneys did not reveal numerous granulocytes in glomeruli, although by painstaking examination some could be distinguished from glomerular cells. Therefore, Biebrich scarlet staining at

TABLE II  
NUMBER OF AZUROPHIL GRANULE-CONTAINING HETEROPHIL LEUKOCYTES OBSERVED  
IN 50 SUCCESSIVE GLOMERULAR CROSS SECTIONS \*

Untreated animals	Hours after provocative endotoxin injection			
	1	2	4	6
20	100	48	132(+)	117(+)
24	90	105	135(+)	Necrosis †
13	118	92(+)	205(+)	"
38	Necrosis †	137(+)	dead after 1st endotoxin	"

(+) indicates microscopic fibrinoid present.

\* Fifty successive glomerular cross sections in 4 untreated and 16 endotoxin-treated rabbits.

† Animals with cortical necrosis had a widespread leukocytic infiltrate. Since the leukocytes in the glomeruli in these cases could be attributed to infiltration secondary to the necrosis, possibly biasing the observations, these animals were excluded from consideration.

pH 9.5 or 10.0 was employed to highlight heterophils by selectively staining the basic protein constituent of azurophil granules.<sup>6</sup> With this stain the number of granulocytes present in glomeruli was seen to be quite substantial (Figs. 7 and 8). Azurophil granules were also stained by the high iron diamine method in these cases, but Biebrich scarlet afforded clearer delineation of granulocytes. Following the provocative endotoxin injection 10 or more heterophils with Biebrich scarlet-reactive granules were frequently observed in capillaries in a single glomerular cross section. In normal kidneys, on the other hand, most glomeruli were free of azurophil granule-containing leukocytes and others contained only 1 or 2 such cells. To estimate this apparently excessive number of azurophil granule-containing heterophils 50 successive glomerular cross-sections in a histologic section from each animal were examined with the oil immersion objective, and the number of granulocytes contained therein was enumerated. The glomeruli of animals which had received the provoking endotoxin injection contained approximately 5 times as many granulocytes as those of normal rabbits (Table II). Based on the approximation that about one-tenth of the granulocytes present in a glomerulus would be seen in a random glomerular cross-section, it is apparent that, during the period of fibrinoid deposition studied, the average glomerulus contained at any given time about 25 heterophils with azurophil granules. Many glomeruli must have contained far more numerous granulocytes (Figs. 7 and 8). The increased numbers of glo-



merular granulocytes occurred in the absence of or prior to the development of fibrinoid thrombi, indicating that the numerous intracapillary granulocytes were not a secondary manifestation of any apparent renal lesion. The numerous intraglomerular leukocytes were not simply a reflection of granulocytosis, since the first 4 hours after the provoking endotoxin are marked by a peripheral granulocytopenia; in comparable experiments granulocyte counts at 2 and 4 hours after the second endotoxin averaged one-third of those in normal animals, confirming earlier findings.<sup>2</sup> The observation of relatively numerous granulocytes in glomeruli following the second endotoxin obviously provides no direct evidence that these cells participate locally in the process of fibrinoid formation, but it indicates at least that they have an opportunity to contribute to the thrombotic event.

#### DISCUSSION

The staining of fibrinoid by two methods which are relatively specific for sulfated mucopolysaccharides suggests that such an acidic moiety may be a constituent of fibrinoid. That prior trypsin digestion elicited or enhanced this staining characteristic further suggests that a trypsin-susceptible protein present in the fibrinoid may partially block the staining of acidic groups in undigested sections. Gasic and co-workers have observed similar masking of acid mucopolysaccharides by protein in histochemical studies of the surface of free tumor cells<sup>15</sup> and of certain abnormal granules in renal collecting tubule epithelium<sup>16</sup>; in these sites neuraminidase-susceptible acidic material, i.e., sialomucin, showed increased staining by the Hale method following proteolysis. Their findings seem comparable to the present demonstration of enhancement of basophilia of fibrinoid by tryptic digestion. Unlike fibrinoid, *in vitro* fibrin clots and coagulated bovine fibrinogen showed no basophilia with these methods, indicating that fibrinoid may contain an acidic moiety not present in fibrin or fibrinogen.

The incorporation of S<sup>35</sup>-sulfate by fibrinoid was an additional characteristic of sulfated mucopolysaccharide-containing sites.<sup>13</sup> Methylation of tissue sections hydrolyzes the sulfate esters of sulfomucins<sup>7</sup>; this procedure removed the isotope from the fibrinoid and eliminated its basophilia, affording strong evidence that the incorporated tracer was present as ester sulfate and suggesting that the sulfate was responsible for the basophilia.

The demonstration by Blömbäck, Boström, and Vestermark<sup>17</sup> that rabbit fibrinogen contains tyrosin-O-sulfate raises the possibility that this sulfated amino acid in the fibrinoid might account for the histochemical and autoradiographic findings. This seems improbable for sev-

eral reasons. Tyrosine-O-sulfate is present in fibrinopeptide B, and the thrombin-catalyzed conversion of fibrinogen to fibrin results in the removal of this peptide from the final fibrin residue.<sup>17</sup> Thus, if one hypothesizes that the fibrinoid of the generalized Shwartzman reaction is, in fact, fibrin, the presence of labeled sulfate therein is not consistent with the origin of the sulfate in the precursor fibrinogen, since labeled tyrosine-O-sulfate would have been removed with the hydrolysis and solubilization of fibrinopeptide B. If, however, some intermediate product in the conversion of fibrinogen to fibrin, such as the fibrinopeptide B-containing cryopofibrin of Shainoff and Page,<sup>18</sup> is the immediate precursor of fibrinoid, it is possible that substantial amounts of tyrosine-O-sulfate could remain in the fibrinoid deposits and account for the observed uptake of sulfate. The presence of this sulfated amino acid in fibrinoid, however, presumably would not account for its basophilia, since bovine fibrinogen (which, like rabbit fibrinogen, contains tyrosine-O-sulfate<sup>17</sup>) showed no such basophilia. In contrast, both the histochemical and autoradiographic characteristics of the fibrinoid were consistent with relatively well established criteria indicating the presence of a sulfated mucopolysaccharide.

The possible origin of a sulfated mucopolysaccharide constituent of fibrinoid in circulating leukocytes, first suggested by Thomas and co-workers,<sup>3,4</sup> is supported by our findings. Comparison of isotope uptake by circulating leukocytes and fibrinoid indicated that the heterophils which are available following the provocative endotoxin injection, rather than those present in the circulation during the initial leukocytosis, are the potential source of the mucopolysaccharide.

This hypothesis would account for the observed effects of synthetic acid polymers and of nitrogen mustard pretreatment on the pathogenesis of the generalized Shwartzman reaction. The effectiveness of synthetic acid polymers in precipitating the fibrinoid could be due to their substitution for the "physiologic" acid polymer. The inhibitory effect of nitrogen mustard could be attributed entirely to the leukopenia, as suggested by Thomas, Smith and von Korff,<sup>4</sup> and perhaps additionally to a thrombocytopenic effect. The latter possibility was considered since platelets are classically associated with clotting phenomena and since they contain a sulfated mucopolysaccharide.<sup>14</sup> That platelets might also contribute this constituent to the fibrinoid could not be ruled out by the present findings, inasmuch as under experimental conditions resulting in the uptake of S<sup>35</sup>-sulfate by fibrinoid, both platelets and heterophils with azurophil granules were labeled. However, Herion, Herring, Palmer and Walker<sup>19</sup> have recently observed that nitrogen mustard treatment of rabbits produces only a mild depression of circulating platelets after

4 days, at a time when profound granulocytopenia is present. At approximately the same interval after nitrogen mustard administration rabbits are unsusceptible to production of the generalized Shwartzman reaction.<sup>2</sup> Since the administration of acidic polymers under these conditions "overcomes" the inhibitory effect of nitrogen mustard,<sup>3</sup> it seems reasonable to infer that the acidic polymer is not exerting its effect by substituting for an otherwise necessary platelet factor. Correlation of these findings would seem to support the original view of Thomas, that the inhibitory effect of nitrogen mustard is due to granulocytopenia, and, as a corollary, that the granulocyte is essential for the production of the reaction.

Thus, the various experimental data are consistent with the hypothesis that an essential element in the pathogenesis of the generalized Shwartzman reaction may be the contribution of a sulfated mucopolysaccharide from granulocytes to the fibrinoid; the findings do not appear to support a similar role for platelets. Likewise, the electron microscopic observation by Pappas, Ross and Thomas<sup>20</sup> of only occasional formed elements in the fibrinoid masses further suggests that platelets do not play a conspicuous role in the final development of the thrombi.

On the basis of previous descriptions<sup>10,20</sup> of the morphologic features of the glomerular lesions there has been little indication that granulocytes are directly involved. Brunson, Thomas and Gamble<sup>10</sup> did not mention the presence of leukocytes in their careful description of the pathologic features of the generalized Shwartzman reaction, and in their review of the effects of pyrogens, Bennett and Cluff<sup>21</sup> stated that leukocytic infiltration is not seen in the kidney. With commonly employed staining procedures we also found it difficult to discern that granulocytes were particularly numerous in such glomeruli. The use of Biebrich scarlet to stain selectively the azurophil granules, however, demonstrated that granulocytes were relatively numerous in the region of developing fibrinoid thrombi.

It is clearly possible that the leukocytes in this site are pathogenetically unrelated to the fibrinoid, but the experimental data pointing toward a functional role for these cells in the process of fibrinoid formation leads one to consider the possibility that there is a local interaction between granulocytes and fibrinous material involving a transfer of the acid mucopolysaccharide constituent of azurophil granules to the fibrinoid. In this regard it is pertinent to note that loss of leukocyte granules has been observed in the course of the infiltration of fibrinous material by granulocytes.<sup>22</sup>

Lysis of leukocyte granules following phagocytosis is now well established.<sup>23</sup> The lysis of azurophil granules and apparent mobilization of granule components into phagosomes following bacterial phagocytosis<sup>24</sup>

indicates that the sulfated mucopolysaccharide constituent of these particular granules may be released similarly. While the bulk of experimental evidence points to transfer of granule material directly into intracellular vacuoles, there is some indication that granule enzymes may appear extracellularly as well.<sup>22,23</sup> Furthermore, since granulocytes respond to ingested material with lysis of their cytoplasmic granules, it does not seem unreasonable to speculate that they might be able to react similarly to appropriate extracellular material.

On the basis of such reasoning it is suggested that interaction of fibrin or fibrin precursors and heterophil granulocytes might accomplish the release of granule-sequestered sulfated mucopolysaccharide. The presence of this acidic polymer could then potentiate the conversion of altered fibrinogen to fibrinoid. This hypothesis would account for the apparently necessary role of the leukocyte in the generalized Shwartzman reaction. It would also raise the question of the significance of these or related events as they might pertain to the general mechanisms of response of the vascular system to inflammatory stimuli.

#### SUMMARY

Fibrinoid thrombi of the generalized Shwartzman reaction were stained with the aldehyde fuchsin and the high iron diamine methods, staining procedures which are relatively specific for sulfated mucopolysaccharides. This basophilia of fibrinoid was elicited or enhanced by prior trypsin digestion of tissue sections, suggesting that in undigested sections a protein constituent of the fibrinoid may have blocked the affinity of the acid polysaccharide for the basic stains employed.

When  $S^{35}$ -sulfate was administered at the time of the preparative endotoxin injection, isotope was found by autoradiography to be localized in association with fibrinoid thrombi. Removal of the label by methylation indicated that the isotope was present in the fibrinoid in the form of ester sulfate, presumably of acid mucopolysaccharide. Labeling of fibrinoid was correlated with the labeling of the azurophil granules of heterophil leukocytes present in the circulation following the second or provocative endotoxin injection, but it was independent of the  $S^{35}$ -sulfate labeling of leukocytes present during the initial post-endotoxin leukocytosis. Similar labeling of platelets occurred under conditions in which fibrinoid demonstrated uptake of the isotope.

The presence of relatively numerous leukocytes in glomeruli during the early period of fibrinoid deposition was demonstrated by staining with Biebrich scarlet at highly alkaline pH.

These findings are discussed in relation to the hypothesis that a sulfated mucopolysaccharide constituent of fibrinoid may originate from circulating leukocytes.

## REFERENCES

1. STETSON, C. A., and GOOD, R. A. Studies on the mechanism of the Shwartzman phenomenon. Evidence for the participation of polymorphonuclear leucocytes in the phenomenon. *J. Exper. Med.*, 1951, **93**, 49-64.
2. THOMAS, L., and GOOD, R. A. Studies on the generalized Shwartzman reaction. I. General observations concerning the phenomenon. *J. Exper. Med.*, 1952, **96**, 605-624.
3. THOMAS, L.; BRUNSON, J. G., and SMITH, R. T. Studies on the generalized Shwartzman reaction. VI. Production of the reaction by the synergistic action of endotoxin with three synthetic acidic polymers (sodium polyanethol sulfonate, dextran sulfate, and sodium polyvinyl alcohol sulfonate). *J. Exper. Med.*, 1955, **102**, 249-261.
4. THOMAS, L.; SMITH, R. T., and VON KORFF, R. Studies on the generalized Shwartzman reaction. VII. The role of fibrinogen in the deposition of fibrinoid after combined injections of endotoxin and synthetic acid polymer. *J. Exper. Med.*, 1955, **102**, 263-278.
5. HORN, R. G., and SPICER, S. S. Sulfated mucopolysaccharide and basic protein in certain granules of rabbit leukocytes. *Lab. Invest.*, 1964, **13**, 1-15.
6. HORN, R. G., and SPICER, S. S. Sulfated mucopolysaccharide and basic protein in certain granules of circulating heterophils of rabbits during endotoxin-induced leukocytosis. *Am. J. Path.*, 1964, **44**, 905-919.
7. SPICER, S. S.; SWARM, R. L., and BURTNER, H. J. Comparison of basophilia with S<sup>35</sup> label in normal and methylated mucopolysaccharides. *Lab. Invest.*, 1961, **10**, 256-264.
8. MCKAY, D. G.; GITLIN, D., and CRAIG, J. M. Immunochemical demonstration of fibrin in the generalized Shwartzman reaction. *Arch. Path.*, 1959, **67**, 270-273.
9. ALTSCHULER, C. H., and ANGEVINE, D. M. Histochemical studies on the pathogenesis of fibrinoid. *Am. J. Path.*, 1949, **25**, 1061-1077.
10. BRUNSON, J. G.; THOMAS, L., and GAMBLE, C. N. Morphologic changes in rabbits following the intravenous administration of meningococcal toxin. II. Two appropriately spaced injections; the rôle of fibrinoid in the generalized Shwartzman reaction. *Am. J. Path.*, 1955, **31**, 655-667.
11. SPICER, S. S., and MEYER, D. B. Histochemical differentiation of acid mucopolysaccharides by means of combined aldehyde fuchsin-alcian blue staining. *Am. J. Clin. Path.*, 1960, **33**, 453-460.
12. SPICER, S. S. Diamine methods for differentiating mucosubstances histochemically. *J. Histochem.* (In press)
13. BOSTRÖM, H., and AQVIST, S. Utilization of S<sup>35</sup>-labeled sodium sulphate in the synthesis of chondroitin sulphuric acid, taurine, methionine, and cystine. *Acta chem. Scand.*, 1952, **6**, 1557-1559.
14. ODELL, JR., T. T., and ANDERSON, B. Isolation of a sulfated mucopolysaccharide from blood platelets of rats. *Proc. Soc. Exp. Biol. Med.*, 1957, **94**, 151-156.
15. GASIC, G., and BAYDAK, T. Adhesiveness of Mucopolysaccharides to the Surfaces of Tumor Cells and Vascular Endothelium. In: *Biological Interactions in Normal and Neoplastic Growth*. BRENNAN, M. J., and SIMPSON, W. L. (eds.). Little, Brown & Co., Boston, 1962, 709-715.
16. GASIC, G., and MORRISON, A. B. Mucopolysaccharides of renal collecting tubule cells in potassium deficient rats. *Proc. Soc. Exp. Biol. Med.*, 1963, **112**, 871-873.
17. BLOMBÄCK, B.; BOSTRÖM, H., and VESTERMARK, A. On the [S<sup>35</sup>] sulphate

- incorporation in fibrinopeptide B from rabbit fibrinogen. *Biochim. Biophys. Acta*, 1960, **38**, 502-512.
18. SHAINOFF, J. R., and PAGE, I. H. Significance of cryoprofibrin in fibrinogen-fibrin conversion. *J. Exper. Med.*, 1962, **116**, 687-707.
  19. HERION, J. C.; HERRING, W. B.; PALMER, J. G., and WALKER, R. I. Cr<sup>51</sup>-labeled endotoxin distribution in granulocytopenic animals. *Amer. J. Physiol.*, 1964, **206**, 947-950.
  20. PAPPAS, G. D.; ROSS, M. H., and THOMAS, L. Studies on the generalized Schwartzman reaction. VIII. The appearance, by electron microscopy, of intravascular fibrinoid in the glomerular capillaries during the reaction. *J. Exper. Med.*, 1958, **107**, 333-340.
  21. BENNETT, I. L., JR., and CLUFF, L. E. Bacterial pyrogens. *Pharmacol. Rev.*, 1957, **9**, 427-475.
  22. RIDDLE, J. M. Fibrin dissolution by inflammatory neutrophils. (Abstract) *Fed. Proc.*, 1964, **23**, 240.
  23. COHN, Z. A., and HIRSCH, J. G. The influence of phagocytosis on the intracellular distribution of granule-associated components of polymorphonuclear leucocytes. *J. Exper. Med.*, 1960, **112**, 1015-1022.
  24. HORN, R. G.; SPICER, S. S., and WETZEL, B. K. Phagocytosis of bacteria by heterophil leukocytes: acid and alkaline phosphatase cytochemistry. *Am. J. Path.*, 1964, **45**, 327-335.

---

#### LEGENDS FOR FIGURES

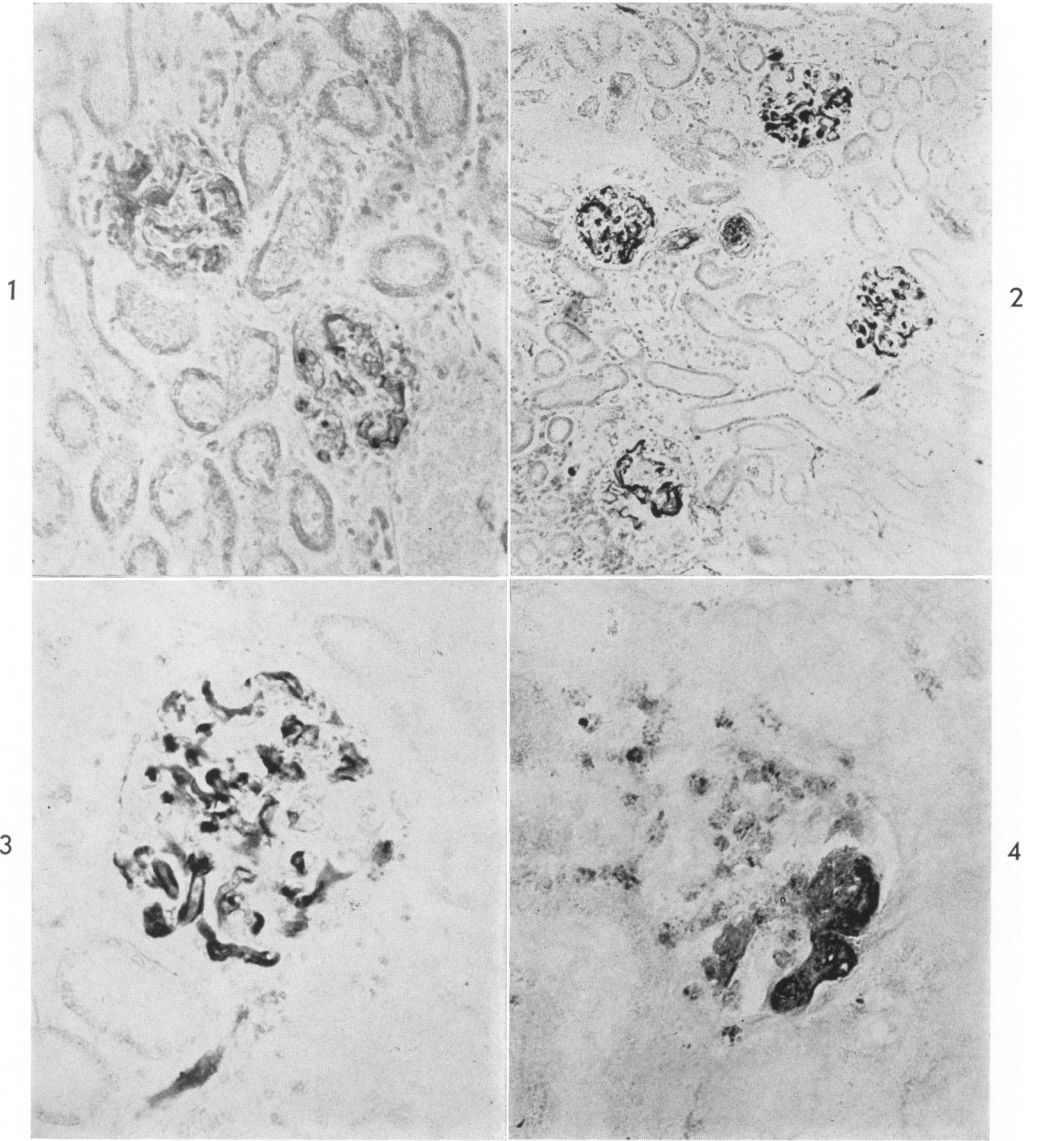
FIGURES 1 to 4. Glomeruli are occluded by fibrinoid in an animal sacrificed 24 hours after a provocative endotoxin injection.

FIG. 1. Glomerular fibrinoid is lightly stained. Buffer control preparation to the section illustrated in Figures 2 and 3. Stained 12 minutes in aldehyde fuchsin.  $\times 200$ .

FIG. 2. Following treatment of a section with trypsin, aldehyde fuchsin stains the fibrinoid more intensely than in the undigested buffer control section (Fig. 1). Fibrinoid is present in most glomerular capillaries and occludes a small artery seen in cross section just above center. Exposed 3 hours to trypsin solution; stained 12 minutes in aldehyde fuchsin, simultaneously with section illustrated in Figure 1.  $\times 105$ .

FIG. 3. Higher magnification of the glomerulus in right center of Fig. 2, showing the configuration of the intracapillary fibrinoid. The acid mucopolysaccharide present in the glomerular basement membrane is not stained by this method. Fibrinoid is also seen below the glomerulus, probably in an arteriole.  $\times 380$ .

FIG. 4. High iron diamine stain of a trypsin-digested section. A portion of a glomerular tuft is occluded by basophilic fibrinoid. Azurophil granules in the numerous infiltrating leukocytes are also stained. Exposed 3 hours to trypsin solution; high iron diamine stain.  $\times 380$ .



FIGS. 5 and 6. Photomicrographs, at two slightly differing planes of focus, of the same glomerulus in a PAS-stained autoradiograph of kidney, taken from a rabbit given 1 mc  $S^{35}$ -sulfate at the time of the preparative endotoxin injection. The animal was sacrificed 12 hours after the provocative injection. Figure 5, taken in the plane of focus of the tissue, illustrates the PAS-reactive fibrinoid. Figure 6, taken in the plane of focus of the overlying emulsion, illustrates the correspondence of the autoradiographic image to the fibrinoid. Exposed 60 days.  $\times 400$ .

FIGS. 7 and 8. Numerous heterophil leukocytes with darkly stained azurophil granules are demonstrated in the glomeruli of a rabbit sacrificed 4 hours after a provocative endotoxin injection. Biebrich scarlet stains the basic protein constituent of azurophil granules, leaving other tissue constituents, including nuclei, essentially unstained in these formalin fixed tissues. The insert in Figure 7 indicates the stained granules in greater detail. Each of the 3 glomerular cross sections contains at least 10 granulocytes. A few leukocytes are also visible in the small interstitial vessels. Aggregates of leukocytes (arrow) are frequently seen in arterioles. Biebrich scarlet, pH 9.5.  $\times 380$ . Insert,  $\times 915$ .



