

# THE CELLULAR PATHOLOGY OF EXPERIMENTAL HYPERTENSION

## II. ARTERIOLAR HYALINOSIS AND FIBRINOID CHANGE

JOSEPH WIENER, M.D.; DAVID SPIRO, M.D., PH.D.,  
AND ROBERT G. LATTES, A.B.

*From the Department of Pathology, College of Physicians and Surgeons  
of Columbia University, New York, N.Y.*

A previous communication has defined the fine structural features of hyperplastic arteriosclerosis in rats with experimental renal hypertension.<sup>1</sup> This paper deals with the electron microscopic aspects of arteriolar hyalinosis and arteriolar fibrinoid necrosis, both of which were encountered in the same group of experimental animals described earlier. The light microscopic features of these forms of arteriolar disease are well-known<sup>2-7</sup> but they have not been well defined at the subcellular level. Two electron microscopic studies of arteriolar hyalinosis in human renal biopsies, with somewhat opposing views regarding the origin of the hyaline material, have recently appeared.<sup>8,9</sup> In the present study further observations regarding the origin and nature of both arteriolar hyalin and fibrinoid are presented.

### MATERIAL AND METHODS

These were identical with the procedures described in our earlier communication<sup>1</sup> and will only be summarized here.

Hypertension was produced in 34 rats by partially constricting the left renal artery with a platinum wire clip.<sup>10</sup> The systolic blood pressures of the hypertensive animals were determined at intervals and were consistently higher than 145 mm Hg. The preoperative systolic blood pressures in these rats as well as the control group and the animals operated upon who failed to develop hypertension were usually less than 130 mm Hg.

Rats were sacrificed after periods of hypertension ranging from 2 weeks to 8 months. Tissue was quickly excised from the right kidney, testis, right adrenal, pancreas, small intestine and skin and apposing surfaces were prepared for electron microscopy and ordinary light microscopy respectively. Material processed for electron microscopy was fixed initially in glutaraldehyde, postfixed in osmium tetroxide and embedded in araldite. Sections of araldite embedded tissue cut at 2  $\mu$  were examined by phase contrast microscopy to locate pathologic arterioles which could on occasion be compared with the same vessel in paraffin embedded, hematoxylin and eosin stained sections. Thin sections were prepared from the araldite embedded tissue containing abnormal

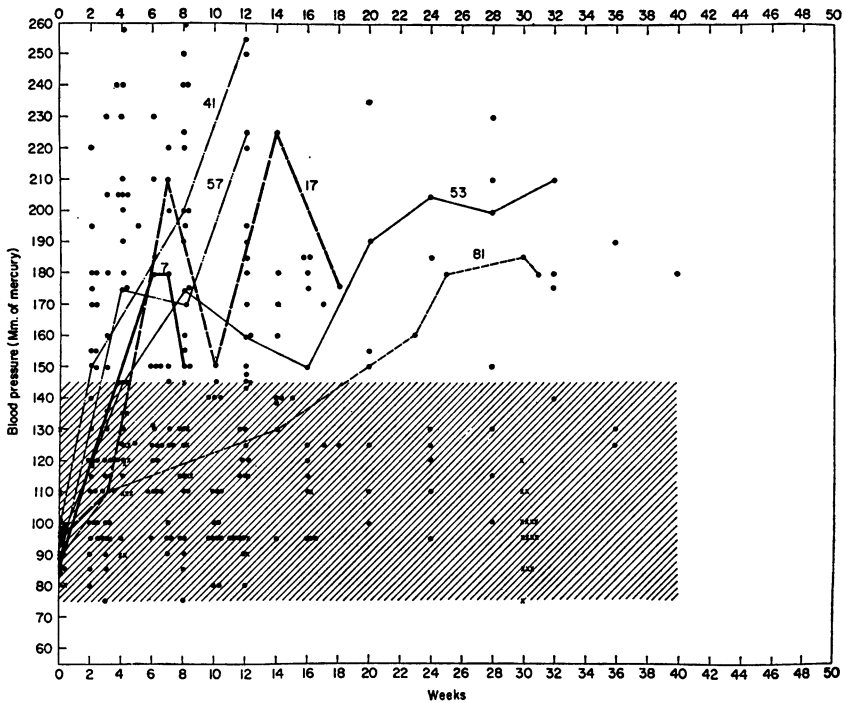
This work was supported in part by the Health Research Council of the City of New York Grant U-1075, and by the General Research Support Grant and Grant H-5906, of the National Institutes of Health of the United States Public Health Service.

This study was presented in part at the Twenty-second Annual Meeting of the Electron Microscopy Society of America, October 15, 1964.

Accepted for publication, April 2, 1965.

arterioles. Appropriate specimens from control animals were similarly processed. Tissues from 4 control and 23 hypertensive animals have thus far been studied by both light and electron microscopy.

The blood pressure measurements in the control rats and those operated on are illustrated in Text-figure 1. This figure also shows the blood pressure curves in 5 hy-



TEXT-FIG. 1. The systolic blood pressure determinations in unoperated control (X) and animals operated upon (circles) are depicted at various intervals. Zero time on the abscissa coincides with the initial blood pressure measurements on the unoperated control litter mates and is also the time immediately prior to operation. Only a few of these initial blood pressure determinations falling in the 80 to 130 mm Hg range are depicted. The range of blood pressures in the unoperated control rats for periods up to 30 weeks are encompassed by the diagonally shaded area. The numbered curves represent the serial blood pressure determinations in 6 hypertensive animals. The vascular lesions in 5 of these animals (nos. 7, 41, 53, 57 and 81) are shown in the accompanying micrographs. The majority of animals that became hypertensive had elevated systolic readings 2 to 8 weeks following operation. A few animals developed hypertension after more prolonged post-operative intervals (animal no. 81).

pertensive animals (Nos. 7, 41, 53, 57 and 81) from whose tissues the light and electron micrographs were selected to illustrate this paper. The sixth blood pressure curve, that of animal no. 17, relates to an animal reported on in our previous paper.<sup>1</sup>

## RESULTS

The lesions of arteriolar hyalinosis tended to occur in vessels that were smaller in diameter than those showing hyperplastic sclerosis. Such arterioles normally lacked an internal elastic lamella. By light microscopy the hyalinized arterioles exhibited walls thickened by acidophilic

homogeneous acellular deposits of hyalin with resultant narrowing of their lumens. In addition, small hyalinized arterioles in animals with severe hypertension frequently displayed small intramural, deeply acidophilic and somewhat granular areas characteristic of fibrinoid alteration. When  $2\mu$  thick araldite-embedded sections of such vessels were examined by phase contrast microscopy the thickening of the vessel walls by homogeneous acellular material was again evident (Fig. 1). The areas of fibrinoid change were also readily identified and appeared as intramural strands of optically dense material.

With electron microscopy the hyaline material was extracellular and replaced the medial smooth muscle to varying degrees (Figs. 2 to 9). The extent of muscle atrophy and replacement varied with the amount of hyaline material present. The hyalin lacked a highly ordered structure, appeared granular and contained occasional filaments (Figs. 7 to 9). Its general appearance and electron opacity resembled that of basement membranes. When abundant, the hyalin formed diffuse deposits that were sharply demarcated from the adventitia and were often contiguous with processes of adventitial fibroblasts (Figs. 2, 3, 5 and 6). These deposits lay in intimate contact with and frequently completely surrounded medial smooth muscle cells which were markedly reduced in size (Figs. 2 to 9). The masses of hyalin were often divided into compartments by narrow strands of residual smooth muscle cell cytoplasm (Figs. 2 to 5). The size and shape of these hyalin containing compartments often approximated those of normal medial smooth muscle cells. In many vessels the hyalin often comprised the major portion of a media whose remaining smooth muscle cells were greatly atrophic (Figs. 2 to 5 and 7 to 8). Hyaline material could also be seen and was occasionally limited to the subendothelial space (Fig. 10).

Hyalinized arterioles, in common with hyperplastic arterioles,<sup>1</sup> also contained numerous discrete layers of basement membranes in the subendothelial space and between medial smooth muscle cells (Figs. 2, 3, 6 and 11). These discrete layers of basement membrane were frequently continuous with the more diffuse and confluent masses of hyalin in the media and subendothelial space (Figs. 3 and 6). The surfaces of smooth muscle cells in intimate contact with the hyalin frequently lacked discrete basement membranes (Figs. 2, 3 and 6 to 9). Neither fibroblasts nor native collagen fibers were noted within the intima or media of hyalinized arterioles. Dense extracellular granules similar to those seen in the walls of the hyperplastic vessels<sup>1</sup> were present in the intima and media of these arterioles (Fig. 6).

Areas of fibrinoid change, as previously stated, were readily recognizable by phase contrast microscopy and were represented by elongated

deposits of considerably greater optical density than the medial hyalin (Fig. 1). With electron microscopy, masses of higher electron opacity than the medial hyalin in which they were embedded, were observed (Figs. 1 to 5 and 12, 13). These masses were elongated or polygonal in shape, occasionally had a periodic structure and were considered to be fibrin. The mean dimensions of the periodicity exhibited by these deposits fell into 2 groups, measuring 115 Å and 230 Å respectively. Individual fibrils, approximately 50 Å in diameter, were noted among the electron opaque deposits (Fig. 13). Smaller deposits of fibrin were also present in the subendothelial space of hyperplastic arterioles.<sup>1</sup>

Another feature in the walls of vessels containing considerable amounts of fibrin or hyalin was the presence of cells with a perikaryon containing numerous cisternae of both rough and smooth surfaced endoplasmic reticulum (Figs. 7, 12, 14 and 15). These cells had numerous cytoplasmic processes containing closely packed filaments measuring approximately 75 Å in diameter which resembled smooth muscle myofilaments (Figs. 14 and 15). The endothelium in the arterioles of hypertensive animals showed no obvious abnormalities. On rare occasion, however, gaps between adjacent endothelial cells were evident (Figs. 3 and 4). The lumen was thus in direct contact with the underlying subendothelial space in such areas. Occasionally, dense oval structures resembling red cell fragments were noted in the walls of vessels which contained hyalin and fibrin (Fig. 5).

Other structural alterations were seen in the smaller arterioles of hypertensive animals. The medial smooth muscle cells exhibited zones of decreased electron density (Figs. 16 and 17). This was accounted for by a marked decrease in the number of myofilaments per unit area of cytoplasm. In addition, varying sized vacuoles (Fig. 17) and myelin forms were noted in the cytoplasm of smooth muscle cells (Fig. 3).

#### DISCUSSION

Arteriolar hyalinosis, which affects primarily the smaller arterioles, is characterized by the presence of granular extracellular deposits which impinge upon and replace the medial smooth muscle cells. Similar deposits are also noted in the intima. The deposition of this material results in a greatly thickened arteriole with a narrowed lumen.

The nature of the hyaline deposits is difficult to assess inasmuch as they lack a highly organized structure. It does, however, in terms of structure and electron opacity, resemble basement membrane. Furthermore, the numerous discrete layers of basement membranes found to varying degrees in hyalinized vessels are often continuous with the hyaline deposits. These observations indicate that the hyaline deposits



are formed by the fusion and confluence of these layers of basement membranes.

McGee and Ashworth have demonstrated deposits of material within the media of hyalinized vessels from human renal biopsy specimens which they concluded were derived from basement membranes.<sup>8</sup> This is in agreement with the present observations as well as those of Montgomery and Muirhead<sup>11-14</sup> and Smith.<sup>15</sup> On the other hand, Biava, Dyrda, Genest and Bencosme suggested that hyaline deposits in human renal arterioles were derived from plasma constituents.<sup>9</sup> This proposal was based primarily upon the localization of the deposits within the intima and their absence from the media. As pointed out in the present study, however, the deposits were usually more abundant in and frequently limited to the media. The fact that vascular hyalin appears to be composed largely of glycoproteins<sup>14</sup> does not establish whether this material develops autochthonously, or is derived from plasma glycoproteins (for review see Reference<sup>16</sup>). The glycoprotein nature of hyalin, however, is compatible with its proposed basement membrane nature.<sup>17</sup> In this regard, increased quantities of basement membranes have been observed in hyalinized glomeruli.<sup>18-22</sup>

Little is known about the mechanical properties of hyalin. It is quite possible, however, that the thickening of the vessel wall by the hyaline deposits with resultant diminution in the size of the lumen plays a significant role in maintaining increased peripheral resistance. The nature and properties of vascular hyalin obviously require more definitive and biochemically oriented investigation.

The areas in smooth muscle cells which contain both decreased numbers of myofilaments as well as vacuoles may be related to functional, atrophic or degenerative changes. Degenerative changes in medial smooth muscle have been described by others in hypertension.<sup>23</sup>

Deposits of great electron opacity, which are interpreted as fibrin, were observed within the media of both hyalinized and hyperplastic arterioles.<sup>1</sup> These deposits, as noted, were readily identifiable by phase contrast microscopy in araldite embedded sections cut at  $2\mu$  and corresponded with areas of fibrinoid change in hematoxylin and eosin stained sections. On occasion, it has been possible to establish the fact that areas exhibiting the tinctorial characteristics of fibrinoid correspond to similar regions exhibiting the dense deposits by phase and electron microscopy. These deposits vary in size from strands which are resolvable only with the electron microscope to larger accumulations which are readily identified as fibrinoid change by light microscopy.

There are several reasons for considering that these deposits are composed of fibrin. As pointed out, they are seen in vessels which exhibit

characteristic fibrinoid alterations and it has been shown by immunofluorescent studies that fibrin is the essential component of fibrinoid.<sup>24</sup> The diameter of the fibrils (approximately 50 Å) within some of the deposits is similar to that of fibrinogen molecules.<sup>25</sup> In addition, the axial periodicity of about 230 Å occasionally observed is characteristic of fibrin.<sup>26,27</sup> The frequent lack of periodicity and the occurrence of a different periodicity measuring 115 Å requires further discussion. It should be emphasized that the absolute dimensions of repeating structures in sections must be interpreted with caution because of uncertainties relating to orientation and to compression artifacts introduced during thin sectioning.<sup>28</sup> Deposits which demonstrate a 230 Å periodicity, a 115 Å periodicity or no period, however, have been observed even when the direction of sectioning, and therefore the compression, is either at right angles to the axial period or parallel to the long axis of the electron opaque strands. Large amounts of similar fibrillar material, which largely lack periodic structure and which are undoubtedly fibrin, have been observed previously in experimental thrombi.<sup>22,29,30</sup> Wyllie has recently identified such aperiodic material in human blood clots as fibrin utilizing the ferritin-conjugated antibody technique.<sup>31</sup>

The nature of the 230 Å periodicity best observed in preparations of fibrin *in vitro* has never been adequately explained. The physico-chemical and electron microscopic estimates of the length of the fibrinogen molecule indicate that the fibrinogen monomer is considerably longer than 230 Å.<sup>32</sup> Electron microscopic studies of Hall and Slayter showed that the fibrinogen molecule could be as long as 475 Å.<sup>25</sup> If Hall and Slayter's data are correct, the so-called "characteristic" periodicity of fibrin could be due to the displacement of individual fibrin monomers in the axial direction by one half of a length in adjacent macromolecules. This half stagger in adjacent laterally aligned fibrin monomers would provide a period of about one half the length of the fibrinogen molecule (i.e. 230 Å) as first suggested by Cohen.<sup>33</sup> The 115 Å periodicity could be similarly explained by a quarter stagger of adjacent molecules relative to each other. An alternative explanation for the 115 Å periodicity may reflect an inability to distinguish between the major period of 230 Å and the subperiod which is half this value.<sup>34</sup> This explanation, however, appears unlikely inasmuch as the subperiod has never been observed in sectioned fibrin with a 230 Å periodicity. If the lateral alignment of adjacent fibrinogen molecules were random, then no periodicity would be evident. Under such circumstances, however, the regular packing of individual fibrin fibrils could still account for the polygonal crystalline forms seen in this study. At the other extreme, if the adjacent fibrin molecules were to align in register without stagger,

the repeating unit would be the length of the fibrinogen molecule or approximately 460 Å. Cohen has recently observed this periodicity occasionally in paracrystalline forms of fibrinogen.<sup>33</sup> While these suggestions regarding varying periodicities of fibrin are somewhat speculative, it has been demonstrated that periodicities of other fibrous proteins such as collagen and paramyosin are due to varying degrees of stagger in the side-to-side alignment of the molecules.<sup>35,36</sup> Schmitt and his associates have demonstrated tactoidal aggregates of collagen that lack periodicity.<sup>35</sup>

It should also be pointed out that the deposits identified as fibrin may be primarily composed of fibrinogen aggregates. Cohen and co-workers have demonstrated 230 Å spacings in paracrystalline forms of fibrinogen by means of both x-ray diffraction<sup>37</sup> and electron microscopy,<sup>38</sup> and have suggested that a staggered array of fibrinogen molecules is responsible for the periodicity. These workers have also observed tactoidal aggregates of fibrinogen which lack a periodicity.<sup>33</sup> The immunologic techniques cannot differentiate between fibrinogen and fibrin inasmuch as these two proteins exhibit immunologic cross-reactivity.<sup>39,40</sup> It is also possible that some of these crystalline masses represent crystals of hemoglobin.

The obvious source for the intramural fibrin would be circulating plasma fibrinogen. The enhanced permeability of vessels which has been postulated in the hypertensive state<sup>41-43</sup> could account for its intramural deposition. Morphologic evidence for increased permeability, consisting of large gaps between adjacent endothelial cells, has been observed in hyalinized vessels. It is therefore of interest that the largest deposits of fibrin are noted in vessels so affected. The presence of intramural bodies resembling red cells or red cell fragments may also be a manifestation of increased permeability.

Additional evidence of increased permeability in hypertension stems from the work of McGee and Ashworth, who observed extracellular intramural granules in hyperplastic vessels.<sup>8</sup> These authors suggested that the granules represented lipoprotein particles and small chylomicrons. Similar structures were observed in this study. It is not felt, however, that the presence of these granules necessarily reflects the passage of excessive quantities of lipoprotein particles and chylomicrons across the vessel wall inasmuch as large numbers of similar particles have been observed in the normal rat coronary artery.<sup>44</sup>

The aggregates of fibrin observed in this study are not associated with cellular degenerative changes or necrosis, as some authors have implied.<sup>45</sup> The lack of necrosis, as well as the presence of varying amounts of fibrin, suggest that the passage of fibrin from the lumen and its intramural accumulation may be a continuous and progressive develop-

ment in the hypertensive state. In any case, the existence of intramural fibrin should not be taken to indicate necrosis.

As previously mentioned, unusual smooth muscle cells containing well developed systems of rough surfaced endoplasmic reticulum and myofilaments limited to the peripheral cell processes, are found in vessels with large amounts of hyalin or fibrin. The significance of these muscle cells is not clear. It is tempting to speculate, however, that the large amounts of rough surfaced endoplasmic reticulum in the smooth muscle may be related to the synthesis of basement membranes and hyalin. If the smooth muscle cells are indeed the major source of the increased amounts of basement membrane or hyalin, then the increase in intramural pressure in hypertension could be the stimulus for this synthetic activity.

#### SUMMARY

The fine structural features of arteriolar hyalinosis and arteriolar fibrinoid change in rats with experimental renal hypertension have been presented. The hyaline material appears granular, lacks a highly ordered structure and resembles basement membrane. The hyaline deposits are found primarily in the media, where they replace the medial smooth muscle to a varying degree. Hyalin may also occasionally be present in the intima. The hyalinized vessels contain numerous discrete layers of basement membranes. Continuity between these and larger confluent masses of hyalin has been demonstrated. The observations suggest that hyaline deposits are formed by the fusion and coalescence of basement membrane layers.

Deposits of intramural fibrin correspond with areas of fibrinoid change noted in hyalinized arterioles by light microscopy. These fibrin aggregates are found in the absence of necrosis. Large gaps are noted between adjacent endothelial cells in hyalinized vessels. The observations suggest that the intramural deposition of fibrin is the result of increased vascular permeability.

#### REFERENCES

1. SPIRO, D.; LATTES, R. G., and WIENER, J. The cellular pathology of experimental hypertension. I. Hyperplastic arteriolar sclerosis. *Amer. J. Path.*, 1965, 47, 19-49.
2. JORES, L. Über die Arteriosklerose der kleinen Organarterien und ihre Beziehungen zur Nephritis. *Virchow Arch. Path. Anat.*, 1904, 178, 367-406.
3. BELL, E. T., and CLAWSON, B. J. Primary (essential) hypertension; a study of four hundred and twenty cases. *Arch. Path. (Chicago)*, 1928, 5, 939-1002.
4. FISHBERG, A. M. Anatomic findings in essential hypertension. *Arch. Intern. Med. (Chicago)*, 1925, 35, 650-668.
5. KERNOHAN, J. W.; ANDERSON, E. W., and KEITH, N. M. The arterioles in cases of hypertension. *Arch. Intern. Med. (Chicago)*, 1929, 44, 395-423.

6. KIMMELSTIEL, P., and WILSON, C. Benign and malignant hypertension and nephrosclerosis. *Amer. J. Path.*, 1936, **12**, 45-82.
7. MORITZ, A. R., and OLDT, M. R. Arteriolar sclerosis in hypertensive and non-hypertensive individuals. *Amer. J. Path.*, 1937, **13**, 679-728.
8. MCGEE, W. G., and ASHWORTH, C. T. Fine structure of chronic hypertensive arteriopathy in the human kidney. *Amer. J. Path.*, 1963, **43**, 273-299.
9. BIAVA, S. G.; DYRDA, I.; GENEST, J., and BENCOSME, S. A. Renal hyaline arteriosclerosis; an electron microscopic study. *Amer. J. Path.*, 1964, **44**, 349-363.
10. WILSON, C., and BYROM, F. B. Renal changes in malignant hypertension. Experimental evidence. *Lancet*, 1939, **1**, 136-139.
11. MONTGOMERY, P. O., and MUIRHEAD, E. E. Similarities between the lesions in human malignant hypertension and in the hypertensive state of the nephrectomized dog. *Amer. J. Path.*, 1953, **29**, 1147-1155.
12. MONTGOMERY, P. O., and MUIRHEAD, E. E. A characterization of hyaline arteriolar sclerosis by histochemical procedures. *Amer. J. Path.*, 1954, **30**, 521-531.
13. MONTGOMERY, P. O., and MUIRHEAD, E. E. A microspectroscopic study of arterioles in benign and malignant hypertension. *Amer. J. Path.*, 1954, **30**, 1181-1189.
14. MONTGOMERY, P. O., and MUIRHEAD, E. E. A differentiation of certain types of fibrinoid and hyalin. *Amer. J. Path.*, 1957, **33**, 285-291.
15. SMITH, J. P. Hyaline arteriolosclerosis in the kidney. *J. Path. Bact.*, 1955, **69**, 147-168.
16. DUSTIN, P., JR. Arteriolar Hyalinosis. In: International Review of Experimental Pathology. RICHTER, G. W., and EPSTEIN, M. A. (eds.). Academic Press, New York and London, 1962, Vol. 1, pp. 73-138.
17. LAZAROW, A., and SPIEDEL, E. The Chemical Composition of the Glomerular Basement Membrane and Its Relationship to the Production of Diabetic Complications. In: Proceedings of the Conference on Small Blood Vessel Involvement in Diabetes Mellitus, held March 25-27, 1963. SIPERSTEIN, M. D.; COLWELL, A. R., SR., and MEYER, K. (eds.). American Institute of Biological Sciences, Washington, D.C., 1964, pp. 127-150.
18. FARQUHAR, M. G.; VERNIER, R. L., and GOOD, R. A. An electron microscope study of the glomerulus in nephrosis, glomerulonephritis and lupus erythematosus. *J. Exp. Med.*, 1957, **106**, 649-660.
19. SPIRO, D. The structural basis of proteinuria in man; electron microscopic studies of renal biopsy specimens from patients with lipid nephrosis, amyloidosis, and subacute and chronic glomerulonephritis. *Amer. J. Path.*, 1959, **35**, 47-73.
20. BERGSTRAND, A., and BUCHT, H. The glomerular lesions of diabetes mellitus and their electron-microscope appearances. *J. Path. Bact.*, 1959, **77**, 231-242.
21. SPIRO, D. Electron Microscopic Studies of Renal Biopsies on Patients with Proteinuria. In: Proceedings of the Eleventh Annual Conference on the Nephrotic Syndrome. METCOFF, J. (ed.). National Kidney Disease Foundation, New York, 1960, pp. 171-221.
22. VASSALLI, P.; SIMON, G., and ROULLER, C. Electron microscopic study of glomerular lesions resulting from intravascular fibrin formation. *Amer. J. Path.*, 1963, **43**, 579-617.

23. SOMMERS, S. C.; RELMAN, A. S., and SMITHWICK, R. H. Histologic studies of kidney biopsy specimens from patients with hypertension. *Amer. J. Path.*, 1958, **34**, 685-716.
24. GITLIN, D.; CRAIG, J. M., and JANEWAY, C. A. Studies on the nature of fibrinoid in the collagen diseases. *Amer. J. Path.*, 1957, **33**, 55-77.
25. HALL, C. E., and SLAYTER, H. S. The fibrinogen molecule: its size, shape, and mode of polymerization. *J. Biophys. & Biochem. Cytol.*, 1959, **5**, 11-15.
26. HALL, C. E. Electron microscopy of fibrinogen and fibrin. *J. Biol. Chem.*, 1949, **179**, 857-864.
27. PORTER, K. R., and HAWN, C.V.Z. Sequences in the formation of clots from purified bovine fibrinogen and thrombin: a study with the electron microscope. *J. Exp. Med.*, 1949, **90**, 225-232.
28. SPIRO, D. The ultrastructure of striated muscle at various sarcomere lengths. *J. Biophys. & Biochem. Cytol.*, 1956, **2**, no. 4, suppl., 157-162.
29. WIENER, J., and SPIRO, D. Electron microscope studies in experimental thrombosis. *Exp. Molec. Path.*, 1962, **1**, 554-572.
30. URIUHARA, T., and MOVAT, H. Z. Allergic inflammation. IV. The vascular changes during the development and progression of the direct active and passive Arthus reactions. *Lab. Invest.*, 1964, **13**, 1057-1079.
31. WYLLIE, J. C. Identification of fibrin with ferritin-conjugated antifibrinogen. *Exp. Molec. Path.*, 1964, **3**, 468-474.
32. SCHERAGA, H. A., and LASKOWSKI, M., JR. The fibrinogen-fibrin conversion. *Advances Protein Chem.*, 1957, **12**, 1-131.
33. COHEN, D. Architecture of the  $\alpha$ -Class of Fibrous Proteins. In: The Eleventh Annual Symposium Publication of the Society of General Physiologists on Molecular Architecture in Cell Physiology. HAYASHI, T. (ed.). Prentice-Hall, Englewood, N.J. (In press)
34. HALL, C. E. Electron microscopy of the fibrinogen molecule and the fibrin clot. *Lab. Invest.*, 1963, **12**, 998-1001.
35. SCHMITT, F. O. Interaction Properties of Elongate Protein Macromolecules with Particular Reference to Collagen (tropocollagen). In: Biophysical Science—A Study Program. ONCLEY, J. L.; SCHMITT, F. O.; WILLIAMS, R. C.; ROSENBERG, M. D., and BOLT, R. H. (eds.). John Wiley and Sons, Inc., New York, 1959, pp. 349-358.
36. HODGE, A. J. Fibrous Proteins of Muscle. In: Biophysical Science—A Study Program. ONCLEY, J. L.; SCHMITT, F. O.; WILLIAMS, R. C.; ROSENBERG, M. D., and BOLT, R. H. (eds.). John Wiley and Sons, Inc., New York, 1959, pp. 409-425.
37. STRYER, L.; COHEN, C., and LANGRIDGE, R. Axial period of fibrinogen and fibrin. *Nature (London)*, 1963, **197**, 793-794.
38. COHEN, C.; REVEL, J.-P., and KUCERA, J. Paracrystalline forms of fibrinogen. *Science*, 1963, **141**, 436-438.
39. GITLIN, D., and BORGES, W. H. Studies on the metabolism of fibrinogen in two patients with congenital afibrinogenemia. *Blood*, 1953, **8**, 679-686.
40. GITLIN, D.; LANDING, B. H., and WHIPPLE, A. The localization of homologous plasma proteins in the tissues of young human beings as demonstrated with fluorescent antibodies. *J. Exp. Med.*, 1953, **97**, 163-176.
41. BAKER, R. D., and KENT, S. P. Nature of the lipid of hyaline arteriosclerosis. *Arch. Path.*, 1950, **49**, 568-573.
42. WILENS, S. L., and ELSTER, S. K. The role of lipid deposition in renal arteriolar sclerosis. *Amer. J. Med. Sci.*, 1950, **219**, 183-196.

43. KUHNS, J. G.; PUCHTLER, H., and SWEAT, F. Histochemical evidence for plasma proteins in arteriosclerosis. (Abstract) *Anat. Rec.*, 1962, 142, 250.
44. SPIRO, D., and WIENER, J. The Fine Structure of the Coronary Artery. In: Coronary Heart Disease; the Seventh Hahnemann Symposium. LIKOFF, W., and MOYER, J. H. (eds.). Grune and Stratton, New York and London, 1963, pp. 11-24.
45. ALLEN, A. C. The Kidney; Medical and Surgical Diseases. Grune and Stratton, New York, 1962, ed. 2, Chapt. 14, Diseases of Vessels, p. 572.

---

[ *Illustrations follow* ]

## LEGENDS FOR FIGURES

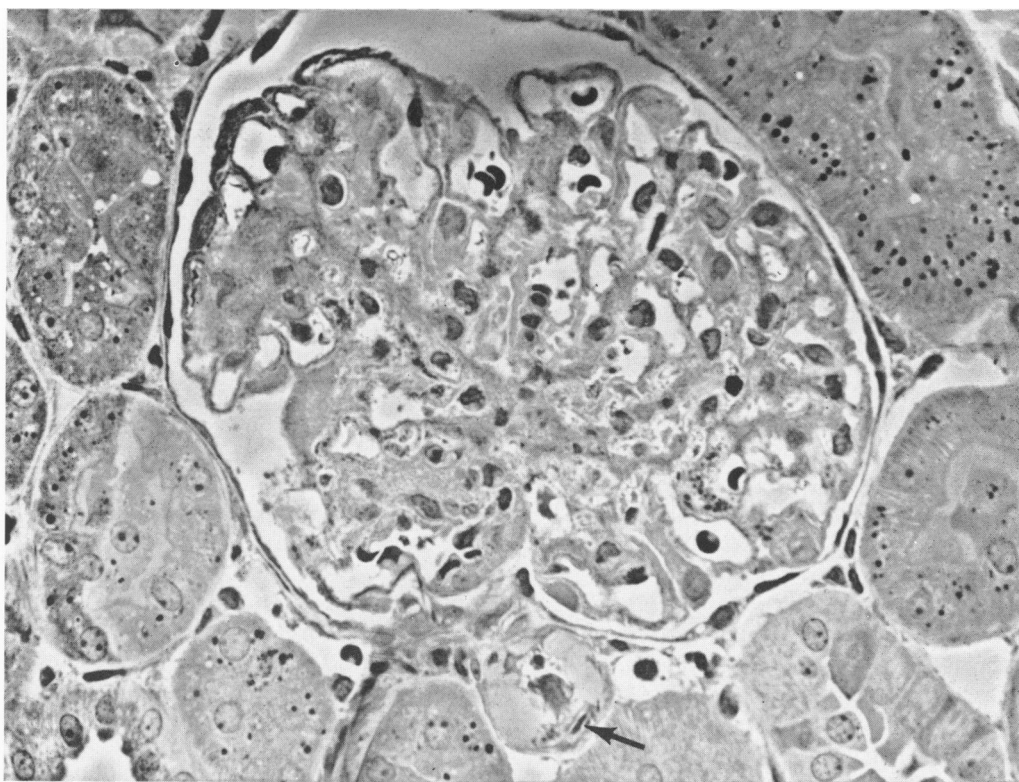
*Key:*

F = fibrin  
H = hyalin

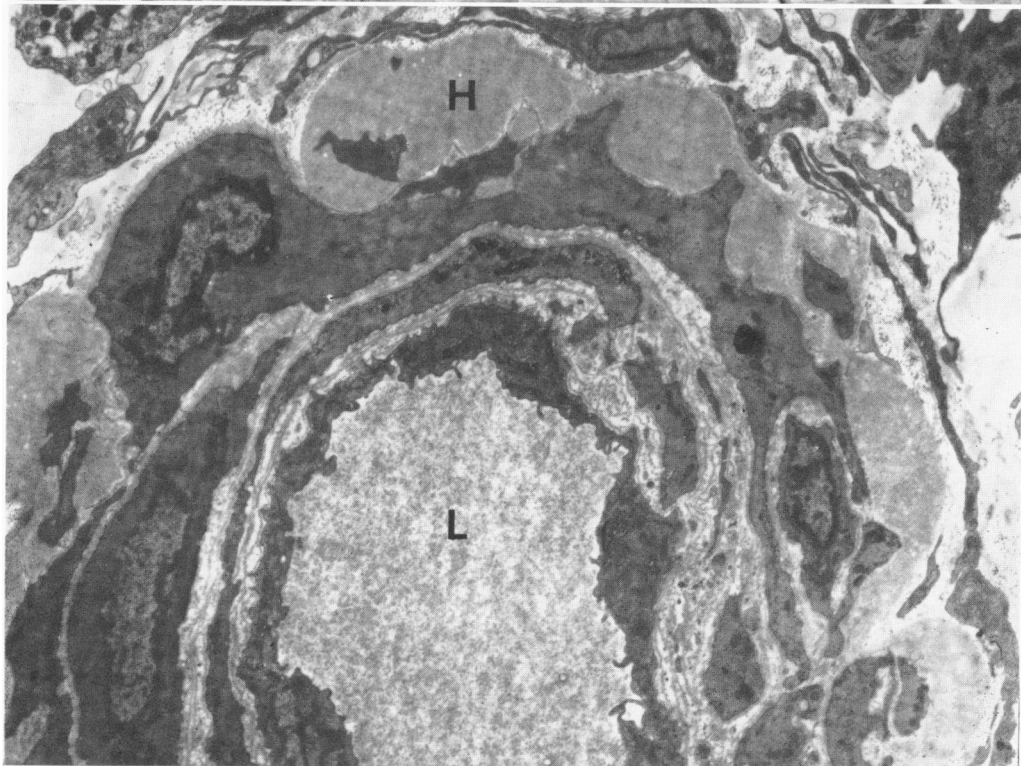
L = lumen  
V = vacuole

- FIG. 1. Phase contrast micrograph, araldite embedded tissue from a hypertensive animal. There is hyalinization of the afferent arteriole. In addition, optically dense deposits of fibrin (arrow) appear within the vessel wall. (Figs. 4 and 5 are electron micrographs of the same vessel.)  $\times 300$ .
- FIG. 2. Extracellular deposits of hyalin (H) impinge upon the smooth muscle cells in the media of this vessel.  $\times 6,000$ .



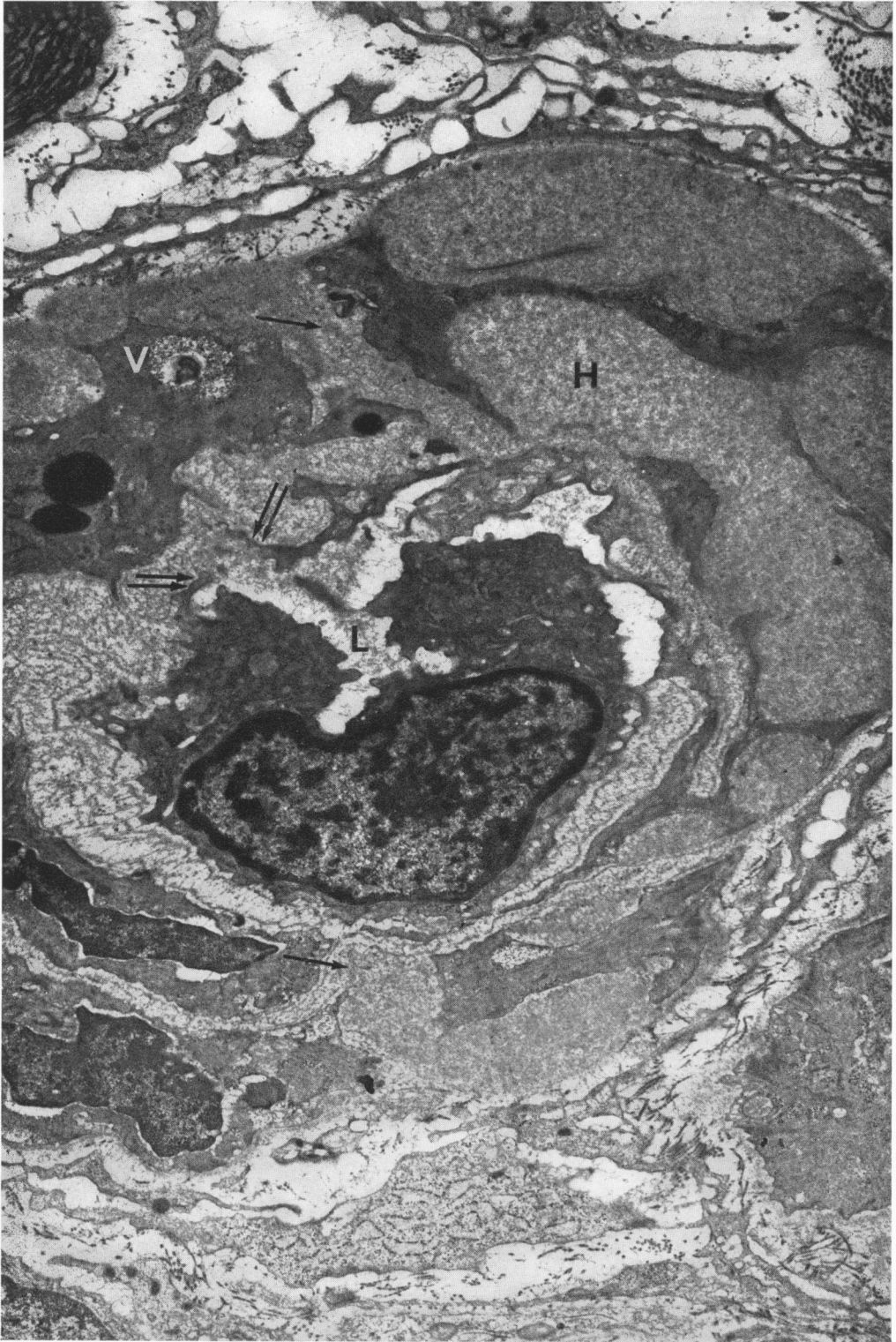


1



2

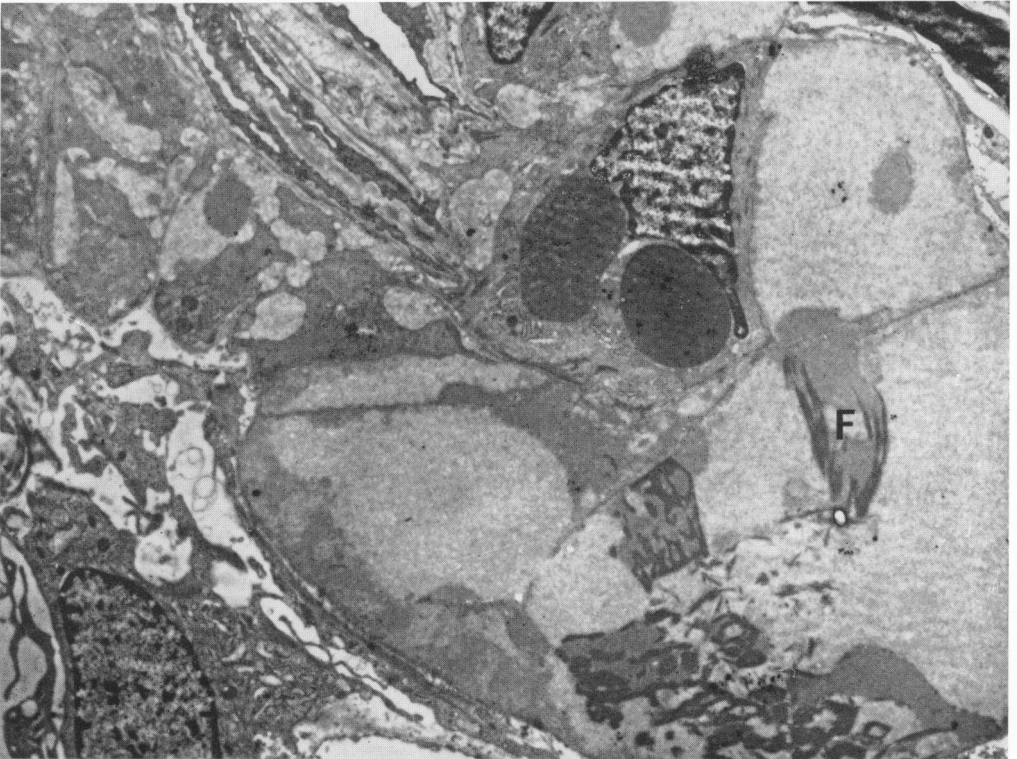FIG. 3. More extensive deposits of hyalin are separated from one another by narrow strands of medial smooth muscle cells and are sharply delimited from the adventitia. Numerous layers of basement membrane are present within portions of the intima and media. In areas, the reduplicated layers of basement membrane fuse with confluent deposits of hyalin (arrow). A large gap is present in the endothelial cell layer (double arrows). Dense droplets, presumably lipid, as well as a vacuole (V) containing a myelin form are present in a smooth muscle cell. The wall of the vessel is markedly thickened and the lumen is narrowed.  $\times 13,000$ .



- FIG. 4. The muscle in this afferent arteriole is extensively replaced by large deposits of hyalin in which may be seen narrow strands of smooth muscle cell cytoplasm. The lower right portion of the micrograph contains numerous strands of fibrin of greater electron opacity than the hyalin. A gap in the endothelium is evident (arrows). In this area, the cytoplasmic process of a hematogenous element, which may be a platelet, is in contact with the reduplicated basement membranes in the subendothelial space.  $\times 6,000$ .
- FIG. 5. This vessel is similar to that shown in Figure 4 and contains extensive deposits of both hyalin and fibrin. Two oval intracellular bodies, which may represent red cell fragments, are noted near the center of the figure.  $\times 6,000$ .



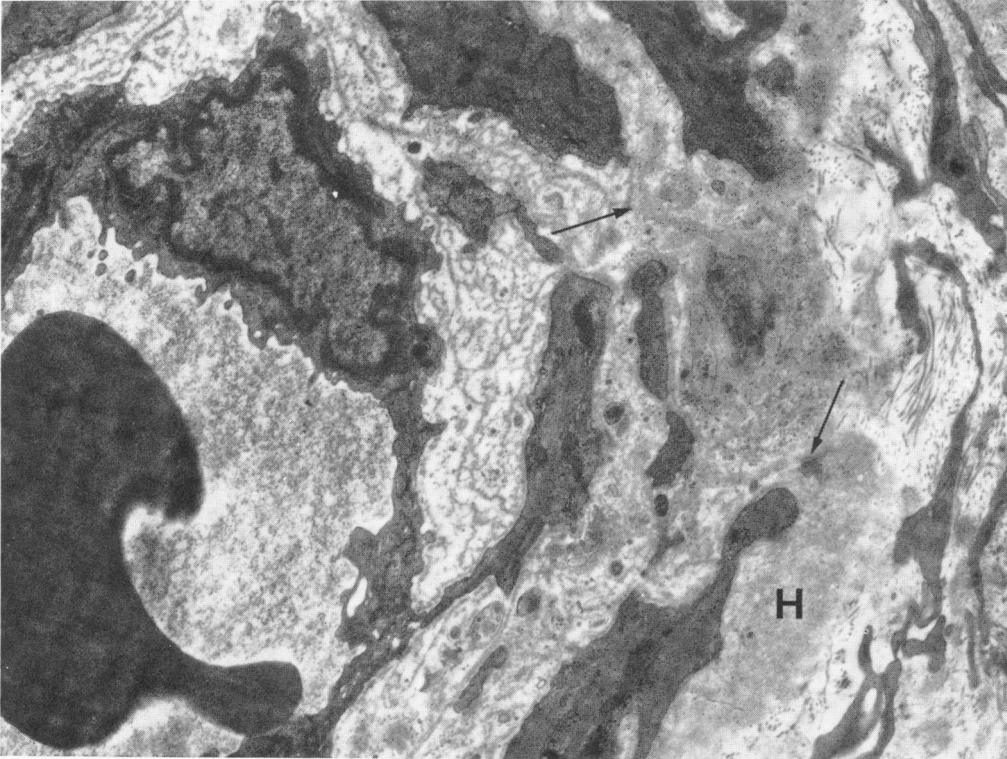
4




5

- FIG. 6. Hyaline material is located principally in the outer layers of the media. The subendothelial space contains numerous layers of basement membrane which in areas fuse with the more compact masses of hyalin (arrows).  $\times 12,000$ .
- FIG. 7. The media here is composed largely of hyalin. Portions of atrophic smooth muscle cells are embedded in the hyalin. The smooth muscle cell in the lower central portion of the figure contains increased numbers of mitochondria and cisternae of endoplasmic reticulum.  $\times 14,000$ .





6

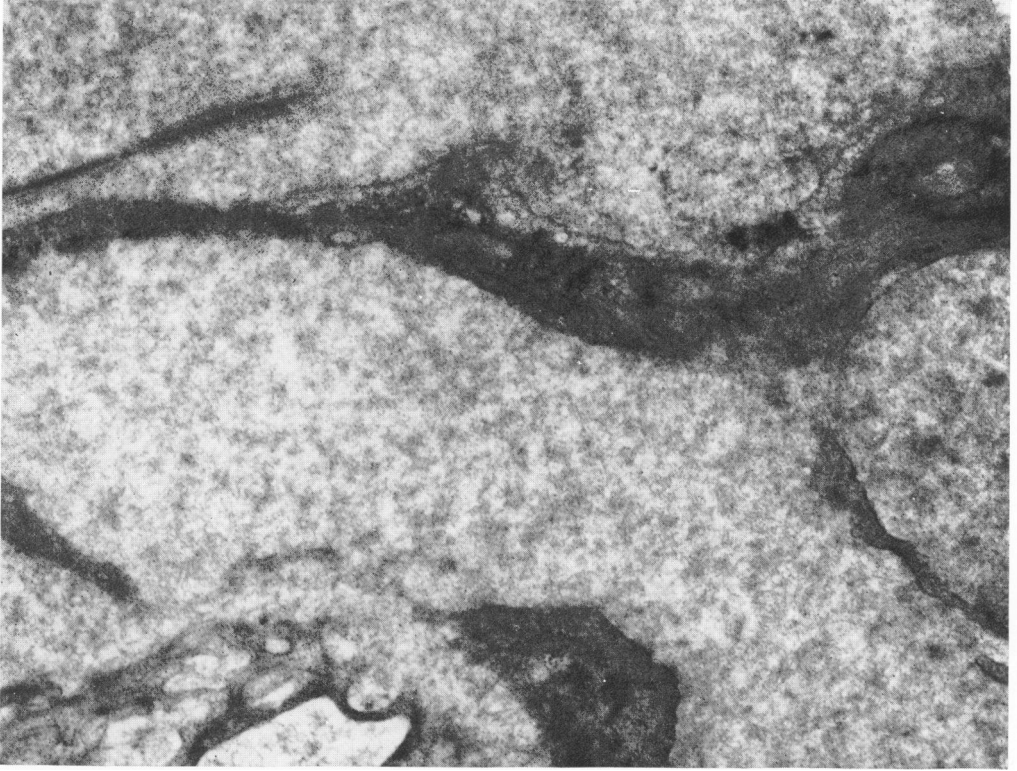


7

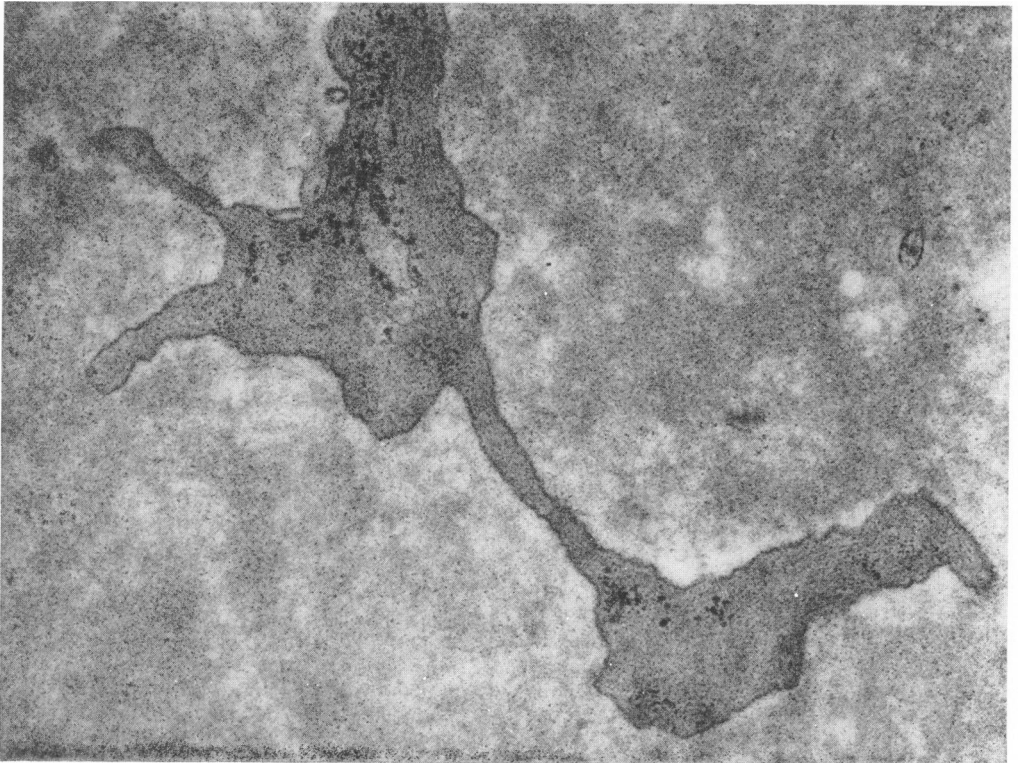
FIG. 8. The granular nature of the hyalin is evident. Portions of atrophic smooth muscle cells are present.  $\times 23,000$ .

FIG. 9. Similar to Figure 8. The granular nature of the hyalin is apparent.  $\times 53,000$ .





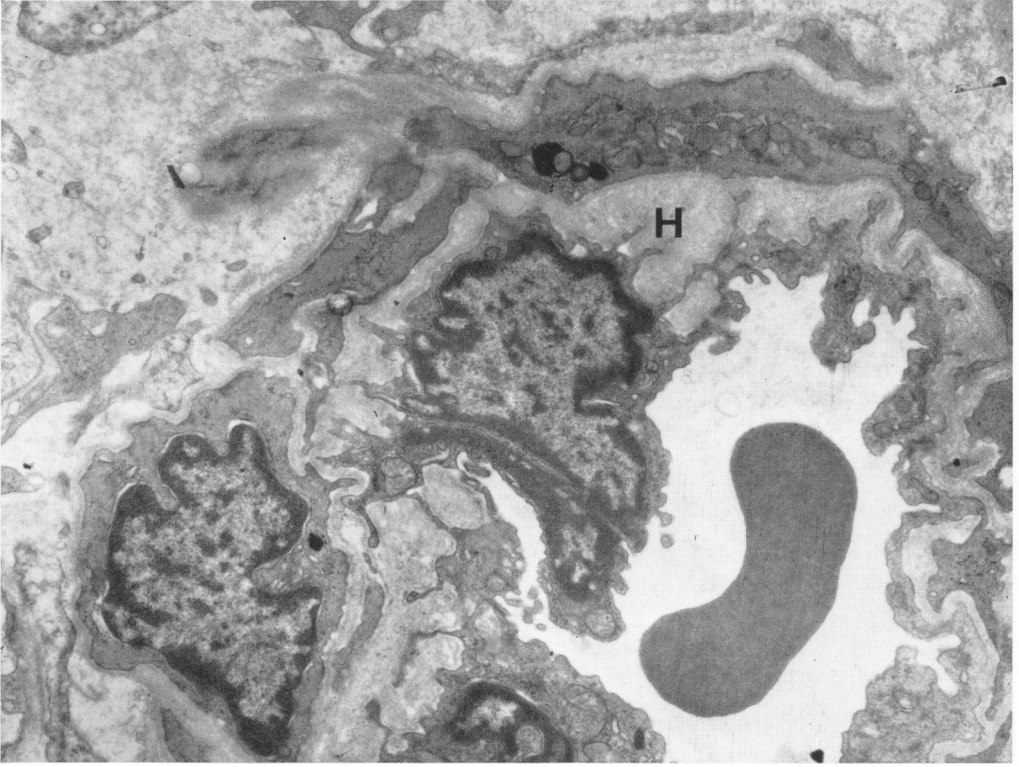
8



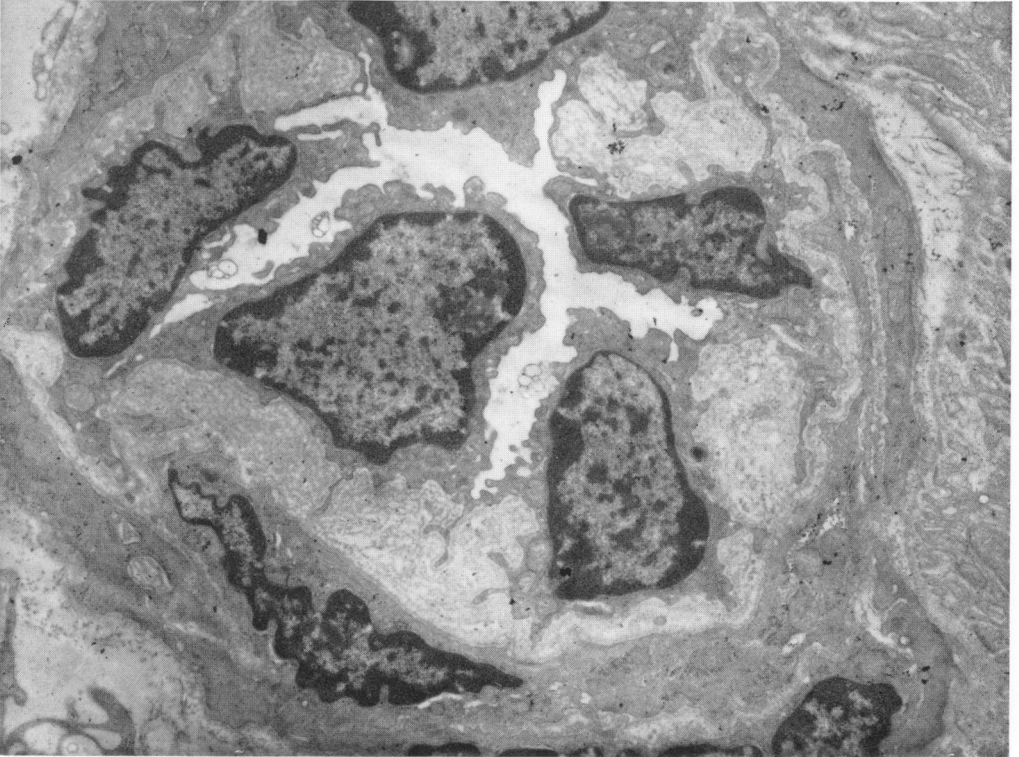
9

FIG. 10. The subendothelial space is widened and occupied by confluent deposits of hyalin.  $\times 10,000$ .

FIG. 11. The subendothelial space of this arteriole contains numerous layers of reduplicated basement membranes.  $\times 10,000$ .

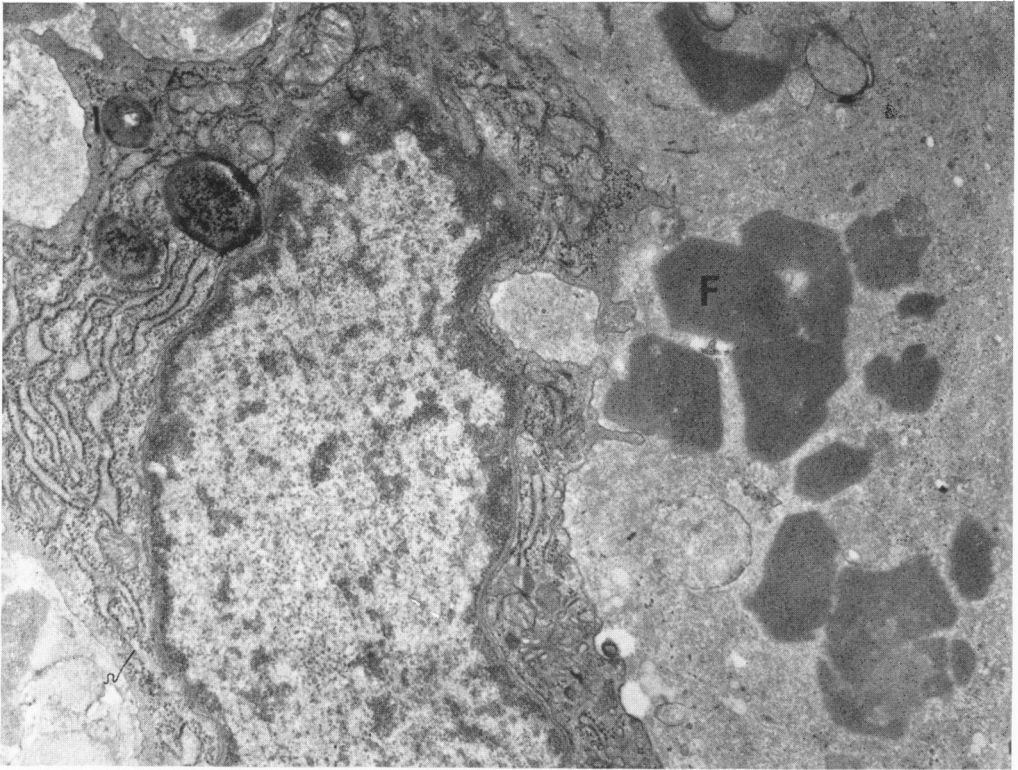


10

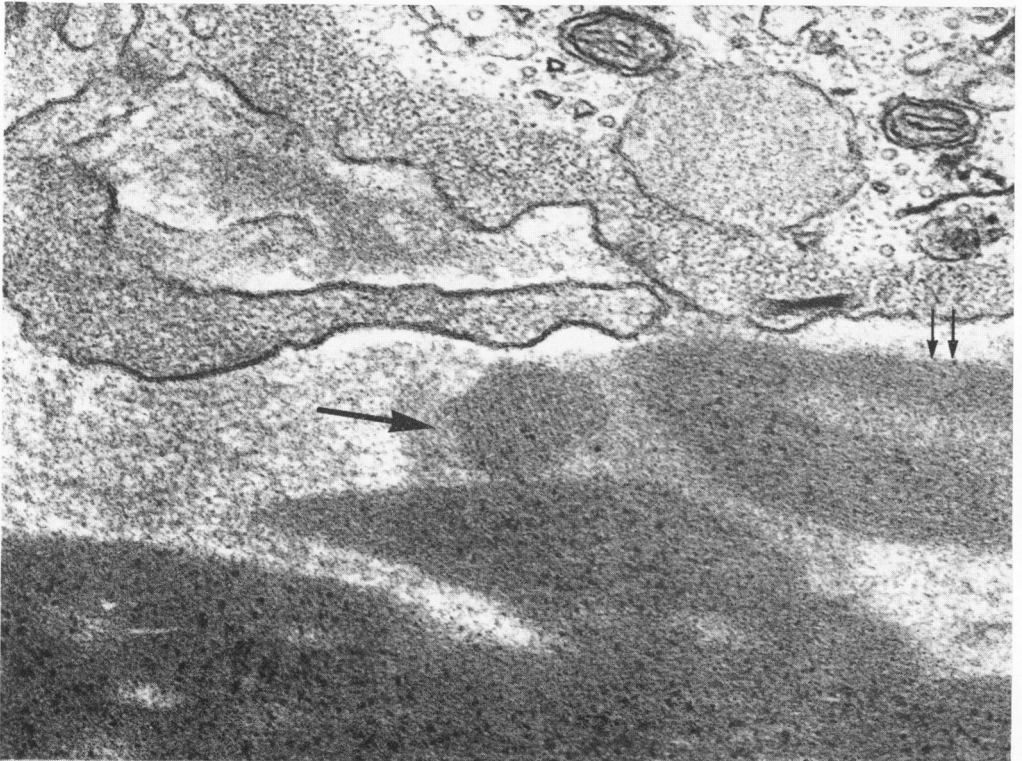


11

- FIG. 12. A number of deposits of fibrin with polygonal profiles are present within the media of a hyalinized arteriole. The adjacent cell contains abundant rough surfaced endoplasmic reticulum as well as a number of dense bodies.  $\times 22,000$ .
- FIG. 13. A higher magnification of an area similar to that shown in Figure 12. One deposit exhibits a periodicity of about  $115 \text{ \AA}$  (arrow). Longitudinal fibrils measuring about  $50 \text{ \AA}$  in diameter are seen in another deposit (double arrows). The dense granules within other fibrin deposits represent lead precipitate which is often found in association with fibrin.  $\times 81,000$ .



12

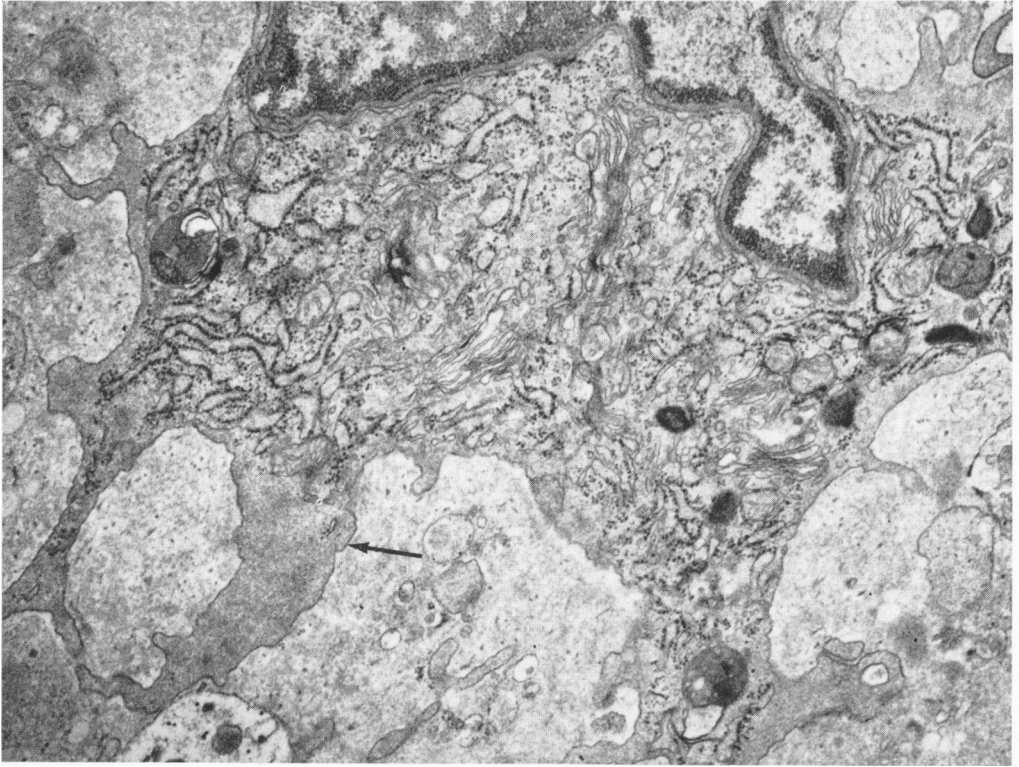


13

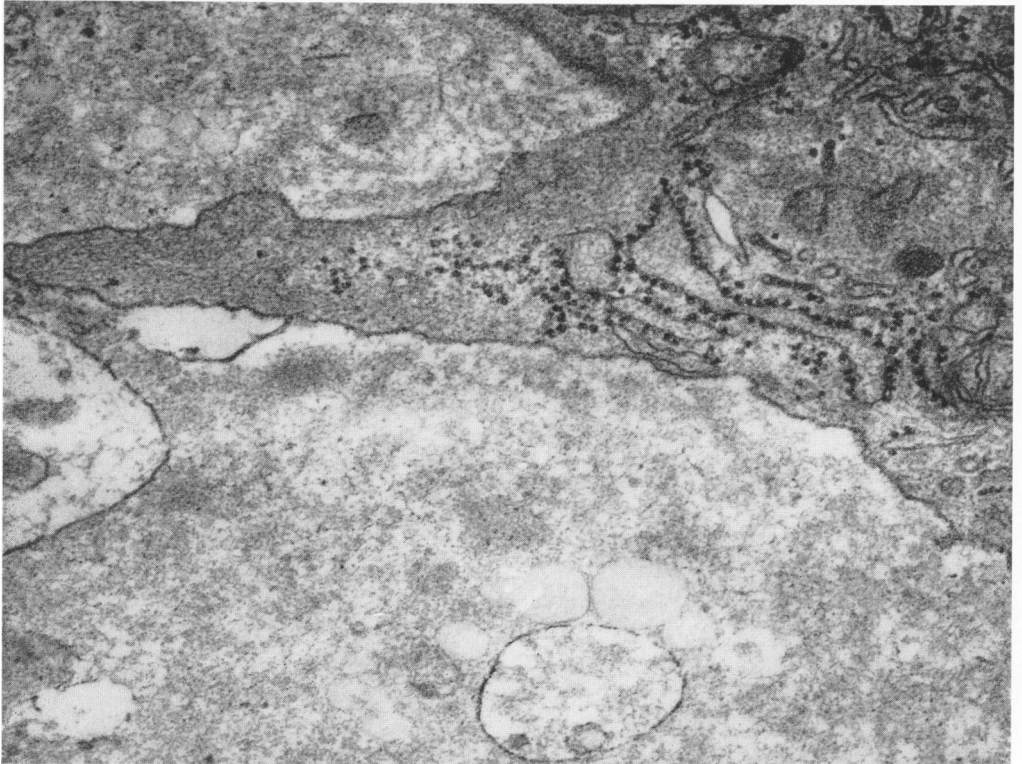
FIG. 14. This cell in the wall of a hyalinized arteriole adjacent to deposits of fibrin contains numerous organelles in the perikaryon. The cytoplasm of the processes (arrow) resembles that of smooth muscle cells.  $\times 22,000$ .

FIG. 15. A process of a cell similar to that shown in Figure 14 contains filaments resembling those of smooth muscle cells.  $\times 40,000$ .





14

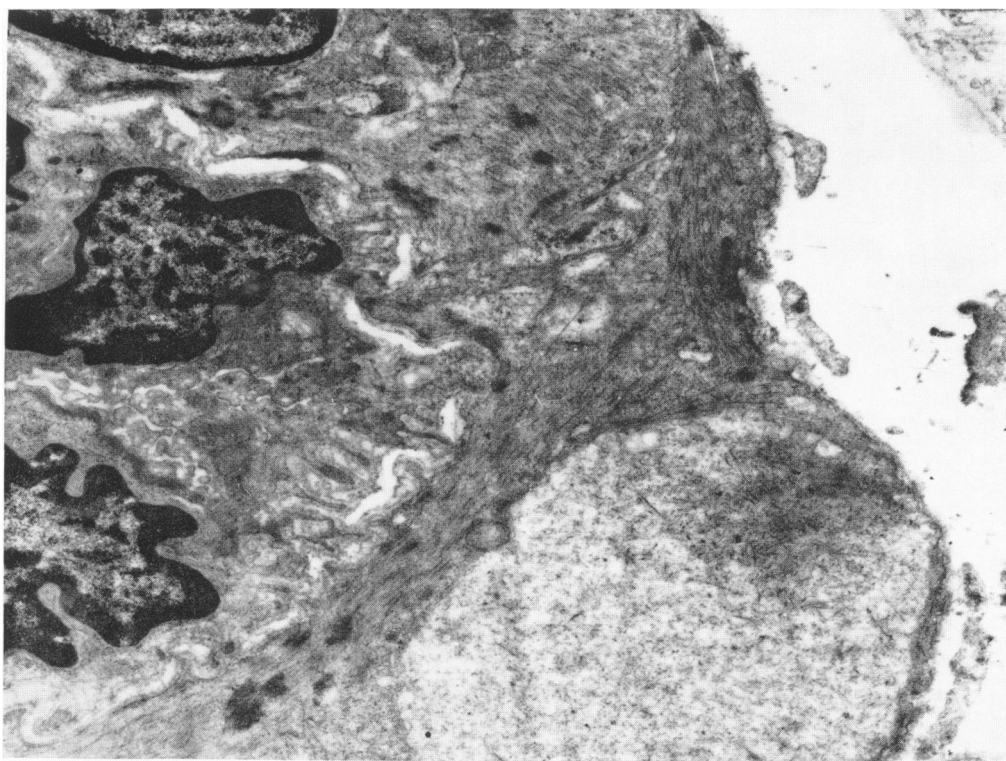


15

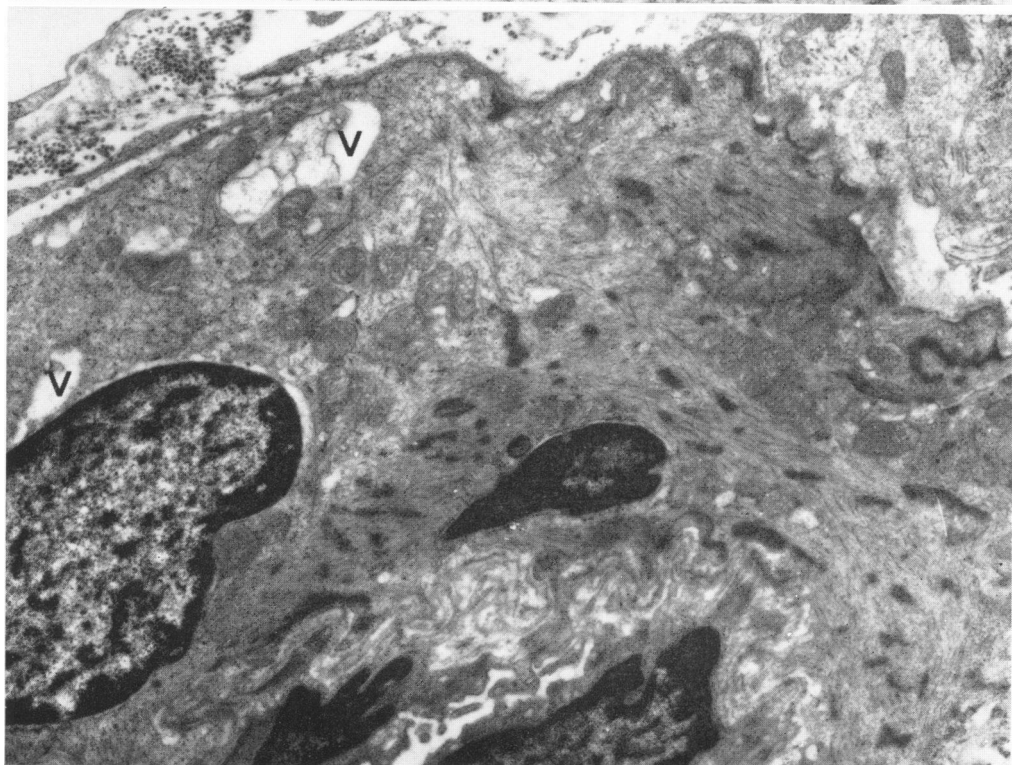
FIG. 16. A portion of the cytoplasm of a medial smooth muscle cell has a lower electron opacity and contains fewer myofilaments than the remainder of the cell.  $\times 16,000$ .

FIG. 17. Similar to Figure 16. In addition, vacuoles are noted.  $\times 16,000$ .





16



17