

## Histological Effect of Certain Pickles on the Human Gastric Mucosa:

### A Preliminary Report

W. C. MacDONALD, M.D., F.R.C.P.[C], F. H. ANDERSON, M.D.  
and S. HASHIMOTO, M.D., Vancouver, B.C.

The histological effects of several types of pickles and control substances were assessed by repeated suction (*per os*) biopsies of the gastric antrum in three healthy men. The ingestion of 30 ounces of fukujinzuke (assorted vegetables pickled in soy sauce) or of vinegared gherkins over a three-day period caused marked changes in the surface epithelium and gastric pits in all three subjects. The abnormalities consisted of loss of cellular mucus, nuclear enlargement, prominent nuclear chromatin and an increased number of mitotic figures. All control biopsies were normal, as were biopsies after the ingestion of 30 ounces of raw carrots or cucumbers over a three-day period. This study shows that eating a sufficient quantity of certain types of pickles causes marked changes in the human stomach. Peroral suction biopsy of the gastric antrum appears to be a practical method for testing the effect of various foods on the human gastric mucosa.

**T**HE mortality rates from gastric cancer<sup>1, 2</sup> and gastric ulcer<sup>3</sup> are much higher in Japan than in Canada or the United States. Japanese who migrate to other countries retain a high mortality rate from stomach cancer, although it is usually somewhat lower than in Japan.<sup>2, 4-6</sup> The Japanese who migrated to British Columbia and the state of Washington are not exceptions to this rule.<sup>7</sup> The mortality rate from stomach cancer is lower in second-generation Japanese Americans than in their first-generation parents, suggesting that it is influenced by environmental factors, possibly dietary.<sup>8</sup> Previously, we compared the dietary habits of 65 elderly Japanese Canadian men from the Greater Vancouver area with those of matched control Canadian subjects of Caucasian origin.<sup>7</sup> About 60% of the Japanese Canadian diet was Japanese in style and as expected it contained much more rice and fish and less bread, meat, milk and other dairy products than did the control diet. In addition, the Japanese Canadians ate much more pickled and salted food and very often flavoured their food with very salty soy sauce and not uncommonly with vinegar. In Japan, Hirayama<sup>9</sup> showed

On a évalué les effets histologiques de plusieurs sortes de marinades et de légumes témoins sur la muqueuse de l'antré gastrique de trois hommes sains. A cet effet, on s'est servi de biopsies en séries par succion perorale. L'ingestion de 30 onces de fukujinzuke (légumes divers dans une sauce au soja) ou de cornichons au vinaigre, sur une période de trois jours a entraîné de profondes modifications de l'épithélium superficiel et des cryptes gastriques chez les trois sujets. Ces changements consistaient en une perte du mucus cellulaire, une hypertrophie du noyau, en une augmentation de la chromatine nucléaire et en une augmentation du nombre des figures de division. Par contre, toutes les biopsies de vérification étaient normales, tout comme les biopsies effectuées après ingestion de 30 onces de carottes ou de concombres crus sur une période de trois jours. Cette étude démontre que manger une quantité suffisante de certaines sortes de marinades provoque des changements importants dans l'estomac de l'homme. La biopsie par succion perorale de l'antré gastrique est une méthode pratique pour étudier l'effet de divers aliments sur la muqueuse gastrique de l'homme.

that patients with stomach cancer ate more salted food and drank less milk than did matched control persons. In this study we have used the technique of peroral suction biopsy to assess the histological effect of various Japanese pickles on the human gastric mucosa.

#### METHODS AND MATERIAL

The subjects studied were three healthy men aged 27 to 35 years who adhered to a typical western diet and whose control biopsies from the gastric antrum were normal. The antral portion of the stomach was chosen for study because it was thought that as the substance to be tested left the stomach it would come in contact with much of the mucosa in the prepyloric area; therefore sampling errors from the antrum should be less than from the much larger area of the body and fundus. Biopsies were performed with the multipurpose biopsy tube.<sup>10</sup> Using an image intensifier control, the biopsy capsule was placed in the prepyloric region and the position confirmed by outlining the antrum with air (Fig. 1). After retrieval the biopsies were carefully oriented, promptly fixed in Bouin's solution, serially sectioned at 6  $\mu$ , and stained with hematoxylin and eosin. For final evaluation the slides were pooled and interpreted without knowledge of their origin. Biopsies were classi-

From the Department of Medicine, University of British Columbia, and the Departments of Medicine and Pathology, Vancouver General Hospital, Vancouver, B.C. Presented at the Annual Meeting of the Canadian Association of Gastroenterology, Edmonton, Alberta, June 15, 1966.

Supported by a grant from the National Cancer Institute of Canada.

Reprint requests to: Dr. W. C. MacDonald, Cytological Diagnostic Laboratory, 2656 Heather Street, Vancouver 9, British Columbia.

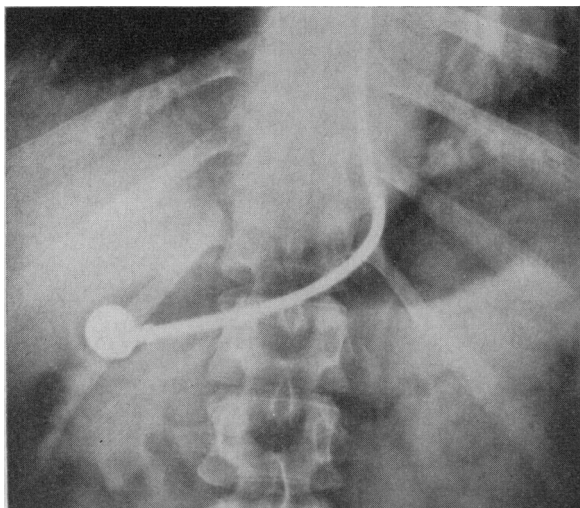


Fig. 1.—Air contrast roentgenogram of the stomach showing the biopsy capsule in the prepyloric region.

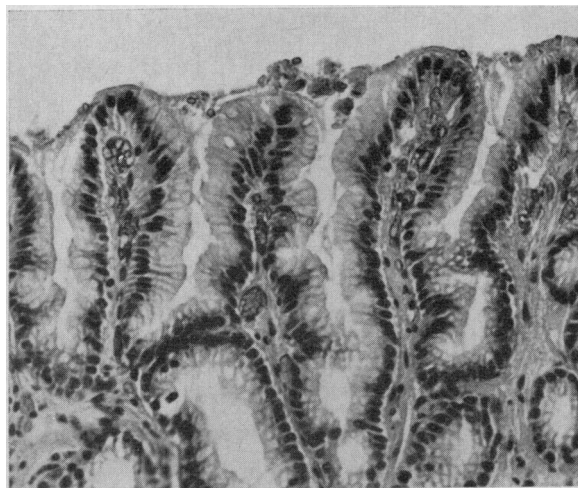


Fig. 2a.—Subject 1. Control gastric biopsy showing normal surface epithelium, pits, and necks of pyloric glands. (X 160.)

fied as being normal or showing a mild, moderate or severe reaction. Mitotic counts were done by counting the number of mitotic figures per 100 well-oriented sections of the gastric pits in each biopsy specimen. Although all the biopsies were from the antral area, about one-quarter contained gastric glands proper (fundal glands) rather than pyloric glands. This is in agreement with the findings of Heinkel *et al.* and is probably related to the tendency of the biopsy capsule to lie along the greater curvature (Fig. 1) where the gastric glands may extend to the pylorus.<sup>11</sup> Because the mitotic counts are normally higher in mucosa with pyloric glands than with gastric glands proper, the type of mucosa in each biopsy is specified in Table I.

During both the control and test periods the subjects adhered to their usual western-style diets. Control biopsies were taken at 5 p.m., four to five hours after a light lunch. The substance to be tested was eaten one to two hours after

supper and at bedtime on the first day, about two hours after each meal and at bedtime on the second and third days, and three or four times on the fourth day. Test biopsies were taken at 5 p.m. on the fourth day, four to five hours after lunch and four to six hours after the last test dose. At least two weeks elapsed between biopsies on each subject. The following substances were tested: (1) sake lees—white cucumber in rice wine mash; (2) fukujinzuke—radish, eggplant, beans, bamboo shoots and beefsteak leaves in soy sauce;\* (3) takuan—salted white radish; (4) gherkins—sweet midget gherkins in vinegar; (5) raw carrots; (6) raw cucumbers.

RESULTS

The appearance of the control and test biopsies and the mitotic counts are summarized in Table I.

\*Japanese soy sauce is made from roasted wheat and soybean fermented in brine.

TABLE I.—HISTOLOGIC APPEARANCE AND MITOTIC COUNTS OF CONTROL AND TEST BIOPSIES

Test	Subject 1		Subject 2		Subject 3	
	Biopsy appearance	Mitotic count	Biopsy appearance	Mitotic count	Biopsy appearance	Mitotic count
Control . . . . .	Normal	32	Normal x 2	13G, 14	Normal	20
Japanese meal . . . . .	Normal	68				
Fukujinzuke, 10 oz., Sake lees, 20 oz. . . . .	Normal	67				
Fukujinzuke, 20 oz., Sake lees, 10 oz. . . . .	Severe reaction	119				
Control . . . . .	Normal	32				
Fukujinzuke, 30 oz. . . . .	Severe reaction	103	Mild reaction	52G	Severe reaction	66G
Control . . . . .	Normal	6G	Normal	37	Normal	17G
Gherkins . . . . .	Moderate reaction	95	Moderate reaction	110		
Control . . . . .			Normal	25		
Salted white radish . . . . .					Equivocal reaction	65
Raw cucumbers . . . . .					Normal	21
Raw carrots . . . . .	Normal	7G				

Mitotic count = number of mitoses per 100 pit sections.  
G = antral biopsy containing gastric glands proper.

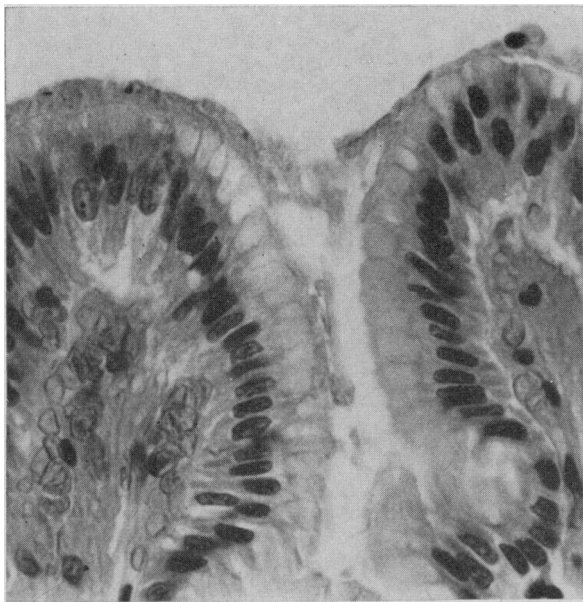


Fig. 2b.—Higher-power view of surface epithelium and pits showing mucus filled cells with regular, basally placed nuclei. (X 400.)

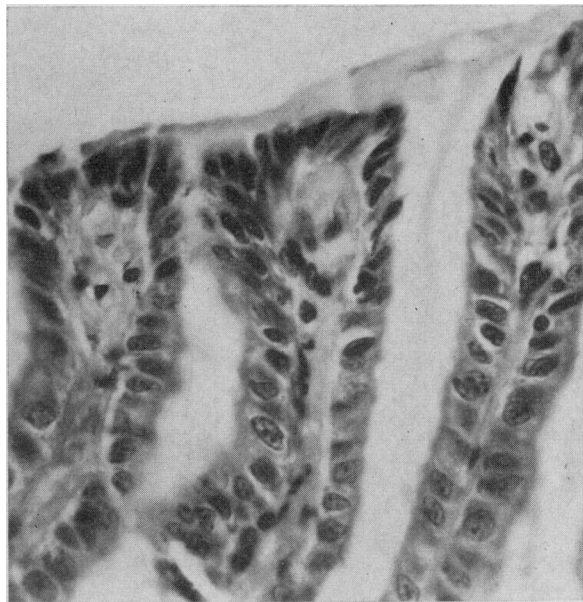


Fig. 3b.—Higher-power view of the cells of the surface epithelium and pits showing loss of cellular mucus, irregularity of size and shape of the nuclei, and prominent nuclear chromatin. (X 400.)

### Subject 1

A control biopsy was normal (Figs. 2a and b). Next, a biopsy was obtained four hours after a single meal of sukiyaki cooked in soy sauce, rice flavoured with soy sauce, two salted pickles, a serving of vinegared cucumbers and radish, and green tea. No clear-cut abnormalities of the pits or surface epithelium were seen, but the mitotic count was more than twice that of the control biopsies (Table I). A specimen obtained after the ingestion of 10 ounces of fukujinzuke (salted vegetables in soy sauce) and 20 ounces of sake lees (white cucumbers in rice wine mash) over a three-day test period also appeared normal but again the mitotic count was twice

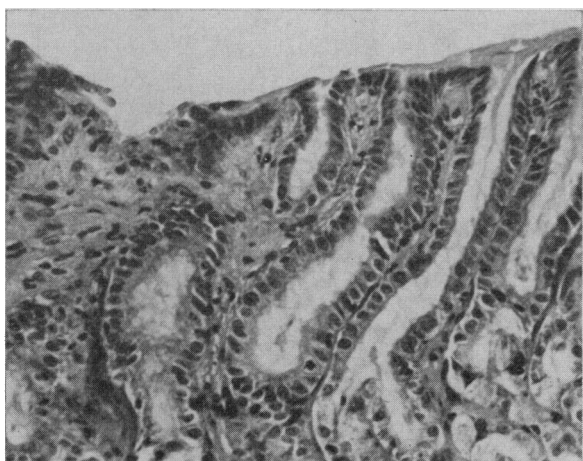


Fig. 3a.—Subject 1. Biopsy after fukujinzuke, showing distortion of the architecture of the surface epithelium and gastric pits without an increase in the inflammatory cell content of the lamina propria. (X 160.)

that of any of the control biopsies (Table I). After 20 ounces of fukujinzuke and 10 oz. of sake lees clearcut abnormalities of the surface epithelium and gastric pits were observed (Figs. 3a and b). The cells at these sites contained less mucus and were arranged in a less orderly manner than those of control biopsies. The nuclei in the neck region and in the pits were enlarged and their chromatin pattern was prominent. Some of the nuclei of the surface cells were enlarged whereas others were small and pyknotic. The mitotic count was markedly increased. No abnormalities of the glandular layer were seen and no increase in inflammatory cells was apparent. A control biopsy two weeks later was again normal. Ingestion of 30 ounces of fukujinzuke without sake lees resulted in a reaction identical with that shown in Fig. 3; a third control biopsy two weeks later appeared perfectly normal. A biopsy after eating 30 ounces of vinegared gherkins over a three-day period showed a reaction similar to, though slightly less prominent than, that illustrated in Fig. 3. Finally, the ingestion of 30 ounces of raw carrots as a control test substance caused no abnormalities (Fig. 4).

### Subject 2

Two control biopsies were normal. After the ingestion of 30 ounces of fukujinzuke a mild reaction was observed in an antral biopsy which contained gastric glands proper. The changes were similar to those illustrated in Fig. 3 but were patchy rather than diffuse. The mitotic

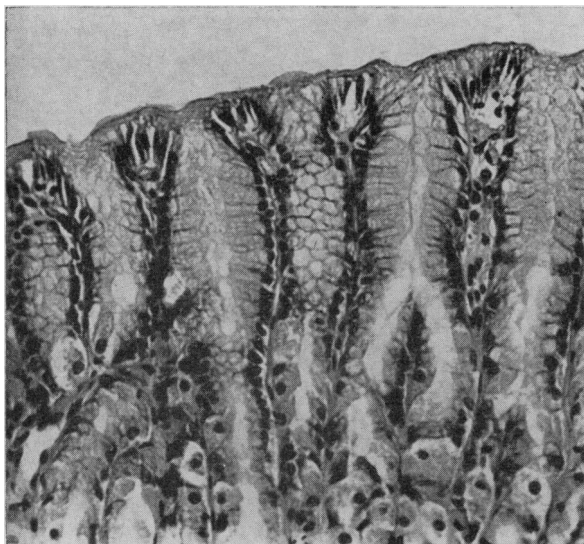


Fig. 4.—Subject 1. Biopsy after ingestion of raw carrots showing normal surface epithelium and pits. ( $\times 160$ ).

count was higher than in any of the control biopsies and four times that present in the control antral biopsies containing gastric glands (Table I). Biopsies were also obtained from the fundus of the stomach and from the duodenal bulb; these showed no differences from the control biopsies but were poor specimens and difficult to interpret. A control biopsy from the antral region two weeks later was normal. The ingestion of 30 ounces of gherkins caused a reaction similar to that shown in Fig. 3, with a marked increase in mitotic figures (Table I). A final control biopsy two weeks later was normal.

#### Subject 3

A control biopsy was normal. After ingestion of 30 ounces of fukujinzuke over the three-day test period the most severe reaction encountered in this series of experiments was observed in the antral biopsy which contained mostly gastric glands proper (Figs. 5a and b). A biopsy six weeks later showed complete reversion to normal. Ingestion of 28 ounces of salted white radish resulted in changes of an equivocal nature; that is, a reaction was not identified on "blind" review, but was strongly suspected when the specimen was directly compared with the subject's control biopsies. The mitotic count was markedly increased (Table I). Finally the ingestion of 30 ounces of raw cucumbers as a control test substance caused no abnormalities in the appearance of the epithelium or in the mitotic count.

#### DISCUSSION

Biopsies after the ingestion of the highly salted soy sauce pickle, fukujinzuke, and after the vinegared gherkins showed definite abnormalities of

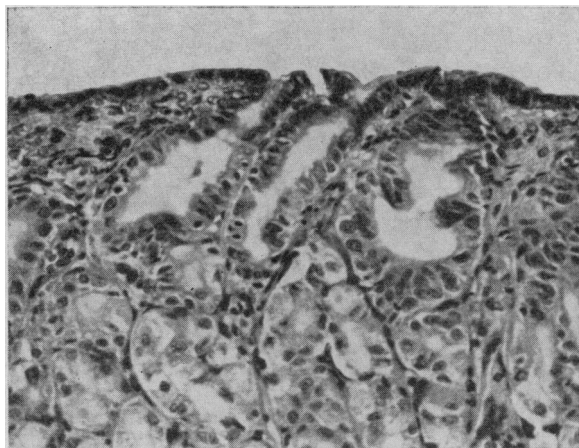


Fig. 5a.—Subject 3. Biopsy after fukujinzuke, showing marked distortion of the surface epithelium and pits with normal gastric glands beneath. ( $\times 160$ .)

the surface epithelium, pits and necks of the glands of the antral mucosa. These changes were not present in control biopsies or after the ingestion of an equal amount of raw cucumbers or raw carrots. The loss of mucus, nuclear enlargement, prominent nuclear chromatin pattern and increased number of mitotic figures observed after pickles suggest that there was a more rapid turn-over of the cells of the pits and surface epithelium, presumably in response to irritation. Mucosa containing pyloric glands or gastric glands proper appeared to be equally susceptible to injury but the glandular layer itself was not involved. Despite the prominent epithelial cell changes an increased number of inflammatory cells was not observed. Subjects 2 and 3 noticed no symptoms during the period of pickle inges-

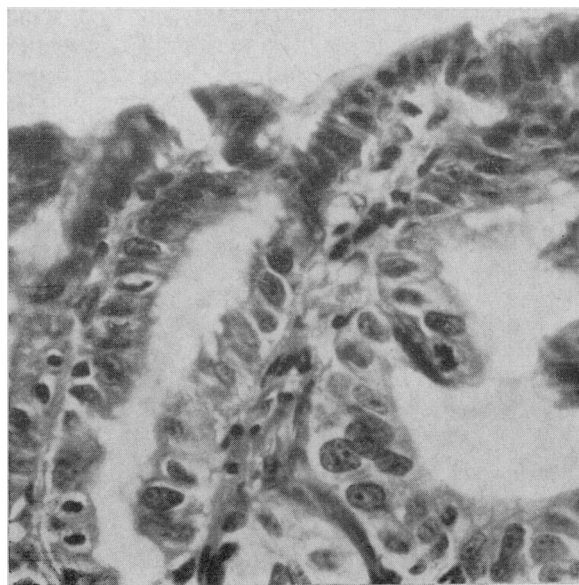


Fig. 5b.—Higher-power view of surface epithelium and pits showing loss of cellular mucus, irregularity of nuclear size and shape, prominent nuclear chromatin, and mitotic figures. ( $\times 400$ .)

tion; Subject 1 was aware of his stomach but felt no actual discomfort. The amount of pickles eaten over the three-day period was large (30 ounces); however, the ingestion of only 10 ounces of fukujinzuke with 20 ounces of the apparently innocuous sake lees, or the ingestion of a single highly salted Japanese meal caused a marked increase in the number of mitotic figures (Table I), though without clearcut epithelial changes. It is likely that smaller amounts of pickles cause abnormalities and studies are in progress to determine the minimum amount needed to produce changes visible by light microscopy.

The reaction appears to be non-specific in that both the highly salted soy sauce pickles and the sweet vinegared gherkins caused abnormalities. It is possible, however, that these very different types of pickle contain a common unidentified irritant, and it will be necessary to test the effect of vinegar and soy sauce individually. The abnormalities could be demonstrated in all three subjects, but too few studies were done to assess whether there were individual differences in susceptibility. Previously, cell proliferation and migration were studied in the human stomach by serial radioautography.<sup>12</sup> The time required for labelled cells to migrate from the bases of the pits and the necks of the glands to the surface varied greatly, from 36 hours to six days. This was in marked contrast to the uniform rate of cell migration observed in the human small bowel.<sup>12</sup> It was suggested that very minor damage to the gastric mucosa might be exceedingly common even in the absence of histological abnormalities in random biopsy specimens and that such minor damage might account for the variable migration time observed. Possibly foods such as pickles accentuate a virtually universal tendency to minor gastric damage. Not only do Japanese eat a great deal of pickles and pickled food, they liberally use flavouring substances, particularly soy sauce and vinegar. The Japanese diet as a whole may be more irritating to the human gastric mucosa than that of most people in Canada or the United States. In this study the pickles were eaten between meals. Possibly other foods protect against damage by the pickles, and foods may vary greatly in their ability to do so. The paucity of milk in the Japanese diet is of particular interest,<sup>9</sup> and studies are in progress comparing the protective effect of milk with that of other foods. It would also be of interest to compare the histological effect of pickles with that of other suspected gastric irritants, particularly alcohol and salicylates.

The long-term effect of the ingestion of pickles and the degree to which the mucosa can adapt

itself to such an insult is only speculative. Possibly the obvious alterations in cellular mucus would predispose to gastric ulceration and perhaps the prominent epithelial cell changes might predispose to the development of the so-called "atrophic gastritis" with intestinal metaplasia so often associated with gastric cancer. It would be worth while to compare the gastric biopsies of healthy middle-aged or elderly Japanese persons with those of matched Canadian control subjects; if no differences were found it would seem unlikely that the long-term ingestion of a Japanese diet resulted in significant morphological changes. The biopsies from the antral region would be of particular interest in such a study. Our experience agrees with that of Magnus<sup>13</sup> and of Glazunov, Smirnov and Yudkovskaya<sup>14</sup> and indicates that the "gastritis" associated with cancer is most often confined to the antrum and lower body of the stomach; less commonly it diffusely involves the stomach as occurs with pernicious anemia<sup>13</sup> and as has been claimed to occur with most cancers by Konjetzny<sup>15</sup> and by Hurst.<sup>16</sup>

In conclusion, this study has shown that the ingestion of 20 to 30 ounces of the highly salted pickle, fukujinzuke, or of vinegared gherkins over a three-day period caused marked changes in the surface epithelium and gastric pits of man. Carefully performed peroral suction biopsy of the gastric antrum appears to be a practical method for studying the histological effects of various foodstuffs on the human gastric mucosa.

The authors wish to thank the resident staff of the Department of Radiology, Vancouver General Hospital, for their co-operation.

#### REFERENCES

1. SEGI, M.: Cancer mortality for selected sites in 24 countries (1950-57), Department of Public Health, Tohoku University School of Medicine, Sendai, Japan, 1960.
2. HAENSZEL, W.: *J. Nat. Cancer Inst.*, 21: 213, 1958.
3. WATKINSON, G.: Geographical aspects of peptic ulcer. In: *Modern trends in gastroenterology*, third series, edited by W. I. Card, Butterworth & Co. (Publishers) Ltd., London, 1961, p. 23.
4. SMITH, R. L.: *J. Nat. Cancer Inst.*, 17: 459, 1956.
5. QUISENBERRY, W. E.: *Acta Un. Int. Cancr.*, 17: 858, 1961.
6. PRUDENTE, A. AND MIRRA, A. P.: *Ibid.*, 17: 851, 1961.
7. MACDONALD, W. C.: Gastric cancer among the Japanese of British Columbia; dietary studies. In: *Proceedings of the Sixth Canadian Cancer Research Conference, 1964*, edited by R. W. Begg, Pergamon Press, London, 1966, p. 451.
8. BUELL, P. AND DUNN, J. E., JR.: *Cancer*, 18: 656, 1965.
9. HIRAYAMA, T.: *Bulletin of the Institute of Public Health, Tokyo*, 12: 85, 1963.
10. BRANDBORG, L. L., RUBIN, G. E. AND QUINTON, W. E.: *Gastroenterology*, 37: 1, 1959.
11. ROSSETTI, M.: *German Med. Monthly*, 6: 1, 1961.
12. MACDONALD, W. C., TRIER, J. S. AND EVERETT, N. B.: *Gastroenterology*, 46: 405, 1964.
13. MAGNUS, H. A.: In: *Modern trends in gastroenterology*, first series, edited by F. A. Jones, Paul B. Hoeber, Inc., New York, 1952, p. 323.
14. GLAZUNOV, M. F., SMIRNOV, N. M. AND YUDKOVSKAYA, I. L.: *Acta Un. Int. Cancr.*, 20: 710, 1964.
15. KONJETZNY, G. E.: In: *Handbuch der speziellen pathologischen Anatomie und Histologie*, vol. 4, part 2, edited by F. Henke and O. Lubarsch, Springer-Verlag, Berlin-Göttingen-Heidelberg, 1928, p. 768.
16. HURST, A. F.: *Lancet*, 2: 1023, 1929.