

Familial Short Arm Deficiency of Chromosome 18 Concomitant with Arhinencephaly and Alopecia Congenita

IRENE A. UCHIDA, K. N. McRAE, H. C. WANG,* AND M. RAY

*Department of Medical Genetics, Children's Hospital of Winnipeg,
and Department of Paediatrics,
University of Manitoba, Winnipeg, Canada.*

SIMPLE LOSS OF PART of an autosomal chromosome was reported by de Grouchy *et al.* in 1963, who observed in a retarded child that the short arm of one of the No. 17-18 chromosomes was missing. Since the publication of this case, other instances of the same deficiency with similar clinical manifestations have been observed (Lewis, Poulding, and Woods, 1963; Bühler, Bühler, and Stalder, 1964; Summitt, 1964; Hickox, 1964; Van Dyke, Valdmanis, and Mann, 1964). Dill and Miller (1963) have found a patient with partial loss of the short arm of chromosome 18.

The cases reported here are a mother and her two children all of whom showed the same chromosomal deficiency.

OBSERVATIONS

Case Histories

Case 1. The propositus (Fig. 1a), male, born March 1962, was referred to the Out-Patient Department of the Winnipeg Children's Hospital at three months of age because of failure to thrive and ptosis. He was the second child of an unmarried, retarded mother aged 29 years. The putative father was 40 years old. The patient was delivered after an uneventful full-term pregnancy and a six hour labor, weighing 6 lbs., 8½ oz. No clinical details were recorded in the neonatal period and the child was discharged at six days of age.

Management on an outpatient basis proved unsuccessful, and he was admitted to the hospital at ten months of age for investigation of failure to thrive. Subsequently, he was admitted on six further occasions for failure to thrive, investigation of convulsions, pneumonia, and eye surgery. At two and one-half years, physical examination revealed a small but fairly well nourished boy whose weight (19 lbs., 8 oz.) and height (30") were below the third percentile. Pertinent clinical findings included normal head circumference, platinum fair hair and blue eyes, bilateral ptosis more marked on the right,

Received May 8, 1965.

Aided by a grant from The National Foundation (U. S.) and by U. S. Public Health Service grant HD 00527 from the National Institutes of Health.

*Present address: Department of Anatomy, University of Saskatchewan, Saskatoon, Saskatchewan, Canada.

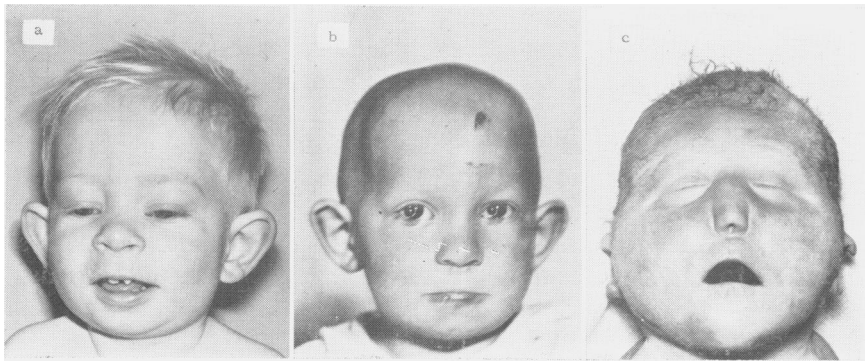


FIG. 1. The three abnormal members of the family reported here. a. Case 1, the propositus at two years; b. Case 2, the mother at 2¾ years (note alopecia); c. Case 3, cetocephalic sibling of the propositus.

epicanthus, small face, protruding mouth with receding chin, large floppy ears, high palate, marked dental caries, generalized hypotonia with normal reflexes, and mental retardation. There was a left hemiparesis with persistent tight fisting and increased tone of the left hand and marked weakness of the left face. Cardiovascular, pulmonary, gastrointestinal, and genitourinary systems were normal. Hearing and vision were within normal limits.

Investigations included estimations of protein bound iodine, serum calcium, serum phosphorus, alkaline phosphatase, blood urea nitrogen, urine for culture and sensitivity, amino acid chromatogram, sweat chloride, urine creatinine, fasting blood sugar, hemoglobin, white blood count and differential, all of which were within normal limits. Ferric chloride test, tuberculin 1 in 2000, and complete urinalysis were negative. Chest and skull X rays were negative. Bone age, although normal at three months, was seven months retarded when tested at 15 and 22 months. Electroencephalography revealed a persistent abnormality with some localization to the right hemisphere.

Repeated examination showed fairly consistent development at 65–70% of normal, in keeping with his mother's level of development. The motor development has been more retarded but is consistently improving.

Case 2. The mother (Fig. 1b) of Cases 1 and 3, was born at home in August, 1932, following a full-term gestation; she weighed 6¼ pounds. Her development in the first year was strikingly similar to her son's. She was seen as an infant in the Out-Patient Department in April, 1933, because of failure to thrive. She showed little improvement as an outpatient and was admitted to the hospital at ten months of age, weighing only 13 lbs., 3 oz.

She was described as having a large "hot cross bun" skull (head circumference 17") with parietal and frontal bossing. The only other pertinent clinical finding was a palpable spleen, 1½ cm. below the costal margin. Investigation revealed an anemia, thought to be nutritional, along with clinical and radiological evidence of rickets. The anemia responded to iron therapy, and the spleen was no longer palpable at four years of age. Her growth curve continued below the third percentile, and skeletal X rays at nine years of age showed normal bone age and no radiological abnormality.

At two years of age her hair began to fall out, and within a few months she was completely bald, with only a few hairs as eyelashes and eyebrows. Over the next 12 months she received various treatments, including quartz lamp, "deep X ray" to the head, and perandren (testosterone propionate) to the scalp, but the alopecia remained total and permanent. Dental caries frequently were noted. There was no further evidence of anemia.

Lumbar puncture, including a colloidal mastic test, at ten years of age was negative. An electroencephalogram was reported abnormal with some localization to the right hemisphere. A Binet intelligence test revealed an I.Q. of 75.

Her present height (4' 11") and weight (105 lbs.) continue to place her below the third percentile. She now wears dentures, all her teeth having been extracted at 21 years of age. The bossing of the skull remains prominent. Repeated physical examinations have shown no abnormality other than total alopecia. Her medical course has been characterized by repeated bouts of asthma, there being a strong family history of allergy.

Case 3. The first born sibling of the propositus, a female (Fig. 1c), was born in July, 1960, following an apparently normal 38 week gestation and a normal delivery. The father of this infant is unknown. At birth, the child had an Apgar rating of 3 and was noted to have cebocephaly with a single nostril, hypotelorism, and choanal atresia. The fontanels were close together and the anterior fontanel was small. There was a low-arched palate with antero-posterior fissures. The feet were inverted with dorsiflexion of the little toes.

The child deteriorated and died on the third day. Additional findings at autopsy included absence of pituitary, hypoplasia and dysplasia of the thyroid and adrenal glands, fissured spleen and accessory spleen.

Details of this case have been reported by Haworth, Medovy, and Lewis (1961).

Family History

The mother (Case 2) of the propositus had seven siblings, all reported to be normal; one brother died at five months of age following an infection of the arm, and another died recently at the age of 40 years following a heart attack. All offspring of her siblings are reported to be normal. The maternal grandparents of the propositus are of Ukrainian origin; the grandfather died at 51 years with pneumonia, and the grandmother is alive and well. The pedigree is shown in Fig. 2.

The father of the propositus, a widower with three legitimate children, is of normal intelligence. He is Scottish-French in origin. The father of the first child is unknown.

Cytology

In cultured leukocytes of peripheral blood samples obtained from the propositus, a normal number of 46 chromosomes was observed. However, the short arm of one chromosome 18 was lost. This was a consistent finding in 100 cells examined. The horseshoe shape of this chromosome made it

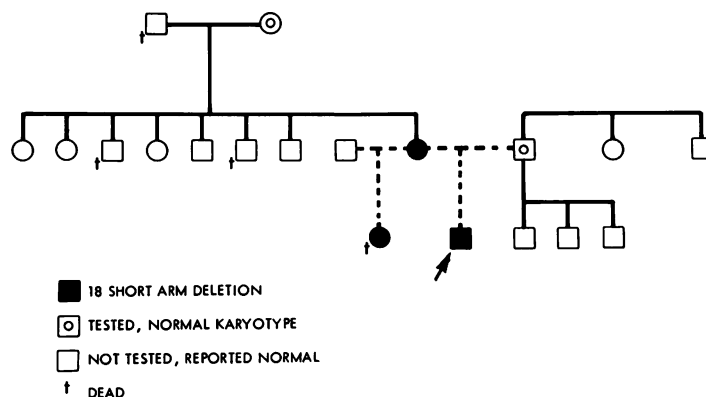


FIG. 2. Pedigree of the family reported here.

readily identifiable (Figs. 3 and 4). No other chromosomal aberration suggestive of a translocation could be identified.

The same abnormal chromosome 18 was found in most of the cells examined in the mother. Among 100 cells karyotyped, 12 were found to be normal and the rest had the deficiency chromosome 18 in a complement of 46.

The chromosomes of bone marrow cells of the mother's first child, the cebocephalic, had been examined in 1960. Our technique at that time was not refined and, although we were sure that the number of chromosomes was 46, we erred in stating that the karyotype was normal (Haworth, Medovy, and Lewis, 1961). New slides were made from cells which had been preserved in 70% alcohol. Only a few mitotic divisions were present, but it was possible to confirm our previous observation of a normal chromosome count of 46. It was not possible to do complete karyotypes because of the inferior quality of the material. However, in four cells the characteristic horseshoe shape of the deficiency chromosome 18, which was midway in size between the D and G chromosomes, was readily recognized.

The chromosomes of the father of the propositus and of the maternal grandmother were normal. The mother's siblings refused to co-operate.

Blood Groups and Serum Factors

Details of blood grouping and serum factor analyses in this family are given in Table 1. The locus for *ABO* cannot be situated on the short arm of chromosome 18 because mother and child are both A_1 while the father is *O*. The *Duffy* locus also cannot be on the deficient segment because the propositus is heterozygous for this group. Likewise the loci for *Rh*, *Hp*, and *Gm* are eliminated; this is in agreement with the findings of de Grouchy *et al.* (1963); Lewis, Poulding, and Woods (1963); Summitt (1964); and Van Dyke, Valdmanis, and Mann (1964), who have also ruled out *MN* and *Kidd*.

Dermatoglyphics

The dermal patterns of the digits, palms, and soles of the propositus, his mother, and four other patients with the same deficiency (courtesy of Dr. J.

TABLE 1. BLOOD GROUPS AND SERUM FACTORS OF PRESENT FAMILY WITH SHORT ARM DEFICIENCY OF CHROMOSOME 18

	Blood groups				Serum factors						
	ABO	MNSs	Rh	Fy	Jk	P	Hp	Tf	Gm	Inv	Gc
Father	O	<i>MsnS</i>	<i>CDe/ce(f+)</i>	a+b+	a+b+	+	1-1	C	a-b+	a-	2-2
Mother (Case 2)	A ₁	<i>MsnS</i>	<i>cDE/cE(f-)</i>	a+b+	a+b+	-	2-2	C	a+b+	a-	2-1
Propositus (Case 1)	A ₁	<i>NsnS</i>	<i>cDE/ce(f+)</i>	a+b+	a+b-	+	2-1	C	a+b+	a-	2-2
Cebocephaly (Case 3)	A		Rh+								

Parents and propositus are K-k+Kp(a-b+), Lu(a-b+), Le(a-), Xg(a+). Parents are Mi(a-), Vw-, Be(a-), Bi(a-), Go(a-), Ra-, W_r(a-), Wiel-.

Blood grouping was carried out by Miss Marion Lewis, Rh Laboratory of Winnipeg; Hp and Tf by Dr. Eloise R. Giblett, King County Central Blood Bank, Seattle; Gm and Inv by Dr. A. C. Steinberg, Western Reserve University, Cleveland; Gc by Dr. B. P. L. Moore, Canadian Red Cross Laboratory, Toronto.

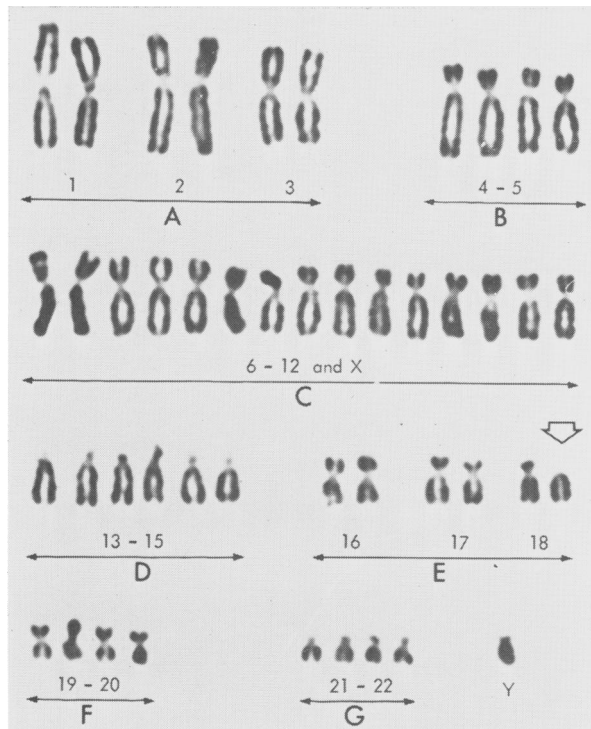


FIG. 3. Karyotype of the propositus showing deficient chromosome 18.

de Grouchy, Dr. F. J. W. Lewis, Dr. R. L. Summitt, and Dr. D. B. Hickox) were analyzed. The only observation of interest is a somewhat high total ridge count on the digits (mean = 170, mean for normals = 134). Flexion creases on the palms and digits were normal. Perhaps characteristic dermal patterns may become noticeable with an increase in sample size, but at present it appears that dermal configurations are not associated with chromosomal deficiencies to the extent that they are with trisomies.

DISCUSSION

A well documented syndrome, caused by the loss of a segment of the short arm of a chromosome in the B group (Nos. 4-5), was first described by Lejeune *et al.* (1963). The characteristic microcephaly and *cri du chat* make this syndrome clinically identifiable. On the other hand, clinical recognition of deficiency of the short arm of chromosome 18 is more difficult. There does not appear to be a specific group of clinical features diagnostic of a well delineated syndrome, although there is a vague facial resemblance that is difficult to describe. Mental retardation, short stature, dental caries, and abnormalities of the eyes and ears appear to be common factors (Table 2), but most of these also are found in other chromosomal syndromes. Late maternal age appears to be an important factor, particularly when our two inherited cases are omitted. Moreover, in this sample, there is a predomi-

TABLE 2. CHARACTERISTICS RELEVANT TO PATIENTS WITH 18 SHORT ARM DEFICIENCY

	Present Report			Lewis <i>et al.</i> 1963	Bühler <i>et al.</i> 1964	Hickox 1964	Van Dyke <i>et al.</i> 1964	Faint and Lewis 1964	Dill and Miller (partial loss) 1963
	Case 1	Case 2 (Mosaic)	Case 3						
Mental retardation	+	+	died	+	+	+	+	died	+
Short stature	+	+		-	+	+	+		-
Dental caries	+	+		+		+	+		
Abnormality of eyes	ptosis epicanthus	-	hypo- telorism	hyper- telorism epicanthus	ptosis	acentric pupils	epicanthus	hyper- telorism	hyper- telorism
Low set and/or prominent ears	+	+		+	+	+			+
Small mandible	+	-		+	+	+			
Webbed neck	-	-						+	+
Other marked pathology	-	alopecia congenita	cebocephaly	-	-	-	hypo- thyroidism	diabetes mellitus	dislocation of hip (R)
Sex	♂	♀	♀	♂	♂	♀	♀	♀	♀
Age at diagnosis	16 mos.	31 yrs.	newborn	6 yrs.	33 yrs.	5 yrs.	3 yrs.	16 yrs.	21 mos.
Maternal age (yrs.)	29	46	28	41	41	21	40	30	28
Paternal age (yrs.)	40	47	42	42	40	26	40	32	31

Blank spaces indicate unknown or not recorded.

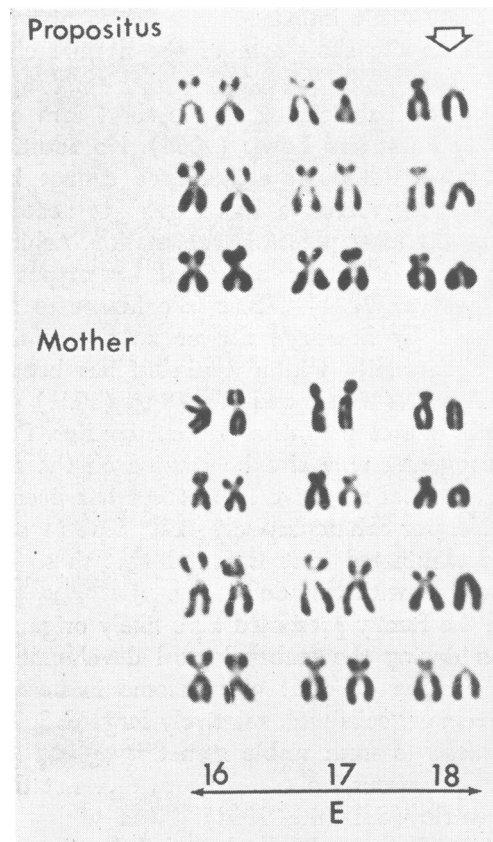


FIG. 4. Chromosomes in the E group of the propositus and his mother. Arrow indicates the deficient chromosome 18.

nance of affected females. Attempts at finding consistent characteristics are made difficult by the age spread at examination of the 11 cases.

The propositus, his sib, and mother all carry the same abnormal chromosome, but the origin of the normal chromosome 18 is different in all three, the mother having received hers from one of her parents, while the two offspring received theirs from two different fathers. It would not be surprising therefore to find certain similarities resulting from the unbalanced genetic constitution created by the deficiency and some differences relating to the genic composition of the short arm of the normal chromosome 18. Similarities in the development and appearance of the propositus and his mother as an infant have been observed, and they resemble other reported instances of 18 short arm deficiency. But the mother's alopecia and the arhinencephaly of the first child are striking abnormalities that have not been observed in the reported cases. Four possibilities could account for these anomalies: (1) they have no relation to the chromosomal picture and their presence is purely fortuitous; (2) additional chromosomal aberrations are present but undetectable; (3) these malformations are merely variants

resulting from the same genic imbalance mentioned above; or (4) hemizygous recessive genes on the short arm of the normal chromosome 18 are responsible.

Cyclopia associated with deficiency of the short arm of chromosome 18 has been observed by Faint and Lewis (1964). No additional chromosomal aberration was detected. Although coincidence cannot be ruled out, the presence of a hemizygous recessive lethal gene to account for their case and ours seems to us the most plausible explanation. Arhinencephalics without extracephalic malformations have normal karyotypes (Landau, Barry, and Koch, 1963; De Myer, 1964). There is evidence to suggest that these cases could be caused by homozygosity of an autosomal recessive gene; recurrence of this abnormality within a sibship has been reported by De Myer, Zeman, and Palmer (1963), and Klopstock (1921) described a family with two affected sibs whose parents were first cousins. Possibly a recessive gene for alopecia congenita may also be located on the short arm of chromosome 18, since autosomal recessive inheritance has been suggested (Danforth, 1925). The loci for arhinencephaly and alopecia congenita on chromosome 18 will be eliminated if it is found that these malformations are too frequently associated with this deficiency.

The deficiency in the family presented here likely originated in early postzygotic cell division during the embryological development of the mother. The presence of the same deficient chromosome in her children indicates that, in the human female, cells with relatively large deficiencies are capable of undergoing oögenesis to form viable gametes.

There has been some discussion as to whether or not the abnormal chromosome is a telocentric (Summitt, 1964). Even with the examination of a number of cells in early metaphase when the chromosomes are still fairly long, we were unable to demonstrate the presence of a remnant of a short arm.

SUMMARY

A family is presented in which a retarded mother with alopecia congenita, who is mosaic for deficiency of the short arm of chromosome 18, had two children with the same chromosomal deficiency. The first child was a cebocephalic who died shortly after birth and whose chromosomes had been erroneously reported as normal. The second is a retarded child similar in phenotype to the mother and to other known cases of 18 short arm deficiency. It is suggested that a recessive gene for arhinencephaly may be located on the short arm of chromosome 18. Possibly a recessive gene for congenital alopecia may also be located here. Other possible explanations for these malformations are given. The loci for *ABO*, *MN*, *Rh*, *Duffy*, *Kidd*, and *Lewis* blood groups and *Hp* and *Gm* serum factors have been excluded from the short arm of chromosome 18. Transmission of the deficient chromosome indicates that cells with relatively large deficiencies can undergo oögenesis to form viable gametes. Dermatoglyphic studies did not show significant departures from normal.

ACKNOWLEDGMENTS

We wish to acknowledge with thanks the assistance of Dr. J. Du in the investigation of this family. We are grateful to Dr. H. Medovy and Dr. J. Haworth for referring the cebocephalic patient to us; to Dr. J. de Grouchy, Dr. F. J. W. Lewis, Dr. R. L. Summitt, Dr. J. R. Miller, and Dr. D. B. Hickox for allowing us to examine the dermatoglyphics of their patients; to Miss Marion Lewis for the blood groupings; to Dr. Eloise R. Giblett, Dr. A. G. Steinberg, and Dr. B. P. L. Moore for the serum factor analyses; and to Mr. D. A. Gibson, F.R.P.S., for the illustrations. Colcemid was provided courtesy of Ciba Company, Dorval, Quebec.

REFERENCES

- BÜHLER, E. M., BÜHLER, U. K., AND STALDER, G. R. 1964. Partial monosomy 18 and anomaly of thyroxine synthesis. *Lancet* i: 170-171.
- DANFORTH, C. H. 1925. Studies on hair. *Arch. Derm. Syph.* 12: 195-232.
- DE MYER, W. 1964. A 46 chromosome cebocephaly, with remarks on the relation of 13-15 trisomy to holoprosencephaly (arhinencephaly). *Ann. Paediat.* 203: 169-177.
- DE MYER, W., ZEMAN, W., AND PALMER, C. G. 1963. Familial alobar holoprosencephaly (arhinencephaly) with median cleft lip and palate. *Neurology* 13: 913-918.
- DILL, F. J., AND MILLER, J. R. 1963. Personal communication.
- FAINT, S., AND LEWIS, F. J. W. 1964. Personal communication.
- GROUCHY, J. DE, LAMY, M., THIEFFRY, S., ARTHUIS, M., AND SALMON, C. 1963. Dysmorphie complexe avec oligophrénie: délétion des bras courts d'un chromosome 17-18. *C.R. Acad. Sci. (Paris)* 256: 1028-1029.
- HAWORTH, J. C., MEDOVY, H., AND LEWIS, A. J. 1961. Cebocephaly with endocrine dysgenesis. *J. Pediat.* 59: 726-733.
- HICKOX, D. B. 1964. Personal communication.
- KLOPSTOCK, A. 1921. Familiäres Vorkommen von Cyklopie und Arrhinencephalie. *Msch. Geburtsh. Gyna.* 56: 59-71.
- LANDAU, J. W., BARRY, J. M., AND KOCH, R. 1963. Arhinencephaly. *J. Pediat.* 62: 895-900.
- LEJEUNE, J., LAFOURCADE, J., BERGER, R., VIALATTE, J., BOESWILLWALD, M., SERINGE, P., AND TURPIN, R. 1963. Trois cas de délétion partielle du bras court d'un chromosome 5. *C.R. Acad. Sci. (Paris)* 257: 3098-3102.
- LEWIS, F. J. W., POULDING, R. H., AND WOODS, G. 1963. Personal communication.
- SUMMITT, R. L. 1964. Deletion of the short arm of chromosome 18. *Cytogenetics* 3: 201-206.
- VAN DYKE, H. E., VALDMANIS, A., AND MANN, J. D. 1964. Probable deletion of the short arm of chromosome 18. *Amer. J. Hum. Genet.* 16: 364-374.