

# THE AMERICAN JOURNAL OF PATHOLOGY

VOLUME XXXV

SEPTEMBER-OCTOBER, 1959

NUMBER 5

## INJECTION-CORROSION STUDIES OF NORMAL AND CIRRHOTIC LIVERS\*

MILTON R. HALES, M.D.†; JOHN S. ALLAN, M.D., and ERNEST M. HALL, M.D.

*From the Department of Pathology of the University of Southern California School of Medicine and the Los Angeles County Hospital, Los Angeles, Calif.*

Since the realization that portal hypertension was a consequence of vascular alterations within the cirrhotic liver, there have been numerous attempts to establish the nature and genesis of these vascular lesions, often with completely conflicting results. Almost a century ago, Frerichs<sup>1</sup> demonstrated by gelatin injections that in cirrhosis the hepatic venous capillaries became obliterated and the portal veins became narrowed and angular, while the hepatic arteries and the arterial bed were enlarged. He also described the development of new communications between all 3 vascular beds in the connective tissue septums. Over 60 years later, Kretz<sup>2</sup> noted that in gelatin injections and in corrosion specimens the hepatic veins were distorted and tortuous and had fewer small branches than normal. In the septums, the portal venous and hepatic arterial beds were increased, and there were new anastomoses between hepatic arteries and portal veins which, along with the obliteration of venous capillaries, contributed to the development of portal hypertension. Kretz also felt that because of the formation of similar new anastomoses between portal and hepatic veins, portal blood by-passed much of the parenchyma, and the latter was consequently supplied by hepatic arteries. A few years later, in 1907, Herrick<sup>3</sup> concluded from post-mortem perfusion studies in cirrhotic livers that there was an increased arterial inflow which, combined with an increased intercommunication between hepatic arteries and portal veins, was the most significant factor in the depression of portal venous flow and in the development of portal hypertension.

\* Supported by a grant from The Attending Staff Association of the Los Angeles County Hospital.

Presented in part at the Fifty-second Annual Meeting of the American Association of Pathologists and Bacteriologists, Houston, Texas, April 9, 1955.

Received for publication, December 29, 1958.

† Now at the Department of Pathology, Yale University School of Medicine, New Haven, Conn.

Segall,<sup>4</sup> in 1923, studied one cirrhotic liver in a series of radiopaque injections and found the hepatic arteries to be enlarged, with an extensive subcapsular arterial bed and numerous arterio-arterial anastomoses; he did not inject either venous bed.

In 1928, McIndoe<sup>5</sup> reported the results of perfusion and injection-corrosion studies which for the next two decades formed the basis of most thinking and writing on the subject. McIndoe concluded that in cirrhotic livers both venous beds were greatly distorted and reduced. As a consequence, most of the portal venous blood by-passed the liver through collaterals. Although the regenerated nodules were supplied by hepatic arteries, these vessels were not enlarged and eventually shared in the same atrophy as the veins; portal hypertension was attributed solely to venous obstruction. In 1942, Wakim and Mann<sup>6</sup> investigated the circulation in cirrhotic rat livers by a transillumination technique. They also noted that the blood supply of the regenerated parenchyma was arterial in nature, and as the cirrhotic process progressed, the venous and especially the arterial channels became tortuous. In the same year, Dock<sup>7</sup> repeated Herrick's simultaneous perfusion studies with essentially similar results. In some livers with alcoholic cirrhosis the arterial system was large and the arterial perfusibility increased. In all the examples of alcoholic cirrhosis there was increased communicability between hepatic arteries and portal veins. This, Dock thought, was a cause of portal hypertension in these cases. He suggested the possibility of lowering the high portal venous pressure by surgically reducing the arterial inflow, a procedure later to receive a disappointing clinical trial in the form of hepatic arterial ligation.

Moschcowitz,<sup>8</sup> in 1948, presented histologic evidence of anastomoses between portal and hepatic veins in cirrhotic livers, which he thought were newly formed vessels rather than persistent sinusoids. In 1950, Kelty, Baggenstoss and Butt<sup>9</sup> reconstructed a portion of a cirrhotic liver by the camera lucida technique and found that the site of vascular obstruction was on the hepatic venous side of the sinusoidal bed. The hepatic veins were displaced and flattened around regenerated pseudolobules as if by expansile pressure. Portal veins, protected by their natural sheath of connective tissue, were little affected by this process. Two years later, after they had developed a technique for estimating hepatic blood flow by application of the Fick principle to the clearance of bromsulphalein, Bradley, Ingelfinger and Bradley<sup>10</sup> were able to show that a significant reduction in total hepatic blood flow occurred in cirrhosis. This was the first direct physiologic evidence of this phe-

nomenon. By rapid serial angiography, however, Daniel, Prichard and Reynell<sup>11</sup> failed to find any impairment of speed or volume of flow of portal venous blood through cirrhotic rat livers, although sinusoidal filling was diminished and the venous trees were stunted and distorted.

In 1952, Popper, Elias and Petty<sup>12</sup> demonstrated by gelatin injections of cirrhotic livers that regenerated nodules were poorly supplied by portal venous blood. In the septums there were numerous anastomoses between portal and hepatic veins, and occasional arteriovenous anastomoses were present, mostly between hepatic arteries and portal veins. In corrosion casts of 4 cirrhotic livers, they described increased tortuosity, irregular spacing, and reduction in number of the vessels, as well as a basket-like arrangement about pseudolobules, and flattening of the hepatic veins. They postulated that the venovenous anastomoses, derived from sinusoids persisting in collapsed reticulum, diverted portal venous blood from the parenchyma and perpetuated the cirrhosis on an ischemic basis. Since the shunts were upstream from the sites of hepatic venous obstruction, they did not prevent the development of portal hypertension. The latter, incidentally, was ascribed to vascular obliteration and, possibly, transmission of arterial pressure into the venous network. The alterations subsequently noted by Mann, Wakim and Baggenstoss<sup>13</sup> in vinylite corrosion casts of cirrhotic livers were very similar to those described by Popper and his colleagues. No significant differences were seen in the cast of a liver with post-necrotic cirrhosis and one with alcoholic cirrhosis. Madden, Loré, Gerold and Ravid<sup>14</sup> reported more recently that in their neoprene casts of cirrhotic livers two patterns were observed. One, associated with chronic ascites, was characterized by an increase in the portal venous and hepatic arterial beds and a reduction in the hepatic venous bed. In the other, observed in cirrhosis without ascites or with ascites of the acute and reversible type, there was a symmetrical deficit in all of the vascular systems. In the former cases, these workers believed that the significant lesion was occlusion of hepatic veins by an obliterative fibrosis, whereas in the latter cases the hepatic venous obstruction was thought to be due to diffuse cellular edema.

From even this brief review of the more significant investigations of the vascular changes in cirrhotic livers, it is apparent that almost all conceivable alterations of the normal pattern have been reported at some time by one or more investigators: expansion of the hepatic arterial bed;<sup>1-4,7,14</sup> reduction in the arterial bed;<sup>5</sup> equal reduction in the two venous beds;<sup>1,5,11</sup> selective or more pronounced reduction in the hepatic venous bed;<sup>2,9,12,14</sup> anastomoses between portal veins and

hepatic veins,<sup>1,2,8,12,13</sup> between hepatic arteries and portal veins,<sup>1-3,7,8,12</sup> and between hepatic arteries and hepatic veins.<sup>1,12</sup> Venous obstruction was specifically attributed to the effect of fibrosis by some<sup>1,5,11,14</sup> and to expansile pressure of regenerated nodules by others.<sup>9,12,13</sup> Portal hypertension has been ascribed primarily to venous obstruction,<sup>5,11,14</sup> to transmission of arterial pressure through arteriovenous anastomoses,<sup>3,7</sup> and to a combination of these factors.<sup>2,12</sup>

It is also apparent from this historical survey that even when employing similar techniques in investigating the vascular alterations in cirrhosis, different workers have rarely made the same observations or been in entire agreement as to interpretations. Thus, even the morphologic end products of cirrhosis cannot be considered to be established until sufficient additional investigation has led to a common basis of understanding. As a contribution toward this end, the present paper reports the examination of a series of normal and cirrhotic livers by the injection-corrosion cast technique. Included in the investigation were 28 non-cirrhotic livers, 25 livers with portal cirrhosis, 6 with congestive (cardiac) cirrhosis, 3 with post-necrotic cirrhosis, and 3 with biliary cirrhosis.

#### MATERIAL AND METHODS

The technique of injection was modified from that described by Liebow, Hales, Lindskog and Bloomer<sup>15</sup> for preparation of bronchovascular corrosion casts of the lung. The injection masses were 8 to 12 per cent solutions of vinylite in acetone, usually with diatomaceous earth or lamp black added in amounts of 33 to 125 gm. per liter. Solutions were colored with appropriate acetone-soluble dyes. To insure uniformity in the injection masses used for different specimens, the viscosities were checked by viscometer just before injection. When indicated, the viscosity was adjusted by the addition of small amounts of concentrated vinylite solution or acetone.

The specimens were obtained from the necropsy service of the Los Angeles County Hospital. They were removed with the diaphragms still attached and with long segments of the inferior vena cava and the hepatoduodenal ligament. The inferior vena cava was cannulated just above the diaphragm and ligated below the liver. The portal vein, hepatic artery and common bile duct were cannulated in the hepatoduodenal ligament. While the liver was submerged in a water bath, a gentle stream of air was blown through each cannulated vessel to permit the identification and ligation of potential leaks.

In our initial studies, the vessels were first cleared of blood by perfusion with tap water and then acetone, but this procedure was later

abandoned when no beneficial effect could be demonstrated. The vinylite solutions were injected from aspirator bottles in which the desired pressure was maintained by means of a rubber hand bulb. The actual injection was completed and the plastic in small vessels partially solidified within a few minutes; blocks were then removed from the right and left lobes for subsequent histologic examination. To compensate for shrinkage of the injection masses as they solidified in the vessels, the cannulas were left attached to the aspirator bottles, under pressure, until the material in the largest vessels had become rigid (approximately 48 hours). The tissue was then digested in a large vat of concentrated hydrochloric acid, and the resultant cast was washed in running water for 24 hours, and when necessary, defatted in petroleum ether.

The masses used to fill the hepatic arterial system and the biliary ducts were made less viscid than those used in the two venous beds. In a few specimens, latex was used instead of vinylite to inject the arterial system and the biliary ducts. Although the relatively high viscosity of the vinylite solutions necessitated injection pressures 50 to 200 per cent higher than physiologic levels, extravasation was rarely encountered and was readily identifiable in the cast when it did occur. The order in which the different vessels were injected was varied from time to time, as were the injection pressures and the viscosities of the injection masses. With each of these variations in technique, normal livers were injected as standards of reference for any features observed in the abnormal livers. In each specimen, the hepatic veins and portal veins were injected at the same pressure with masses which were identical except for color.

Histologic sections were stained with hematoxylin and eosin and were graded by one of us (E.M.H.) from 0 to 4+ for the degree of fibrosis, fatty change, necrosis and regeneration. A histologic diagnosis as to the type of cirrhosis, if any, was also made. The clinical history of each patient was searched for evidence of alcoholism, dietary dyscrasia, previous hepatic or biliary tract disorder, ascites, varices or hematemesis. The necropsy protocols were reviewed for pertinent observations, including the presence of varices, ascites, splenomegaly or other possible signs of portal hypertension.

## RESULTS

### *Normal Livers*

Since excellent detailed investigations of the vascular anatomy of normal livers are available,<sup>16,17</sup> only those features need be described here which pertain to the alterations occurring in cirrhosis.

The extent and pattern of the vascular injection were remarkably uniform in all livers considered to be normal grossly and microscopically. The injection masses penetrated equally far in the portal and hepatic venous systems, terminating in vessels between 100 and 200  $\mu$  in diameter with the masses most commonly used (Figs. 1 and 7). The small branches of the two venous beds interdigitated in such a manner that portal and hepatic veins were always removed as far as possible from each other. The pattern of division generally appeared to be dichotomous in type, although very small branches also entered or left the large parent trunks, often at very nearly right angles. The latter were particularly striking with fine injections of the hepatic veins, where tiny tributaries were often sufficiently numerous that the parent trunk had a bristly, fuzzy appearance. Portal veins appeared to be end-veins; only in the bed and wall of the gallbladder did separate branches intercommunicate. On the other hand, arcade-like subcapsular anastomoses between separate small hepatic veins were not at all uncommon, especially on the posterior surface and along the sharp inferior margin. No gross anastomoses between portal veins and hepatic veins were found in normal livers.

Within the liver there was one artery accompanying each portal vein, and situated between the portal vein and the bile duct; occasionally another much smaller artery was also present which communicated with the major artery. Through similar tiny vessels in the hilum there was often communication between the right and left hepatic arteries. The vinylite arterial injection mass terminated in vessels approximately 100  $\mu$  in diameter and hence did not fill vessels of the peribiliary plexus. No arteriovenous anastomoses were ever demonstrated.

In the wall and bed of the gallbladder, portal veins formed a network of anastomosing vessels, as did the arteries. The veins and arteries closely paralleled each other, the veins usually being paired and situated on each side of the artery. Although a small cystic vein often drained along the cystic duct into a large portal vein at the hilum, most of the veins drained toward the bed of the gallbladder and emptied through several trunks into portal veins within the hepatic parenchyma. There were never any tributaries of the hepatic veins in the wall of the gallbladder.

Injection of smaller radicles of the biliary ducts was unsuccessful, presumably because their viscid content could not be evacuated or forced back into canaliculi.

### *Portal Cirrhosis*

*Hepatic Arteries.* In all of the casts of livers considered to represent portal cirrhosis grossly and histologically, there were gross alterations in the vessels. The most consistent variations from normal were enlargement of the hepatic arteries and increase in the injectable hepatic arterial bed (Figs. 2, 3 and 11). These features were observed to a minor degree even in livers with slight periportal fibrosis which could not be considered frankly cirrhotic. In severe cirrhosis, the arteries were not only enlarged but were often extremely tortuous. Instead of only one major arterial trunk accompanying each portal vein, there were usually 2 or 3 large intercommunicating arteries of nearly equal size in each portal zone.

As an indication of the magnitude of the hepatic arterial enlargement, the diameters of peripheral hepatic arteries were compared with the diameters of the adjacent portal veins. Several measurements were taken in random fields through the ocular micrometer of a dissecting microscope. Portal veins of 0.5 to 1.0 mm. in diameter were used as the standards of reference, and the relative diameters of the adjacent artery and vein were determined at this level. In normal livers the average diameter of these peripheral hepatic arteries was approximately one third that of the adjacent portal veins, whereas in cirrhosis the hepatic arteries averaged two thirds of the diameter of adjacent portal veins. In one cirrhotic liver the hepatic arteries were fully as large as the adjacent portal veins (Fig. 2). Such altered arteriovenous ratios in cirrhosis could, of course, result from a selective reduction in the diameter of portal veins rather than an increase in the diameter of hepatic arteries, but even casual inspection of the casts indicated that this was not the case. The injected portal venous bed often appeared almost as extensive as in non-cirrhotic livers, and the individual portal veins selected for measurement were not flattened and were rarely distorted. Considering also that 2 or 3 hepatic arteries of nearly equal size were often present with each portal vein, only one of which was measured, there was little question that in cirrhotic livers there was a striking increase in the total cross sectional area of the hepatic arteries.

Not only were hepatic arteries enlarged and their number in each portal zone increased, but the total injectable arterial bed was significantly expanded in cirrhotic livers (Figs. 3 and 11). This was manifested by the successful injection of the plastic into numerous *vasa vasorum* to the portal veins, small arteries enmeshing the bile ducts,

and small arteries ramifying within or beneath the capsule. In all of these sites the small arteries formed an anastomosing network. At the hilum, large communications between right and left main hepatic arteries made it possible to inject the bed of the left hepatic artery by way of the right hepatic artery, and vice versa. In one cirrhotic liver a peripheral hepatic artery communicated with a sizable diaphragmatic artery; the latter vessel was injected in retrograde manner. In the one liver examined in which the portal vein was occluded by an old thrombus, the hepatic arteries were enlarged and the arterial bed greatly expanded, but not beyond that seen in many cirrhotic livers with patent portal veins. The degree of hepatic arterial enlargement could not be shown to correlate significantly with the varying degrees of fibrosis or regeneration noted in the histologic sections, nor was it related to the weight of the liver.

With the injection mass most commonly used, the smallest arteries which were filled measured about 75 to 100  $\mu$  in diameter. In the cirrhotic as in the normal livers, no arteriovenous anastomoses were demonstrated. In a few livers, the arteries were injected with latex or with a low viscosity vinylite mass which penetrated some arteries of only 25 to 35  $\mu$  diameter. In several of the cirrhotic livers so injected, the arterial mass found its way into portal veins. Occasionally, normal livers similarly injected exhibited the same arteriovenous transfer, but to a much lesser degree. All attempts to identify the actual site of arteriovenous communication under the dissecting microscope were unsuccessful. In the histologic sections from these same livers, a few sinusoids which were dilated to 25 to 35  $\mu$  in diameter and contained the arterial injection mass were invariably found. It was thus impossible to state whether the arteriovenous communication was by way of parenchymal sinusoids or by way of vessels in the fibrous septums. At any rate, communication between hepatic arteries and portal veins seemed unduly free in cirrhotic livers, although it was apparently through vessels of minute size.

Another confirmation of the easy communication between hepatic arteries and portal veins in cirrhosis was incidentally encountered early in our studies when we were perfusing the vessels with tap water to remove the blood. As was noted by Herrick<sup>3</sup> in 1907, when the hepatic artery of a normal liver was perfused, the return of fluid was primarily by way of the hepatic vein, although there was also some return by way of the portal vein. In cirrhotic livers the reverse was usually true; the hepatic arterial perfusate was returned primarily, and sometimes exclusively, by way of the portal vein. Clamping the portal vein resulted in the development of extremely high



pressures, but still failed to increase significantly the meager return through the hepatic veins.

*Portal and Hepatic Veins.* In all of the vascular casts of livers with portal cirrhosis there was some reduction in the hepatic venous bed, and in 80 per cent of them there was also reduction in the portal venous bed (Figs. 4 and 8). Hepatic venous reduction was considered of severe degree in 60 per cent, whereas portal venous reduction was severe in only 36 per cent. Thus, in almost two thirds of the casts there was a disparity in the extent of the injection in the two venous beds, the hepatic being more severely reduced than the portal venous system. This disparity was particularly striking in 4 casts in which the portal venous bed appeared essentially normal but the hepatic venous bed was markedly restricted (Fig. 4).

Attempts at correlating the venous reduction independently with fibrosis or with the size of the pseudolobules was generally impossible because all but one of the livers with pseudolobules as large as 2 mm. also had severe fibrosis. However, in 8 of the 18 livers with severe fibrosis there were no pseudolobules over 2 mm. in diameter; 6 of these 8 livers had severe hepatic venous reduction, and 2 had severe portal venous reduction. This observation of severe venous reduction in the presence of only tiny, and usually widely separated pseudolobules suggests that fibrosis *per se*, independent of any expansile pressure from enlarging pseudolobules, had a role in the obstruction of small veins in the cirrhotic liver, and that this primarily involved the small hepatic veins. This selective effect on the small hepatic veins was well demonstrated in focal scars present in 4 specimens (Figs. 9 and 10). In these scars, histologic sections revealed only tiny, widely spaced nests of persistent hepatic parenchyma. In the casts, these zones were characterized by almost complete absence of hepatic veins, while the portal veins were not only well injected but actually appeared compacted and more numerous than normal (Figs. 5 and 6).

Although the close association of severe fibrosis and large pseudolobules made it impossible to demonstrate that vascular obliteration could be produced solely by expanding pseudolobules, there was no question of the relationship of the pseudolobules to venous distortion. All of the 12 livers with pseudolobules measuring 3 mm. or more had significant hepatic venous distortion, and in 66 per cent of these it was of severe degree. Nine of the 12 livers had significant portal venous distortion; this was severe in 4 cases. Significant distortion was rarely seen in the absence of large pseudolobules, regardless of the severity of the fibrosis. Venous distortion, like venous reduction,

was nearly always more severe in the hepatic veins than the portal veins; in only 2 livers was the distortion of portal veins considered equal to or greater than that of the hepatic veins. Under the dissecting microscope, the small distorted hepatic veins often appeared to have been abruptly flattened and displaced to the side, as if by pressure of a small expanding mass of tissue (Fig. 12). There was striking similarity to the appearance of the hepatic veins in the camera lucida reconstruction of Kelyt and co-workers.<sup>9</sup>

A marked degree of fatty alteration was present in only 5 of the 25 livers with portal cirrhosis; 6 others had a slight amount, and the other 14 had minimal or no fat. That fat was not essential to venous reduction was indicated by the fact that 8 of the livers with severe hepatic venous reduction had minimal or no fat. Fatty change may contribute to vascular obstruction, however, as Himsworth<sup>18</sup> has contended. The two livers in which the degree of hepatic venous reduction seemed excessive for the degree of fibrosis or nodularity were severely fatty.

The weight of the livers correlated with the degree of fibrosis, the size of the nodules, and the severity of the venous reduction. Of the 8 livers weighing less than 1,400 gm., all had marked fibrosis, 7 had nodules larger than 2 mm., 7 had marked hepatic venous reduction, and 5 had marked portal venous reduction. Of the 12 livers with cirrhosis, weighing over 2,000 gm., only 6 had marked fibrosis, 5 had nodules larger than 2 mm., 4 had severe hepatic venous reduction, and only 1 had severe portal venous reduction.

In the cases of portal cirrhosis there did not appear to be any correlation between the disparity in venous reduction and the presence of chronic ascites, as reported by Madden and his colleagues.<sup>14</sup> Half of the patients with a disparity in the extent of the injection in the two venous beds did have evidence or history of chronic ascites, but the other half either had no ascites or developed ascites terminally for the first time.

*Venovenous Anastomoses.* Since the masses injected into the venous beds were relatively viscid, the casts indicated the presence or absence of only sizable communications between separate veins. As a consequence of the disproportionate reduction in the hepatic venous bed in cirrhosis, gross anastomoses (0.1 to 1.0 mm.) were present between separate hepatic veins in only 28 per cent of the cirrhotic livers compared with 46 per cent of the non-cirrhotic specimens. Anastomoses between separate portal veins were present in 4 (16 per cent) of the cirrhotic livers, but were present in only 2 (7 per cent) of the non-cirrhotic livers; both of the latter were small and atrophic, although

otherwise unremarkable. Gross anastomoses between portal veins and hepatic veins were present in only 2 (8 per cent) of the cirrhotic livers, one of these being an atypical portal cirrhosis in a patient with severe, prolonged and untreated hyperthyroidism. Such portal-hepatic vein anastomoses were also present in 2 non-cirrhotic livers with severe passive congestion, and in focal transverse bands of subcapsular atrophy and fibrosis in 2 otherwise unremarkable livers. In one of the latter and in the case of "thyrotoxic cirrhosis," some of the anastomoses measured over 1 mm. in diameter (Fig. 15). Remarkable dilatation of the venous trunks supplying and draining the anastomoses indicated an appreciable shunt of blood through them during life.

*Intrahepatic Collaterals.* In the casts of cirrhotic livers, there was consistent enlargement of certain veins communicating between intrahepatic branches of the portal vein and branches of the systemic venous system. Although measurements indicated no consistent dilatation of the main portal vein, the small veins which normally run in the *porta hepatis* and communicate with portal veins within the liver were often appreciably dilated. In most examples of cirrhosis there was a venous trunk extending from the left portal vein into the falciform ligament in the normal course of the umbilical vein. Although a tiny similar vessel was occasionally injected in a non-cirrhotic liver, in cirrhosis it was usually present and was of appreciable size. Indeed, in 4 casts such vessels measured over 5 mm. in diameter (Figs. 11 and 13). In only 1 of these 4 cases was a diagnosis of Cruveilhier-Baumgarten syndrome made clinically.

In addition to these vessels representing patent and dilated umbilical veins, there was often an entirely separate group of collateral vessels entering the falciform ligament. These were usually multiple, and while occasionally arising from the left portal vein near the normal entrance of the umbilical vein, they more often took origin from distal portal veins at the anterior margin of the liver (Fig. 14). Portal veins there failed to diminish in caliber as the capsule was approached and continued into the falciform ligament after a short tortuous course near or in the capsule. These vessels were often of appreciable size, measuring in 2 cases over 5 mm. in diameter. In normal livers there were often tiny extensions into the falciform ligament from adjacent peripheral portal veins, and it was presumably from these that the large para-umbilical collaterals developed in cirrhosis. Because of their empty, collapsed state, such collaterals were rarely recognized at necropsy unless specifically sought.

Diaphragmatic veins were often injected from the inferior vena cava, along with the hepatic veins. They sometimes seemed unusually

numerous and dilated, but they never established gross communications with either portal or hepatic veins in portal cirrhosis. In only one example of portal cirrhosis were communications demonstrated between intrahepatic branches of the hepatic arteries and arteries outside the liver; a very fine arterial injection disclosed communications between capsular branches of the hepatic artery and diaphragmatic arteries, the latter being injected in retrograde fashion. None of the cases investigated had had surgical ligation of the hepatic artery.

#### *Post-necrotic Cirrhosis*

Although none of the livers examined had the classical gross appearance of the "lobar" type of post-necrotic cirrhosis, 3 cases had microscopic features and clinical histories suggestive of a post-necrotic origin and were so classified. In another 3 cases, alcoholism and dietary dyscrasia were specifically and reliably denied by the patients, but since in these 3 the livers were grossly and histologically indistinguishable from portal cirrhosis, they were included in the latter group. Whether or not this was justified is of little importance in the present study since the casts of all 6 differed in no significant manner from the other instances of portal cirrhosis in patients with a strong history of alcoholism or dietary dyscrasia.

#### *Congestive Cirrhosis*

Six livers studied were considered to have the microscopic features of congestive or cardiac cirrhosis. In 5, central and portal fibrosis was minor, there was minimal lobular distortion, and the vascular pattern in the casts differed from that of normal livers only in dilatation of the hepatic veins and slight arterial enlargement. One liver, however, from a patient with tricuspid insufficiency, had severe cirrhosis with significant fibrosis and even pseudolobule formation. In this case, hepatic arteries were large, the hepatic veins were remarkably dilated, and the hepatic venous bed was more extensively filled than the portal venous bed (Fig. 16). On the diaphragmatic surface communications were present between hepatic veins and diaphragmatic veins, and between enlarged hepatic arteries and diaphragmatic arteries. A striking lesion in this instance consisted of large para-umbilical collateral branches of the portal veins entering the falciform ligament at the sharp anterior margin of the left lobe. Portal hypertension in this case was not solely a reflection of high systemic venous pressure, but was sufficiently augmented by intrahepatic venous obstruction that collateral pathways had developed to by-pass this obstruction.

### *Biliary Cirrhosis*

One of the 3 cases of biliary cirrhosis had extreme focal dilatation of biliary ducts. In these sites the hepatic arteries were enlarged, the hepatic veins completely absent, and the portal veins markedly distorted and reduced in size and number. The 2 other specimens, from patients with portal hypertension, also manifested hepatic arterial enlargement but were especially remarkable for the fact that the portal venous reduction was more severe than that of the hepatic venous bed. Many portal veins were abruptly obliterated in a segmental fashion as if by thrombosis, and their distal segments were injected in retrograde manner from collateral communications with adjacent unobstructed portal veins. This observation correlated well with the presence of thrombophlebitis of small portal veins observed microscopically in these livers. MacMahon<sup>19</sup> has commented on the frequency of thrombophlebitis of small portal veins complicating cholangitis. Incidentally, similar obstructions of portal veins, with distal collateral communications, were observed in the walls of large congenital cysts present in two otherwise normal livers.

### DISCUSSION

The vascular alterations in the casts of livers with portal cirrhosis support the concept that the initial venous obstruction in this disorder is in the small hepatic veins rather than in the portal veins. In a majority of such casts, hepatic venous reduction was more severe than portal venous reduction, and in some, the portal venous bed was little if at all altered. The observation that large pseudolobules were invariably associated with distortion and often with flattening of the hepatic veins indicates that the expansile pressure of regenerating nodules may well be a factor in the venous obstruction, as originally proposed by Kelty and his associates.<sup>9</sup> However, there was an impressive independent relationship between fibrosis *per se* and reduction of the hepatic venous bed in our casts of cirrhotic livers. This was especially apparent in broad scars devoid of pseudolobules, where the hepatic venous bed was restricted invariably and profoundly.

How fibrosis results in obliteration of the small veins, and especially the small hepatic veins, is not known. The force exerted by the contraction of maturing collagenous fibers may be the responsible agent, just as it is responsible elsewhere for the vascular obliteration in granulation tissue as the latter becomes converted into avascular scar. Whatever the mechanism of venous obstruction, whether by expansile pressure of regenerating nodules or by contraction of septal connective

tissue, the hepatic veins are much more susceptible than the portal veins. The latter may be afforded some protection by their natural sheath of periportal connective tissue.

We could not escape the impression that as the cirrhotic process became more severe, the degree of portal obstruction tended to approach or equal the degree of hepatic venous obstruction, and that this was the reason for the apparently equal venous reduction noted in some cases. Other examples of equal reduction of the two venous beds, however, appeared to be instances of relatively early cirrhosis and must be explained on another basis. As Phillips and Davidson<sup>20</sup> have noted, individuals dying of early cirrhosis often have severely fatty livers and acute parenchymal necrosis. In our casts of early cirrhosis it is likely that the observed venous reduction was a reflection of sinusoidal obliteration by the swollen, fatty and necrotic parenchymal cells. For a successful vascular injection, it is essential that there be a reservoir of sinusoids or capillaries to receive the blood and air displaced from larger vessels by the injection mass. In livers with early, fatty cirrhosis this sinusoidal reservoir must be appreciably reduced.

Our coarse injections did not fill vessels of the size of the anastomoses which Popper, Elias and Petty<sup>12</sup> found so numerous in their delicate gelatin injections of cirrhotic livers. We did, however, demonstrate gross anastomoses of this type in two of the cirrhotic livers. Surprisingly, we also encountered them in two livers with severe chronic passive congestion and in two others with only focal zones of subcapsular atrophy and fibrosis. These observations are in perfect accord with the conclusion of Popper and his colleagues that such venovenous anastomoses represent dilated sinusoids persisting in collapsed reticulum. Although our casts demonstrate that these anastomoses may on occasion attain macroscopic size, in most cirrhotic livers they must either be very small, or infrequent, or, as Popper suggests, "upstream" from the site of hepatic venous obstruction; otherwise, cirrhosis would not be complicated by portal hypertension.

The enlargement of hepatic arteries, with expansion of the arterial bed, is in conformity with the observations of both the older and more recent investigators. Dock<sup>7</sup> and Madden and co-workers<sup>14</sup> have made similar observations, although inconstantly. On a theoretical basis, such enlargement should be expected, for there is evidence in other studies that regenerated pseudolobules are supplied primarily by arterial blood.<sup>2,3,6</sup> The connective tissue of the fibrous septums must also be supplied by hepatic arteries, since arterial enlargement is almost as conspicuous in broad scars essentially devoid of paren-

chyma as in regions of closely grouped pseudolobules. Indeed, arterial enlargement is even evident in livers with portal fibrosis but without lobular distortion or true cirrhosis. Increased intercommunication between hepatic arteries and portal veins has been described in several reports, and Popper and his associates<sup>12</sup> claim to have demonstrated true arteriovenous fistulas anatomically by gelatin injection. In other organs, arteries supplying even tiny arteriovenous fistulas are enlarged as a reflection of their increased flow. This might well be another factor contributing to hepatic arterial enlargement in cirrhotic livers. A final explanation for the arterial enlargement concerns the entire adjustment of parenchymal circulation that must occur in sites where and when small hepatic veins are selectively obliterated. Circulation there must utilize the only available venous bed, that of the portal veins, for efferent flow, and hence must rely solely on hepatic arteries for the afferent supply to the parenchymal sinusoids. Thus, in regions where hepatic veins are obstructed, arterial blood, after traversing the parenchymal sinusoids, must flow in retrograde manner in portal veins. It may then be shunted into extrahepatic collaterals of the falciform ligament, into anastomoses between portal veins and hepatic veins, or into sinusoids in regions where hepatic veins still persist and drain parenchyma.

The blood supply of the parenchyma in sites of hepatic venous obliteration must resemble that of the gallbladder, being supplied solely by the hepatic arteries and drained solely by portal veins. The possibility of localized retrograde flow has been suggested by others.<sup>21-23</sup> In casts with large regions essentially devoid of small hepatic veins, yet with a fairly well preserved portal venous bed and an expanded arterial bed, the conclusion is inescapable that the portal veins must be functioning as efferent channels for the blood supplied to the parenchyma and the connective tissue by the hepatic arteries. It is doubtful if such retrograde flow in the portal veins often involves the entire liver or extends to the main portal vein. There is, however, at least one case on record in which the latter phenomenon was noted at operation for the surgical treatment of portal hypertension.<sup>21</sup>

The hepatic arterial enlargement and the expansion of the arterial bed in cirrhosis indicate that the ratio of hepatic arterial to portal venous blood flow in the cirrhotic liver must be appreciably higher than the 1:3 figure generally accepted for the normal liver, but how much so is unknown and must vary appreciably from case to case. From the change in estimated hepatic blood flow following portocaval shunting procedures, Bradley, Smythe, Fitzpatrick and Blakemore<sup>24</sup> concluded that approximately 75 per cent of the blood flow to the

cirrhotic liver was from the hepatic artery. This was the average figure, and the range was extremely broad. Myers<sup>25</sup> arrived at a similar figure in one of the cases he studied by a sulfathiazole dilution technique.

McIndoe<sup>5</sup> estimated from his perfusion studies that at least 87 per cent of the portal venous blood by-passed the cirrhotic liver through portocaval collaterals. This figure, combined with more recent evidence that total hepatic blood flow in cirrhotic patients is about two thirds normal,<sup>10</sup> would also indicate that the major blood supply to the cirrhotic liver is from the hepatic arteries. Although these and other observations<sup>3,7</sup> support the morphologic evidence of an increased arterial blood supply to the cirrhotic liver, actual determination of the degree of arterialization must await the development of a reliable technique for measuring relative arterial and portal venous blood flows in normal patients, those with cirrhosis, and experimental animals.

If the hypothesis is correct that because of the obliteration of small hepatic veins the cirrhotic liver primarily becomes an arterial organ, then the treatment of portal hypertension by hepatic arterial ligation is obviously an entirely nonphysiologic procedure, saved from higher morbidity and mortality by the remarkable ability of the hepatic arteries to develop new collateral supplies. Similarly, any attempt to increase hepatic blood flow in cirrhosis by arterializing the portal vein, as is being presently contemplated by some,<sup>26-30</sup> may be destined to equally costly failure. Such a procedure may increase the circulation to those regions where parenchymal sinusoids are still drained by hepatic veins. But in sites where hepatic veins have been obliterated and an active parenchymal circulation is maintained only by means of retrograde flow in portal veins, arterialization of the portal vein must decrease rather than increase the supply of blood to the hepatic cells. Should such regions of arterial-parenchymal-portal circulation be extensive, arterialization of the portal vein might be disastrous, decreasing rather than increasing total hepatic blood flow. Indeed, it seems likely that in the normal course of cirrhosis it is the elimination of this retrograde portal venous flow by obliteration of the small portal veins that is responsible for the increasing circulatory impairment and functional insufficiency in the final stages of the disease.

#### SUMMARY

An investigation of injection-corrosion casts of a large series of normal and cirrhotic livers revealed consistent enlargement of the hepatic arteries and arterial bed in cirrhosis, with an increased inter-



communication between hepatic arteries and portal veins. The venous beds were reduced and often distorted, these effects being most pronounced in the hepatic veins. Venous reduction was often associated with fibrosis, in the absence of any possible compressive effect from expanding pseudolobules. Occasionally, gross anastomoses were demonstrated between portal veins and hepatic veins in cirrhotic livers; they were also seen in some livers with severe chronic passive congestion, and in livers with focal bands of subcapsular atrophy and fibrosis. Umbilical and para-umbilical collaterals were surprisingly large and frequent in portal cirrhosis.

No significant differences were noted in the vascular pattern of portal and post-necrotic cirrhosis. In biliary cirrhosis, portal venous obstruction was often more severe than hepatic venous obstruction, presumably because of portal thrombophlebitis secondary to recurrent cholangitis. Congestive or cardiac cirrhosis was associated with dilatation of large hepatic veins, and, in one case with severe cirrhosis, with large para-umbilical collateral veins.

The possible genesis and physiologic effects of the vascular alterations in portal cirrhosis are discussed, including the probability of local retrograde flow of blood in the portal veins in sites where the parenchymal circulation is purely arterial in nature. It is suggested that these observations contraindicate surgical ligation of the hepatic artery or arterialization of the portal vein in the treatment of portal hypertension due to cirrhosis.

#### REFERENCES

1. Frerichs, F. T. A Clinical Treatise on Diseases of the Liver. Murchison, C. (trans.). The New Sydenham Society, London, 1861, Vol. 2, pp. 28-30.
2. Kretz, R. Lebercirrhose. *Verhandl. deutsch. path. Gesselsch.*, 1904, 8, 54-59.
3. Herrick, F. C. An experimental study into the cause of the increased portal pressure in portal cirrhosis. *J. Exper. Med.*, 1907, 9, 93-104.
4. Segall, H. N. An experimental anatomical investigation of the blood and bile channels of the liver; with special reference to the compensatory arterial circulation of the liver in its relation to surgical ligation of the hepatic artery—report of a case of arteriosclerotic aneurysm of the gastroduodenal artery. *Surg. Gynec. & Obst.*, 1923, 37, 152-178.
5. McIndoe, A. H. Vascular lesions of portal cirrhosis. *Arch. Path.*, 1928, 5, 23-42.
6. Wakim, K. G., and Mann, F. C. Effect of experimental cirrhosis on the intra-hepatic circulation of blood in the intact animal. *Arch. Path.*, 1942, 33, 198-203.
7. Dock, W. The rôle of increased hepatic arterial flow in the portal hypertension of cirrhosis. *Tr. A. Am. Physicians*, 1942, 57, 302-306.

8. Moschcowitz, E. Laennec cirrhosis; its histogenesis with special reference to the role of angiogenesis. *Arch. Path.*, 1948, 45, 187-215.
9. Kelty, R. H.; Baggenstoss, A. H., and Butt, H. R. The relation of the regenerated liver nodule to the vascular bed in cirrhosis. *Gastroenterology*, 1950, 15, 285-295.
10. Bradley, S. E.; Ingelfinger, F. J., and Bradley, G. P. Hepatic circulation in cirrhosis of the liver. *Circulation*, 1952, 5, 419-429.
11. Daniel, P. M.; Prichard, M. M. L., and Reynell, P. C. The portal circulation in experimental cirrhosis of the liver. *J. Path. & Bact.*, 1952, 64, 53-60.
12. Popper, H.; Elias, H., and Petty, D. E. Vascular pattern of the cirrhotic liver. *Am. J. Clin. Path.*, 1952, 22, 717-729.
13. Mann, J. D.; Wakim, K. G., and Baggenstoss, A. H. Alterations in the vasculature of the diseased liver. *Gastroenterology*, 1953, 25, 540-546.
14. Madden, J. L.; Loré, J. M., Jr., Gerold, F. P., and Ravid, J. M. The pathogenesis of ascites and a consideration of its treatment. *Surg. Gynec. & Obst.*, 1954, 99, 385-391.
15. Liebow, A. A.; Hales, M. R.; Lindskog, G. E., and Bloomer, W. E. Plastic demonstrations of pulmonary pathology. *J. Technical Methods*, 1947, 27, 116-129.
16. Elias, H., and Petty, D. Gross anatomy of the blood vessels and ducts within the human liver. *Am. J. Anat.*, 1952, 90, 59-111.
17. Andrews, W. H. H.; Maegraith, B. G., and Wenyon, C. E. M. Studies on the liver circulation. II. The micro-anatomy of the hepatic circulation. *Ann. Trop. Med.*, 1949, 43, 229-237.
18. Himsworth, H. P. Lectures on the Liver and Its Diseases. Blackwell Scientific Publications, Oxford, 1947, ed. 1, 204 pp.
19. MacMahon, H. E. Biliary cirrhosis. Differential features of the five types. *Lab. Invest.*, 1955, 4, 243-261.
20. Phillips, G. B., and Davidson, C. S. Acute hepatic insufficiency of the chronic alcoholic. Clinical and pathological study. *A. M. A. Arch. Int. Med.*, 1954, 94, 585-603.
21. Egbert, H. L., and Raber, R. M. The physiologic effect of hepatic artery and portal vein ligation: results of perfusion studies and observations on patients at operation. *Surgical Forum*, 1951, 2, 153-158.
22. Taylor, F. W., and Rosenbaum, D. The case against hepatic artery ligation in portal hypertension. *J. A. M. A.*, 1953, 151, 1066-1069.
23. Popper, H., and Schaffner, F. Liver: Structure and Function. The Blakiston Div., McGraw-Hill Book Co., 1957, p. 284.
24. Bradley, S. E.; Smythe, C. M.; Fitzpatrick, H. F., and Blakemore, A. H. The effect of a portacaval shunt on estimated hepatic blood flow and oxygen uptake in cirrhosis. *J. Clin. Invest.*, 1953, 32, 526-537.
25. Myers, J. D. The hepatic blood flow in Laennec's cirrhosis, with an estimate of the relative contributions from the portal vein and hepatic artery. *J. Clin. Invest.*, 1950, 29, 836-837.
26. Schilling, J. A.; McKee, F. W., and Wilt, W. Experimental hepatic-portal arteriovenous anastomoses. *Surg. Gynec. & Obst.*, 1950, 90, 473-480.
27. Cohn, R., and Herrod, C. Some effects upon the liver of complete arterialization of its blood supply. *Surgery*, 1952, 32, 214-218.

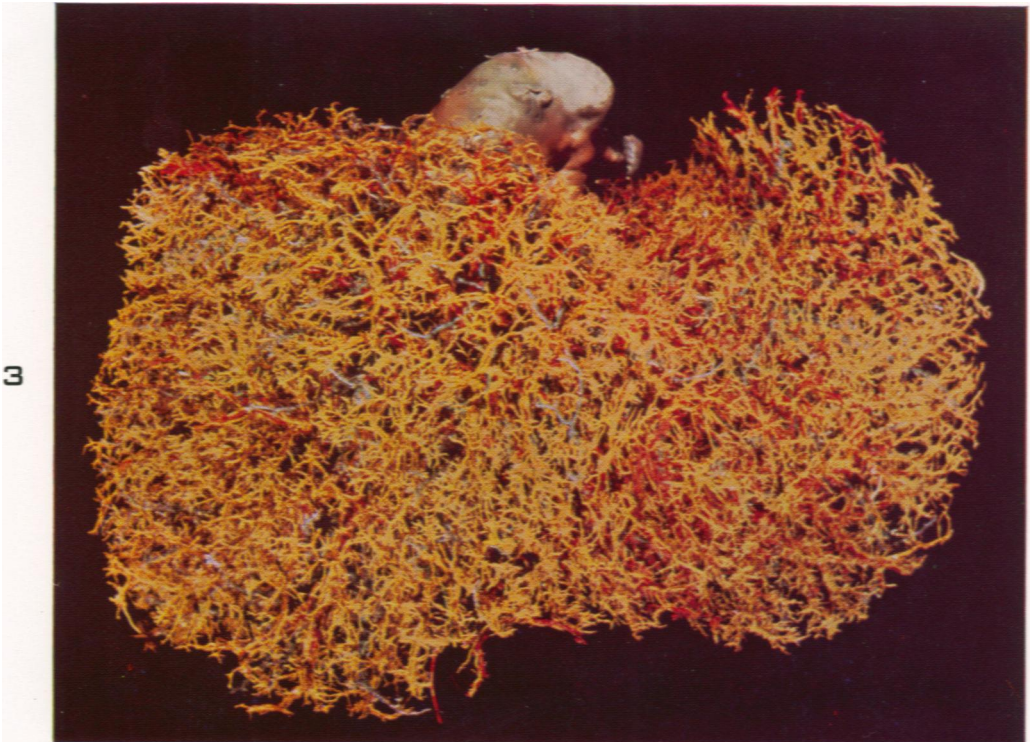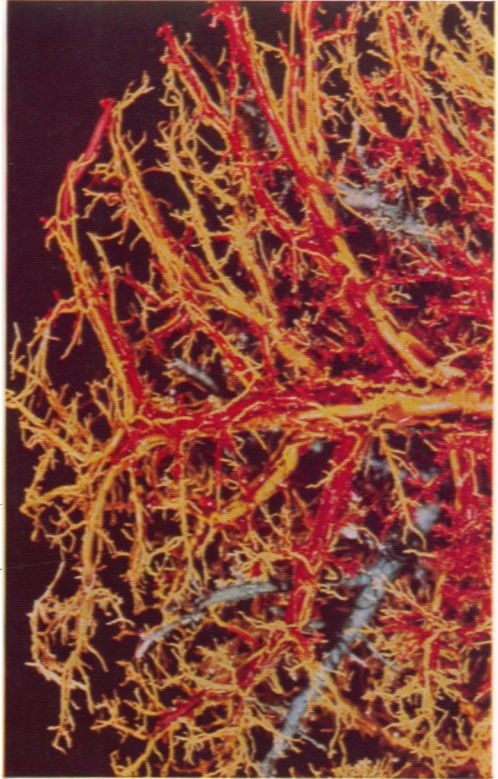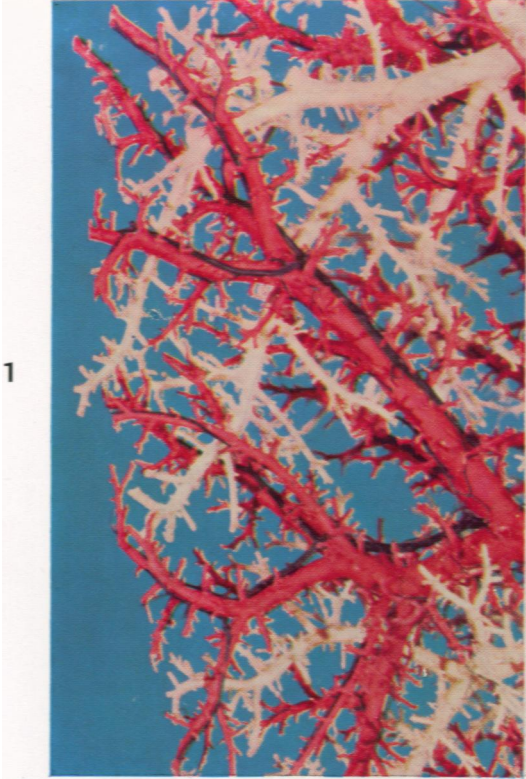28. Fisher, B.; Russ, C.; Fedor, E.; Wilde, R.; Engstrom, P., and Fisher, E. R. Further experimental observations on animals with arterialized livers. *Surgery*, 1955, 38, 181-193.
29. Jones, S. A.; Reynolds, T. B.; Schultz, E. B., and Gregory, G. Arterialization of the human liver following portocaval anastomosis; case report. *West. J. Surg.*, 1955, 63, 574-579.
30. Servello, M., and Petronio, R. Some experimental methods for arterialization of the liver: the aortosplenic anastomosis. *J. Internat. Coll. Surgeons*, 1956, 25, 448-454.

---

[ *Illustrations follow* ]

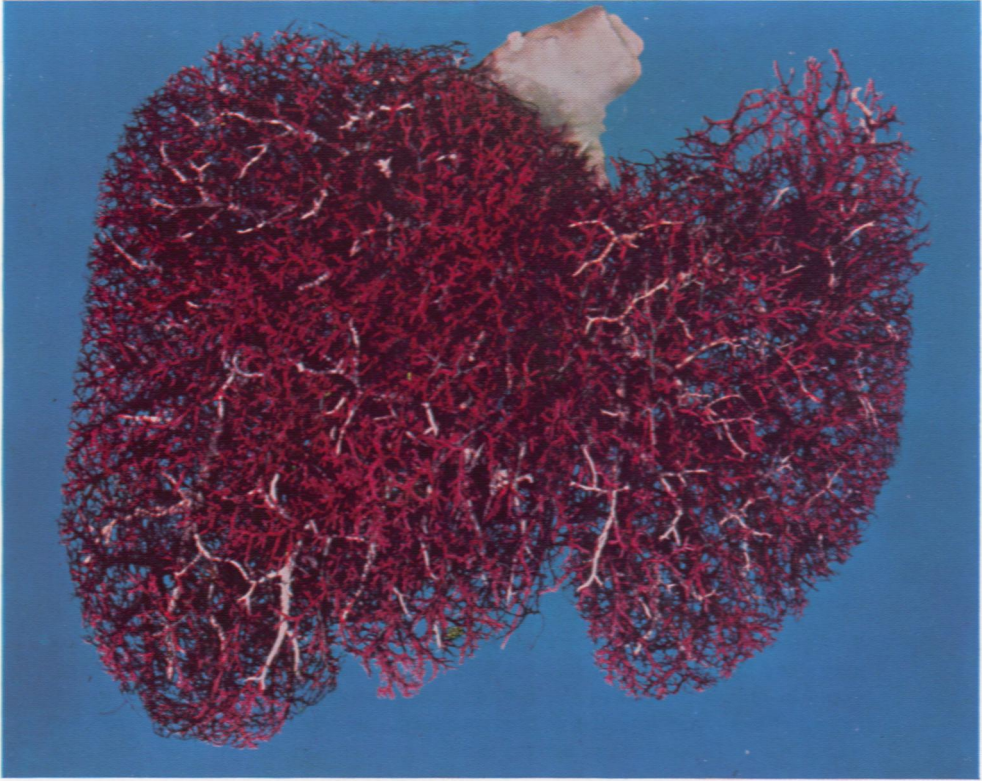
## LEGENDS FOR FIGURES

- FIG. 1. Portion of the cast of a normal liver. There is regular interdigitation of the distal portal (red) and hepatic veins (white). Even sizable hepatic veins receive numerous tiny tributaries at almost 90° angles. The distal hepatic arteries (black) are rarely more than one third the diameter of the portal veins they accompany. Small biliary ducts were not injected.  $\times 2.4$ .
- FIG. 2. Portion of the cast of a cirrhotic liver. Hepatic arteries (yellow) are increased in number and are often fully as large as the adjacent portal veins (red). At the right margin some of the small portal veins are well injected, whereas only the larger hepatic veins (blue) persist.  $\times 1.4$ .
- FIG. 3. Cast of a liver with portal cirrhosis. In the expanded arterial bed the enlarged hepatic arteries (yellow) almost completely hide the stunted portal veins (red) and the even more severely stunted hepatic veins (blue).  $\times 0.6$ .

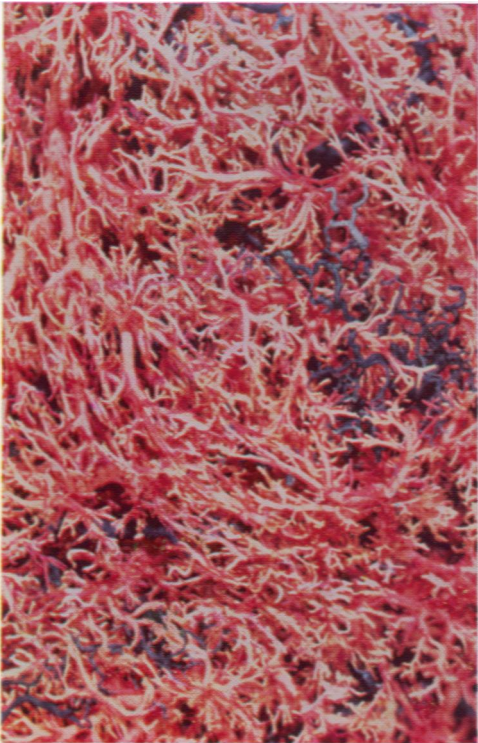


- FIG. 4. Cast of a liver with portal cirrhosis. The portal venous bed (red) is little if at all altered from the normal, whereas the hepatic venous bed (white) is markedly restricted. This pattern of disproportionate reduction in the two venous beds was noted in two thirds of the livers with portal cirrhosis. The hepatic arterial bed (black) is greatly expanded.  $\times 0.5$ .
- FIG. 5. Portion of the cast of the cirrhotic liver shown in Figure 9. Distorted portal veins (white) are compacted in a broad depressed scar. Hepatic veins (blue) are essentially absent in the scar, but are present and severely distorted in the large bulging nodule of regenerated parenchyma seen at the right center. Hepatic arteries (red) are enlarged.  $\times 1.5$ .
- FIG. 6. Posterior surface of the right half of the cast of the cirrhotic liver shown in Figure 10. In the depressed triangular scar at the right margin, portal veins (white) are compacted and appear even more numerous than normal, but few hepatic veins (blue) could be injected there. Hepatic arteries (red) are enlarged, even in the scar.  $\times 0.5$ .

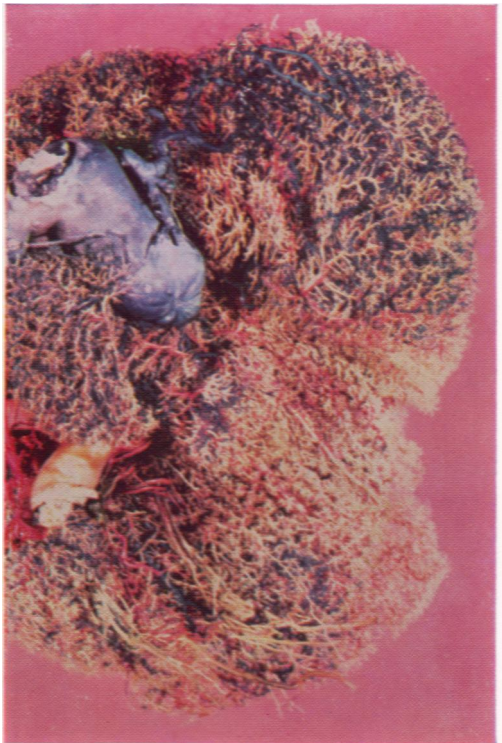4



5

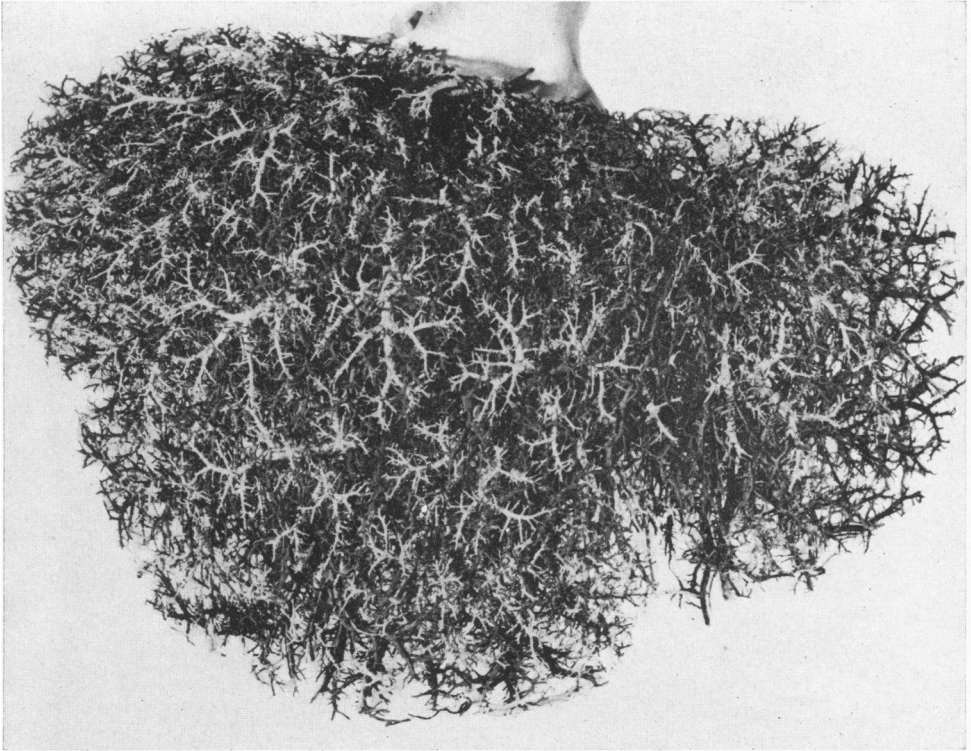


6

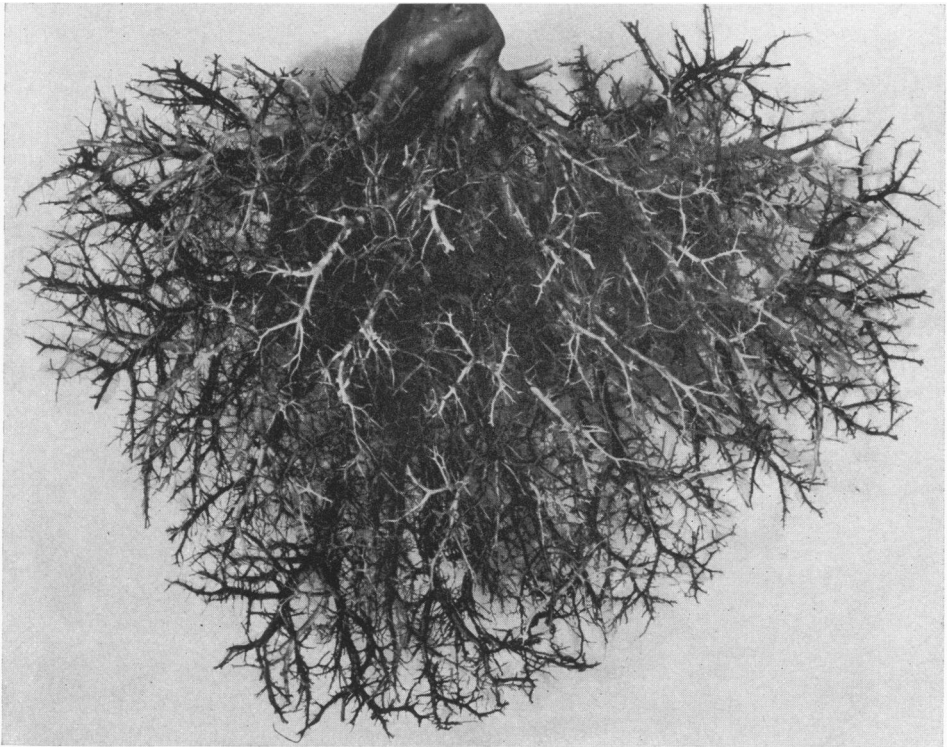


- FIG. 7. Cast of a normal liver. Portal veins (gray) and hepatic veins (white) have been injected equally far to the periphery where their distal branches alternate uniformly. Hepatic arteries (black) are too small to be seen well at this magnification.  $\times 0.55$ .
- FIG. 8. Cast of a liver with portal cirrhosis. In this specimen the portal (dark gray) and the hepatic venous beds (light gray) are equally reduced, a pattern noted in only one third of the cirrhotic livers studied. Only the right hepatic artery (black) was injected in this specimen, but the left hepatic arterial bed was partially filled through arterio-arterial anastomoses at the hilum.  $\times 0.44$ .



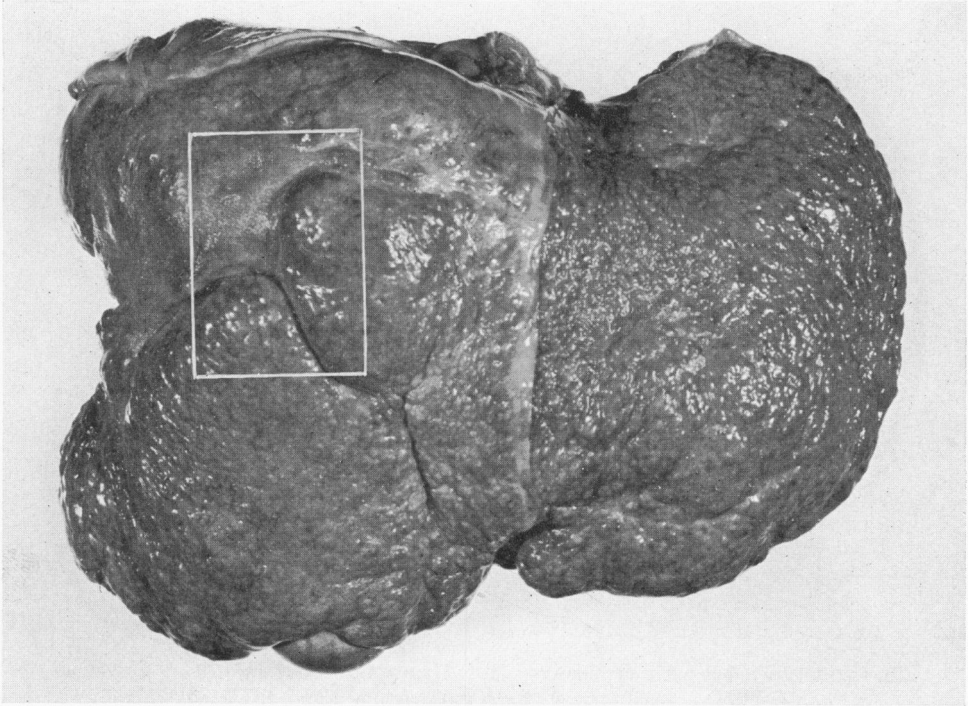


7

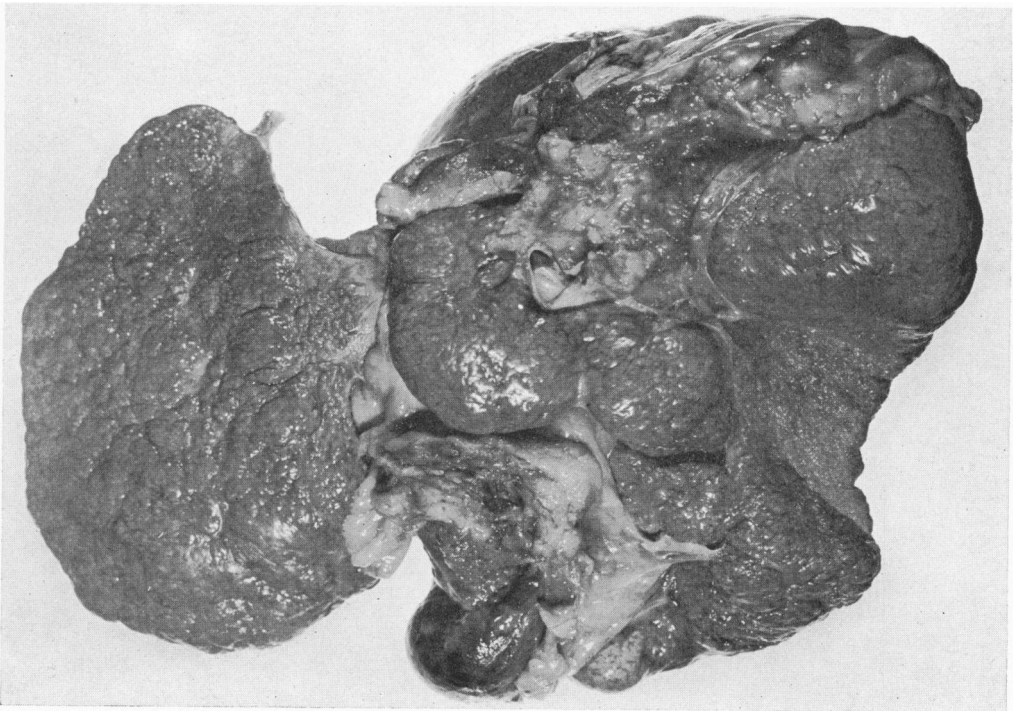

8

- FIG. 9. Cirrhotic liver with focal broad scars. The portion outlined is illustrated in Figure 5, after injection and corrosion. Distorted hepatic veins were demonstrated among regenerated pseudolobules, but only portal veins and hepatic arteries could be injected in the broad scars which were almost devoid of parenchyma.  $\times 0.39$ .
- FIG. 10. Posterior surface of a cirrhotic liver with a depressed scar at the right margin. Histologic sections from the scar revealed only a few widely separated, tiny nests of hepatic cells. In the cast from this liver (Fig. 6) hepatic veins were essentially absent from the scar, but portal veins were numerous and compacted there.  $\times 0.4$ .

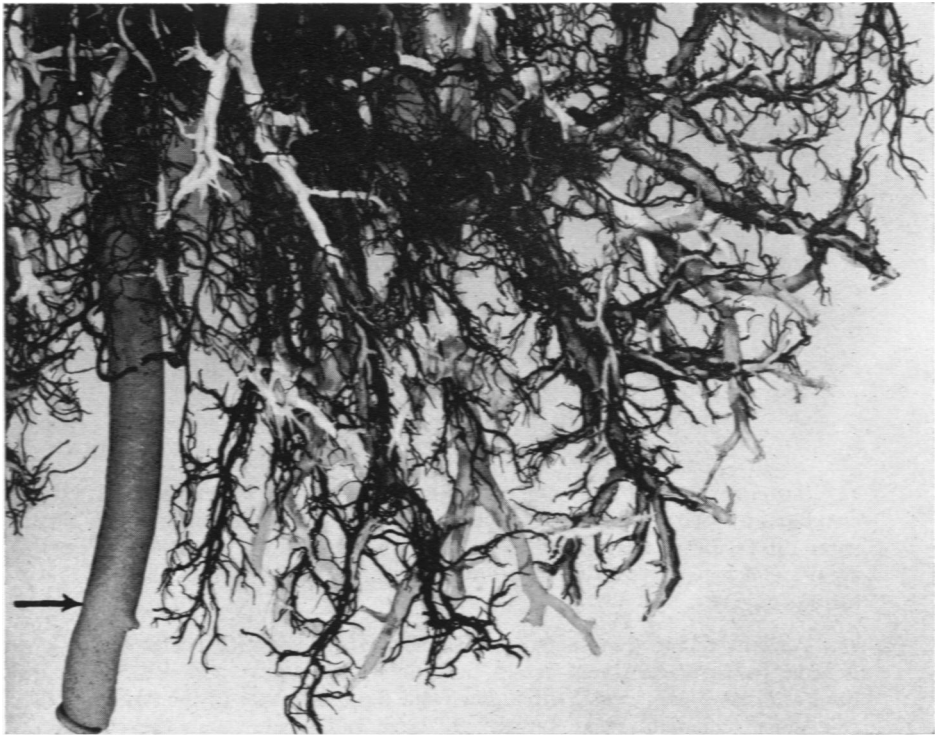


9

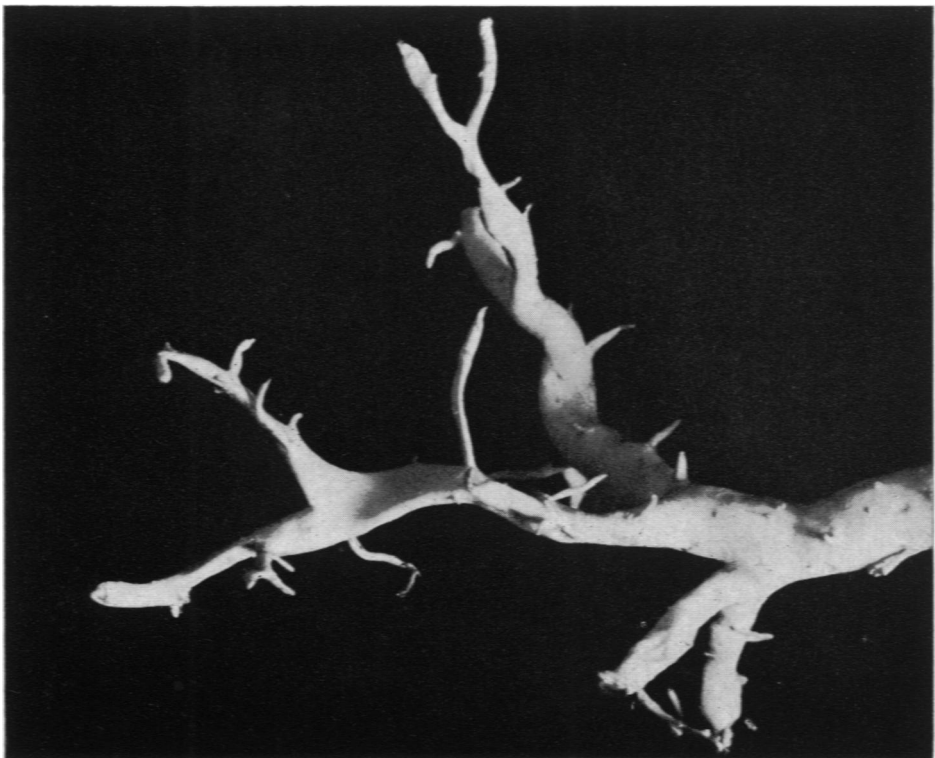

10

- FIG. 11. Anterior inferior surface of the left lobe of a liver with portal cirrhosis. The vessel indicated by the arrow is a large patent umbilical vein. Hepatic arteries (black) are reduplicated, tortuous and enlarged, and many tiny branches have been injected. Portal (gray) and hepatic veins (white) are distorted and reduced.  $\times 1.2$ .
- FIG. 12. Distorted hepatic venous twig from the cast of a cirrhotic liver. Segments of the vessel have been abruptly flattened, narrowed and displaced. The normal regular pattern of arborization has been lost. Only a few small, stunted and distorted tributaries persist.  $\times 4.8$ .




11



12

FIG. 13. Posterior view of the cast of a cirrhotic liver. A large umbilical vein communicates with the left portal vein. Two smaller para-umbilical veins also enter the falciform ligament from the sharp margin of the right lobe. Portal (gray) and hepatic veins (white) are reduced in number and are greatly distorted.  $\times 0.48$ .

FIG. 14. Partially trimmed segment from the cast of a liver with portal cirrhosis. A large para-umbilical vein enters the falciform ligament with an S-shaped bend after receiving several tributaries from distal branches of the right portal vein. Such collaterals were surprisingly large and numerous in the cirrhotic livers examined. The tiny, nonbranching vessel to the right is a patent umbilical vein. Note the plexus of enlarged hepatic arteries (black) along each portal vein (gray).  $\times 1.5$ .



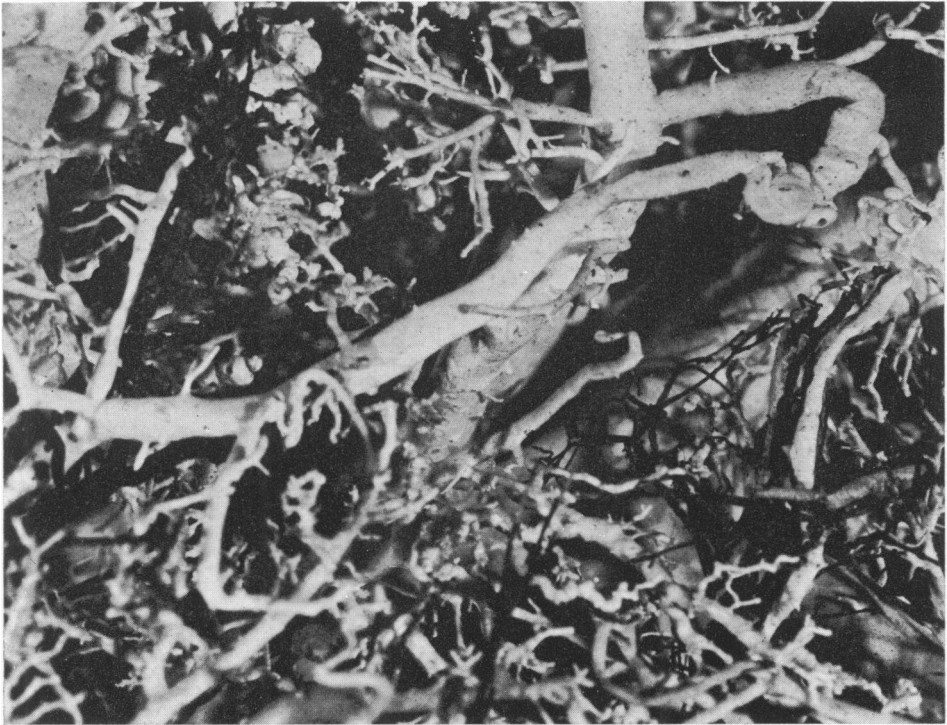13




14

- FIG. 15. Portion of the cast of a liver with "thyrotoxic" cirrhosis. A large looping anastomosis communicates between a portal vein on the left and a hepatic vein at the right center. Large venovenous anastomoses such as this were uncommon in cirrhotic livers.  $\times 2.5$ .
- FIG. 16. Cast of a liver with severe congestive (cardiac) cirrhosis from a patient with congenital tricuspid insufficiency. The inferior vena cava and the hepatic veins are tremendously dilated, and both portal and hepatic veins are distorted. The arteries, appearing almost white in the illustration, are enlarged. At "A" diaphragmatic arteries and veins have been injected in retrograde manner through anastomoses with hepatic arteries and veins. At "B" is seen a large collateral para-umbilical vein arising from distal branches of portal veins.  $\times 0.45$ .





15



16