

## EXPERIMENTAL DIETARY SIDEROSIS\*

THEODORE GILLMAN, D.Sc., M.B., B.Ch.; M. HATHORN, M.B., B.Sc., and  
P.A.S. CANHAM, Ph.D.

*From the Department of Physiology, and the Schlesinger Organisation Medical  
Research Unit, Medical School, University of Natal, Durban, South Africa.*

The etiology and pathogenesis of siderosis, so widespread and frequently so severe among Africans in the Union, is still a subject of considerable controversy.<sup>1-4</sup> Especially debated are the significance of malnutrition, of dietary iron overload in the production of this interesting pathologic feature and, especially, of other possible factors permitting or actively promoting excessive iron absorption. Answers to these questions may throw considerable light not only on dietary siderosis in human subjects but on many aspects of iron metabolism in general.

Two major schools of thought have arisen in relation to the etiology of African siderosis. The one maintains that dietary iron overload, due to the reported high iron content of the African diet, is alone responsible for the excessive iron uptake and its subsequent deposition in the tissues.<sup>3</sup> According to those who hold this view, there is no need to invoke malnutrition or any nutritionally induced or other cellular metabolic disorder to account for the phenomenon. The other school of thought, while always maintaining that the excessive tissue iron is derived from the diet,<sup>2</sup> considers that the excessive absorption of dietary iron is an expression of some primary underlying disorder of cellular metabolism, perhaps consequent on long-standing and probably intermittent chronic malnutrition.

It has now been shown that the so-called "mucosal block" to iron uptake varies and, in nonanemic individuals, can be overcome at least by dietary iron overload. Thus, the feeding of large quantities of iron increases the total uptake of this mineral although the proportion of iron absorbed decreases progressively with the increase in the dose administered. This has now been repeatedly confirmed for acute experiments in man and animals.<sup>5-8</sup> It has also been shown experimentally that greater quantities of iron are absorbed and deposited in the tissues even if a relatively good diet is enriched with iron.<sup>6,8</sup> The investigators of the latter have, however, clearly demonstrated that greater amounts of iron accumulate in the tissues of rats fed an inadequate but iron-enriched diet than in animals given the same amounts of iron in a "good" diet. Their experiments thus indicate that the proportion

\* Received for publication, July 11, 1958.

of iron absorbed is in some way a function of the non-ferric constituents of the diet. Hegsted, Finch and Kinney<sup>9</sup> revealed that even on a "bad" (maize) diet, iron uptake is in part a function of the dietary phosphate content; however, they found that the concentration of several amino acids in the diet may also affect iron uptake, independently of the phosphate content. More recently, too, several investigators have shown that the calcium, vitamin C and vitamin E contents of the diet influence not only the rate of iron uptake but also the speed of its incorporation into hemoglobin, i.e., the intermediary metabolism and utilization of iron.<sup>10</sup>

It seemed important, therefore, to study further the effects of dietary iron overload and of malnutrition on iron uptake and tissue siderosis. This was all the more necessary in view of the absence from the literature of any data concerning the histogenesis of nutritionally induced siderosis and especially about the way excessively absorbed dietary iron is deposited in the tissues in the early stages of such experiments.

The object of the present study is to assess the effects of feeding excessive quantities of iron to rats maintained on a "good" as opposed to a "bad" diet, with a view to determining whether properties of the diet other than its iron content would influence the amount and distribution of iron in the body. Particular attention has here been paid to the hepatic changes at different stages of these experiments and to the site of initial appearance of histochemically demonstrable iron, first in the liver but later also in other tissues. Comparisons have also been made between the histochemically and chemically demonstrable iron content of various tissues.

#### MATERIAL AND METHODS

Male Wistar-strain rats initially weighing 200 to 230 gm. (mean weight: 215 gm.) were divided into 4 groups and fed *ad libitum* on our stock diet or uncooked mealie-meal (corn meal), with or without supplements of 4 per cent ferric citrate. The iron, calcium and phosphorus contents of these 4 diets are shown in Table I. In addition, all groups of rats were fed milk 3 times weekly and fresh vegetables twice weekly. At 50 and 100 days respectively, half the rats in each group were subjected to laparotomy and wedge-shaped specimens removed from the livers. The biopsy tissue was fixed in 10 per cent neutral formalin, and paraffin-embedded sections were stained with hematoxylin and eosin and by the ferrocyanide method for iron.<sup>11</sup>

At the conclusion of the experiment at 156 days, the rats were anesthetised with ether, and were bled by cardiac puncture for iron

estimations. The rats were then perfused with warm iron-free saline. Weighed specimens from various organs were removed for histologic examination and for iron estimations. The remaining carcasses were minced and also analyzed chemically for iron.

The iron contents of the various organs and carcass were determined by the  $\alpha$ - $\alpha$ -dipyridyl reagent after wet digestion with sulphuric

TABLE I  
*Summary of Chemical Observations*

	Group I	Group II	Group III	Group IV
Diet	Stock	Mealie meal	Stock + iron	Mealie meal + iron
Number of rats	5	5	10	7
Mean daily food intake per rat (gm.)	23	13	20	11
Dietary minerals (mg./100 gm. dry weight)				
Iron	77	4.2	1017	974
Phosphorus	830	6.7	818	61
Calcium	2640	33	2584	29
Mean daily iron intake per rat* (mg.)	18	0.6	203	107
Mean daily iron absorption per rat* (mg.)	0.19	0.26	0.35	0.57
Mean weight change per rat during experiment (gm.)	+140	+115	+87	-17
Concentration of iron (mg./100 gm. wet weight)				
Total body	8.2±0.5†	12.3±0.6	18.5±1.0	45.1±2.2
Liver	32.3±2.5	22.1±2.4	66.6±6.3	367±19

\* Calculated from food and milk consumed in each group.

† Standard error of the mean.

and perchloric acids. Total body iron was calculated by adding, to the determined carcass iron, estimates of (a) the small samples of tissue removed for histologic and chemical study, and (b) total hemoglobin and plasma iron.

#### OBSERVATIONS

*Growth.* Increase in the body weight was greatest in animals fed the stock diet, slightly less in rats on mealie-meal alone, less still in those consuming the iron-enriched stock diet, and least of all in the animals fed mealie-meal supplemented with iron. It is clear from Table I that the addition of large quantities of iron suppressed the growth of rats consuming either the stock or the mealie-meal diets.

### *Histologic Observations*

*Liver.* Even after 50 days there was a striking amount of histochemically demonstrable iron in the livers of rats fed the iron-enriched mealie-meal diet. At this stage, the iron-containing pigments were almost entirely confined to the liver cells in the portal third of each lobule. Only minimal amounts of stainable iron were detectable in the sinusoidal or portal phagocytes (Figs. 1 and 2). The affected liver cells were somewhat vacuolated and their walls were prominent ("plant-like"), the appearances resembling those previously described in the liver cells of man in "anoxia."<sup>2,12</sup> At this time iron was not demonstrable histochemically in the livers of any of the other groups of rats.

By the 100th day of the experiment, the alterations ascribed to anoxia and the hepatocellular siderosis in the rats fed the iron-enriched mealie-meal diet were even more marked in the liver biopsy specimens obtained at laparotomy. This is well exemplified in Figure 3, in which, apart from the alterations in the hepatic cells, the Kupffer cells and even some portal tract phagocytes can be seen to be laden with iron pigment. A typical example of the degree and extent of hepatocellular and phagocyte siderosis, at the end of the experiment (156 days) in rats fed mealie-meal and iron, is shown in Figures 4 and 5. Especially noteworthy is the greater extent of the siderosis of the liver cells in each lobule. In liver cells near the central veins, iron appeared as fine granules localized mainly along the biliary poles (Figs. 7 and 8) in a manner closely resembling that previously described in the early stages of siderosis in Africans.<sup>1,2,13,14</sup> In the periportal liver cells, however, iron-containing pigment occurred in coarser clumps scattered throughout the cytoplasm of the affected cells (Figs. 9 and 10). This appearance is indistinguishable from the Type III stage of siderosis described and portrayed in siderotic livers of Africans.<sup>1,2,13</sup> The hepatic phagocytes were also more heavily laden with iron pigment and many clumps of siderotic sinusoidal and portal phagocytes were now regularly observed (Figs. 4 and 5).

In contrast with the livers of rats fed mealie-meal and iron, the livers of animals fed the iron-enriched stock diet contained only minimal amounts of histochemically demonstrable iron, and this was confined to a few sinusoidal and portal phagocytes (Fig. 6) even though, as will be shown, the concentration of chemically-estimated hepatic iron at this stage doubled itself as compared with rats fed the stock diet alone for the same period of time.

*Other Organs.* Iron was not detected microscopically in either the

parenchymal or the connective tissue cells of the pancreas, heart, stomach and other tissues examined from any of the groups enumerated above. The splenic tissue of rats fed either the stock or the mealie-meal diets enriched with iron did appear, histologically, to be more heavily siderotic, the spleens of the mealie-meal plus iron group being perhaps slightly more laden with iron, but not very strikingly so (compare Figs. 11 and 12). The same remarks apply to the bone marrow (Figs. 13 and 14.). In the rats fed the stock diet plus iron, both the numbers and the sizes of the iron-laden phagocytes in the bone marrow were less than in those fed mealie-meal plus iron. This can be readily appreciated by studying any randomly selected field in the photomicrographs of bone marrow.

Very fine granules of iron were demonstrable in scattered epithelial cells of the proximal convoluted renal tubules of rats fed mealie-meal plus iron. This was not the case in the kidneys of the other groups.

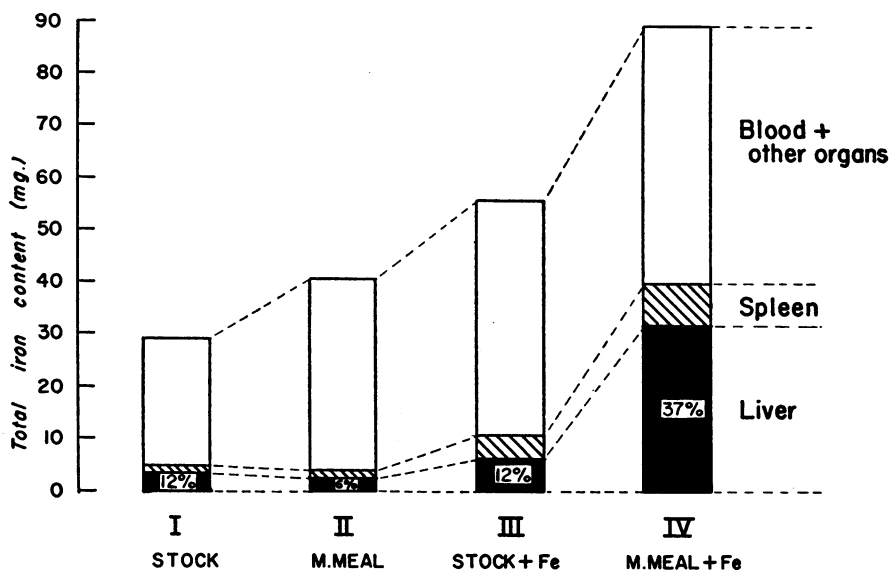
Especially striking were the differences in the iron content of the colonic surface epithelium, *tunica propria* and submucosa in rats fed mealie-meal and iron as compared with those given the iron-enriched stock diet for 156 days (compare Figs. 15 and 16). In the former group, the lumen poles of almost all the surface epithelial cells revealed numerous fine iron-containing granules closely resembling the lesions described by Gillman and Ivy<sup>15</sup> in the duodenal mucosa of iron-fed guinea pigs. Only occasional granules of iron were detected in the colonic surface cells of the control group (i.e., stock diet plus iron). Even more striking, however, were the massive accumulations of iron in the phagocytes of the *tunica propria* of the rats fed mealie-meal plus iron, when they were examined at the end of the experiment. It is generally considered that the duodenum and jejunum play a most active role in iron absorption; certainly in the guinea pig and in man, this is where iron is most commonly encountered in both the surface epithelium and phagocytes of the *tunica propria*.<sup>2,15</sup> However, only minimal amounts of epithelial and phagocyte iron were seen in the duodenum even of the heavily siderotic rats fed mealie-meal and iron (Fig. 17).

Whether the colonic iron, here described and portrayed, is being absorbed or excreted cannot be stated without the aid of radioactive tracers. It should be noted, however, that Granick<sup>16</sup> did describe a moderate increase in the ferritin demonstrable in the colonic mucosa of guinea pigs some time after a single dose of orally administered iron. The latter evidence suggests that the colon can absorb some dietary iron, at least in the guinea pig.

### Chemical Data

A summary of the results of the chemically estimated iron content of the entire rats and of various tissues, studied at the end of the experiments, is presented in Table I.

The following are the most striking observations: (1) The concentration of total body iron was increased in the groups fed excessive quantities of iron added either to the stock or to the mealie-meal diets. In the former, the total body iron concentration rose to just over twice that of animals fed only the stock diet. In the rats which consumed mealie-meal plus iron, however, the total body iron concentration rose to almost 4 times that of the mealie-meal controls and to almost  $2\frac{1}{2}$  times that found in the group fed the iron-enriched stock diet. Comparisons of total iron content of different organs are shown in Text-figure 1.



Text-figure 1. Mean total iron content of liver, spleen and whole animal after 156 days on various diets. Percentages denote contribution of hepatic iron to total body iron in each group.

(2) From Table I and Text-figure 1 it can be seen that the increase in the concentration of total body iron, most notable in groups III and IV, was found to be associated with a two-fold increase in hepatic iron concentration in group III (compared with group I) while in group IV rats the hepatic iron concentration increased by 16-fold as compared with group II. In fact, the concentration of iron in the livers of group IV rats was almost 6 times greater than that in the livers in group III rats. In the rats fed mealie-meal plus iron (group IV), the

livers contained over 30 per cent of the total body iron as compared with 2.4 to 6.5 per cent of the body iron in the other groups (Text-fig. 1). This indicates that rats fed the iron-enriched mealie-meal diet not only absorbed and retained far more iron than any other rats, but in addition, in the group IV animals the liver seemed particularly susceptible to iron accumulation.

As is also shown in Table I, the estimated rate of daily iron absorption was higher in both groups of rats fed mealie-meal when compared with their appropriate stock diet controls. Especially notable, perhaps, is the high iron absorption in the rats fed mealie-meal alone (group II) despite the very low iron content of this diet (Table I). Enriching mealie-meal with iron considerably enhanced the iron uptake even though the daily food and iron intake in this group (group IV) was half that of group III.

Especially noteworthy were the contributions to the total body iron from the various organs in the different groups of rats. Text-figure 1 displays in a striking way the very much greater susceptibility to siderosis of the livers of rats fed mealie-meal and iron. The quantitative findings fully confirm the histologic data outlined above.

#### DISCUSSION

Observations indicate that dietary iron overload leads to an increase in the total body iron whether animals are consuming a "good" or a "bad" diet. However, rats fed the iron-enriched mealie-meal diet (group IV) became siderotic much more rapidly and more severely than rats fed a similarly enriched "good" diet. The "mucosal block" for iron, while not complete, is nevertheless more efficient in well-nourished than in malnourished rats. Whether the far greater iron uptake in rats fed mealie-meal and iron is a function of the phosphate, calcium, amino acid, or other dietary components, operating in the lumen of the intestine, as suggested by others,<sup>10,17</sup> still remains to be determined with the aid of radioactive iron. It still seems possible, however, that alterations in the mucosal block may perhaps be a reflection of profound changes in the intermediary metabolism of iron (and possibly of other substances, too) in cells throughout the body, but perhaps particularly in the liver.

In the rats fed mealie-meal and iron whose organs ultimately became heavily siderotic, iron-containing pigment was detectable, in notable quantities, first within the hepatic epithelium and only much later in sinusoidal or portal phagocytes. Moreover, even when the liver was severely siderotic, and when the hepatic iron had increased 6 or 7 fold, very little was visible in the epithelium of other parenchymal organs.

In this regard, dietary siderosis in the rat resembles human siderosis, for Gillman and Gillman<sup>1,2</sup> described iron as being detectable along the biliary poles of the liver cells in the earliest phase of African siderosis. This seems to be the pattern in other types of experimental dietary siderosis (cat<sup>7</sup>) and differs from siderosis induced by injecting iron, where this metal accumulates first in the reticuloendothelial cells in both the rat and the cat, but not in the rabbit.<sup>18</sup> If siderosis is studied in the late stages only, it becomes impossible, on histologic grounds, to determine where iron accumulates first, since, in advanced siderosis, both epithelial and phagocytic cells become laden with this metal. It seems that in African siderosis, as in dietary siderosis in rats, iron appears first in hepatic epithelium and only in the later stages in hepatic phagocytes.

It is also our impression that, as in our rats, so too in Africans, the epithelial cells of other organs, e.g., pancreas, salivary glands, and kidneys, become laden with iron only late in the disease but before the phagocytes of these organs. However, the spleen, lymph nodes and bone marrow, which contain only reticuloendothelial elements and are devoid of epithelium, may and usually do become siderotic fairly early. It is also noteworthy that in rats on an iron-enriched stock diet, the hepatic epithelium is free of histochemically demonstrable iron even though the total iron content of the liver, as estimated chemically, is twice that of the controls.

Our figures thus reveal the liver to be liable to iron accumulation to a greater extent than other organs, and especially so when the animals are malnourished.

It is not yet known whether, in idiopathic hemochromatosis, the epithelium or the phagocytes are the first to accumulate iron, simply because most tissue from such cases has been obtained at necropsy and late in the disease. Hence, biopsy specimens of the liver and other tissues from young individuals inheriting the hemochromatotic metabolic disorder, as evinced by plasma iron abnormalities, would be of fundamental importance. Very early stages of African siderosis have already been studied.<sup>2</sup> Until material becomes available from subjects in the earliest stages of idiopathic hemochromatosis, comparisons of these two human diseases, on the basis of the distribution of iron between epithelium and phagocytes of parenchymal organs, cannot permit conclusions as to their pathogenesis.

The massive accumulation of iron in hepatic epithelium and its retention in the liver (even at a later stage in the experiments) certainly seem to indicate that some alteration has occurred in the movements of iron throughout the body in the malnourished rats. This



possibility is supported by the heavy colonic siderosis in rats fed iron-enriched mealie-meal diets. Since excretion of endogenous iron increases, if the total iron content of the body and hence the turnover is greater,<sup>19</sup> this heavy colonic siderosis may perhaps indicate increased excretion of iron by our rats. However, this point can be settled only with the aid of radioactive isotopes.

It has been shown that the rate of iron uptake from the intestine may be altered in at least the following ways: (a) by increasing the dietary iron content; (b) by changing the dietary phosphate, calcium, protein, or amino acid contents; (c) by modifying the vitamin C or E content of the diet; (d) by acute or prolonged simulated high altitude (decompression anoxia).

It has also been suggested that the increased iron uptake and the better utilization of absorbed iron, induced by vitamin C and especially by vitamin E, is attributable to improved cellular oxidation-reduction systems, especially in the bone marrow, but perhaps also in the intestinal mucosa. Beilig and Bayer<sup>20</sup> have demonstrated the direct uptake of ferrous iron by apoferritin to form ferritin in the presence of oxygen, while Mazur, Baiz and Shorr<sup>21</sup> have shown that iron is released from ferritin in tissue slices under anaerobic conditions in the presence of ascorbic acid, glutathione, cysteine or anaerobic liver tissue. Loewus and Fineberg<sup>22</sup> further revealed that under aerobic conditions, and in the presence of ascorbic acid or boiled liver extracts, ferric iron may be reduced, adsorbed onto apoferritin and re-oxidized by atmospheric oxygen to ferritin. Furthermore, Takeda and Hara<sup>23</sup> maintained that the primary lesion in ascorbic acid deficiency is the mobilization of ferrous iron causing an inactivation of the enzymes which require the ferrous ion as a co-factor; this alteration is accompanied by a decrease in the activities of other enzymes leading, *inter alia*, to a depression of synthetic reactions including enzyme formation, with consequent quantitative decline in mitochondrial enzymes as a whole.

In the light of all the above, it is not surprising that artificially induced anoxia (decompression) rapidly causes a greater uptake of a single dose of ingested iron<sup>24</sup> and is soon associated with a distinct increase in circulating siderophilin and a drop in plasma iron content.<sup>25</sup> The well-known increase in the size of the circulating erythron, accompanying acclimatization to high altitudes, is possibly the later outcome of these initial changes, perhaps facilitated by an increase in circulating "erythropoietin."<sup>26</sup>

Thus, anoxia and several nutritionally induced intracellular metabolic disorders can and apparently do promote profound and wide-

spread alterations in tissue metabolism, all of which affect the activity and synthesis of mitochondria and especially of their iron-containing enzymes. Perhaps similar alterations in intracellular metabolism throughout the body, induced by the inadequate maize-meal diet, are ultimately responsible for the considerable changes noted in the absorption, transport, distribution and even in the intermediary metabolism of dietary iron in our experiments. How far these metabolic changes may exert their effects on iron absorption and metabolism through the "erythropoietin" hormone described by Jacobson, Goldwasser, Fried and Plzak<sup>27</sup> seems worthy of further study.

We have shown that consumption of a maize diet markedly increases the uptake of iron from the intestine and alters its distribution in the body. Gillman and Gillman suggested from their cytologic studies<sup>28</sup> that the earliest detectable lesions in African siderosis seemed to be in and around the hepatic mitochondria. It is interesting to note that this early opinion has been confirmed by Richter's recent electron microscope study which also indicates that "hemosiderin is derived from altered mitochondria or 'siderosomes'."<sup>29</sup> The biochemical data quoted above and our present experimental findings would seem to support the Gillmans' contention that some nutritionally conditioned intracellular metabolic disorder (or disorders) seems to underlie the excessive absorption and utilization of dietary iron and its consequent deposition in the liver and other tissues in Africans with siderosis. Moreover, the cytologic evidence, coupled with our chemical findings and other data from the literature,<sup>29,30</sup> provide strong indications that many derangements in iron metabolism (including microcytic anemia) previously attributed solely to peculiarities in iron intake, may be shown to be due rather to widespread, initially intracellular metabolic disorders, resulting, in many instances, from one or another form of malnutrition.

Perhaps the accumulation of iron pigment within the liver cells, like the accumulation of fat, may be the end result of a variety of metabolic lesions acting through a single final common intracellular path. Whereas fatty change is known to be one morphologic expression of several distinct derangements in fat metabolism, so too, perhaps, siderosis may result from disturbances in the rate of synthesis and destruction of iron-containing enzymes, perhaps primarily in the liver. Recent reviews<sup>29</sup> of various aspects of iron metabolism indicate that, contrary to previous expectations, intracellular iron enzymes may be far more susceptible than the circulating erythron to peculiarities in dietary iron content. Of particular interest in this connection, is Beutler's observation<sup>30,32</sup> of a fall in cytochrome C content of the liver

and kidney of rats on an iron deficient diet before anemia developed. This further underlines the susceptibility of intracellular iron-containing enzymes, and the mitochondria with which they are associated, to alterations in metabolism resulting from various forms of malnutrition.<sup>31</sup>

All the present indications are that, as first suggested by Gillman and Gillman in 1944,<sup>28</sup> some lesion involving the iron-containing enzymes, located in or on the mitochondria, is to be anticipated as the underlying basis for increased uptake of dietary iron so clearly induced by a "bad" diet. Such mitochondrial lesions could perhaps be produced by anoxia or at least by intermittent cellular hypoxia. The effects on plasma iron and iron uptake of a single brief exposure to hypoxia may persist for several days.<sup>24,25</sup> Using this knowledge, we have now completed further experiments, the preliminary results of which demonstrate clearly that short, intermittent decompression (at 360 mm. of Hg for 1½ hours twice weekly) markedly increases the rate and amount of iron absorbed and stored in the liver of rats fed an iron-enriched maize diet, but has very little effect on rats fed the stock diet plus iron. In rats fed the mealie-meal and iron diet, but with the calcium and phosphorus content equal to the stock diet plus iron, intermittent decompression exerts effects on hepatic iron which are intermediary between the groups just mentioned.

These recent experiments demonstrate that intermittent hypoxia markedly augments the amount and speed of iron uptake by rats on an iron-rich but otherwise "bad" diet, but not by rats on a "good" diet even if heavily laden with iron. The intermediary metabolic effects of the "bad" diet and of intermittent hypoxia seem to act synergistically, promoting speedy and excessive iron absorption and deposition in tissues, initially especially in hepatic cells.

The results of our decompression experiments will be fully reported elsewhere. Yet we feel justified, at this stage, in suggesting that the basic alteration promoting excessive iron uptake in subjects consuming a mealie-meal diet, is not the high iron intake alone. The low calcium and especially phosphate content, coupled particularly with intracellular hypoxia or anoxia (perhaps intermittent, due to seasonally linked malnutrition in man—e.g., pellagra), seem to be of fundamental importance in iron metabolism.

Whatever the mechanism(s), however, one thing seems clear from the foregoing experiment. It is far easier to produce an increased iron uptake and demonstrable hepatic siderosis by dietary iron overload (coupled with intermittent hypoxia) in malnourished than in well-fed animals.

## SUMMARY AND CONCLUSIONS

Histochemical and quantitative chemical data reveal that the uptake of iron from iron-enriched diets, is much greater in rats fed a "bad" (maize-meal) diet than those fed a "good" (stock) diet. This increased iron uptake by rats consuming iron-enriched mealie-meal is reflected in the far greater total carcass iron despite the smaller daily and total iron ingested. It is also characterized by lesser growth of these rats when compared with other groups.

Dietary siderosis in rats is characterized by an accumulation of histochemically demonstrable iron in liver cells before it appears in hepatic phagocytes or other parenchymal cells. Iron absorbed in excess seems to accumulate in the liver to a large extent before other non-reticuloendothelial organs become notably siderotic. In these respects the lesions in rats resemble those in the early stages of African dietary siderosis.

The colon becomes heavily laden with iron whereas the duodenum remains virtually free of it even in heavily siderotic rats.

The histochemically and chemically determined distribution of iron in these experiments, taken in the light of data from the literature, adds additional information in support of the possibility that the underlying lesion in nutritional siderosis pertains to the intracellular iron-containing enzymes located on the mitochondria. The role of intracellular hypoxia (or anoxia), perhaps induced by malnutrition in increasing the speed and degree of iron uptake and the onset of hepatocellular siderosis, is discussed in the light of the present results.

It is concluded that dietary siderosis in rats and, perhaps, in man, too, is not due to iron overload alone but may rather be attributable to some effects of a "bad" diet on intracellular metabolism.

## REFERENCES

1. Gillman, J., and Gillman, T. Structure of the liver in pellagra. *Arch. Path.*, 1945, 40, 239-263.
2. Gillman, J., and Gillman, T. Perspectives in Human Malnutrition. A Contribution to the Biology of Disease from a Clinical and Pathological Study of Chronic Malnutrition and Pellagra in the African. Grune & Stratton, New York, 1951, 584 pp.
3. Walker, A. R. P., and Arvidsson, U. B. Iron "overload" in the South African Bantu. *Tr. Roy. Soc. Trop. Med. & Hyg.*, 1953, 47, 536-548.
4. Higginson, J. The liver in haemochromatosis. (Letter to the editor.) *Lancet*, 1957, 1, 994-995.
5. Steinkamp, R.; Dubach, R., and Moore, C. V. Studies in iron transportation and metabolism. VIII. Absorption of radioiron from iron-enriched bread. *A. M. A. Arch. Int. Med.*, 1955, 95, 181-193.

6. Kinney, T. D.; Hegsted, D. M., and Finch, C. A. The influence of diet on iron absorption. I. The pathology of iron excess. *J. Exper. Med.*, 1949, **90**, 137-146.
7. Taylor, J.; Stiven, D., and Reid, E. W. Haemochromatosis in a depancreatized cat. *J. Path. & Bact.*, 1931, **34**, 793-797.
8. Rather, L. J. Hemochromatosis and hemosiderosis. Does iron overload cause diffuse fibrosis of the liver? *Am. J. Med.*, 1956, **21**, 857-866.
9. Hegsted, D. M.; Finch, C. A., and Kinney, T. D. The influence of diet on iron absorption. II. The interrelation of iron and phosphorus. *J. Exper. Med.*, 1949, **90**, 147-156.
10. Factors affecting iron absorption. *Nutrition Rev.*, 1958, **16**, 113-114.
11. Dry, D. S. Improved methods for the demonstration of mitochondria glycogen, fat and iron in animal cells. *South African J. Sc.*, 1945, **41**, 298-301.
12. Gillman, J., and Gillman, T. Anoxia and the liver with special reference to shock and chronic malnutrition. *Am. J. Digest. Dis.*, 1949, **16**, 348-372.
13. Gillman, T. Nutrition, liver disease and some aspects of ageing in Africans. Ciba Foundation Colloquia on Ageing. 3. Methodology of the Study of Ageing. Little, Brown & Co., Boston, 1957, **3**, 104-114; 188-190.
14. Gillman, T.; Hathorn, M., and Lamont, N. Liver disease in Durban Africans. Histological findings in biopsies. *South African J. Med. Sc.*, 1959, (in press).
15. Gillman, T., and Ivy, A. C. A histological study of the participation of the intestinal epithelium, the reticulo endothelial system and the lymphatics in iron absorption and transport. Preliminary report. *Gastroenterology*, 1947, **9**, 162-169.
16. Granick, S. Ferritin. IX. Increase of the protein apoferritin in gastrointestinal mucosa as a direct response to iron feeding. The functions of ferritin in the regulation of iron absorption. *J. Biol. Chem.*, 1946, **164**, 737-746.
17. Chapman, D. G., and Campbell, J. A. Effect of calcium and phosphorus salts on the utilization of iron by anaemic rats. *Brit. J. Nutrition*, 1957, **11**, 127-133.
18. Goldberg, L.; Smith, J. P., and Martin, L. E. The effects of intensive and prolonged administration of iron parenterally in animals. *Brit. J. Exper. Path.*, 1957, **38**, 297-311.
19. Bothwell, T. H., and Finch, C. A. The intestine in iron metabolism. Its role in normal and abnormal states. *Am. J. Digest. Dis.*, 1957, **NS2**, 145-158.
20. Bielig, H. J., and Bayer, E. Synthetisches Ferritin, ein Eisen(III)-komplex des Apoferritins. *Naturwissenschaften*, 1955, **42**, 125-126. Cited by Loewus and Fineberg.<sup>22</sup>
21. Mazur, A.; Baez, S., and Shorr, E. The mechanism of iron release from ferritin as related to its biological properties. *J. Biol. Chem.*, 1955, **213**, 147-160.
22. Loewus, M. W., and Fineberg, R. A. The incorporation of iron by apoferritin. *Biochim. et. biophys. acta.*, 1957, **26**, 441-443.
23. Takeda, Y., and Hara, M. Significance of ferrous ion and ascorbic acid in the operation of the tricarboxylic acid cycle. *J. Biol. Chem.*, 1955, **214**, 657-670.
24. Smith, D. L.; Bierwagen, M. E., and Early, T. K. Effect of environmental oxygen tension on intestinal iron absorption. *Proc. Soc. Exper. Biol. & Med.*, 1957, **94**, 710-711.

25. Colehour, J. K.; Borsook, H., and Graybiel, A. Effect of hypoxia on serum iron and the unsaturated iron-binding capacity of serum in rats. (Abstract.) *Am. J. Physiol.*, 1957, 191, 113-114.
26. Goldwasser, E.; Jacobson, L. O.; Fried, W., and Plzak, L. F. Studies on erythropoiesis. V. The effect of cobalt on the production of erythropoietin. *Blood*, 1958, 13, 55-60.
27. Jacobson, L. O.; Goldwasser, E.; Fried, W., and Plzak, L. Cited by Goldwasser *et al.*<sup>26</sup>
28. Gillman, T., and Gillman, J. Mitochondrial origin of cytosiderin (iron pigment) in the liver of human pellagrins. (Letter to the editor.) *Nature, London*, 1944, 154, 148.
29. Iron stores and iron deficiency. (Editorial.) *Brit. M. J.*, 1958, 1, 1167-1168.
30. Cytochrome C levels in iron deficiency without anaemia. *Nutrition Rev.*, 1958, 16, 155-157.
31. Gillman, T. Cell enzymes and iron metabolism in anemias and siderosis. *Nutrition Rev.*, 1958, 16, 353-355.
32. Beutler, E. Iron enzymes in iron deficiency. I. Cytochrome C. *Am. J. M. Sc.*, 1957, 234, 517-527.

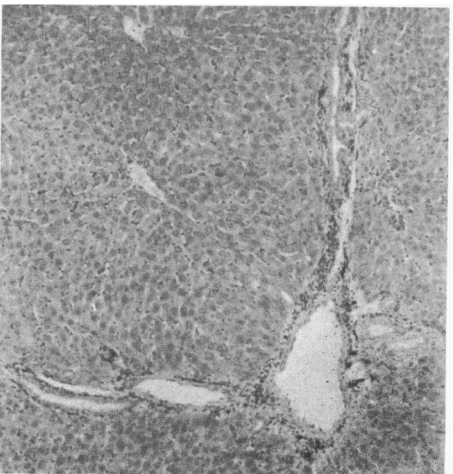
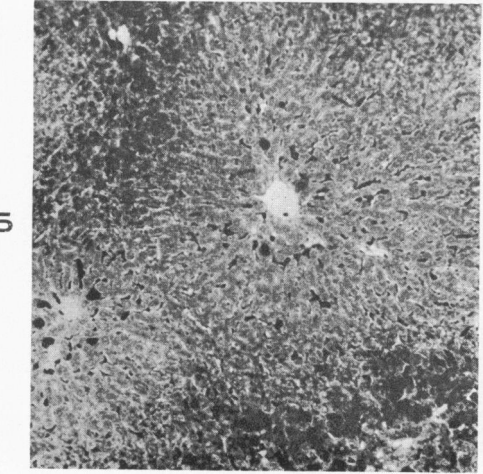
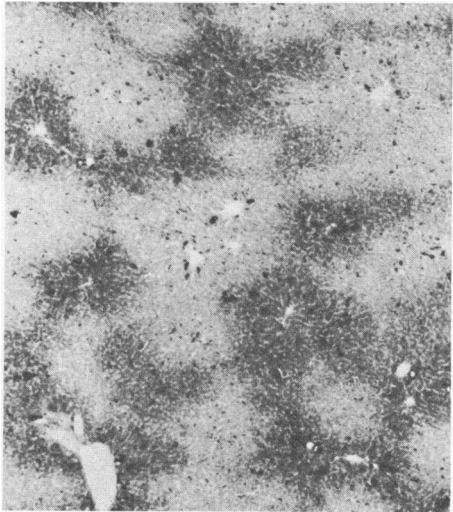
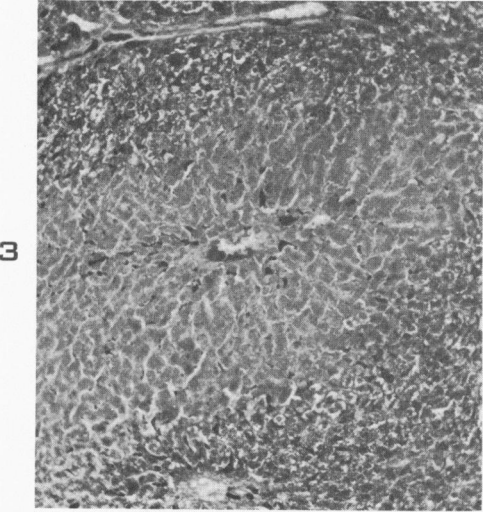
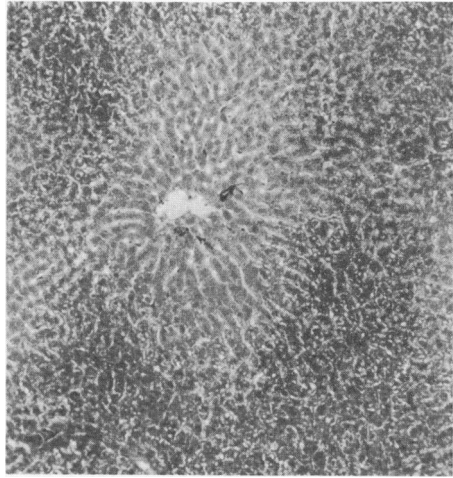
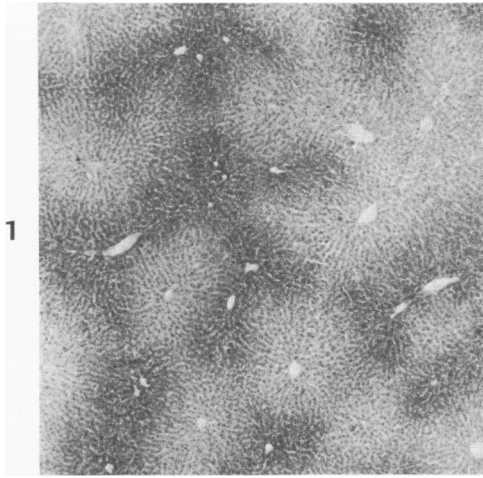
We are grateful to the Schlesinger Organisation for the financial support which made this work possible and to Mrs. Florence Powell for her generous grant in aid of essential library facilities. We also wish to thank Miss M. D. Carolan, Mrs. A. Hart, Miss A. Killerby and Mrs. P. Kruger for secretarial, technical, photographic and histologic assistance, and Mr. H. J. Klomfass, Miss P. Bilbrough, and Messrs. J. Natesen and N. M. Govender for help with animals.

---

#### LEGENDS FOR FIGURES

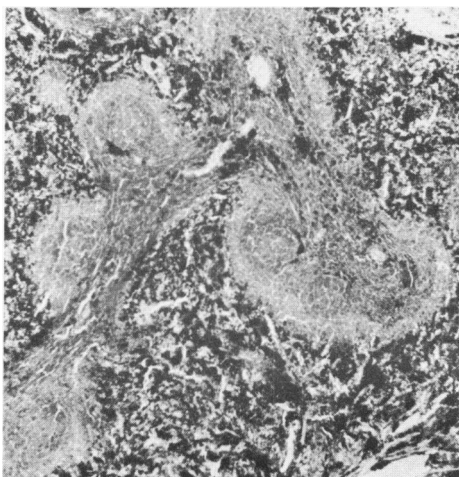
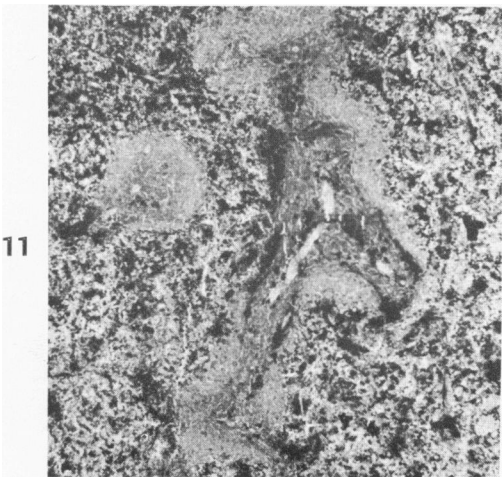
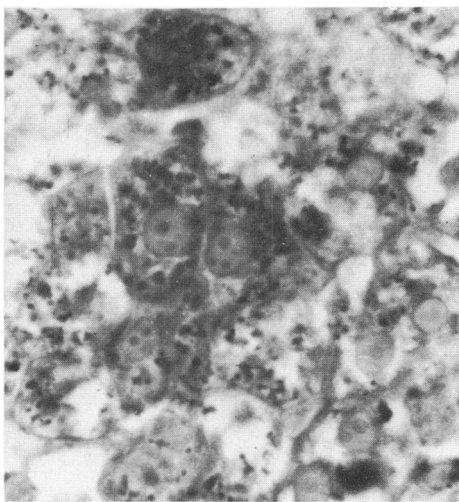
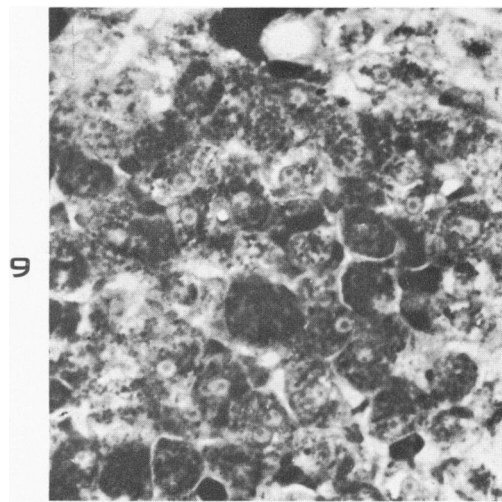
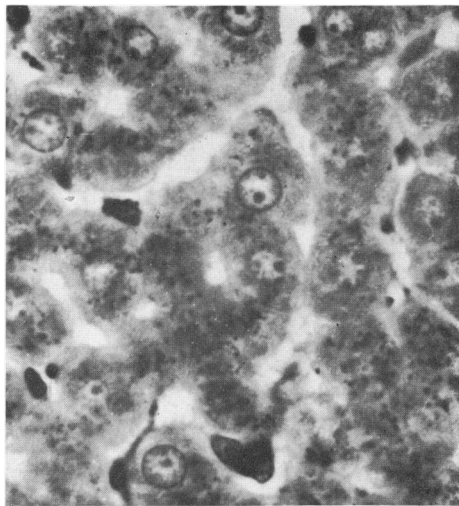
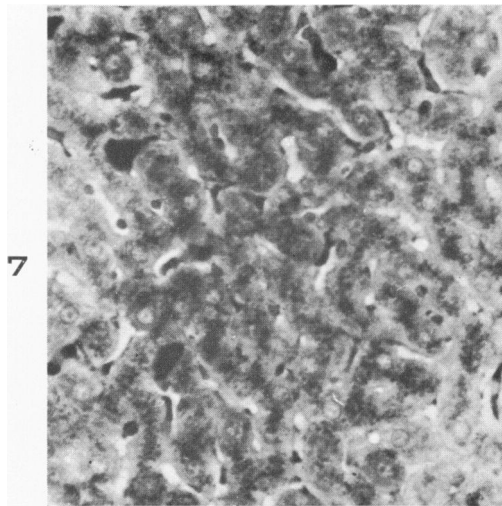
All sections have been stained to demonstrate iron.

- FIG. 1. Liver from rat fed maize-meal plus iron for 50 days, showing moderate amount of iron primarily in periportal epithelial cells.  $\times 30$ .
- FIG. 2. Higher power view of liver in Figure 1, showing majority of iron as fine granules in somewhat vacuolated (non-fatty) periportal liver cells. There are minimal amounts in sinusoidal phagocytes.  $\times 85$ .
- FIG. 3. Liver of rat fed maize-meal and iron for 109 days, showing clumping of iron in hepatic cells, especially periportally, and now also in sinusoidal and portal phagocytes.  $\times 85$ .
- FIG. 4. Low power view, showing heavy siderosis of liver cells as well as sinusoidal phagocytes in a rat fed iron-enriched maize-meal diet for 156 days. Note that periportal liver cells are still most severely siderotic.  $\times 30$ .
- FIG. 5. Higher power view of liver in Figure 4 to show clumping of iron within liver cells and the extent and distribution of iron in phagocytes (compare with Figure 6).  $\times 85$ .
- FIG. 6. Section of liver typical of control rats fed iron-enriched stock diet for 155 days. Note absence of histochemically demonstrable iron in liver cells and only small granules in occasional sinusoidal and portal tract phagocytes.  $\times 85$ .



- FIG. 7. High power view of mid-lobular liver cells to show fine intracellular iron-containing granules near the biliary poles of the cells; also moderate amounts of iron in sinusoidal phagocytes. Rat fed maize-meal plus iron for 155 days.  $\times 375$ .
- FIG. 8. Same section as Figure 7 but showing details of essentially biliary location of the fine iron-containing granules in the liver cells. This appearance is not easily distinguishable from that seen in the liver in the early stages of African siderosis.  $\times 830$ .
- FIG. 9. Diffuse distribution and clumping of iron within the more severely siderotic periportal liver cells in another rat fed maize-meal plus iron for 156 days.  $\times 375$ .
- FIG. 10. Vacuolation (non-fatty) of liver cells, resembling that described in anoxic livers, together with fine and coarse iron granules in liver cells of rat fed maize-meal plus iron for 50 days.  $\times 830$ .
- FIG. 11. Spleen of control rat, fed stock diet plus iron for 154 days, showing moderately severe siderosis of pulp and malpighian corpuscles. Compare with Figure 12.  $\times 30$ .
- FIG. 12. Spleen of rat fed maize-meal plus iron for 156 days. Both the pulp and the corpuscles seem to be somewhat more severely siderotic than in the control spleen (Fig. 11). Clear differences cannot be established with histochemical criteria although quantitative chemical data do show distinctly greater splenic iron in rats consuming mealie-meal plus iron.  $\times 30$ .





- FIG. 13. Femoral bone marrow of rat fed stock diet plus iron for 155 days. Note numbers and sizes of iron-containing (dark black) cells. Compare with Figure 14.  $\times 85$ .
- FIG. 14. Femoral marrow of rat fed maize-meal plus iron for 155 days. Comparison, with a ruler, indicates greater numbers of larger iron-containing phagocytes in any field here than in the control rat marrow exemplified in Figure 13.  $\times 85$ .
- FIG. 15. Typical appearance of colon of rat fed stock-diet plus iron for 155 days, with minimal amounts of iron in either the epithelium or the phagocytes of the *tunica propria*. Compare with Figure 16.  $\times 85$ .
- FIG. 16. Moderate siderosis (fine granules) of colonic surface epithelium and massive siderosis of phagocytes, especially in the *tunica propria* but also in the submucosa, typical of rats fed maize-meal plus iron for 155 days.  $\times 85$ .
- FIG. 17. Typical appearance of duodenum in rats fed maize-meal plus iron for 156 days. Note virtual absence of iron from epithelium of mucosa and submucosal Brunner's glands and even from the phagocytes in the *tunica propria*. This is in striking contrast to the colon.  $\times 85$ .

