

SUDDEN APPARENTLY UNEXPLAINED DEATH DURING INFANCY  
III. PATHOLOGIC FINDINGS IN INFANTS DYING IMMEDIATELY AFTER  
VIOLENCE, CONTRASTED WITH THOSE AFTER SUDDEN APPARENTLY  
UNEXPLAINED DEATH \*

IRENE GARROW, M.D., and JACOB WERNE, M.D.

*(From the Office of the Chief Medical Examiner of the City of New York and the  
Departments of Pathology of the Flushing and St. John's Long Island  
City Hospitals, New York, N.Y.)*

In attempting to evaluate the histologic changes in infants who died suddenly while in apparent good health and in whom the gross necropsy findings were insufficient to explain death,<sup>1</sup> we have found it essential to compare the microscopic findings in these cases with those of infants dying rapidly of unquestioned violence. Only by the study of such control material can one establish what is normal for this age group.

In a routine hospital necropsy service such normal viscera rarely are available for study, since violent deaths usually are referred to the medicolegal authorities. Furthermore, violent deaths are not common in infancy. In the few that do occur, the cause of death usually is evident and therefore these cases are seldom necropsied.

In this paper we are reporting upon the pathologic study of 26 consecutive cases in which the infants died immediately after violence.† Of these, 24 were between 17 days and 18 months of age. This period is within the age range of almost all of our cases of sudden apparently unexplained death during early life. The majority of such cases of sudden death occur within the first 6 months of life and are quite rare after the first year.

Also included in this material are 2 cases falling outside the age period with which we are particularly concerned: one newborn dying of manual strangulation, and a 4-year-old child dying of homicidal suffocation by a pillow. They are included because they represent types of asphyxial death not encountered in the other 24 cases. They also serve as control material for the few cases seen in the neonatal period and in early childhood.

The scarcity of normal control tissues from infants under the age of 7 months (dying immediately after trauma), excluding the new-

\* Supported by a grant from the United States Public Health Service of the Federal Security Agency.

Received for publication, December 10, 1952.

† Two of these infants survived burns  $\frac{1}{2}$  and 1 hour, respectively.

born, is illustrated by the fact that in a medicolegal experience of 20 years in the Borough of Queens, New York City,\* we have been able to accumulate only 10 such cases, as is seen in Table I.

There are no reports in the literature on the weights of organs of infants dying immediately after violence. Because of this lack of information undue significance frequently has been attached to the presence of a "large" thymus gland (status thymicolymphaticus) and "small" adrenal glands (so-called paper thin). Table I shows great variation in the weights of the thymus and adrenal glands of "normal" infants, who were well nourished and free of significant disease. Thymic weights as high as 60 gm. and as low as 18.5 gm. were noted for the same age (Fig. 10). The smallest adrenal glands, weighing 1.6 gm., were found in case 16, an 8-months-old infant dying of illuminating gas poisoning. Because of the variation found in the present control material, the size of thymus and adrenal glands does not seem to be related to the cause of death.

In the infants dying suddenly while in apparent good health, and in whom the gross necropsy findings were inadequate to explain death, we have described two categories of lesions: one local in the respiratory tract and the other comprising vascular, lymphatic, and parenchymal changes. Our observations in this series of "violent deaths" will therefore be presented in these two groups.

## RESPIRATORY TRACT

### *Lungs*

Since the pulmonary findings were found to vary with the manner of death, they will be discussed in relation to the cause of death.

*Drowning.* Five infants (cases 2, 5, 12, 13, and 22) drowned. Grossly, the lungs were light pinkish tan and crepitant (Fig. 9 of this paper and Fig. 2 of Part I of this series<sup>1</sup>). From the cut surface a large amount of watery fluid exuded; pleural petechiae were absent or inconspicuous. Microscopically, the bronchi and pulmonary parenchyma in cases 2, 5, and 12 (ages 17 days, 2½ months, and 7 months) were essentially normal (Figs. 1 and 13; also Figs. 4, 26, 27, and 47 of Part I of this series<sup>1</sup>). Occasional areas in the periphery showed patches of slight collapse and intra-alveolar hemorrhage (Fig. 14). Accumulations of alveolar macrophages were seen within these areas (Fig. 21). In case 13 (8 months old) the lung was normal except in one section where there was bronchial mural lymphocytic infiltration

\* Population now 1,500,000.

TABLE I  
*Infants Dying Immediately after Trauma*

Case no.	Sex	Age	Cause of death	Organ weights in grams	
				Thymus	Adrenal gland
1. ME 43-19	F	Newborn	Manual strangulation		
2. ME 47-112	M	17 days	Drowning	8.4	4.8
3. A 3075	F	2 mos.	Extensive burns	40.8	3.0
4. ME 49-5	M	2 mos.	Suffocation by live steam	25.9	1.8
5. ME 46-101	F	2½ mos.	Drowning	18.5	2.6
6. ME 43-143	M	3 mos.	Aspiration of stomach contents following impaction of safety pins in pharynx and esophagus	25.0	2.45
7. ME 47-47	F	3 mos.	Illuminating gas poisoning	28.1	2.0
8. ME 47-27	M	3 mos.	Extensive burns	29.0	2.3
9. ME 48-109	F	6 mos.	Suffocation by live steam	22.5	2.3
10. A 2582	M	6 mos.	Death under ether anesthesia for repair of cleft palate	40.0	
11. ME 46-82	M	6 mos.	Extensive burns	33.7	3.6
12. ME 39-122	F	7 mos.	Drowning	40.0	
13. ME 42-65	M	8 mos.	Drowning	18.5	2.0
14. ME 44-44	F	8 mos.	Aspiration of stomach contents following suspension from bed by shoulders in sleeping bag	30.0	1.6
15. ME 48-13	M	8 mos.	Aspiration of stomach contents following wedging of head in angle of crib	46.9	2.5
16. ME 51-62	M	8 mos.	Illuminating gas poisoning	27.0	1.5
17. ME 44-114	M	8 mos.	Strangulation by harness	28.3	2.8
18. ME 42-196	M	8 mos.	Strangulation by rope, homicide	60.0	
19. ME 51-257	M	9 mos.	Suffocation by live steam	50.0	
20. 44-RA-15	F	9 mos.	Extensive burns	17.4	1.9
21. ME 42-67	M	9 mos.	Extensive burns	31.0	3.0
22. ME 45-75	M	9 mos.	Drowning	22.7	3.7
23. ME 50-144	M	16 mos.	Asphyxia by aspiration of lollypop	47.5	3.0
24. 51-A-95	M	18 mos.	Asphyxia by compression of chest by overturned dresser		
25. 42-A-72	F	18 mos.	Asphyxia by blood clot surrounding impacted eggshell in larynx	32.0	
26. A 3809	M	4 yrs.	Homicidal suffocation by pillow	30.6	3.1

and epithelial degeneration. In the lung parenchyma immediately adjacent to this area of bronchitis there was thickening of the alveolar wall, mainly due to the presence of numerous mononuclear cells. This histologic appearance warranted a diagnosis of focal interstitial pneumonitis. In this case serous fluid was found in both mastoids. It is of interest that this infant was described as having been "extremely cranky" the day that it was accidentally drowned.

One other case (no. 22), 9 months old, also had focal interstitial pneumonitis similar to that described in the preceding cases (Fig. 11). An adjacent bronchus and a section of trachea showed non-suppurative mural infiltration. Elsewhere in this infant's lung there was a single nodule, approximately 0.5 cm. in diameter, which in the gross resembled a tuberculous focus. Microscopically, this proved to be an area of organized pneumonia (Fig. 12). This infant had had whooping cough 6 weeks before. It should be emphasized that except for these two small areas, the lung was normal (Fig. 13).

*Carbon Monoxide Asphyxia.* In cases 7 and 16 death resulted from accidental illuminating gas poisoning. Blood carbon monoxide saturations of 65 and 60 per cent were found. In both cases the blood and viscera showed typical cherry-red discoloration. Pleural petechiae were not seen. Both cases showed gross pulmonary edema. Microscopically, the lungs showed widespread intra-alveolar edema and patchy atelectasis (Fig. 17). Congestion of alveolar capillaries was moderate. The number of intra-alveolar macrophages varied from one section to another. In some areas they were extremely numerous, resulting in complete filling of the alveoli. The bronchi showed only slight epithelial degeneration; there was no mural infiltration, hyperemia, edema, or mucous gland degeneration.

*Conflagrations.* The infants designated as cases 3, 8, 11, 20, and 21 died in conflagrations. In cases 3 and 21 the infants were burned in an open carriage out-doors and survived  $\frac{1}{2}$  and 1 hour, respectively. Carbon monoxide saturation of less than 2 per cent was found. In case 8 the carbon monoxide saturation of the blood was 65 per cent. In these cases the bronchial epithelium showed marked desquamation and degeneration as a direct effect of the extreme exposure to smoke (Fig. 2). The injured epithelial cells were mixed with mucus and carbon particles, frequently occluding the lumina. There was no evidence of mural bronchitis. Alveolar capillary congestion, when present, was slight. There was also slight to moderate patchy collapse and slight intra-alveolar edema; in some cases the alveolar macrophages were numerous (Fig. 17). Interstitial edema or hemorrhage was rarely seen

and when present was of limited extent in comparison with the lungs of infants "found dead."

*Suffocation by Steam.* Bronchial epithelial degeneration and desquamation were seen also in the 3 infants dying of suffocation and live steam (Fig. 3). At necropsy the denuded epithelium admixed with edema fluid actually poured from the bronchi. The pulmonary parenchymal changes were less marked but similar to those seen in illuminating gas poisoning.

*Miscellaneous.* Of the remaining 11 cases, 3 infants died of strangulation (Fig. 4), 3 of aspiration of stomach contents (Figs. 15 and 18), 2 of impaction of foreign body in larynx (Figs. 5 and 19), one of homicidal asphyxiation by a pillow, one of asphyxia by compression of chest by an overturned dresser (Fig. 20), and one by overdose of ether during repair of cleft palate. Varying degrees of collapse and of intra-alveolar edema with intra-alveolar accumulations of macrophages and lymphocytes were again encountered. Deviation from the normal was least marked in case 10 (death under ether anesthesia) and in case 25 (asphyxia by blood clot surrounding impacted eggshell). Areas of normal lung, uninvolved by edema or collapse, were seen in all cases in this group, although the amount of normal lung seen varied considerably. Slight mural bronchial lymphocytic infiltration was found in 3 cases (nos. 17, 18, and 24) and marked infiltration in 2 (nos. 23 and 26).

#### *Mastoids*

Grossly normal mastoids were reported in 21 cases. In 4 cases the mastoid antrum and middle ear contained serous fluid or mucoid material. In 2 of these 4 cases sections were available and microscopic study confirmed the presence of early inflammation. Of the 10 grossly normal mastoids that were studied microscopically, 7 were normal (Fig. 37 of Part I of this series<sup>1</sup>); 3 had infiltration of the epithelium lining the air spaces by lymphocytes and eosinophils. In 2 of the 3 latter cases there was also infiltration by a few polymorphonuclear leukocytes. Thus, in 7 cases there was evidence of early mastoiditis, although frank pus was never seen grossly.

#### *Tonsils*

In 14 cases sections of the tonsil were available for study. All but 2 contained follicles with very distinct borders (Fig. 45 of Part I of this series<sup>1</sup>). Even in the 3 cases that showed a few polymorphonuclear leukocytes in the crypts, the follicular borders were distinct.

*Larynx and Trachea*

In 4 cases there was moderate, and in 3 cases there was slight diffuse lymphocytic infiltration of the submucosa of the trachea or larynx. No suppurative or necrotic lesion was found in any case (Fig. 6). Aspiration of stomach contents was seen in 8 cases. In 3 this aspiration was massive and regarded as the cause of death, since it occurred under circumstances in which the infant was unable to free itself from a position of restraint (cases 14 and 15), or unable to dislodge an obstruction in the upper respiratory passages (case 6). When aspiration occurs in association with another and adequate cause of death, such as the presence of a lethal amount of carbon monoxide or extensive burns, it would seem reasonable to regard the aspiration as an agonal event, and purely incidental to the asphyxia-induced vomiting during the unconscious and moribund state.

## OTHER ORGANS

*Brain.* Slight meningeal edema was noted in 2 cases of strangulation; in one case of asphyxia by compression of the chest; and in one case of carbon monoxide asphyxia. Occasional focal, usually perivascular, hemorrhages were noted, particularly in the cases of strangulation. The vessel walls and the extravasated erythrocytes in these involved areas were normal. Thrombi were never seen.

*Adrenal Glands.* Slight hyperemia was found twice in the adrenal glands. In no instance was hemorrhage noted.

*Liver.* In 8 cases occasional minute foci of lymphocytic infiltration were seen in the liver. As a rule these were smaller than those noted in the infants found dead. Sinusoidal congestion was not present. The hepatic cells usually contained abundant glycogen.

*Kidney.* Fifteen cases had minute foci of healed glomerulitis varying from the presence of a single hyalinized glomerulus to several groups of scarred glomeruli in one section. Active glomerulitis was not seen.

*Submaxillary Gland and Testis.* The submaxillary gland was available for study in 8 cases; 2 of these showed minute foci of lymphocytic infiltration. The testis was similarly involved in one of the 7 instances in which sections were taken. In the 3 cases with the lymphocytic infiltration described, there was also either gross or microscopic evidence of early incidental mastoiditis.

*Lymphatic Tissues.* In all but 2 infants the spleen contained large follicles with distinct borders and normally developing conspicuous germinal centers (Fig. 43 of Part I of this series<sup>1</sup>). Demarcation be-

tween the white and red pulp was distinct. In the thymus the Hassall's corpuscles were seen to contain far less nuclear debris than those of infants found dead. Hyperemia was seldom present, hemorrhages were rare, and thrombi were never seen. The cervical, axillary, bronchopulmonary, and peripheral lymph nodes usually had large well defined follicles. Hyperemia was observed in only 6 cases and, when seen, usually was slight: those dying of carbon monoxide asphyxia, burns, or of suffocation by live steam. In these cases the hyperemia was limited to the bronchopulmonary lymph nodes. Minute hemorrhage was encountered in only one instance, a case of suffocation by steam. Depletion of lymphocytes or sinus catarrh was not seen.

#### BACTERIOLOGIC EXAMINATION

In 17 of the 26 cases cultures were taken, usually from one or more of the following sources: tonsil, bronchus, lung, spleen, and heart's blood. Mastoids containing fluid were cultured in several instances. In 6 cases a mixed flora which we considered to be non-pathogenic was recovered. In 3 cases the organs cultured were sterile; in 2 of these only lung and spleen were cultured; in the third, lung, spleen, heart's blood, and cerebrospinal fluid were sterile and non-pathogens were recovered from the bronchus. In 3 cases hemolytic *Staphylococcus aureus*, and in 3 cases *Streptococcus haemolyticus*, was recovered. Two cases had both. These organisms usually were found in tonsil, tracheobronchial tree, or lung; and twice in the mastoid. The spleen and heart's blood in 6 of these cases were sterile. *Strep. haemolyticus* was recovered from the spleen twice; once when it was found also in the tonsil (case 3) and once when it was present in mastoid, lung, and heart's blood (case 16). As a result of these bacteriologic findings in the violent deaths we regard the mere recovery of pathogenic organisms to be of questionable significance.

#### DISCUSSION

The lungs of the 5 infants who drowned were normal except for occasional minute patches of collapse found in the periphery. However, in 2 of the older infants (cases 13 and 22, eight and nine months old) there were lesions consistent with a diagnosis of focal interstitial pneumonitis. These changes were limited in extent. The absence of widespread pulmonary congestion, edema, hemorrhage, and collapse in the remainder of the lung readily distinguished these incidental lesions from the lungs of infants found dead. Since in some of the cases of drowning the post-mortem interval was as much as 18 to 24

hours, it may be concluded that congestion of the lungs in human material is not a post-mortem development as has been alleged.<sup>2</sup>

In the deaths due to causes other than drowning, more prominent, although varying, degrees of edema, collapse, and intra-alveolar accumulation of macrophages and lymphocytes were seen in all of the lungs. Congestion of slight to moderate extent was found in several asphyxial deaths including deaths from carbon monoxide. Hemorrhage was seen only rarely; it was always slight and usually limited to the intra-alveolar spaces. Extravasated red cells were well preserved and thrombi were never seen. The extent of the pulmonary changes seemed related to the rapidity of death and to the age of the subject. When death was slow there was more time for response of the lungs to the stimulus of anoxia. In older infants collapse was less marked, probably because of the better development of their lung structure.<sup>3</sup> A frequent response during even the brief period of agony in these infants was the focal accumulation of macrophages and lymphocytes within the alveoli, especially in association with edema and collapse. This microscopic appearance, when seen in sudden death, has recently been called "mononuclear pneumonia."<sup>4</sup> While it is true that these cells appear in varying numbers in the lungs of infants dying suddenly, this change may be equally prominent in many rapid deaths from violence.

Bronchial epithelial changes were found in those cases exposed to smoke in conflagration and live steam. It is well known that chemical and physical irritants may provoke a response in respiratory epithelium with great rapidity. Winternitz, Smith, and McNamara<sup>5</sup> have shown previously that changes in the lungs in chemical pneumonia were indistinguishable from those of influenza. Bronchial mural lymphocytic infiltration was encountered in 8 cases, 2 of which also had isolated foci of interstitial pneumonitis. In 4 cases the lesions were extremely minimal. All but one of these infants were over 7 months of age. The absence of changes indicating severe bronchial inflammation, such as hyperemia, mural edema, epithelial degeneration, or polymorphonuclear leukocytic infiltration, distinguished these cases of incidental mural bronchitis from those in which the inflammatory lesions of the bronchi were manifestations of fulminating respiratory disease.

The mastoid changes found in 7 cases were interpreted as evidence of recent respiratory inflammation, with the exception of the infant of case 3 who had survived extensive burns for ½ hour. The edema and eosinophilic infiltration found in the lining epithelium of the mastoid



in this case could readily have been a reaction to irritating smoke inhaled by the infant. Therefore, we did not consider it indicative of incidental respiratory disease. In this case, in addition, no lesions were found in any other region of the respiratory tract. In 5 of the 6 cases with early mastoiditis there were other changes seen in the respiratory tract. As already noted, in one case interstitial pneumonitis was found; in 4 others there was either mural bronchial or tracheal submucosal lymphocytic infiltration. In the sixth case in which serous fluid in the mastoid had been found at necropsy and for which there was a history of exposure to the mother with a cold, no sections of the upper respiratory tract were available for study. In 5 of these 6 remaining cases of microscopic mastoiditis the pathologic evidence for the presence of incidental respiratory disease was further supported by the clinical history. In one case there had been medical attention for a cold the day of death; one child had recent pertussis; one had been exposed to a mother with a cold; one had just recovered from a cold; and one (drowning, with interstitial pneumonitis) was reported to have been unusually fretful the day of death.

Since acute respiratory infection is so common in early life, it is not surprising that such incidental lesions were found in the mastoids, tonsils, bronchi, or lung. The mild character and limited extent of the lesions, as well as the absence of generalized visceral congestion, thrombosis, tissue edema, and changes in the lymphatic system, distinguished these tissues of infants dying of violence from those of infants found dead,<sup>1</sup> observed to die,<sup>6</sup> or dying after fulminating clinical infection,<sup>7</sup> in whom the gross necropsy findings were inconclusive.

#### SUMMARY AND CONCLUSION

Gross and microscopic studies of 26 infants, the majority under 1 year of age, dying immediately of violence, revealed the following findings:

The viscera of drowned infants most closely resembled the normal. In violent deaths from other causes focal pulmonary changes consisting of collapse, intra-alveolar edema, and accumulations of alveolar macrophages and mononuclear cells of varying degrees were noted. The pulmonary changes, however, were limited to the alveoli except in those infants dying in conflagrations or exposed to live steam in whom there was, in addition, bronchial epithelial injury.

Multiple, though minimal, lesions indicative of incidental respiratory disease occurred in 6 cases. In 7 additional cases there were single minimal lesions in the respiratory tract.

The absence of morphologic evidence of systemic reaction (vascular or lymphatic tissue) as well as the low incidence of minor respiratory lesions in infants dying immediately after violence is in sharp contrast to the histologic findings in infants dying suddenly while in apparent good health. This contrast establishes the pathologic significance of the microscopic findings we have described in the previous two papers of this series.<sup>1,6</sup>

## REFERENCES

1. Werne, J., and Garrow, I. Sudden apparently unexplained death during infancy. I. Pathologic findings in infants found dead. *Am. J. Path.*, 1953, 29, 633-675.
2. Durlacher, S. H., Banfield, W. G., Jr., and Bergner, A. D. Post-mortem pulmonary edema. (Abstract.) *Am. J. Path.*, 1951, 27, 688.
3. Engel, S. *The Child's Lung*. Edward Arnold & Co., London, 1947, p. 31.
4. Gruenwald, P., and Jacobi, M. Mononuclear pneumonia in sudden death or rapidly fatal illness in infants. *J. Pediat.*, 1951, 39, 650-662.
5. Winternitz, M. C., Smith, G. H., and McNamara, F. P. Epithelial proliferation following the intrabronchial insufflation of acid. *J. Exper. Med.*, 1920, 32, 205-209.
6. Werne, J., and Garrow, I. Sudden apparently unexplained death during infancy. II. Pathologic findings in infants observed to die suddenly. *Am. J. Path.*, 1953, 29, 817-831.
7. Garrow, I., and Werne, J. Pathologic findings in infants dying after fulminating illness. (To be published.)

## LEGENDS FOR FIGURES

- FIG. 1. Case 2 (ME 47-12). Male, 17 days old. Drowning. Lung: Normal bronchus and surrounding parenchyma.  $\times 40$ .
- FIG. 2. Case 8 (ME 47-27). Male, 3 months old. Extensive burns. Lung: Agonal aspiration of stomach contents. Normal bronchial wall. Intra-alveolar edema and slight macrophage proliferation.  $\times 40$ .
- FIG. 3. Case 19 (ME 51-257). Male, 9 months old. Suffocation by live steam. Lung: Marked epithelial degeneration and desquamation. Minute patches of collapse are seen also.  $\times 20$ .
- FIG. 4. Case 18 (ME 52-196). Male, 8 months old. Homicidal strangulation by rope. Lung: Slight collapse and presence of edema fluid and macrophages in the alveoli may be seen. There is no congestion despite a post-mortem interval of 20 hours.  $\times 20$ .
- FIG. 5. Case 25 (42-A-72). Female, 18 months old. Asphyxia by blood clot surrounding impacted eggshell in larynx. Lung: Normal lung, well aerated alveoli, complete absence of congestion, alveolar macrophages, or edema.  $\times 4$ .
- FIG. 6. Case 24 (51-A-95). Male, 18 months of age. Asphyxia by compression of chest by overturned dresser. Vocal cord is normal.  $\times 20$ .
- FIG. 7. Case 6 (ME 43-143). Male, 3 months old. Aspiration of stomach contents following impaction of safety pins in pharynx and esophagus. Larynx shows normal epithelium and mucous glands, with no infiltration. Aspirated material is visible in the lumen.  $\times 20$ .
- FIG. 8. ME 52-273. Male, 7 months old. Accidental strangulation by harness. Cervical lymph node.  $\times 9$ .

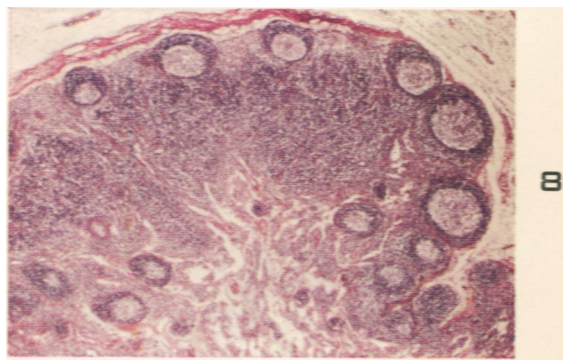
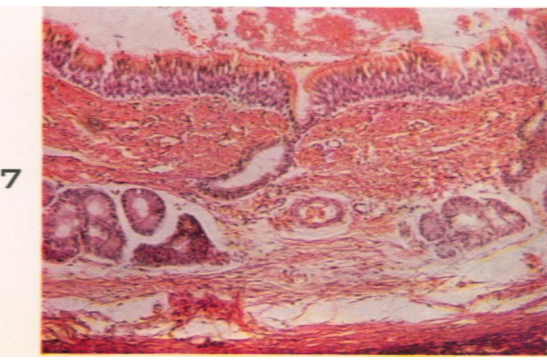
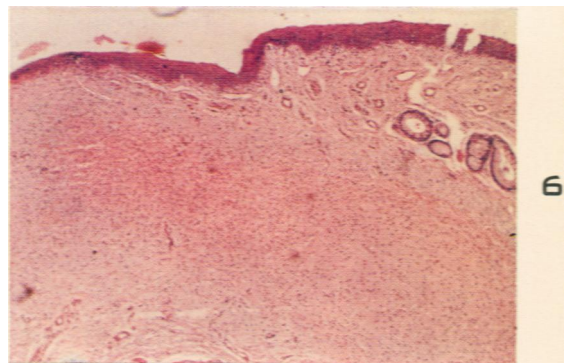
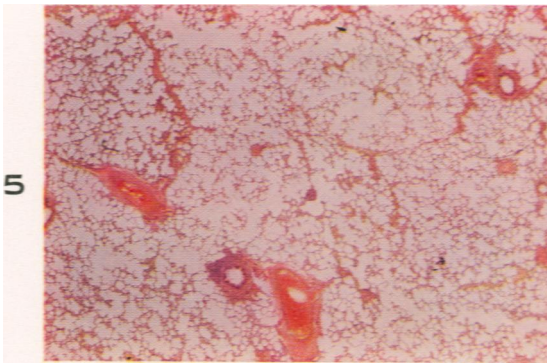
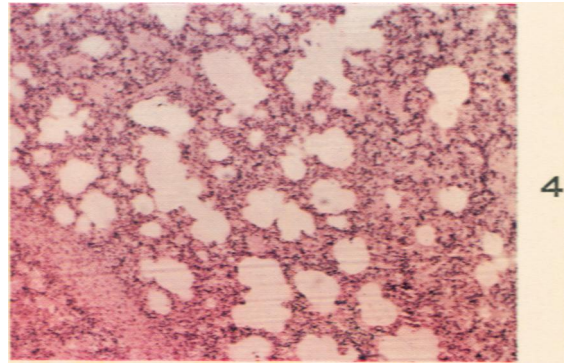
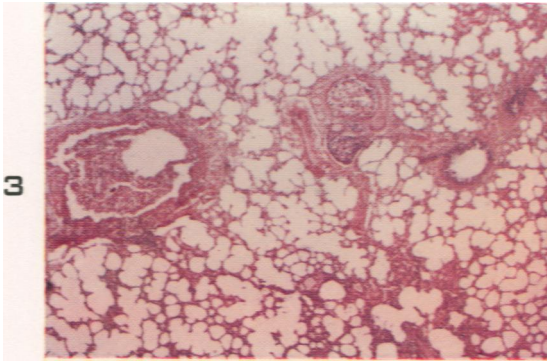
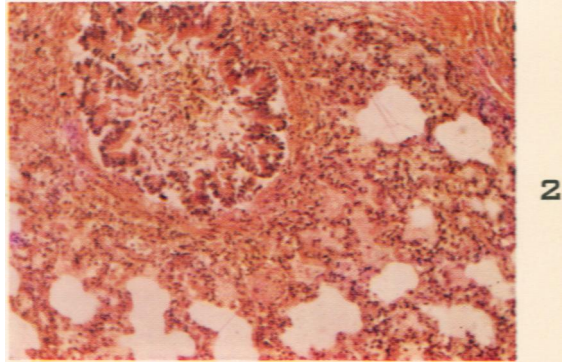
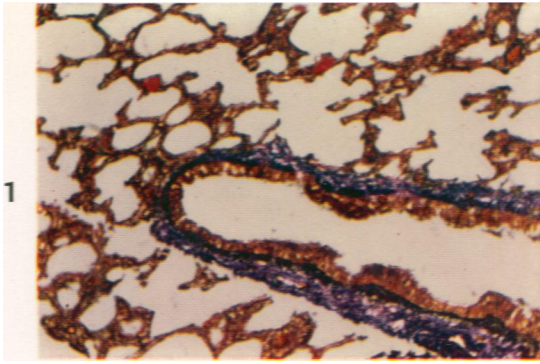


FIG. 9. Case 13 (ME 42-65). Male, 8 months old. Drowning. Pale lung; no congestion. A few petechiae are seen.

FIG. 10. Case 18 (ME 42-196). Male, 8 months old. Homicidal strangulation by rope. Normal thymus, 60 gm. Normal adrenal glands. Petechiae are absent.

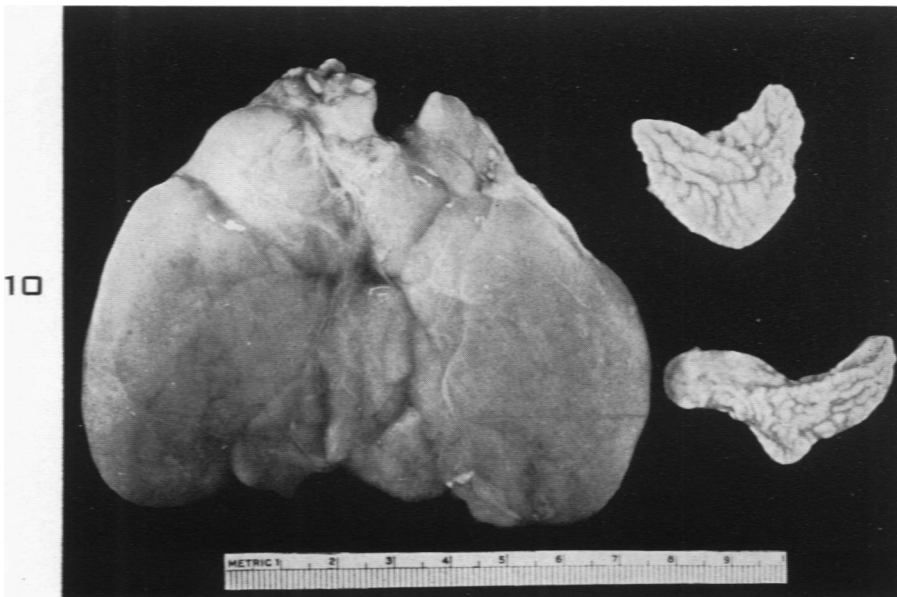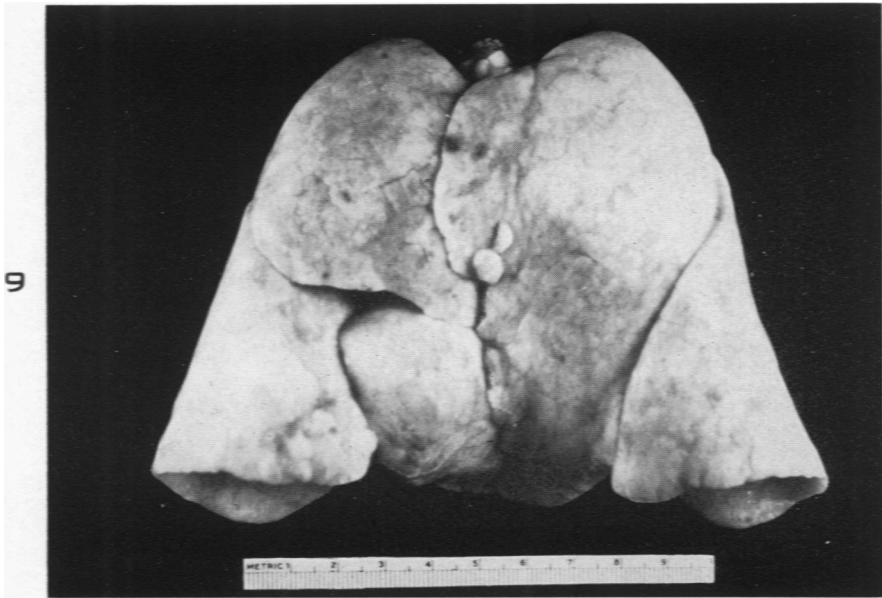


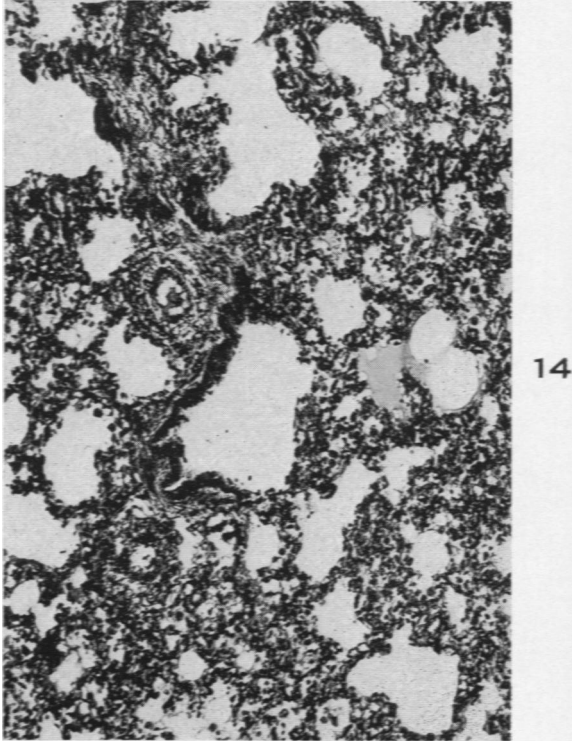
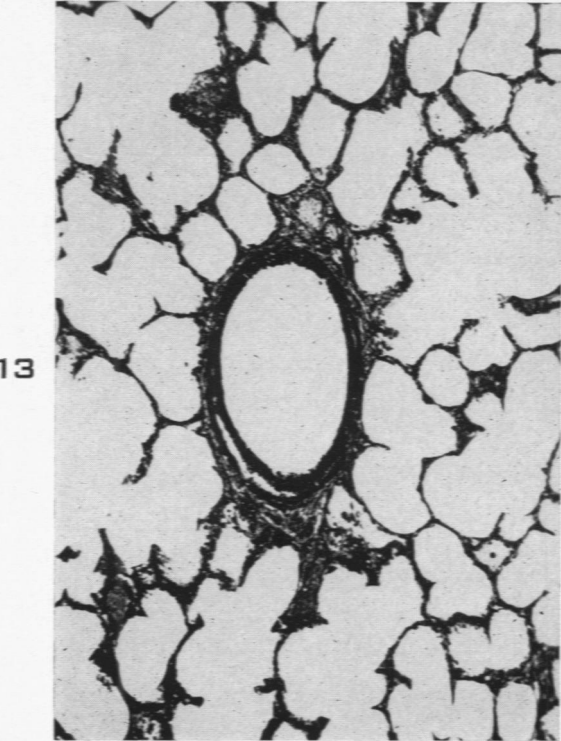
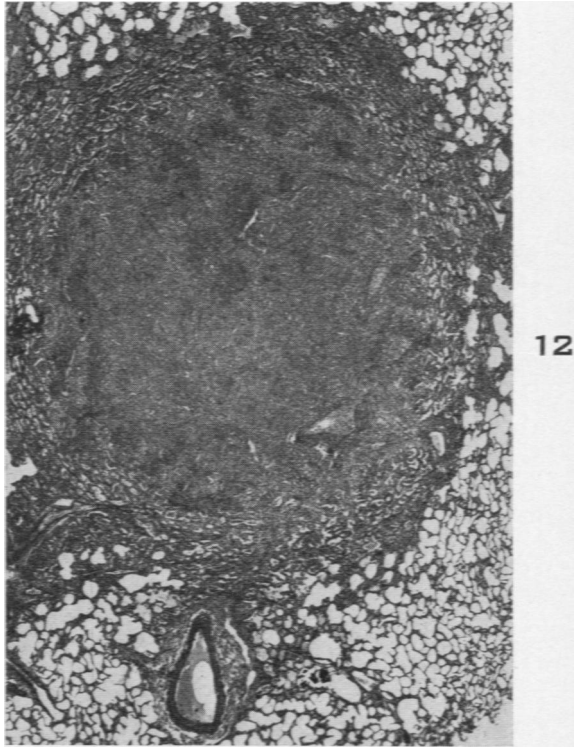
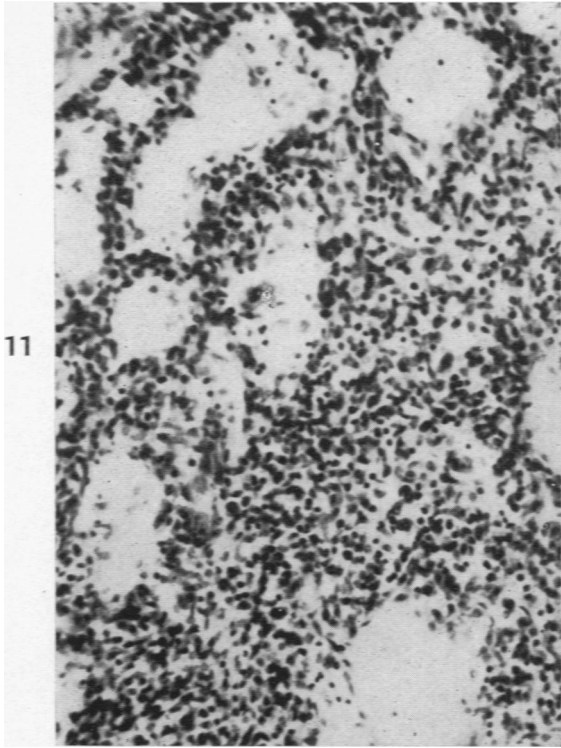
FIG. 11. Case 22 (ME 45-75). Male. 9 months old. Drowning. Lung: Interstitial pneumonitis, incidental finding. Remainder of lung was normal.  $\times 205$ .

FIG. 12. Same case as that from which Figure 11 was taken. Lung: Residual organizing pneumonitis. The adjacent parenchyma is normal, with no congestion or edema.  $\times 12$ .

FIG. 13. Higher power ( $\times 110$ ) of normal lung in periphery of Figure 12.

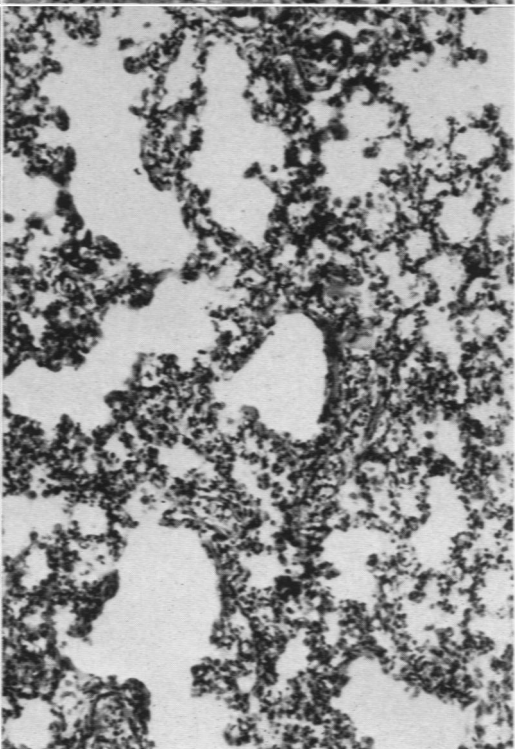
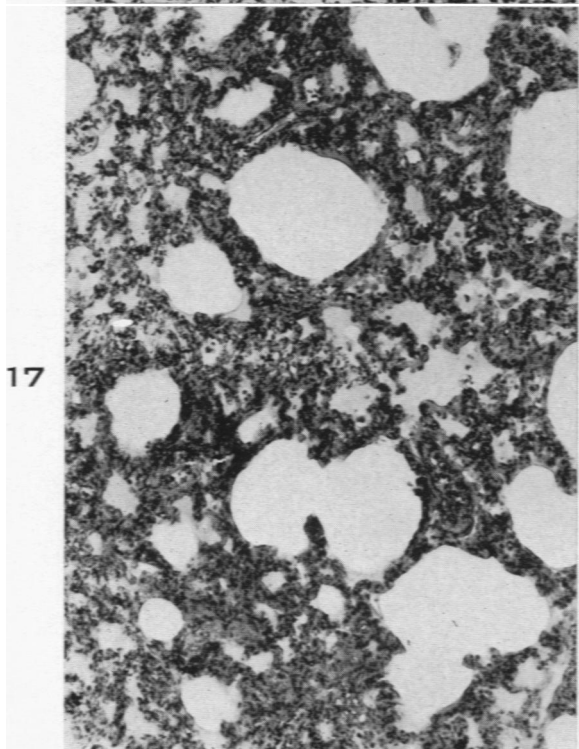
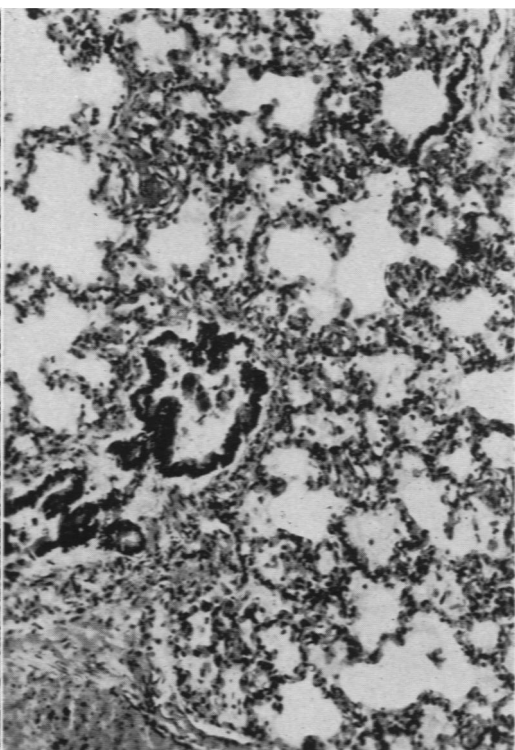
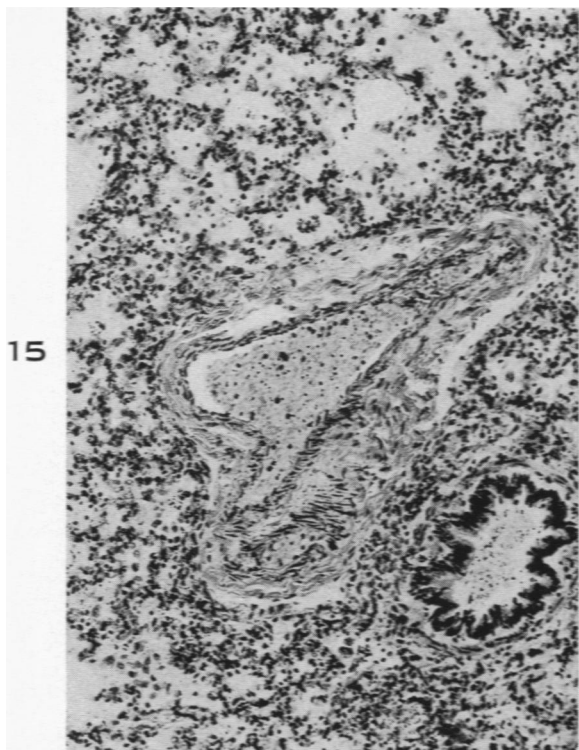
FIG. 14. Case 5 (ME 46-101). Female.  $2\frac{1}{2}$  months of age. Drowning. Lung: Slight collapse; a few alveolar macrophages and edema fluid are seen. This was present in only small areas in the periphery.  $\times 110$ .





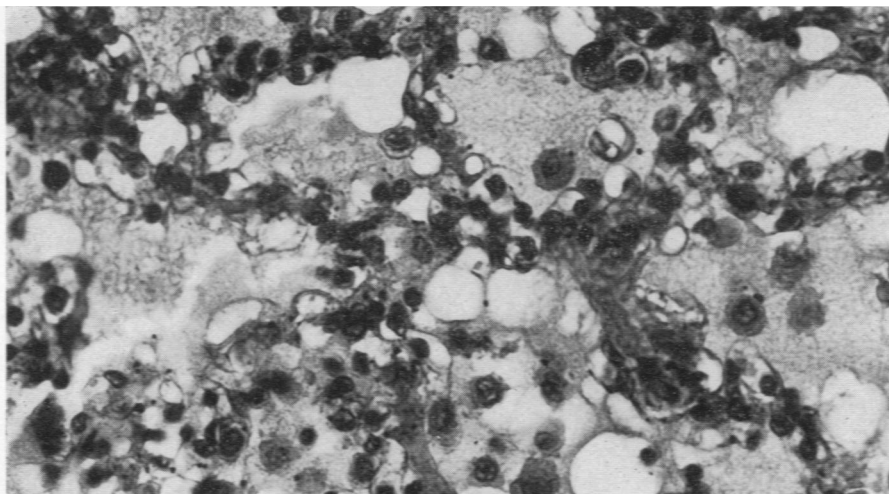
- FIG. 15. Case 14. (ME 44-44). Female. 8 months old. Aspiration of stomach contents while in restraint. Lung: Of note are the intra-alveolar edema and the presence of intra-alveolar macrophages. No congestion.  $\times 110$ .
- FIG. 16. Case 8 (ME 47-27). Male. 3 months old. Extensive burns. Lung: Same changes as in Figure 17.  $\times 110$ .
- FIG. 17. Case 16 (ME 51-62). Male. 8 months of age. Carbon monoxide asphyxia. Lung: The congestion of alveolar walls is more marked than in other traumatic deaths, but is less prominent than that seen in the great majority of infants "found dead."  $\times 110$ .
- FIG. 18. Case 6 (ME 43-143). Male, 3 months old. Aspiration of stomach contents following impaction of safety pins in pharynx and esophagus. Lung: Intra-alveolar edema and macrophages; minimal congestion.  $\times 110$ .



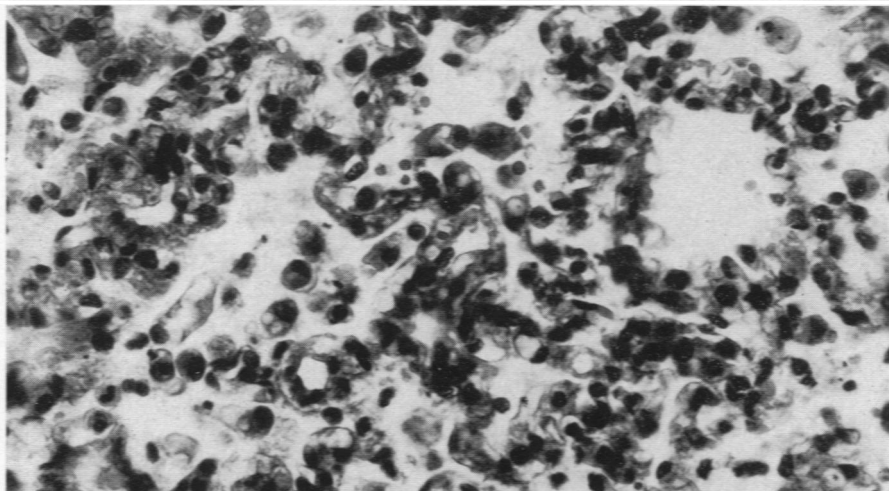


- FIG. 19. Case 23 (ME 50-144). Male, 16 months old. Asphyxia by aspiration of lollypop. Lung: Intra-alveolar edema, macrophages, and lymphocytes.  $\times 460$ .
- FIG. 20. Case 24 (51-A-95). Male, 18 months old. Asphyxia by compression of chest by overturned dresser. Lung: Of note are the intra-alveolar edema and the presence of macrophages. This was seen only in focal areas.  $\times 460$ .
- FIG. 21. Case 5 (ME 46-101). Female,  $3\frac{1}{2}$  months of age. Drowning. Lung: Intra-alveolar macrophages (high power of Fig. 14). Absence of congestion in the alveolar capillaries in Figures 19, 20, and 21 is to be noted when compared to Figures 46 to 48 of Part I.<sup>1</sup>

19



20



21

