

Mendelian recessive inheritance. In this condition there is probably a partial defect in organic binding of iodine in the thyroid gland, and compensatory goitre results from increased secretion of thyrotrophin.

The authors wish to express their thanks to Drs. J. M. McKenzie, G. C. McMillan, and A. C. Ritchie for their kind interest and advice.

## PULSELESS SYNDROME\*

G. A. COPPING, M.D., C.M., M.R.C.P.(L),  
F.R.C.P.[C],† Montreal

INTEREST in the "pulseless syndrome" dates from Takayashu's article of 1908. Since then there has been a considerable literature, including several surveys,<sup>1-4</sup> in which the disease as a whole and its particular effect on certain body systems have been extensively studied. Reviewing the published material allows for certain generalizations:

1. The pulselessness occurs most often in the vessels from the aortic arch.
2. There are several possible pathological processes responsible.
3. The affected vessels from the aorta are most often narrowed close to their origin.
4. The symptomatology produced is varied.
5. A certain homogeneous group of considerable interest has emerged. This grouping, originally based on clinical similarities, seems increasingly to present specific pathological findings as well.

### THE PULSELESS SYNDROME (OR DISEASE)

There are two principal groups among the cases published, those in which the pulseless state is secondary to an atherosclerotic and thrombosing process at the mouth of the vessel and those in which the closure is the result of vessel wall fibrosis with secondary contraction. The former group, which has the age, sex and other incidence features of its underlying process, is capable of specific diagnosis, and the term "pulseless" need serve it only as a descriptive clinical term. In the second group, however, the basic pathological process is not sufficiently understood to allow for etiological diagnosis. Hence the use of "pulseless syndrome"; if "pulseless disease" is invoked, it should be with reservation. When one considers the multiplicity of signs and symptoms possible in ischemia of the brain, the eyes and the upper extremities and when one realizes that in addition to the above types there are cases secondary to syphilis, dissecting aneurysms and congenital atresias, it is apparent that any attempt to simplify the situation

### REFERENCES

1. BRAIN, W. R.: *Quart. J. Med.*, **20**: 303, 1927.
2. DERAEMAERKER, R.: *Am. J. Human Genet.*, **8**: 253, 1956.
3. THIEME, E. T.: *Ann. Surg.*, **146**: 941, 1957.
4. MORGANS, M. E. AND TROTTER, W. R.: *Lancet*, **1**: 607, 1958.
5. ELMAN, D. S.: *New England J. Med.*, **259**: 219, 1958.
6. MCGIRA, E. M., HUTCHISON, J. H. AND CLEMENT, W. E.: *Scottish M. J.*, **4**: 107, 1959.
7. FRASER, G. R.: *Pro. Roy. Soc. Med.*, **52**: 1039, 1959.
8. STANBURY, J. B. AND QUERIDO, A. J.: *J. Clin. Endocrinol.*, **16**: 1522, 1956.

by further clinical and pathological definition would be welcome.

### CASE HISTORY

A 35-year-old housewife had been short of breath and unduly fatigued for as long as she could remember, particularly when using her upper extremities. There was a history of possible rheumatic fever at age 3 but there were no details concerning this. At 21, the patient spent five months in bed with enlarged glands of the neck, considered to be tuberculous, from which she recovered completely. A year later, in 1945, a fever of unknown origin appeared and she was again in bed for five months. The onset of this last illness had been associated with breathlessness, precordial pain, 10 days' temperature elevation to 102° F. and an electrocardiogram (ECG) suggestive of pericarditis. For the first time, attention was drawn to absent pulses in the radial and brachial arteries in each arm; it was noted that the carotid and femoral arteries pulsated. In 1947, during a routine examination, the right common carotid artery was found to pulsate only to the upper border of the thyroid cartilage, the left vigorously to the ear. The right femoral pulsation was now reduced and the aortic pulsation, as felt through the abdominal wall, was abnormally small. The arms were notably thin in relation to the size of the legs, and the feet and the hands were cold and clammy. There was clubbing of the fingers. Blood pressure was: arms—0 and legs—170/110 mm. Hg.

The patient continued to complain of tiredness. She married and in 1954 became pregnant, when she was sent for an opinion as to whether the numerous absent pulses and her constant tiredness might not constitute reasons for interrupting the pregnancy. Arguing that the sudden change at delivery from the high pulse-pressure placental circulation might have disastrous effects, permission was given for abortion. At the time of operation, it was noted that the lower aortic calibre was greatly reduced.

After operation, the patient did very well for four years, but in 1958 she developed a spontaneous, subarachnoid hemorrhage. During the next six days there appeared a right hemiplegia and a left retinal vein thrombosis, and the patient died in coma eight days later.

### Post-Mortem Examination

On postmortem examination the most striking external feature was the disproportion between the small, poorly nourished arms and the normally developed and well-nourished legs.

\*Read at the Annual Meeting of the Royal College of Physicians and Surgeons of Canada, January 23, 1960.  
†Associate Professor of Medicine, McGill University; Senior Physician, Montreal General Hospital.

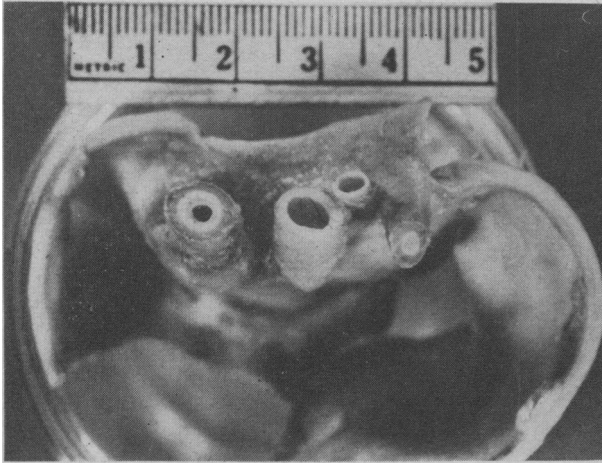

Fig. 1.—Great vessels. This photograph of the aortic arch branches demonstrates: (1) on the left, the greatly thickened and narrowed innominate artery, its coats being distinguishable in the gross; (2) the normal left common carotid artery; (3) the thickened obliterated left subclavian artery. The left vertebral artery has an anomalous origin directly from the aortic arch, can be seen between the left common carotid and the left subclavian vessels and shows no lesion.

The heart itself was normal but the pericardium showed firm, fibrous adhesions nearly obliterating the pericardial sac. The aortic arch was normal but there were striking changes in its branches—the innominate

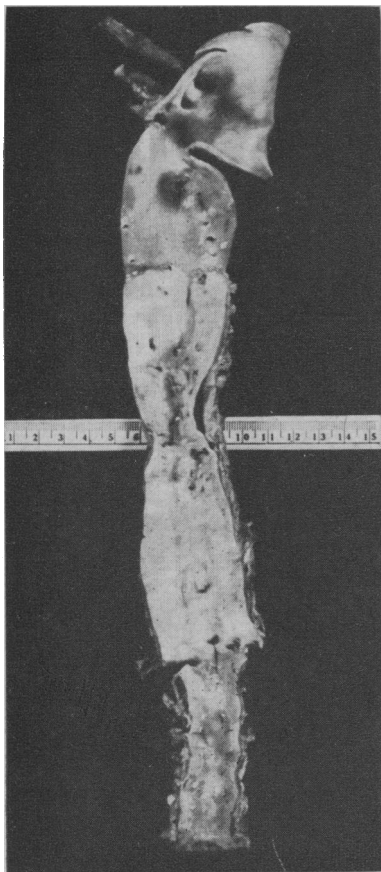


Fig. 2.—Aorta. This photograph of the aorta shows the marked constriction at the diaphragmatic level, and the thickened adventitia at the same level can be seen lying to the side of the curled-in intima and media. Irregular surface discolourations in this region represent erosions over calcific plaques. Midway between the lower end of the arch and the above constriction an abrupt transition between the normal thin yellow intima above and the distal pearly intimal thickening can be readily seen. This thickening extended throughout the rest of the vessel and into its iliac branches.

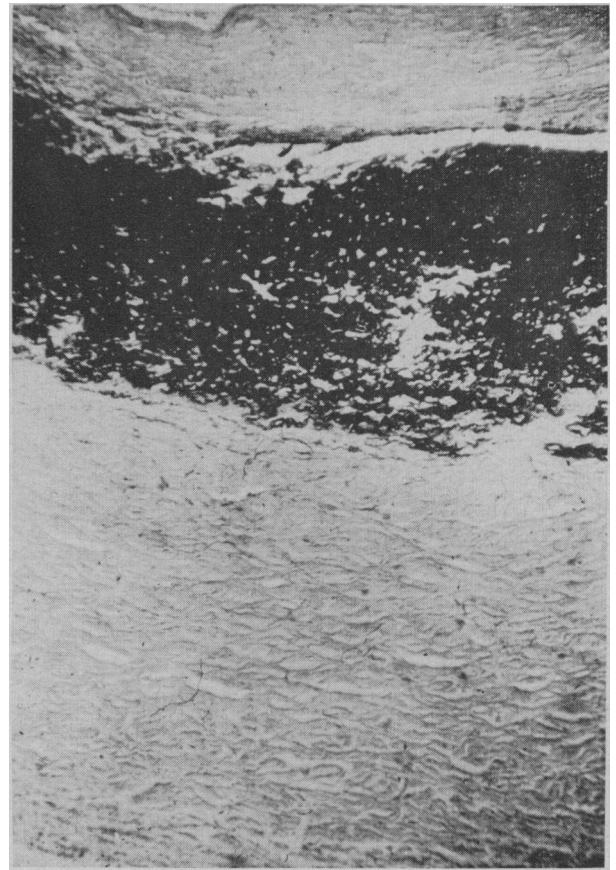

Fig. 3.—Innominate artery wall. (Elastic tissue stain. The lining appears at the extreme top of the section.) The intima and especially the adventitia show great thickening by dense collagenous mature fibrous tissue. That the media has been compressed is indicated by the densely compact elastic tissue. There is no inflammatory reaction.

artery was greatly thickened and stenosed, as were the right common carotid and the two subclavian arteries. In each case the coats of these vessels were clearly defined and the thickening was seen to be of the adventitia and the intima. From the lower half of the thoracic aorta down to its termination, there was a thick, opaque, pearly white fibrous replacement of the aortic intima accompanied by fibrous thickening of the adventitia, and at the diaphragmatic level there was narrowing of the aortic circumference from 4.5 cm. to 2.5 cm. The factor of the organization of mural thrombus cannot be neglected in any attempt to explain intimal thickening but in this case it certainly could not account for the medial and adventitial changes.

The brain showed a ruptured fusiform aneurysm of the congenital type with intracerebral and extracerebral hemorrhage and a cortical thrombophlebitis with infarction of the left hemisphere.

#### DISCUSSION

Pulselessness due to blockage of arteries arising from the aortic arch when not secondary to atherosclerosis occurs most often in young women. It is a manifestation of disease of the upper aortic branches and sometimes, it would appear, of the aorta itself. The disease runs a varying course and there may or may not be systemic reaction. The process is often intermittent with long periods of good health, though with residual disability. The cause or causes are unknown. Its resemblance to

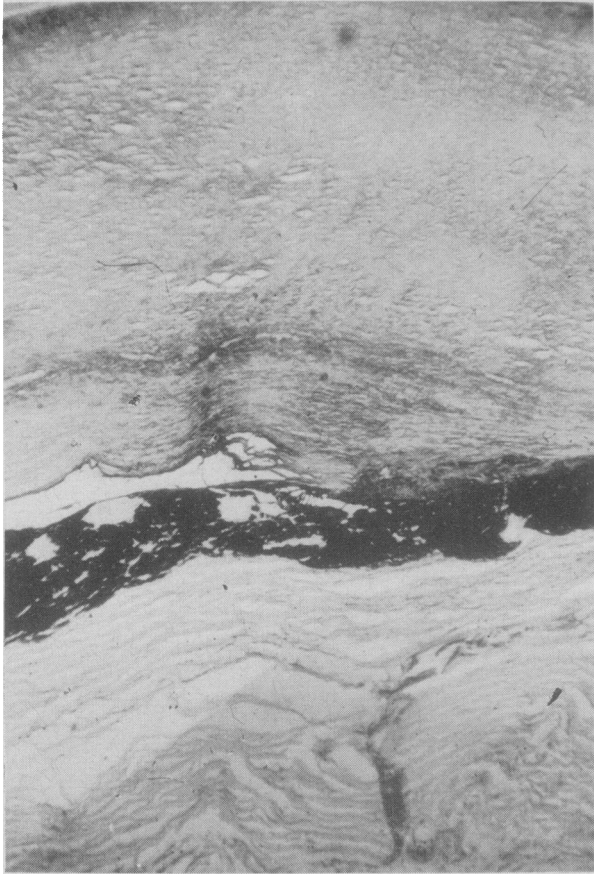


Fig. 4.—Aortic wall at the constriction. (Elastic tissue stain. The lumen can just be seen in the upper corners of the photograph.) The tremendous collagenous thickening of the intima, described in the gross as pearly and opaque, is demonstrated as is the adventitial thickening.

The compression and narrowing of the media described in the section of the innominate artery is also apparent and is even more marked.

necrotizing arteritis, temporal arteritis and thromboangiitis obliterans is not impressive.

The clinical picture is determined by the relative preponderance of cerebral, ocular and upper extremity ischemia and may include such extraordinary features as gangrene of the nose and ear

tips, perforated septum, unilateral cataract and iris atrophy, reduction of the retinal circulation to wreaths of vessels about the retinal discs and a myriad of central nervous system disorders varying from memory loss and mild dementia to hemiplegia and coma. The disease is probably always fatal, but there seems to be a wide spread of possible life expectancy in those who survive. Steroid and anticoagulant therapy have been tried but the intermittent nature of the disease makes it difficult to draw conclusions.

Of particular importance in the study of the disease has been the discovery that the aorta itself may be affected. This opens up a large array of ischemic possibilities. Over half of the aortic length was involved in this present case, and in one previously reported<sup>5</sup> the total vessel was affected; and secondary renal,<sup>6</sup> mesenteric and coronary artery ostial constrictions<sup>1, 7</sup> have been reported. In the present case, the aorta was beginning to be constricted and if the congenital cerebral aneurysm had not ruptured causing death, clinical aortic coarctation might eventually have developed. This seems to be the first instance reported with aortic narrowing and it is also the first with concurrent cerebral aneurysm.

It is suggested that the term "pulseless syndrome" or "pulseless disease" be restricted to the disorder as it occurs typically in young women, when it is due to a stenosing fibrosis of upper aortic branches and sometimes involves the aorta itself.

The author wishes to acknowledge the assistance given by Dr. Howard Root of the Department of Pathology, the Montreal General Hospital, in the preparation of this paper.

#### REFERENCES

1. ASK-UPMARK, A.: *Acta med. scandinav.*, 149: 161, 1954.
2. KALMANSOHN, R. B. AND KALMANSOHN, R. W.: *Circulation*, 15: 237, 1957.
3. PATERSON, M. W.: *Scottish M. J.*, 2: 57, 1957.
4. ROSS, R. S. AND MCKUSICK, V. A.: *A.M.A. Arch. Int. Med.*, 92: 701, 1953.
5. BARKER, N. W. AND EDWARDS, J. E.: *Circulation*, 11: 486, 1955.
6. DANARAJ, R. J. AND ONG, W. H.: *Ibid.*, 20: 856, 1959.
7. FROVIG, A. G.: *Acta psychiat. et neurol. (suppl.)*, 39, 1946.

### A SUMMARY OF EXPERIENCE WITH ALPHA CHYMOTRYPSIN AT THE VANCOUVER GENERAL HOSPITAL\*

JOHN A. McLEAN, M.D. and  
GLENVILLE C. BENDING, M.D.,  
Vancouver, B.C.

THIS PAPER is intended merely as a preliminary assessment of the experience in the use of alpha chymotrypsin (Zonulyn B.D.H.) at the Vancouver General Hospital over a one-year period. Many recent articles in the ophthalmological literature

have discussed the mode of action of alpha chymotrypsin. It is hoped that this article will contribute a little more perspective to the general picture.

Barraquer of Barcelona first discovered that alpha chymotrypsin in a 1:5000 dilution weakened the lens zonule. Alpha chymotrypsin has a specific effect on the lens zonule. In clinical use it apparently affects no other ocular tissue. The use of this drug for zonulolysis has passed from the experimental research phase into practical, daily, and accepted use.

The principal advantage of the use of alpha chymotrypsin is that the lens zonule is broken down chemically over a period of 3 to 4 minutes. Little or no mechanical instrumentation is usually neces-

\*From the Department of Ophthalmology, Vancouver General Hospital.