

## NEPHROTOXIC PROPERTIES OF COPPER UNDER EXPERIMENTAL CONDITIONS IN MICE

WITH SPECIAL REFERENCE TO THE PATHOGENESIS OF THE RENAL  
ALTERATIONS IN WILSON'S DISEASE

F. STEPHEN VOGEL, M.D.

*From the Department of Pathology, The New York Hospital-Cornell  
Medical Center, New York, N.Y.*

Amino-aciduria, glycosuria, proteinuria, calciuria, and phosphaturia<sup>1,2</sup> have been observed frequently in cases of Wilson's disease (hepatolenticular degeneration). It is well known that this disorder is regularly associated with lowered concentrations of copper-binding globulin, ceruloplasmin, and copper in the serum, with deposition of the metal in many tissues, including the kidneys, and with hypercypuria.<sup>3</sup> Although it is also clear that copper has nephrotoxic properties,<sup>4</sup> these have not been defined precisely, and the possible role of copper itself in the pathogenesis of the aforementioned abnormalities remains obscure.<sup>2,5</sup>

Recent studies have shown that fish kept in water to which copper sulfate had been added took up and retained the metal within cells of many tissues. The concentrations in the kidneys equaled those in Wilson's disease, and conspicuous cytologic alterations appeared in the epithelium of the renal tubules.<sup>6</sup> In the present studies, copper has been given to mice in the form of a copper-albumin complex. Under these conditions the metal has accumulated in the kidneys, again in concentrations similar to those occurring naturally in patients with Wilson's disease, and marked necrosis of the epithelial cells of the proximal convoluted tubules has regularly been found. The observations as a whole make it seem likely that copper itself plays an important role in the pathogenesis of the renal abnormalities in hepatolenticular degeneration.

### MATERIAL AND METHODS

Mice received intraperitoneal injections of a copper-albumin complex made by equilibrium dialysis. At regular intervals thereafter the concentrations of copper in various tissues were determined by chemical analysis; the distribution of the metal was studied by histochemical methods;

This investigation was supported by research grant B-803(C<sub>3</sub>) from the National Institute of Neurological Diseases & Blindness of the United States Public Health Service.  
Received for publication, September 28, 1959.

and the cytologic effects were observed in tissues stained by histologic techniques and in individual nephrons dissected from digested specimens. To learn more about the manner of action of copper upon the renal tissues, the effects of reduced glomerular filtration upon the rate of accumulation of metal in the renal parenchyma was observed in animals with ligated ureters, and studies were made of the effects of repeated exposure of the renal epithelium to the metal.

Young adult mice of AKD<sub>2</sub>/JAX strain, 20 to 30 gm. in weight, were used.

#### *Copper-albumin Complex*

A 5 per cent solution of bovine albumin (Armour) was made in demineralized water. In amounts of 300 cc., this solution was encased in cellulose tubing and placed in 3,000 cc. of a 0.0025 M copper sulfate solution (Mallinckrodt, analytical reagent grade) for approximately 6 hours or until the appearance of a fine, cloudy precipitate. Dialysis was then carried out in free-flowing tap water for 3 days. As proved by chemical analysis, one solution used in these studies contained 293 gamma of copper per cc. and another, 199 gamma.

#### *Injection of Copper in Mice*

Forty mice each received an intraperitoneal injection of 1.25 cc. of a solution of copper-albumin that contained 366 gamma of metal. As controls, 24 mice received 1.25 cc. of a 5 per cent solution of bovine albumin. Animals were sacrificed in pairs or groups of 4 at regular intervals from 1 to 144 hours later. In parallel studies 20 mice received injections of 368 gamma of copper in 1.85 cc. of a copper-albumin solution; each cc. contained 199 gamma of copper.

#### *Ureteral Ligation and Copper Injection*

The left ureters of 20 mice were doubly ligated just distal to the renal pelvis. Three days later 12 of the animals were given intraperitoneal injections of 366 gamma of copper in 1.25 cc. of a copper-albumin solution. With 8 mice serving as controls, pairs of animals were sacrificed periodically from 6 to 96 hours thereafter.

#### *Multiple Injections of Copper in Mice*

Thirty mice received intraperitoneal injections of 293 gamma of copper in 1 cc. of copper-albumin solution. Eight were sacrificed in pairs 6, 24, 48, and 96 hours later. Five days after the first injection, the remaining animals were given an injection of 293 gamma of copper, and 8

more were sacrificed in pairs 6, 24, 48, and 96 hours thereafter. Another 5 days after the second injection, the remaining animals received a third injection with 293 gamma of copper, and all animals were sacrificed in pairs 6, 24, 48, 72, and 96 hours later. The morphologic alterations in the kidneys were investigated.

### *Chemical Analysis for Copper*

Tissues for chemical analysis were fixed in 10 per cent formalin made with demineralized water. Quantitative analyses for copper were performed upon duplicate samples by the method of Eden and Green, using the DU Beckman spectrophotometer.<sup>7</sup> The values were expressed in gamma of copper per 100 mg. of wet tissue.

### *Histologic and Histochemical Procedures*

Routinely, small portions of tissue from all principal organs were fixed in 10 per cent formalin. These were embedded in paraffin, sectioned at 4  $\mu$ , and were then stained by hematoxylin and eosin, the periodic acid-Schiff reagent, the von Kossa method for phosphates to show calcification, the Perls method for iron, and histochemically for copper by rubeanic acid.<sup>8</sup>

Nephrons from both normal and experimental mice were dissected by the method of Oliver, MacDowell and Tracy.<sup>9</sup> Digestion by concentrated HCl required approximately 12 hours; the dissected nephrons were lightly stained with Mayer's hematoxylin.

## RESULTS

### *The Effects of Copper upon the Kidneys of Mice*

Promptly after the intraperitoneal injection of copper-albumin, notable elevations occurred in the content of this metal in the liver, kidneys, spleen, and brain (Table I). Within one hour after the injection, copper in amounts of 2.19 gamma per 100 mg. of wet tissue were present in the renal parenchyma and persisted, for more than 6 hours, in concentrations that were 3 to 6 times normal. The content of copper then decreased precipitously and reached normal concentrations approximately 48 hours after the injection. The quantity of metal in the liver and spleen also increased markedly and remained elevated for more prolonged periods; in the neural tissues the content of copper was also notably elevated above the normal.

The kidneys appeared normal to gross examination up to 5 hours after the injection of copper-albumin. Within the next 2 hours notable enlargement of this organ occurred, and marked congestion of the cortex

became evident. Maximally enlarged kidneys, with weights up to 300 mg. (normal, 200 mg.), were present in animals sacrificed 24 and 48 hours after injection. The renal parenchyma was softened, and there was a sharp delineation between the blanched cortex and the dark con-

TABLE I  
THE CONCENTRATION OF COPPER IN THE ORGANS OF MICE RECEIVING  
INTRAPERITONEAL INJECTIONS OF A COPPER-ALBUMIN COMPLEX

Hours after injection	Copper content, gamma per 100 mg. wet tissue				Copper content, gamma per 100 mg. wet tissue	
	Kidney	Liver	Spleen	Brain	Left kidney (ligated ureter)	Right kidney (patent ureter)
0	1.15	1.21	3.97	0.34	0.23	
controls	0.26	1.76	5.88	0.47	0.55	
controls	0.55	1.14	6.27	0.58	0.92	
controls	0.95	0.73	4.11	0.60		
controls	1.30	1.94	1.95	0.83		
1	2.19	3.37	7.93	—		
2	3.65	3.51	—	—		
3	4.17	3.65	6.88	—		
4	4.24	4.53	—	—		
5	3.71	3.70	5.06	—		
6	4.48	3.21	9.04	1.73	0.63	2.05
7	4.17	2.75	—	—		
24	1.26	2.68	10.40	1.72	0.63	2.09
48	0.74	2.39	10.65	2.82	0.53	0.35
72	0.45	1.65	4.45	2.33	0.25	0.75
96	0.16	2.25	7.21	2.83	0.49	0.56
120	—	1.41	6.88	1.99		
144	—	0.23	5.51	2.21		

gested medulla. Death occurred most often during this period, and regularly the kidneys were conspicuously altered. In contrast, the kidneys of animals that survived and were sacrificed 72 to 144 hours after the injection of copper either showed minimal degrees of congestion or were normal in appearance.

The renal tissues taken 6 hours after the injection of copper-albumin, when stained histochemically for copper by rubeanic acid, showed it to be present in abundance and to stain as fine particles in the glomerular tufts and subcapsular spaces as well as in the content of the tubules. Small amounts were present in the epithelial cells of the proximal convoluted tubules, distributed haphazardly in the lumen margins of the cytoplasm (Fig. 1). More marked staining was regularly present in the epithelium 24 hours after the injection, the cells of the proximal convoluted segments and those of the distal conducting tubules staining most intensely (Fig. 2). At these times, the fine granules were distributed irregularly throughout the cytoplasm, but were not found within

the nuclei. In general, there was poor correlation between the quantity of copper that was stained by histochemical methods and the amounts shown to be present by chemical analysis.

The earliest cytologic lesions were clearly evident in the renal tissues taken 6 hours after the injection of copper-albumin. Initially, these were confined to the epithelium of the proximal convoluted segment of the nephrons and were characterized regularly by vacuolation, pale staining, and swelling of the cytoplasm. These alterations progressed rapidly to coagulative necrosis which varied moderately in degree from animal to animal but was ordinarily conspicuous in mice sacrificed 24 hours after the injection of copper. The cytologic changes remained localized to the proximal convoluted tubules. This was true even when they were marked in degree and characterized by lysis or hypereosinophilia of the cytoplasm, pyknosis and karyorrhexis of the nuclei, and extensive cellular desquamation. The tubules were filled with cellular debris. Many of the basement membranes were ruptured and erythrocytes were present in small numbers within the tubules (Fig. 3). Much granular basophilic material was also present in the cellular debris; this stained positively for phosphates and calcification, but did not stain for iron (Fig. 4). Examinations of the renal parenchyma obtained 72 to 144 hours after the injection of copper-albumin regularly showed striking degrees of epithelial regeneration, but with residual pleomorphism, hyperchromasia, and mitotic activity in the reconstituted lining epithelium of the proximal convoluted tubules. The glomeruli and renal blood vessels were unaltered.

#### *Dissected Nephrons of Animals Injected with Copper-Albumin*

The individual nephrons taken from mice 24 to 48 hours after the injection of copper-albumin and examined by light and phase microscopy consistently showed expansion of the proximal convoluted segments and obliteration of the normal epithelial architecture in this region. The delicate pattern of epithelial cells, clearly visible in the control specimens (Fig. 5), was replaced throughout the proximal convoluted segment by amorphous and coarsely granular masses of cellular debris. These filled the proximal convoluted tubules, and around them the basement membranes were swollen and fragmented. The diverticula that were numerous on normal nephrons were even more abundant and were notably dilated in animals that had received copper-albumin. The tubular dilatation and epithelial disruption ended abruptly just proximal to the thin loop of Henle (Fig. 6). The distal tubules were lined by epithelium and did not show significant dilatation, although many cellular casts lay within them. The glomeruli appeared normal.

*The Effects of Reduced Glomerular Filtration Upon the Accumulation of Copper in the Kidneys*

When copper-albumin was injected intraperitoneally into mice that had had the left ureter ligated previously, the content of copper in the left kidney increased only slightly and in amounts readily attributable to increases in the content of copper in the blood of the kidney. In contrast, significant elevations in the content of this metal occurred in the contralateral kidneys (Table I).

As shown in histologic sections, ligation of the ureter in control animals was always followed by dilatation of the tubules, which contained much fluid and were lined by atrophic epithelium. The injection of copper-albumin in such animals was not followed by additional cytologic alterations. Necrosis did not occur in kidneys with ligated ureters, but was regularly conspicuous in the contralateral ones where the histologic alterations were identical to those described above in animals without ureteral ligation.

*The Effects of Repeated Injections of Copper-Albumin*

The renal tissues taken from mice for histologic examination 24 and 48 hours after a single injection of 293 gamma of copper showed necrosis of the epithelium in the proximal convoluted segments of the nephrons. Identical lesions were present in mice examined at the same intervals after second and third injections of copper. Reconstitution of the renal epithelium had largely been completed in animals sacrificed 72 and 96 hours after the third injection. Variable quantities of calcium were present; generally these became greater after multiple injections.

DISCUSSION

The observations make it clear that when copper was injected intraperitoneally in mice in the form of an albumin-complex, it passed promptly into the glomerular filtrate where, in sections stained histochemically for the metal, it was clearly visible in the subcapsular spaces of the glomeruli. As ancillary evidence, stoppage of glomerular filtration by ureteral ligation regularly excluded the metal from the renal parenchyma. It was also clear from the histochemical preparations that copper was then at least partially reabsorbed by the epithelium of the renal tubules, and when present in concentrations comparable to those in patients with hepatolenticular degeneration, as shown by chemical analysis, was accompanied by marked epithelial necrosis in the proximal convoluted tubules. These changes proved fatal in some animals. In others they were transitory, and epithelial regeneration occurred rapidly

but with residual epithelial hyperplasia and calcification. The findings make it evident that therapeutic measures designed to increase the excretion of copper by the kidney in Wilson's disease<sup>10</sup> are potentially hazardous.

It is well known that because persons with hepatolenticular degeneration have a deficiency of the copper-binding globulin, ceruloplasmin, the copper they take in through the gastrointestinal tract is loosely bound by serum albumin in the form of a copper-albumin complex.<sup>3</sup> As has been stated above, the molecular composition and the manner of transmission of the metal through the kidneys of human beings remains obscure,<sup>2,5</sup> and its cytophysiologic effects upon the renal tissues also remain in doubt.<sup>3</sup> Although the present studies provide direct information only about the cytotoxic action of copper upon the nephron, observations by others have provided much evidence to suggest that these cytologic alterations can be correlated directly with certain renal dysfunctions.<sup>11</sup> In this relation, it is also noteworthy that intoxications by other heavy metals, particularly by mercury, cadmium, uranium, and lead, provide additional examples of cytotoxic agents that cause similar cytologic changes in the epithelium of the proximal convoluted tubules, and these are frequently associated with amino-aciduria, proteinuria, and calciuria.<sup>12,13</sup>

#### SUMMARY

When ionized copper was combined with bovine albumin and injected intraperitoneally into mice as a copper-albumin complex, it promptly entered the glomerular filtrate and was taken into the cytoplasm of the renal tubular epithelium. Marked necrosis of the proximal convoluted tubular epithelium occurred when concentrations of copper were present that approximated those frequently found in the kidneys of patients with hepatolenticular degeneration. Death ensued in some animals, while in others epithelial regeneration occurred promptly, with residual epithelial hyperplasia and calcification. The observations as a whole, when considered in the light of observations upon other nephrotoxic agents, make it seem likely that copper itself is an important factor in the pathogenesis of the renal abnormalities of Wilson's disease.

#### REFERENCES

1. UZMAN, L. L., and DENNY-BROWN, D. Amino-aciduria in hepato-lenticular degeneration (Wilson's disease). *Am. J. M. Sc.*, 1948, **215**, 599-611.
2. BEARN, A. G.; YŪ, T. F., and GUTMAN, A. B. Renal function in Wilson's disease, *J. Clin. Invest.*, 1957, **36**, 1107-1114.
3. BEARN, A. G. Wilson's disease; an inborn error of metabolism with multiple manifestations. *Am. J. Med.*, 1957, **22**, 747-757.

4. GONZALES, T. A.; VANCE, M.; HELPERN, M., and UMBERGER, C. J. *Legal Medicine, Pathology and Toxicology*. Appleton-Century-Crofts, Inc., New York, 1954, ed. 2. 767 pp.
5. UZMAN, L. L. On the relationship of urinary copper excretion to the aminoaciduria in Wilson's disease (hepatolenticular degeneration). *Am. J. M. Sc.*, 1953, **226**, 645-652.
6. VOGEL, F. S. The deposition of exogenous copper under experimental conditions; with observations on its neurotoxic and nephrotoxic properties in relation to Wilson's disease. *J. Exper. Med.*, 1959, **110**, 801-810.
7. EDEN, A., and GREEN, H. H. Micro-determination of copper in biological material. *Biochem. J.*, 1940, **34**, 1202-1208.
8. UZMAN, L. L. Histochemical localization of copper with rubeanic acid. *Lab. Invest.*, 1956, **5**, 299-305.
9. OLIVER, J.; MACDOWELL, M., and TRACY, A. The pathogenesis of acute renal failure associated with traumatic and toxic injury. Renal ischemia, nephrotoxic damage, and the ischemic episode. *J. Clin. Invest.*, 1951, **30**, 1307-1439.
10. DENNY-BROWN, D., and PORTER, H. The effect of BAL (2,3-dimercaptopropanol) on hepatolenticular degeneration (Wilson's disease). *New England J. Med.*, 1951, **245**, 917-925.
11. OLIVER, J. An approach towards structural-functional equivalents in the nephron. (The Middleton-Goldsmith Lecture, December, 1958). *Bull. New York Acad. Med.* (In press).
12. WILSON, V. K.; THOMSON, M. L., and DENT, C. E. Amino-aciduria in lead poisoning. A case in childhood. *Lancet*, 1953, **2**, 66-68.
13. CLARKSON, T. W., and KENCH, J. E. Urinary excretion of amino acids by men absorbing heavy metals. *Biochem J.*, 1956, **62**, 361-372.

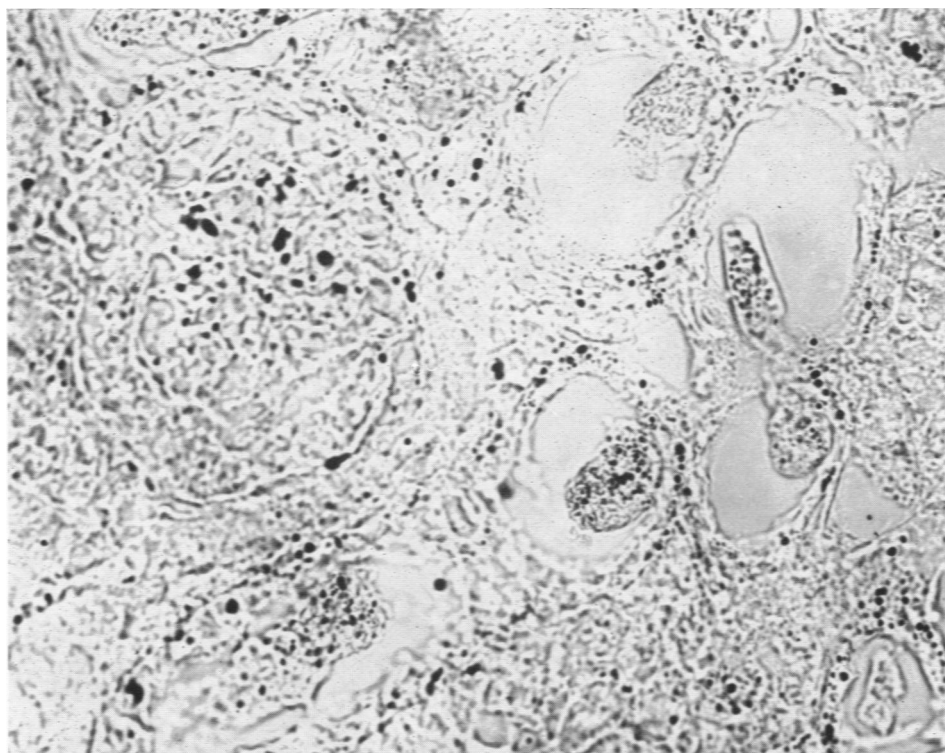
The proficient technical assistance of Miss Lieselotte Kemper is gratefully acknowledged.

---

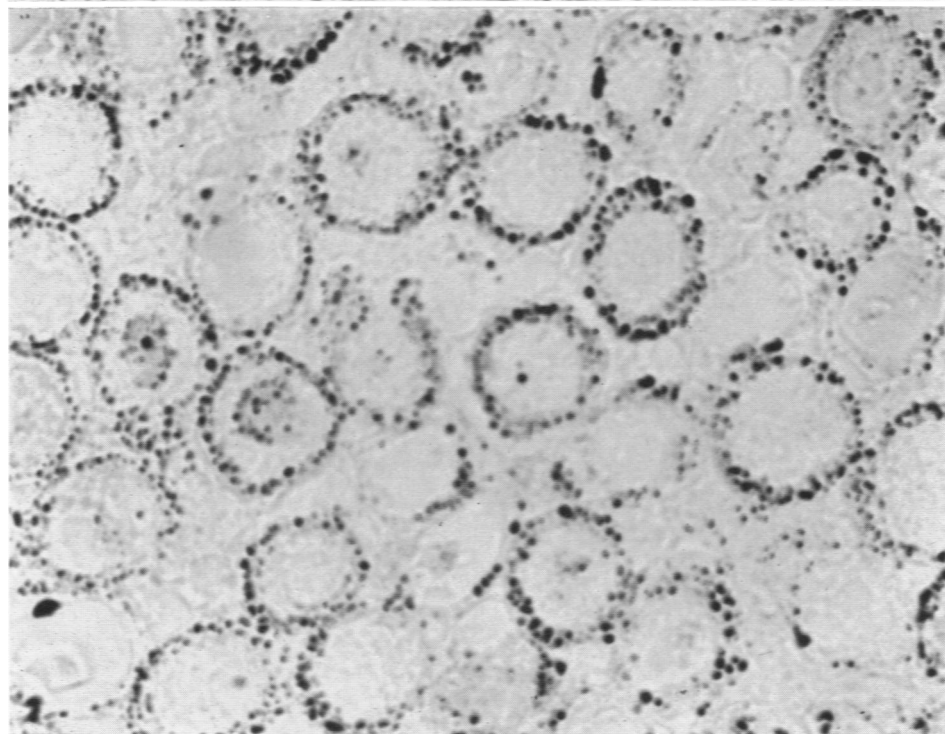
#### LEGENDS FOR FIGURES

- FIG. 1. A mouse received 366 gamma of copper intraperitoneally, as a copper-albumin complex. After 6 hours there is much metal in the renal parenchyma. The stainable copper is particularly abundant in the glomerular tuft shown in the left upper portion of the illustration, and in the contents of the tubules. Some is also present in the cytoplasm of the epithelium lining the tubules. Rubeanic acid stain for copper, without counterstain.  $\times 900$ .
- FIG. 2. Greater quantities of copper are contained in the cytoplasm of the tubular epithelium in a mouse sacrificed 24 hours after the intraperitoneal injection of 366 gamma of metal. Rubeanic acid stain for copper, without counterstain.  $\times 420$ .



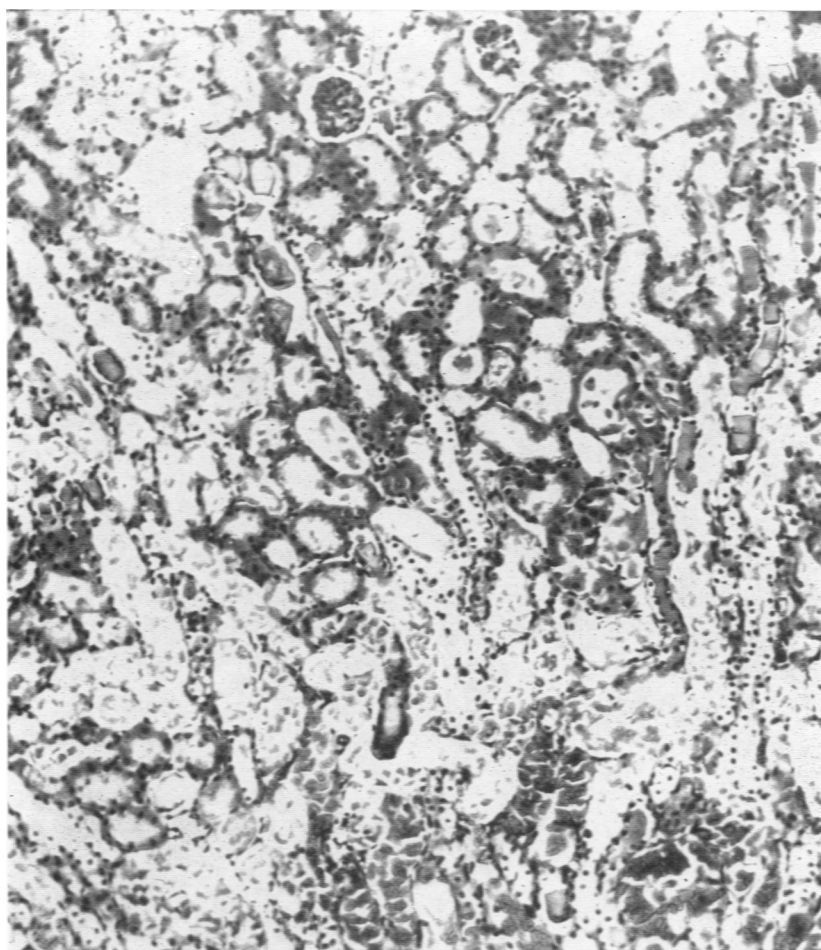


1

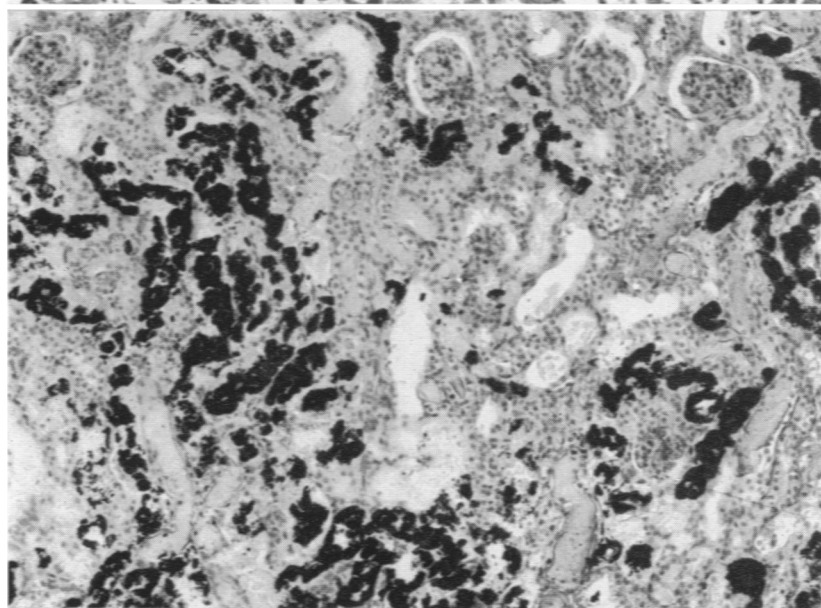


2

- FIG. 3. There is extensive coagulative necrosis of the proximal convoluted tubular epithelium in a mouse with 366 gamma of copper introduced intraperitoneally 24 hours previously. The renal tissues contain 4.48 gamma of copper per 100 mg. of wet tissue, as shown by chemical analysis. Hematoxylin and eosin stain.  $\times 160$ .
- FIG. 4. Marked calcification is present in the renal tubules of a mouse 72 hours after the intraperitoneal injection of 366 gamma of copper. Von Kossa stain.  $\times 180$ .



3



4

- FIG. 5. The normal nephron of a mouse. Mayer's hematoxylin stain.  $\times 38$ .
- FIG. 5A. The normal epithelium of the proximal convoluted tubule forms a regular delicate pattern. Mayer's hematoxylin stain.  $\times 320$ .
- FIG. 6. The proximal convoluted tubule in a mouse 24 hours after the injection of 366 gamma of copper. There are marked, irregular dilatation and extensive degeneration of the epithelium. The basement membrane is swollen. There is a sharp transition at the junction with the nondilated proximal loop of Henle; this segment is lined by intact epithelium. Mayer's hematoxylin stain.  $\times 320$ .

