

# THE MESANGIUM OF THE RENAL GLOMERULUS

## ELECTRON MICROSCOPIC STUDIES OF PATHOLOGIC ALTERATIONS

YASUNOSUKE SUZUKI, M.D.\*; JACOB CHURG, M.D.†; EDITH GRISHMAN, M.D.;  
WILLY MAUTNER, M.D., AND SAMUEL DACHS, M.D.

*From the Department of Pathology, The Mount Sinai Hospital, New York, N.Y.*

The concept of the renal glomerular mesangium was first proposed by Zimmerman<sup>1,2</sup> who conceived it to be a connective tissue stalk extending from the glomerular hilus to the peripheral capillary lobules, providing support for the capillaries. The mesangium immediately became a subject of controversy, with many microscopists supporting Zimmermann<sup>3,4</sup> and others categorically denying his hypothesis.<sup>5,6</sup> McManus<sup>7</sup> used the term "intercapillary space" as mainly representing a potential space which only became important in diseases involving the glomerulus. Jones<sup>8</sup> studied inflammation and repair of the glomerulus and came to the conclusion that these processes essentially affected the mesangium or intercapillary space. Similar conclusions were obtained by the use of phase microscopy.<sup>9</sup>

The controversy concerning the existence of this glomerular component was carried on by numerous investigators using electron microscopic techniques. A number of the early workers in this field<sup>10-19</sup> did not recognize its existence at all and stated unequivocally that the glomerulus consisted only of epithelial and endothelial elements and basement membrane. They considered the mesangial or intercapillary cell to be identical with the endothelial cell. A minority of early workers, including Policard, Collet and Giltaire-Ralyte,<sup>20</sup> Sakaguchi,<sup>21</sup> and Yamada,<sup>22</sup> on the other hand, felt that this element in fact constituted a separate component of the glomerulus. This divergence of opinion has, of course, led to confusion in the interpretation of pathologic alterations.

Later studies, including investigations of the embryologic origin,<sup>23,24</sup> comparative anatomy,<sup>25-27</sup> pathologic reaction,<sup>28-31</sup> and functional significance<sup>32</sup> of these cells, have supported the concept that the mesangium constitutes a separate component of the glomerulus. A number

Supported by Research Grants A-918 and H-1095 from the National Institutes of Health, United States Public Health Service.

Accepted for publication, May 4, 1963.

\* Present address: Department of Pathology, Keio University Medical School, Tokyo, Japan.

† Requests for reprints should be addressed to: Dr. J. Churg, The Mount Sinai Hospital, New York 29, N.Y.

of names have been used, including mesangial cell,<sup>1,2</sup> intercapillary cell,<sup>22,25-28,30,31</sup> deep cell,<sup>32</sup> and interluminal cell aggregates.<sup>24</sup> Even among those workers who accepted the existence of the third cell type, there were differences of opinion as to the nature of the substance found between cells. Some considered this to be an extension of the basement membrane itself<sup>22</sup> or extensions of layers of the basement membrane<sup>25</sup> which separated the mesangial cell from the endothelial cell. Jones, Mueller and Menefee,<sup>33</sup> by employing glass and plastic reconstruction techniques, felt that the material represented projections of glomerular basement membrane. By forming multiple interconnecting and interlacing fibers, it enveloped the mesangial cells in a spongy network separating them from the endothelium. Other investigators felt that it was not merely a partitioning extension of the basement membrane but had a special nature. Various designations for the mesangial matrix,<sup>23</sup> intercellular substance or matrix,<sup>34</sup> or spongy material,<sup>32</sup> the material was noted to be distinctive embryologically, morphologically, and physiologically from basement membrane.

The purpose of this paper is to extend these observations by examining the pathologic alterations of the mesangium under various circumstances. While a number of the pathologic conditions to be reported have been investigated by other workers, only scant attention has been paid to changes in the mesangium.

#### MATERIAL AND METHODS

Nephrotoxic serum nephritis (Masugi)<sup>35</sup> was produced in male Sprague-Dawley albino rats by the intravenous injection of nephrotoxic rabbit serum.<sup>30</sup> Of 41 animals examined, 2 in the acute stage 3 weeks after injection, and 2 in the chronic stage 3 months after injection were selected for special study of the mesangium. Renal tissue was taken from live anesthetized animals.<sup>34</sup>

Snake venom poisoning was produced in 16 adult male rabbits (weight approximately 2 kg.) by the intravenous injection of Habu snake venom (2 mg. per kg.).<sup>36</sup> Tissues were removed by the technique indicated above and were examined 2, 4, 6 and 8 hours after injection.

Human tissue was obtained by percutaneous renal biopsy. Four specimens from cases of renal amyloidosis were studied, the patients varying in age from 10 years to 53 years and from 6 months to 2 years in duration of clinical symptoms. Glomerular involvement was demonstrated by crystal violet and Congo red stains and varied from minimal to severe in intensity. Twelve cases of diabetes were confirmed clinically or by diabetic glucose tolerance curves; duration of clinical symptoms varied from 1 to 20 years; glomerular alterations by light microscopy varied from none to extensive intercapillary glomerulosclerosis.

Fresh animal and biopsy tissues were fixed immediately in formalin and in ice cold 1 per cent phosphate or veronal-buffered osmium tetroxide, pH 7.4, and embedded in Epon.<sup>37</sup> Osmium-fixed tissues were stained with uranyl acetate or lead hydroxide, and were examined with a Phillips 100B, an RCA EMU 2-C and, in some instances, an RCA EMU 3-F microscope.

## OBSERVATIONS

*Normal Mesangium*

The structure and location of the normal mesangium has been well described by many investigators.<sup>8,20-34,38,39</sup> It is located between capillary lumens from which it is largely separated by endothelial cells; occasionally it appears to be in direct contact with the bloodstream.<sup>1,22,32</sup> Where it faces the urinary space, it is covered by basement membrane and epithelium. This portion of the basement membrane is referred to as the axial portion, in contradistinction to that portion surrounding the capillary lumen, which is the peripheral portion (Fig. 16). The mesangium consists of cells (mesangial cells) and an intercellular matrix (mesangial matrix) made up of fine fibrils (mesangial fibrils)<sup>32,38</sup> (Figs. 1 and 2) embedded in a ground substance probably containing mucopolysaccharide. The edges of the mesangial cells exhibit a complicated pattern of cytoplasmic processes (Fig. 2). The peripheral portions of the mesangial cells contain very fine filaments 70 to 100 Å in diameter. The extracellular fibrils have approximately the same dimensions. Collagen fibers are known to occur at the hilus but were not encountered in the mesangium of the peripheral lobules in our normal material. Latta<sup>39</sup> described collagen fibers in the mesangium close to the capillary lumen in normal adult rats. Suzuki (unpublished) found collagen fibers and a large number of mesangial fibrils in the peripheral mesangium of the adult avian glomerulus. It is not possible to be certain that small numbers of collagen fibers in similar location are present in the normal adult mammalian glomerulus but are usually masked by mesangial matrix.

The mesangial matrix has a density somewhat less than that of the basement membrane. It surrounds mesangial cells, partly separating them from each other, from the endothelium and from the axial portion of the basement membrane (Fig. 1).

*Acute Stage of Masugi Nephritis*

The first change in the mesangium of the rat with Masugi nephritis was characterized by edema of the mesangial matrix (Fig. 3). This became less dense, making the mesangial fibrils and the axial portion of the basement membrane relatively more prominent. A marked increase in the number of mesangial cells followed (Fig. 5). The proliferated cells were distinguished from endothelium by being individually surrounded by a layer of mesangial matrix, and by possessing a complicated pattern of pseudopodia along the cytoplasmic edge (Fig. 4). The amount of mesangial matrix increased as the lesion progressed. By 3 weeks a small number of collagen fibers were found in the enlarged matrix usually im-

mediately adjacent to the mesangial cell surface; the number of mesangial fibrils was also markedly increased (Fig. 6). In addition to mesangial fibrils and collagen fibers, small deposits of a dark, granular material, presumably protein in nature, were found within the mesangial matrix (Fig. 4), and occasionally also within the mesangial cell cytoplasm. Rarely, unusual blood spaces could be seen in the deep portion of the mesangium far from podocytes and the basement membrane. The shape of the cells surrounding these spaces was quite different from that of normal endothelium, rather resembling that of mesangial cells (Fig. 5). This unusual blood space was quite reminiscent of the early stages of the developing glomerulus.<sup>23</sup> It was uncertain whether the blood cavity was an original capillary lumen later surrounded by proliferating mesangial cells or whether it was, in fact, a result of canalization of the mesangium, analogous to that observed in embryologic development or to the process of capillary formation in granulation tissue.

#### *Chronic Stage of Masugi Nephritis*

The general histologic pattern in chronic Masugi nephritis was similar to that in the acute stage, except that some of the alterations were much more severe. Thus, cellular proliferation, increase in matrix and in its content of mesangial fibrils and collagen fibers became much more marked. At the same time, the electron opacity of the mesangial matrix increased, occasionally making it difficult to distinguish from basement membrane (Fig. 7). Some of the proliferated mesangial elements closely resembled smooth muscle cells in general shape, fibrillarity of cytoplasm and in the presence of dense material along the cell membrane (Fig. 9). The majority of proliferated cells, however, resembled the original mesangial cells. Some of them contained round, electron-dense bodies resembling the large granules of the tubular epithelium,<sup>40</sup> and some showed lysosome-like granules<sup>41</sup> (Fig. 8). None had the typical morphologic features of fibroblasts; nonetheless, the collagen fibers found in the matrix were often located adjacent to the mesangial cell membranes. These collagen fibers varied in diameter, but their major periodicity was approximately 640 Å. The number of mesangial fibrils in the areas of collagen formation were usually increased. However, the density of the matrix in the immediate vicinity of the fiber bundles was usually reduced (Fig. 10). Rarely, collagen fibers were also found in the basement membrane proper, usually within an area of reduced electron opacity (Fig. 7).

In addition, small droplets of homogeneous, electron-dense substance were found in the mesangial matrix (Fig. 7). The presence of lipid demonstrated by conventional light microscopic staining suggested that these were lipid droplets. They differed in appearance from the granular deposits in the acute stages.

### *Diabetes Mellitus*

Thickening of the basement membrane is a well known feature of early diabetes. There was also an increase in the number of mesangial cells. This, however, was often masked by the much more marked increase of mesangial matrix and fibrils (Fig. 11). In the early stages, the structure of the increased matrix resembled that of the normal glomerulus in appearance (Fig. 12). With progression of the lesion, the electron opacity of the mesangial matrix increased, approaching and occasionally even exceeding that of the basement membrane proper. The progressive accumulation of mesangial matrix to the extent that Kimmelstiel-Wilson nodules were formed has been reported.<sup>42,43</sup> The appearance of collagen fibers within such nodules has also been described.<sup>43</sup> Mesangial cells within such nodules often showed loss of cell organelles and cytoplasm.

Small electron-dense droplets, presumably lipid in nature, appeared within both the mesangial matrix and the mesangial cells (Fig. 11). Small accumulations of granular electron-dense material, presumably protein in nature, were also found occasionally in the matrix.

### *Amyloidosis*

Amyloid fibrils were of the same range of thickness (50 to 100 Å) as mesangial fibrils, but were more sharply defined and more irregularly oriented, giving amyloid a distinctly more fibrillar appearance electron microscopically (Fig. 14). On occasion they also showed a rough periodicity or beading. In the early stage of amyloidosis, following a slight proliferation of mesangial cells, the smallest deposits of amyloid were found within the mesangial matrix (Fig. 13). In the more advanced stages, extensive deposits were found in both the mesangial matrix and the basement membrane (Fig. 15). However, the proportion of amyloid was always much greater in the mesangial matrix. Massive deposits of amyloid were always found here, although they sometimes extended into the axial portion of the basement membrane. In such instances, this portion of basement membrane was sometimes completely replaced by amyloid; the peripheral portion, however, almost invariably showed some remnant of lamina densa, even when extensively involved.

Amyloid fibrils were not demonstrated intracellularly in our material. However, in massive amyloidosis there was loss of cell membranes and organelles.

### *Snake Venom Poisoning*

Two hours after the injection of snake poison, there was vacuolation of the mesangial cells (Fig. 16). At the same time there was edema of the mesangial matrix with increased prominence of fibrils (Fig. 17).

After 8 hours mesangial cells exhibited evidence of degeneration, with a pale cytoplasm devoid of organelles or other organization, and with only the nuclear membrane remaining intact (Fig. 18). The matrix also showed severe degeneration with a loss of density and of architecture. The loss of mesangium led to fusion of the capillaries with the formation of a large blood cyst or aneurysm. This was surrounded by the capillary basement membrane, which remained intact.

## DISCUSSION

### *Mesangial Cell Proliferation*

Cellular proliferation within the glomerulus in human and experimental nephritis is a well-known phenomenon. The problem has been to identify the cell type which participates in this proliferation. This identification depends upon the interpretation of the structure of the normal glomerulus. Those workers who did not accept the existence of a third cell type generally considered the proliferating cells to be endothelial in origin.<sup>12,19,44</sup> On the other hand, those who recognized the mesangium as a separate component<sup>24,29,30</sup> considered them to be predominantly mesangial in nature. Two characteristics of the normal mesangial cells are (a) irregular cytoplasmic processes along the cell edge; and (b) a surrounding intercellular material or matrix. Most of the proliferated cells showed these same features. It therefore appeared that mesangial cell proliferation was the main inflammatory response in the glomerulus.

Moderate mesangial cell proliferation was also found in the early stages of amyloidosis and diabetes. This has been reported in toxemia of pregnancy as well.<sup>24,25</sup> It thus appears to be a nonspecific response to injury.

### *Increase of Mesangial Matrix*

The mesangial matrix showed a marked variation in response to various pathologic conditions. In Masugi nephritis, there was a slight increase in matrix in the acute stage, and a progressive increase in the chronic stage. In diabetes mellitus, on the other hand, there was a very great increase even in relatively early stages of the disease. This increase in matrix is the same alteration described as deposition of hyaline material or basement membrane-like material by other investigators<sup>11,16,17</sup>; it accounts for the diffuse and nodular glomerulosclerosis of diabetes. In all these conditions, proliferation of mesangial cells, though varying in degree, appeared to precede or accompany an increase in matrix. In the embryologic development of the glomerulus,<sup>23</sup> cellular proliferation also precedes the formation of mesangial matrix. This would suggest that the mesangial cells contributed to the formation of mesangial matrix.

### *Collagen Fiber Formation*

Attention has been focused on the importance of periglomerular fibrosis in the development of intraglomerular fibrosis.<sup>46</sup> We also found severe periglomerular fibrosis in chronic Masugi nephritis and believe that this is an important mechanism in glomerular fibrosis. However, small bundles of collagen were found in the acute stage of Masugi nephritis, well before the development of periglomerular fibrosis. Also, in acute and chronic stages, the presence of small, isolated bundles of collagen fibers within the mesangium indicated that collagen fiber formation could begin in this area. This is supported by the evidence that within 6 days after uranium salt injection,<sup>31</sup> collagen fibers are found in the mesangium in the absence of periglomerular fibrosis or fibrous crescents.

Although the proliferated mesangial cells do not have the typical appearance of fibroblasts, their close proximity to the collagen fibers represents a relationship closely resembling that described for fibroblasts.<sup>47-49</sup> Collagen fibers have also been found within the mesangium in diabetes mellitus,<sup>43,50</sup> systemic lupus erythematosus, and cystinosis.<sup>51</sup>

### *Deposition of Substances*

While a number of investigators have examined glomeruli with amyloid deposit,<sup>52-56</sup> both human and experimental, these workers focused upon the basement membrane alterations. It appears certain, however, that amyloid deposition begins in the mesangial matrix, and with severe involvement the massive deposits also are usually found in the mesangium. This mesangial localization has been postulated from previous studies with phase microscopy.<sup>9</sup>

Protein and lipid deposits were also found within the mesangial matrix as well as within mesangial cells. The mesangium therefore appeared to be a site of predilection for the deposition of protein, lipid and amyloid substances. The reason for this was not clear. However, the evidence that the mesangial matrix is relatively permeable and the mesangial cell phagocytic<sup>32</sup> helps to explain this pattern of deposition.

### *Degeneration of the Mesangium*

In Habu snake poisoning, Kitamura, Hashiguchi, Hamaguchi and Oyama,<sup>36</sup> found a loss of glomerular architecture with conversion of the glomerulus into a blood-filled cavity surrounded by basement membrane and epithelial cells. When the venom was injected into experimental animals, the degenerative process was found to involve the mesangium ("mesangiolysis"). This was the only condition in which degeneration

of the mesangium was the primary process. There was involvement of both the mesangial cells and the matrix, and it was the only condition which was not preceded by either proliferation of cells or increase in matrix. We were able to confirm these observations by utilizing the same technique. The fact that the basement membrane remained preserved indicated that there was a difference between the mesangial matrix and the basement membrane in their response to certain forms of injury.

Other types of mesangial degeneration may occur in other varieties of glomerular disease. For example, in diabetes mellitus, marked increase in mesangial matrix was accompanied by atrophy and disappearance of mesangial cells. A similar alteration took place in amyloidosis, where massive deposition of amyloid in the mesangium was accompanied by mesangial cell alterations. In both instances, the cellular alterations consisted of loss of cell organelles and cytoplasm. It was impossible to say whether these alterations were due to compression or to interference with the metabolism of the cell, or to both.

#### *Embryologic Considerations*

For a long time it was accepted that the glomerulus was derived from an invagination of the metanephrogenic vesicle into which capillaries and their supporting connective tissue grew from the adjacent mesenchyma. More recent evidence has indicated that the glomerulus develops directly from mesenchymal cells of metanephrogenic tissue.<sup>15,23,24</sup> This implies that all the cells within the glomerulus are of mesenchymal cell origin. The cells making up the elements of the peripheral capillary wall differentiate first and also show the highest degree of differentiation (e.g., foot processes, endothelial sheets with pores). The cells in the axial portion differentiate the least, most closely resemble mesenchymal cells, and with the formation of mesangial matrix become mesangial cells in the mature glomerulus. The various properties ascribed to these cells—proliferation, phagocytosis,<sup>32</sup> fiber formation,<sup>31</sup> possibly also matrix formation—may be an expression of their origin and development.

#### *Relationship of Mesangial Matrix to Basement Membrane*

The axial portion of the basement membrane is in direct contact with the mesangial matrix and appears to be continuous with it. The distinguishing morphologic features—the relative homogeneity of the basement membrane contrasted to the fibrillarity and lesser electron opacity of the mesangial matrix—were pointed out by Farquhar and Palade.<sup>32,57</sup> Nonetheless, the concurrent increase in both basement membrane and mesangial matrix in diabetes and in Masugi nephritis suggests a close relationship between these two substances. Also, the similarity of staining reactions with PAS, periodic acid-silver methenamine, aniline blue



and other connective tissue stains suggests that there may be a similarity in chemical composition. Recent chemical studies<sup>58,59</sup> have demonstrated the presence of considerable amounts of hydroxyproline in normal as well as in abnormal (diabetic) glomeruli. It is not known how this amino acid is distributed between the basement membrane and the mesangial matrix and between their fibrillar and nonfibrillar components. However, the presence of hydroxyproline implies the existence of a protein chemically related to collagen. Immunohistochemical methods reveal the presence of collagen or a substance closely related to collagen in the capillary basement membrane.<sup>60</sup>

On the other hand, in addition to the morphologic differences mentioned above, the matrix further differs from basement membrane in that it is variable in thickness and does not form a complete membrane, sometimes leaving the endothelial cells incompletely separated from the mesangial cells. There is also thought to be a marked difference in permeability.<sup>32</sup> Embryologically, the basement membrane develops prior to and independently of the mesangial matrix.<sup>23</sup> There is also a difference in their reaction to some pathologic stimuli, e.g., Habu snake venom. Thus, although basement membrane and mesangial matrix may be closely related, a distinction between the two is certainly warranted.

#### *Nature of the Mesangium*

Zimmermann<sup>1,2</sup> considered the mesangium to be a type of connective tissue supporting the glomerular capillaries and suggested that its cells were fibroblasts. A number of electron microscopic observations, particularly during earlier studies, appeared to contradict Zimmermann's concept of a connective tissue-like mesangium. The location, with partial contact with the bloodstream, would speak against such a concept, since connective tissue is usually separated from the vascular tissue. Secondly, the relative lack of intercellular substance, a conspicuous component of connective tissue, and the lack of connective tissue fibers pointed against a connective tissue nature. Further distinction was the paucity of fibroblast characteristics, such as a lack of well-developed endoplasmic reticulum in mesangial cells. The demonstration that capillaries and connective tissue do not grow into the glomerulus during embryologic formation ("invagination" theory) seemed to constitute further contradictory evidence to the concept that a connective tissue element was a component of the glomerulus.

As a consequence, even those investigators who considered the mesangial cells to be a third cell type avoided any terminology which would associate them with a connective tissue origin. Thus, a number of names given avoided any connotation of function or origin (intercapillary cell, third cell type, interluminal cell aggregates, deep cell).

Later, more extensive investigation of the structure, function and development of the mesangium with improved techniques suggested that this component had certain features of connective tissue. It provides the necessary mechanical support for the capillaries, loss of which (e.g., as a consequence of mesangial degeneration in Habu snake poisoning) leads to disruption of the capillary architecture. It responds to injury by cellular proliferation and by the deposition of intercellular substances such as matrix and collagen. However, mesangium also exhibits properties not ordinarily found in connective tissue. Mesangial cells are strongly phagocytic, indicating a relationship to macrophages or the reticuloendothelial system. Some of the cells are, to a degree, directly exposed to the bloodstream. Some cells, particularly when in process of proliferation, resemble smooth muscle cells.<sup>61</sup> This combination of features suggests that the mesangium is a specialized tissue of mesenchymal origin. In many respects it is similar to the pericapillary tissue.<sup>32,62</sup>

The term "mesangium" indicates a tissue lying between capillaries. Even though the present concept of this tissue is somewhat more complex than that proposed by Zimmerman, the term itself remains both pertinent and useful.

#### SUMMARY

The renal glomerular mesangium is composed of mesangial cells (intercapillary cells) and intercellular substance, designated mesangial matrix. Pathologic changes in the mesangium were investigated in 4 conditions: nephrotoxic (Masugi) serum nephritis and Habu snake poisoning in animals, and diabetes mellitus and amyloidosis in man. In Masugi nephritis, mesangial cell proliferation with increase in mesangial matrix and focal collagen formation were observed. In diabetes, marked increase in the mesangial matrix followed a slight mesangial cell proliferation. In amyloidosis the deposition of amyloid substance appeared to begin within the mesangial matrix and massive deposits in later stages were also localized in the mesangium. In Habu snake poisoning degeneration of both mesangial cells and matrix was noted.

The structure and the behavior of the mesangium is best explained by the assumption that it is a special type of mesenchymal tissue similar to pericapillary tissue.

#### REFERENCES

1. ZIMMERMANN, K. W. Über den Bau des Glomerulus der menschlichen Niere. *Ztschr. mikr.-anat. Forsch.*, 1929, 18, 520-552.
2. ZIMMERMANN, K. W. Über den Bau des Glomerulus der Säugerniere. *Ztschr. mikr.-anat. Forsch.*, 1933, 32, 176-278.
3. VON MÖLLENDORF, W. Handbuch der mikroskopischen Anatomie des Menschen. J. Springer, Berlin, 1930, Vol. 7, 574 pp.
4. BENSLEY, R. R., and BENSLEY, R. D. The structure of the renal corpuscle. *Anat. Rec.*, 1930, 47, 147-175.

5. ALLEN, A. C. *The Kidney, Medical and Surgical Diseases*. Grune & Stratton, New York, 1951, 583 pp.
6. BELL, E. T. *Renal Diseases*. Lea & Febiger, Philadelphia, 1950, ed. 2, 448 pp.
7. MCMANUS, J. F. A. The structure of the glomerulus of the human kidney. *Am. J. Path.*, 1948, **24**, 1259-1269.
8. JONES, D. B. Inflammation and repair of the glomerulus. *Am. J. Path.*, 1951, **27**, 991-1009.
9. CHURG, J., and GRISHMAN, E. Phase microscope studies of renal glomeruli; glomerular deposits of "hyaline" substances. *Am. J. Path.*, 1953, **29**, 199-215.
10. RINEHART, J. F.; FARQUHAR, M. G.; JUNG, H. C., and ABUL-HAJ, S. K. The normal glomerulus and its basic reactions in disease. *Am. J. Path.*, 1953, **29**, 21-31.
11. FARQUHAR, M. G.; HOPPER, J., JR., and MOON, H. Diabetic glomerulosclerosis; electron and light microscopic studies. *Am. J. Path.*, 1959, **35**, 721-753.
12. FARQUHAR, M. G.; VERNIER, R. L., and GOOD, R. A. Studies on familial nephrosis. II. Glomerular changes observed with the electron microscope. *Am. J. Path.*, 1957, **33**, 791-817.
13. PEASE, D. C., and BAKER, R. F. Electron microscopy of the kidney. *Am. J. Anat.*, 1950, **87**, 349-389.
14. HALL, B. V. Studies of Normal Glomerular Structure by Electron Microscopy. Proceedings of the Fifth Annual Conference on the Nephrotic Syndrome, Philadelphia, Nov. 5-7, 1953. National Nephrosis Foundation, Inc., New York, 1954, pp. 1-39.
15. HALL, B. V., and ROTH, L. E. Preliminary Studies on the Development and Differentiation of Cells and Structures of the Renal Corpuscle. In: *Electron Microscopy. Proceedings of the Stockholm Conference, September, 1956*. SJOSTRAND, F. S., and RHODIN, J. (eds.). Academic Press, Inc., New York, 1957, pp. 176-179.
16. BERGSTRAND, A., and BUCHT, H. Electron microscopic investigations on the glomerular lesions in diabetes mellitus (diabetic glomerulosclerosis). *Lab. Invest.*, 1957, **6**, 293-300.
17. BERGSTRAND, A., and BUCHT, H. The glomerular lesions of diabetes mellitus and their electron microscope appearances. *J. Path. & Bact.*, 1959, **77**, 231-242.
18. MUELLER, C. B. The structure of the renal glomerulus. *Am. Heart J.*, 1958, **55**, 304-322.
19. VERNIER, R. L.; FARQUHAR, M. G.; BRUNSON, J. G., and GOOD, R. A. Chronic renal disease in children—the renal lesion by light and electron microscopy. (Abstract) *J. Lab. & Clin. Med.*, 1956, **48**, 951-952.
20. POLICARD, A.; COLLET, A., and GILTAIRE-RALYTE, L. Recherches au microscope électronique sur la structure du glomérule rénal des mammifères. *Arch. anat. micr.*, 1955, **44**, 1-19.
21. SAKAGUCHI, H. Fine structure of the renal glomerulus. *Keio J. Med.*, 1955, **4**, 103-118.
22. YAMADA, E. The fine structure of the renal glomerulus of the mouse. *J. Biophys. & Biochem. Cytol.*, 1955, **1**, 551-566.
23. SUZUKI, Y. An electron microscopy of the renal differentiation. II. Glomerulus. *Keio J. Med.*, 1959, **8**, 129-144.
24. KURTZ, S. M., and MCMANUS, J. F. A. A reconsideration of the development, structure and disease of the human renal glomerulus. *Am. Heart J.*, 1959, **58**, 357-371.
25. PAK POY, R. K. F. Electron microscopy of the marsupial renal glomerulus. *Australian J. Exper. Biol. & M. Sc.*, 1957, **35**, 437-447.

26. PAK POY, R.K.F. Electron microscopy of the amphibian renal glomerulus. *Australian J. Exper. Biol. & M. Sc.*, 1957, **35**, 583-593.
27. PAK POY, R. K. F., and ROBERTSON, J. S. Electron microscopy of the avian renal glomerulus. *J. Biophys. & Biochem. Cytol.*, 1957, **3**, 183-192.
28. GRISHMAN, E., and CHURG, J. Acute glomerulonephritis. A histopathologic study by means of thin sections. *Am. J. Path.*, 1957, **33**, 993-1007.
29. SAKAGUCHI, H.; SUZUKI, Y., and YAMAGUCHI, T. Electron microscopic study Masugi nephritis. I. Glomerular changes. *Acta path. jap.*, 1957, **7**, 53-66.
30. CHURG, J.; GRISHMAN, E., and MAUTNER, W. Nephrotoxic serum nephritis in the rat. Electron and light microscopic studies. *Am. J. Path.*, 1960, **37**, 729-749.
31. BENCOSME, S. A., STONE, R. S.; LATTA, H., and MADDEN, S. C. Acute reactions with collagen production in renal glomeruli of rats studied electron microscopically. *J. Ultrastruct. Res.*, 1959, **3**, 171-185.
32. FARQUHAR, M. G., and PALADE, G. E. Functional evidence for the existence of a third cell type in the renal glomerulus. Phagocytosis of filtration residues by a distinctive "third" cell. *J. Cell Biol.*, 1962, **13**, 55-87.
33. JONES, D. B.; MUELLER, C. G., and MENEFFEE, M. The cellular and extracellular morphology of the glomerular stalk. *Am. J. Path.*, 1962, **41**, 373-388.
34. LATTA, H.; MAUNSBACH, A. B., and MADDEN, S. C. The centrolobular region of the renal glomerulus studied by electron microscopy. *J. Ultrastruct. Res.*, 1960, **4**, 455-472.
35. MASUGI, M. Über das Wesen der spezifischen Veränderungen der Niere und der Leber durch das Nephrotoxin bzw. das Hepatotoxin. Zugleich am Beitrag zur Pathogenese der Glomerulonephritis und der eklamptischen Lebererkrankung. *Beitr. path. Anat.*, 1933, **91**, 82-112.
36. KITAMURA, W.; HASHIGUCHI, T.; HAMAGUCHI, R., and OYAMA, M. Pathological study on the snake poisoning. *Nichibyokaishi*, 1957, **46**, 355.
37. LUFT, J. H. Improvements in epoxy resin embedding methods. *J. Biophys. & Biochem. Cytol.*, 1961, **9**, 409-414.
38. SUZUKI, Y.; CHURG, J.; GRISHMAN, E.; MAUTNER, W., and DACHS, S. Pathologic alterations of the mesangium. (Abstract) Fifth International Congress of Electron Microscopy, Philadelphia. 1962.
39. LATTA, H. Collagen in normal rat glomeruli. *J. Ultrastruct. Res.*, 1961, **5**, 364-373.
40. RHODIN, J. Correlation of Ultrastructural Organization and Function in Normal and Experimentally Changed Proximal Convolute Tubule Cells of the Mouse Kidney. Karolinska Institutet, Stockholm, Aktiebolaget Godvil, 1954, 76 p.
41. NOVIKOFF, A. B. Lysosomes and Related Particles. In: *The Cell; Biochemistry, Physiology, Morphology*. BRACHET, J., and MIRSKY, A. E. (eds.). Academic Press, Inc., New York, 1961, Vol. 2, pp. 423-488.
42. SAKAGUCHI, H.; SUZUKI, Y., and RI, T. Electron microscope studies of the kidney. V. Changes in diabetes mellitus. *Medicine, (Tokyo)*, 1959, **16**, 541.
43. DACHS, S.; MAUTNER, W.; GRISHMAN, E., and CHURG, J. Electron microscopic studies of diabetic nephropathy. (Abstract) Program of the American Association of Pathologists and Bacteriologists, Montreal, 1962, p. 9.
44. BERGSTRAND, A., and BUCHT, H. Electron Microscope Investigations on Biopsy Material from Patients with Renal Disease. A Case of Subacute Glomerulonephritis. In: *Electron Microscopy. Proceedings of the Stockholm Conference, September, 1956*. SJOSTRAND, F. S., and RHODIN, J. (eds.). Academic Press, Inc., New York, 1957, pp. 256-258.

45. MAUTNER, W.; CHURG, J.; GRISHMAN, E., and DACHS, S. Preeclamptic nephropathy; an electron microscopic study. *Lab. Invest.*, 1962, **11**, 518-530.
46. PAK POY, R. F. K., and ROBERTSON, J. S. An electron microscopical study of glomerular changes in experimental hydronephrosis in rats. *Australian J. Exper. Biol. and M. Sc.*, 1959, **37**, 65-75.
47. PORTER, K. R., and PAPPAS, G. D. Collagen formation by fibroblasts of the chick embryo dermis. *J. Biophys. & Biochem. Cytol.*, 1959, **5**, 153-166.
48. ROSS, R., and BENDITT, C. P. Wound healing and collagen formation. I. Sequential changes in components of guinea pig skin wounds observed in the electron microscope. *J. Biophys. & Biochem. Cytol.*, 1961, **11**, 677-700.
49. YARDLEY, J. H.; HEATON, M. W.; GAINES, L. M., JR., and SHULMAN, L. E. Collagen formation by fibroblasts: preliminary electron microscopic observations using thin sections of tissue cultures. *Bull. Johns Hopkins Hosp.*, 1960, **106**, 381-393.
50. KIMMELSTIEL, P.; KIM, O. J., and BERES, J. Studies on renal biopsy specimens, with the aid of the electron microscope. I. Glomeruli in diabetes. *Am. J. Clin. Path.*, 1962, **38**, 270-279.
51. CHURG, J., and MAUTNER, W. Unpublished observation.
52. SPIRO, D. The structural basis of proteinuria in man. Electron microscopic studies of renal biopsy specimens from patients with lipid nephrosis, amyloidosis, and subacute and chronic glomerulonephritis. *Am. J. Path.*, 1959, **35**, 47-73.
53. MILLER, F., and BOHLE, A. Electron Microscopy of the Glomerular Basement Membrane in Experimental Amyloidosis of the Mouse. In: *Electron Microscopy. Proceedings of the Stockholm Conference, September, 1956.* SJOSTRAND, F. S., and RHODIN, J. (eds.). Academic Press, Inc., New York, 1957, pp. 254-256.
54. GEER, J. C.; STRONG, J. P.; MCGILL, H. C., JR., and MUSLOW, I. Electron microscopic observations on the localization of amyloid in the kidney in secondary amyloidosis. *Lab. Invest.*, 1958, **7**, 554-565.
55. MOVAT, H. Z. The fine structure of the glomerulus in amyloidosis. *Arch. Path.*, 1960, **69**, 323-332.
56. COHEN, A. S., and CALKINS, E. A study of the fine structure of the kidney in casein-induced amyloidosis. *J. Exper. Med.*, 1960, **112**, 479-490.
57. FARQUHAR, M. G., and PALADE, G. E. Glomerular permeability. II. Ferritin transfer across the glomerular capillary wall in nephrotic rats. *J. Exper. Med.*, 1961, **114**, 699-716.
58. GOODMAN, M.; GREENSPON, S. A., and KRAKOWER, C. A. The antigenic composition of the various anatomic structures of the canine kidney. *J. Immunol.*, 1955, **75**, 96-104.
59. BONTING, S. L.; DE BRUIN, H., and POLLAK, V. E. Quantitative histochemistry of the nephron. VI. Hydroxyproline in the human glomerulus. *J. Clin. Invest.*, 1961, **40**, 177-180.
60. ROTHBARD, S., and WATSON, R. F. Antigenicity of rat collagen. Demonstration of antibody to rat collagen in renal glomeruli of rats by fluorescence microscopy. *J. Exper. Med.*, 1961, **113**, 1041-1051.
61. HUHN, D.; STEINER, J. W., and MOVAT, H. Z. Die Feinstruktur des Mesangiums im Nierenglomerulum von Hund und Maus. *Ztschr. Zellforsch.*, 1962, **56**, 213-230.
62. SAKAGUCHI, M., and SUZUKI, Y. Electron microscopic study of the renal glomerulus, particularly of the mesangium. *Japanese Soc. Nephrology*, 1960, **2**, 339.

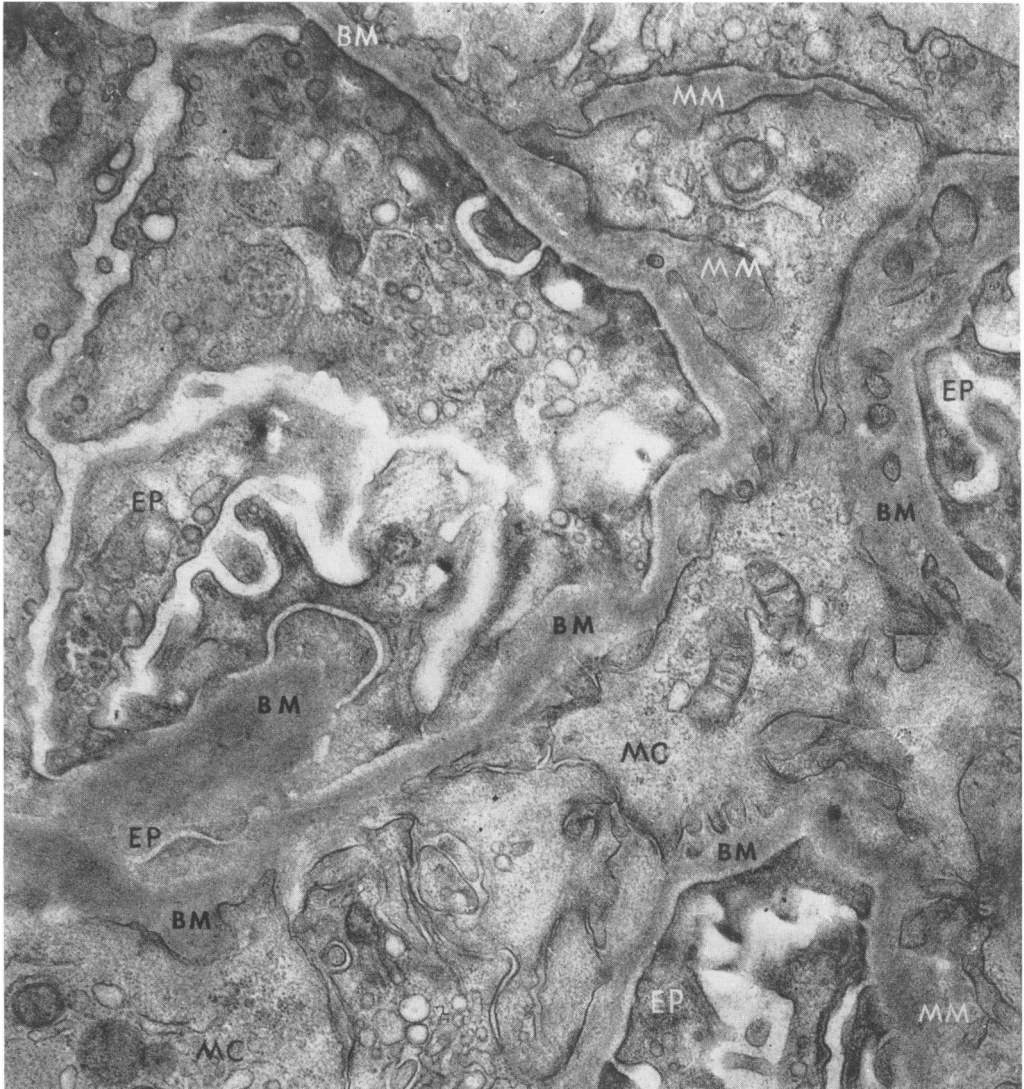
## LEGENDS FOR FIGURES

*Key:*

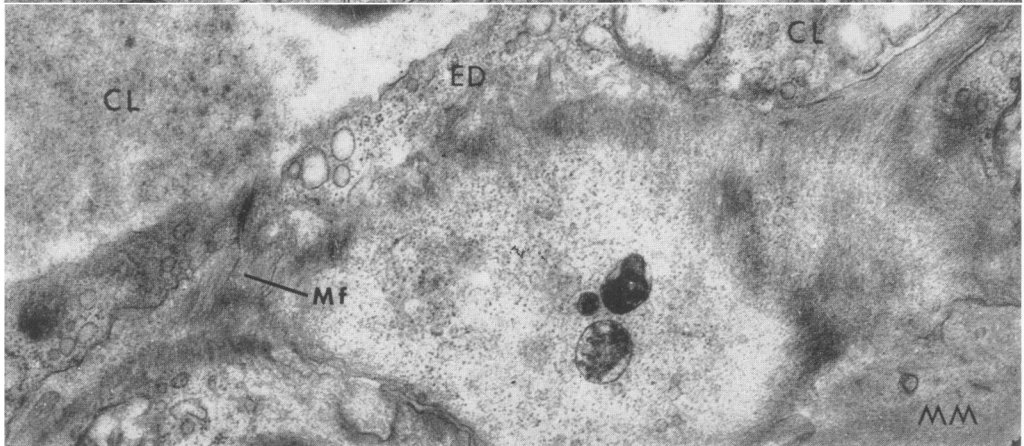
A = Amyloid	CL = Capillary lumen
BM = Basement membrane	ED = Endothelial cell
BM-A = Axial portion, basement membrane	EP = Epithelial cell (including foot process)
BM-P = Peripheral portion, basement membrane	MC = Mesangial cell
Cf = Collagen fiber	Mf = Mesangial fibrils
	MM = Mesangial matrix

FIG. 1. Normal rat glomerulus. The mesangium is bordered on the right and left and at the bottom by basement membrane and foot processes of epithelial cells, at the top by endothelial and capillary lumen. Mesangial matrix separates mesangial from endothelial cells. Edges of mesangial cells consist of irregular cytoplasmic processes. Mesangial cells contain mitochondria, endoplasmic reticulum, and dense bodies.  $\times 17,000$ .

FIG. 2. Normal rat glomerulus. The mesangial matrix contains fine fibrils; a mesangial cell contains filaments of approximately the same caliber (70 to 100 Å).  $\times 27,000$ .



1



2

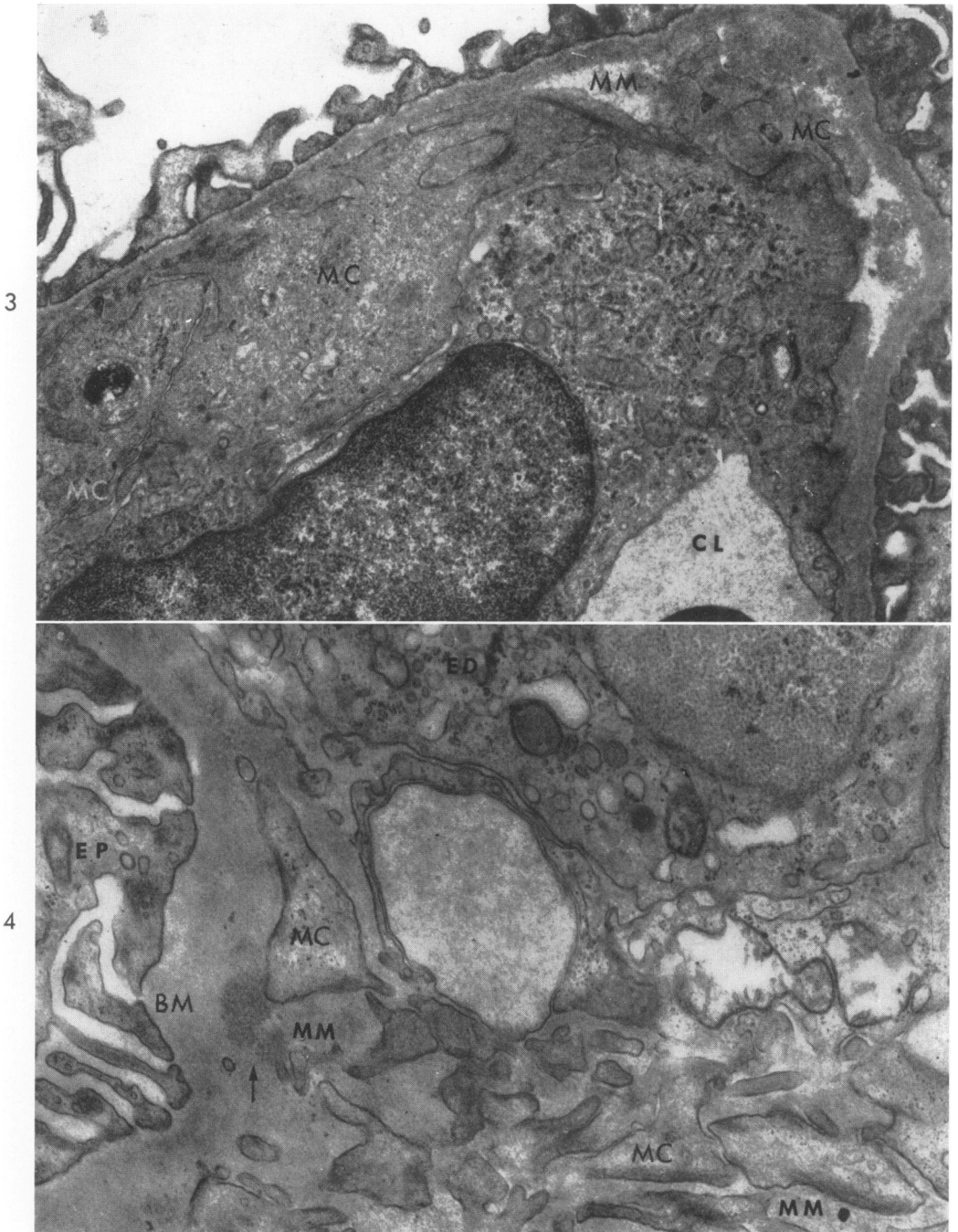


FIG. 3. Acute nephrotic (Masugi) nephritis in the rat. The endothelial cell contains numerous mitochondria and endoplasmic reticulum. The mesangial matrix is pale and appears swollen. Irregular edges of the mesangial cell are maintained.  $\times 14,000$ .

FIG. 4. Acute (Masugi) nephritis. The endothelial cell cytoplasm at the top is separated from irregular processes of a mesangial cell by mesangial matrix. Arrow shows a deposit of granular material, presumably protein, in the matrix.  $\times 17,000$ .



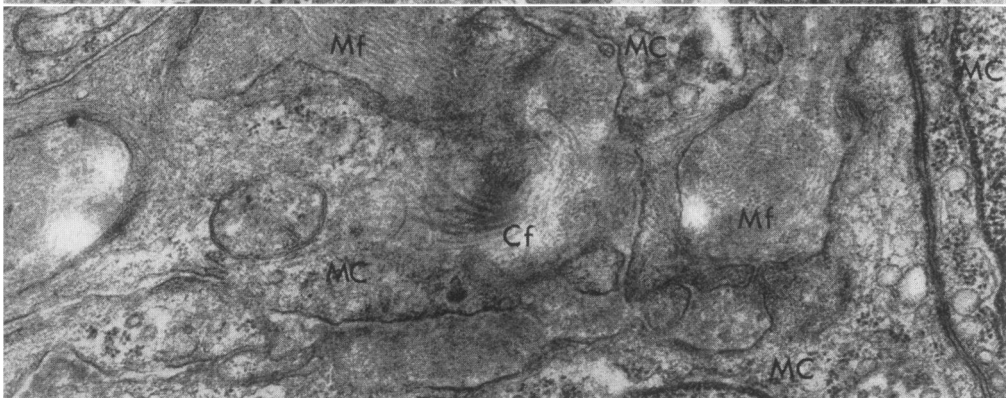
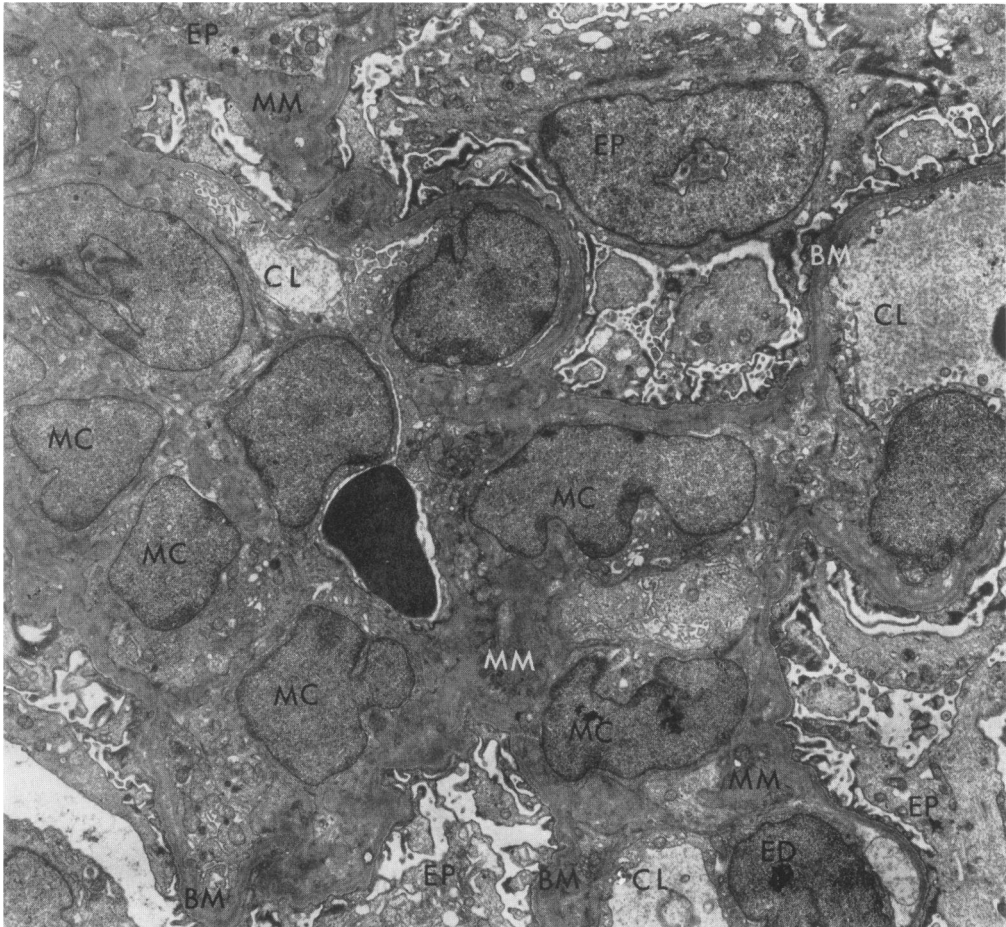


FIG. 5. Acute (Masugi) nephritis. There is marked cellularity of the mesangium. In the center of the lobule is a lumen filled by a red cell. This may be a residual of a former lumen or may represent "canalization."  $\times 3,500$ .

FIG. 6. Acute (Masugi) nephritis. Collagen fibers appear adjacent to a mesangial cell whose membrane has been cut tangentially. The mesangial matrix in the vicinity of the fibers contains numerous mesangial fibrils but is less dense in the area of fiber formation.  $\times 28,000$ .

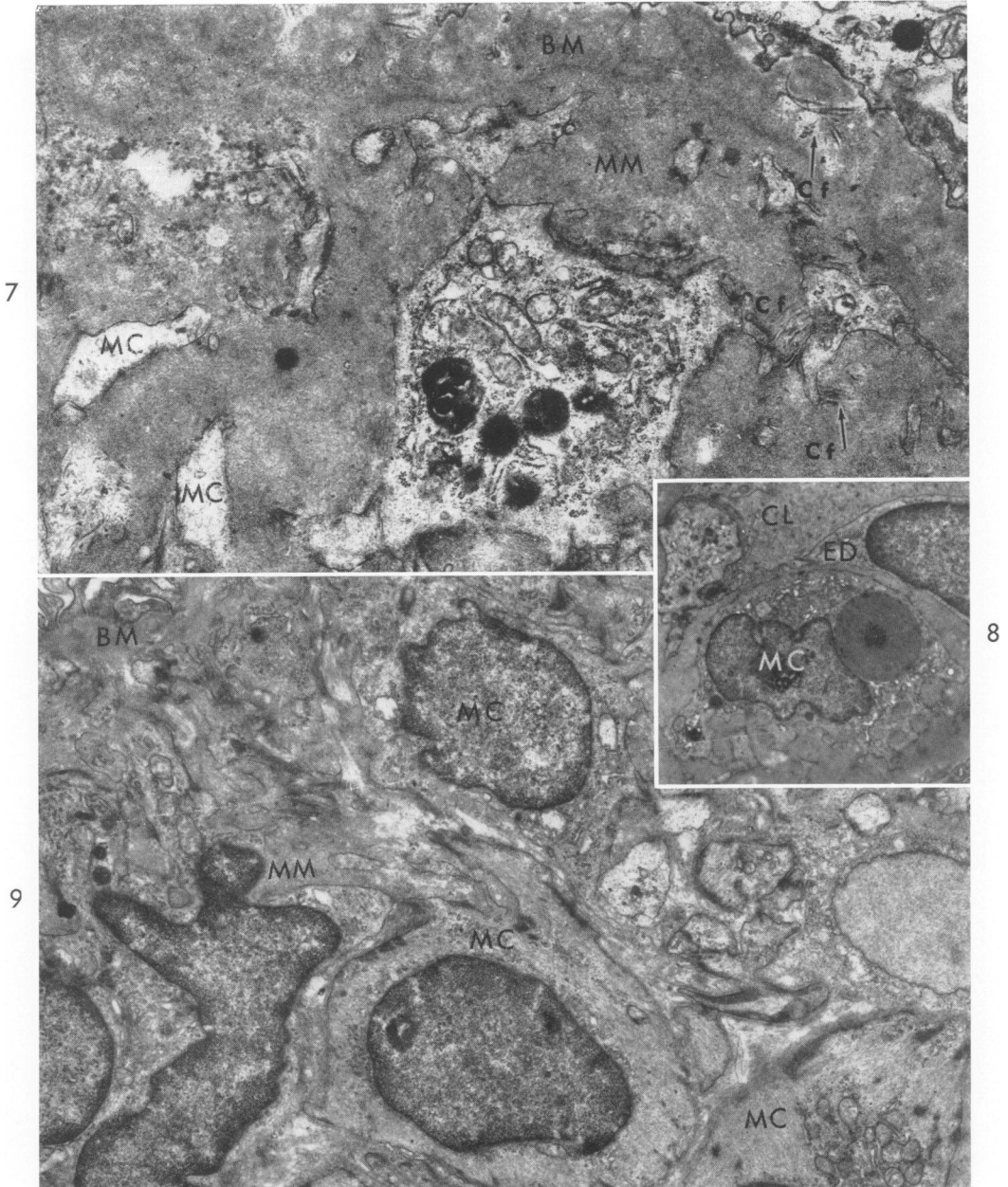


FIG. 7. Chronic (Masugi) nephritis. There is marked enlargement of mesangial matrix. Separation between the basement membrane and the mesangial matrix is not always clearly defined. Collagen fibers are found in the matrix adjacent to the mesangial cell membrane and occasionally in the basement membrane. The mesangial cell contains dense granules, some resembling lysosomes.  $\times 17,500$ .

FIG. 8. Chronic (Masugi) nephritis. In the mesangial cell cytoplasm is a "large granule" resembling a hyaline droplet.  $\times 4,000$ .

FIG. 9. Chronic (Masugi) nephritis. Some of the proliferated mesangial cells resemble normal elements (top) while others resemble smooth muscle cells (bottom).  $\times 7,500$ .

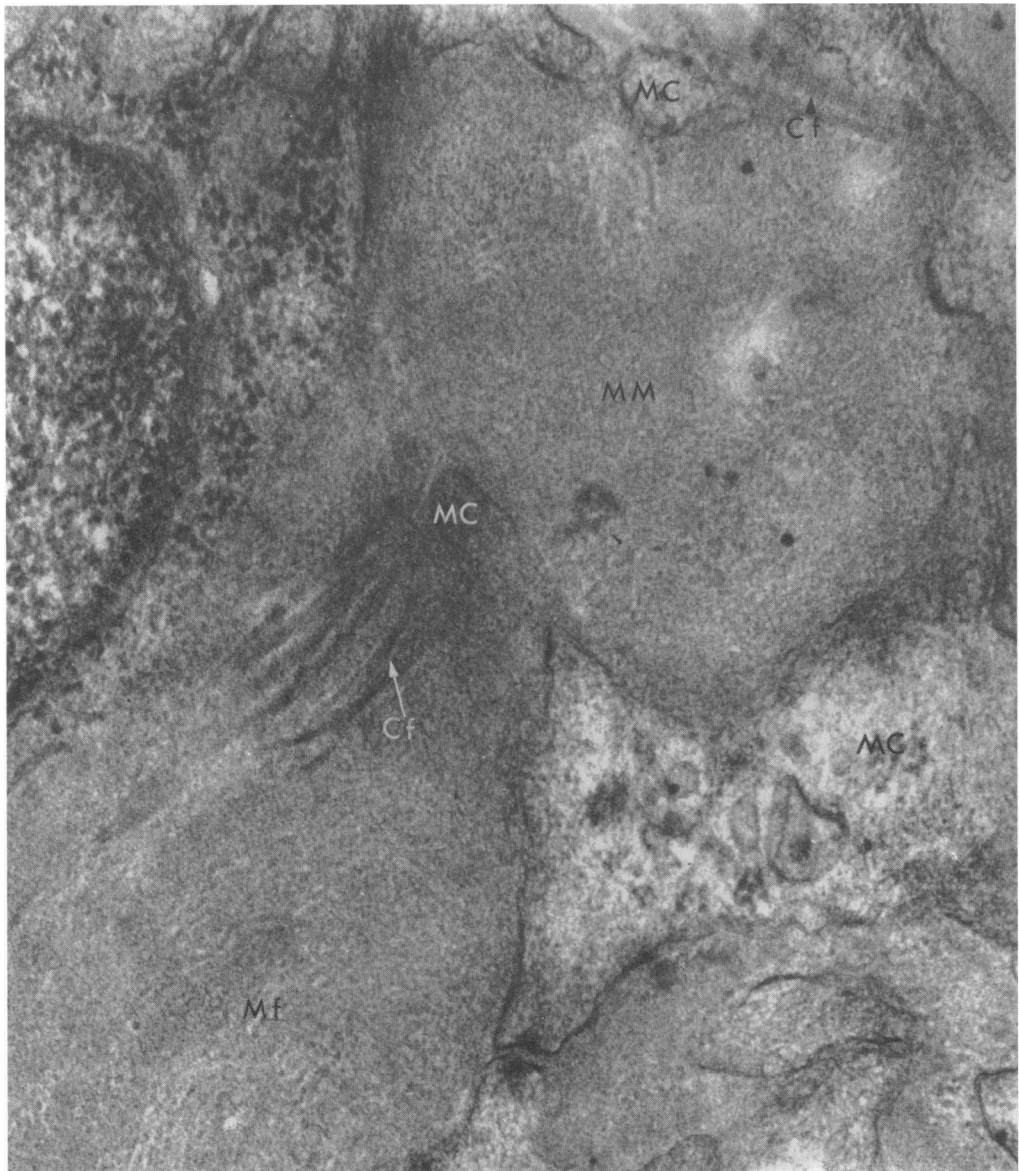


FIG. 10. Chronic (Masugi) nephritis. Two bundles of collagen fibers are immediately adjacent to the cell membrane. The subperiod of the collagen fiber can be made out. The mesangial matrix contains numerous fibrils and is less electron-opaque in the area of collagen formation.  $\times 55,000$ .

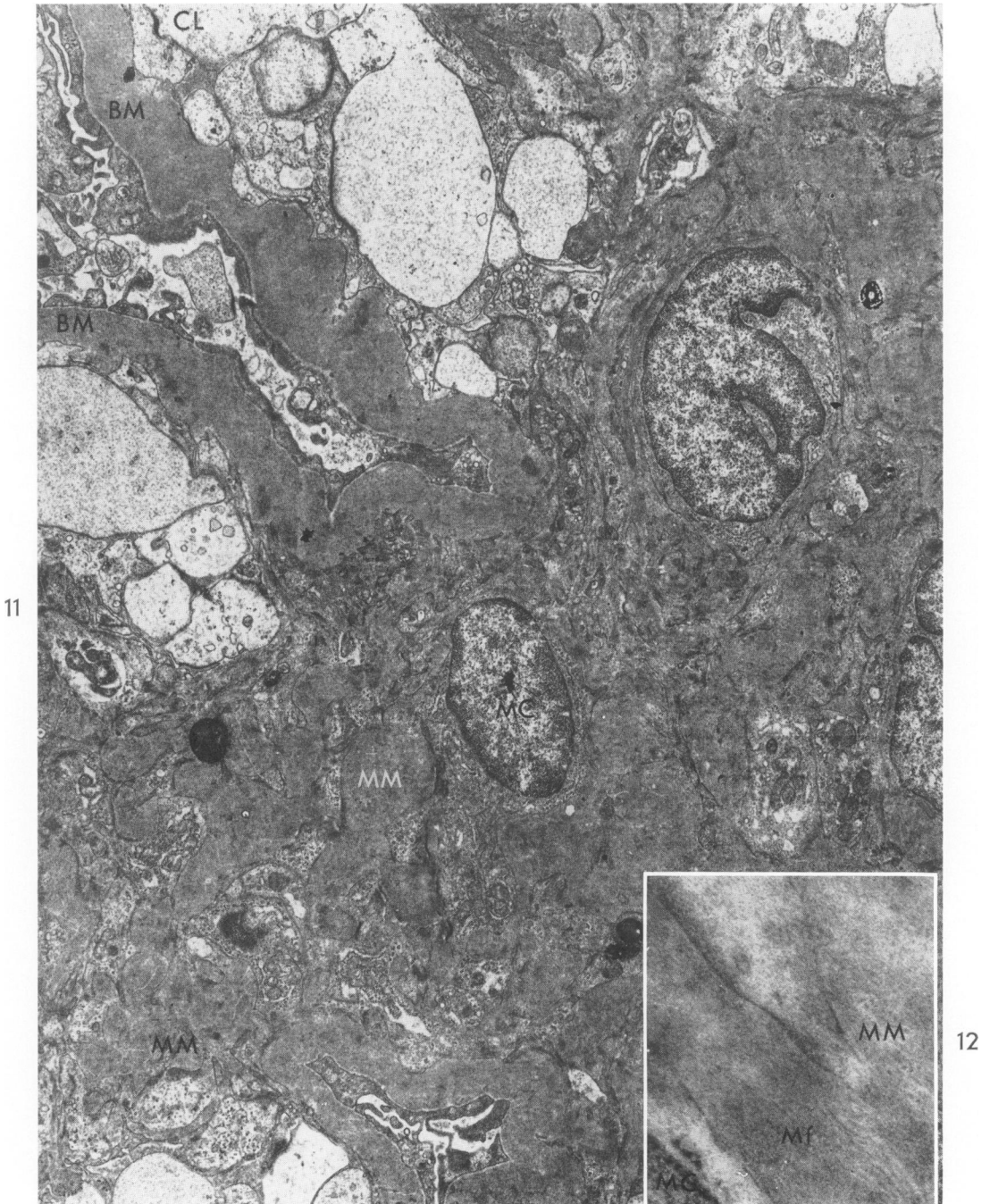
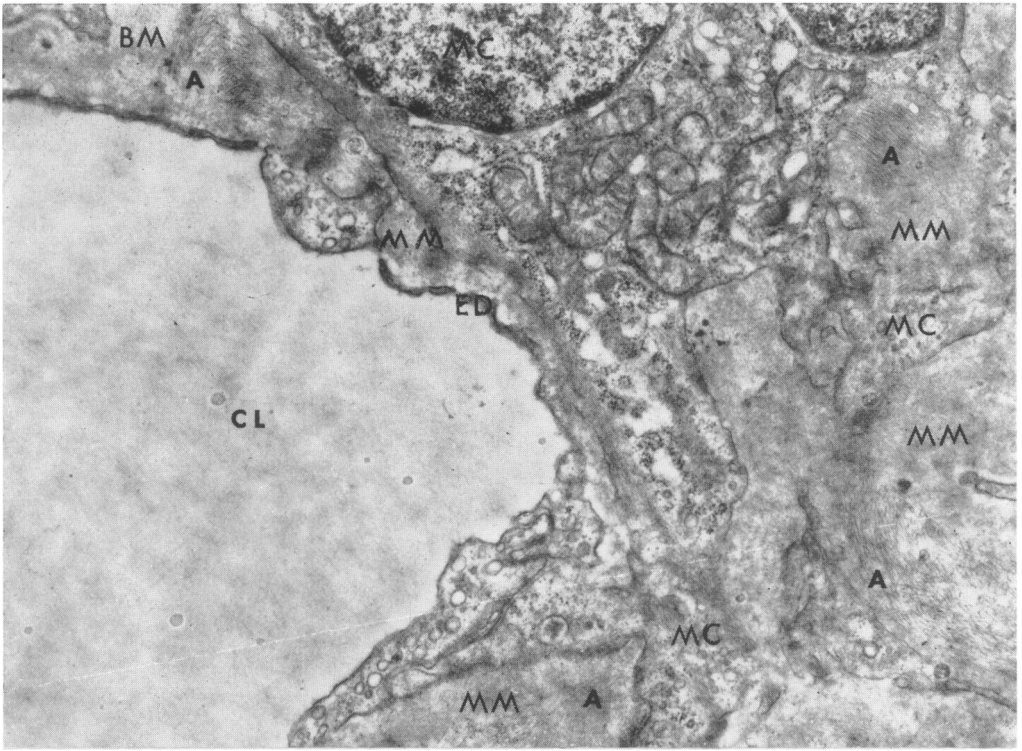
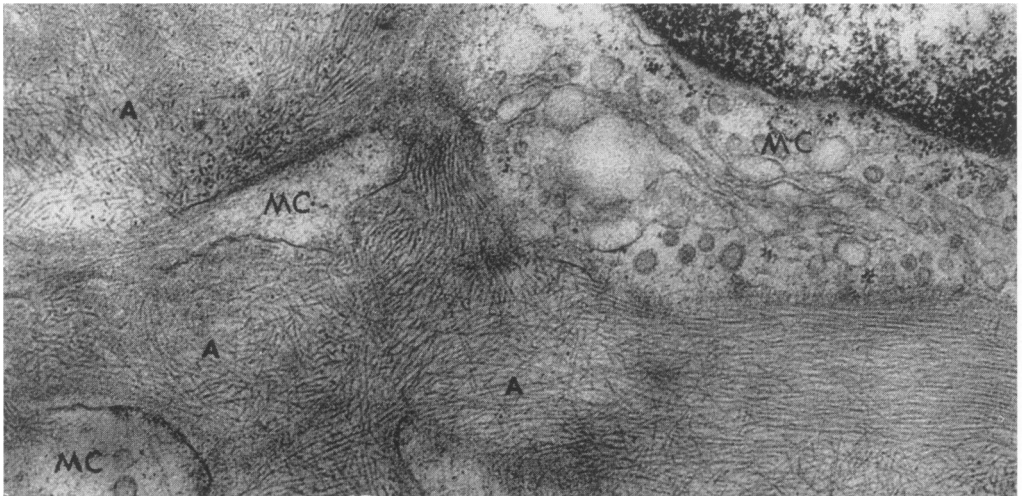


FIG. 11. Diabetes mellitus. The mesangial matrix is markedly enlarged and appears between a slightly increased number of mesangial cells. Capillary lumens are found at the periphery of the enlarged mesangium. Lipid droplets and small deposits of granular material appear within the matrix.  $\times 4,000$ .

FIG. 12. Diabetes mellitus. The mesangial matrix contains fine fibrils with the same diameter as those in a normal glomerulus.  $\times 44,000$ .



13



14

FIG. 13. Amyloidosis. Small deposits of amyloid are manifest in the mesangial matrix.  $\times 24,000$ .

FIG. 14. Amyloidosis. Amyloid fibrils are more prominent than mesangial fibrils and are irregularly oriented.  $\times 60,000$ .

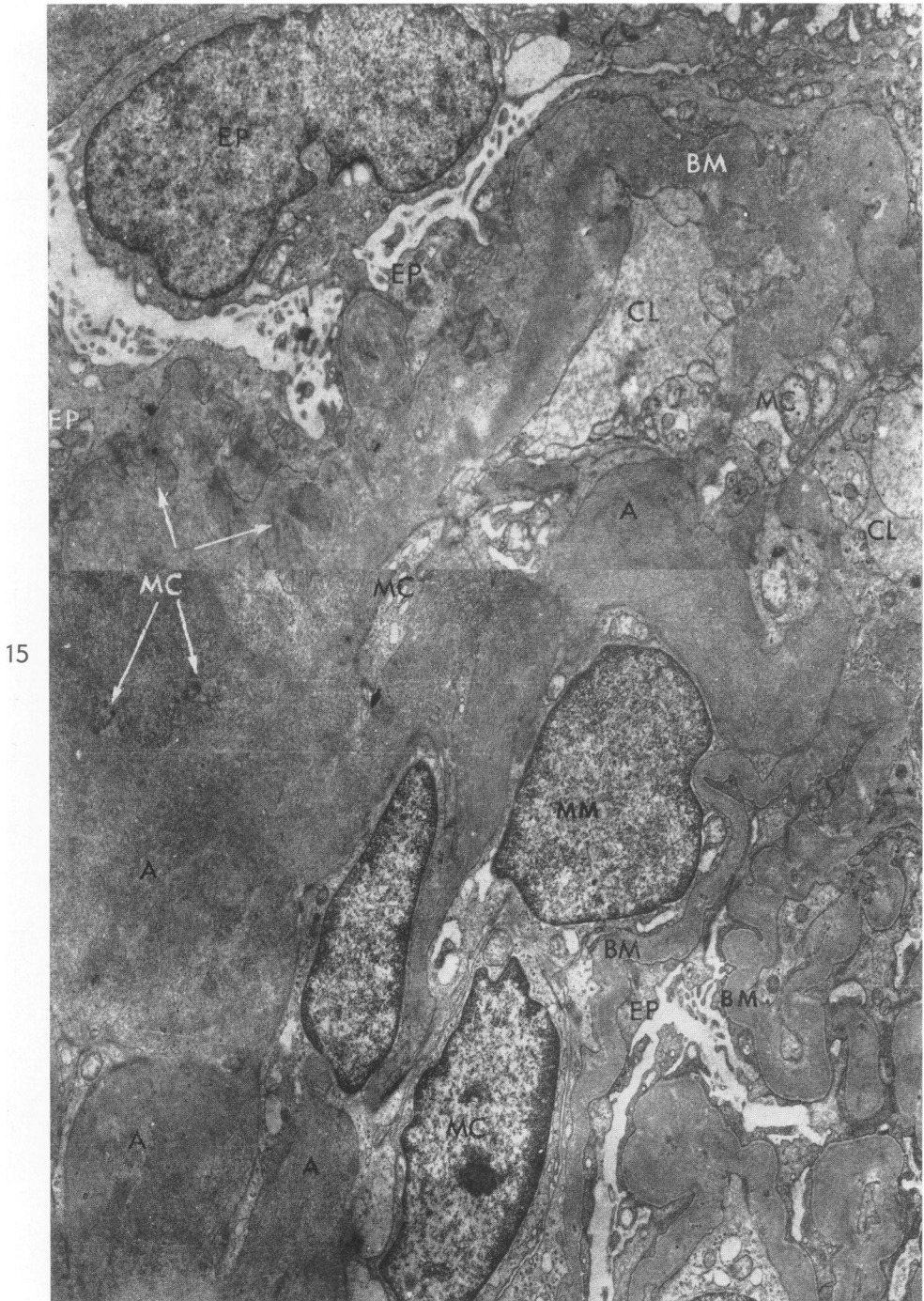
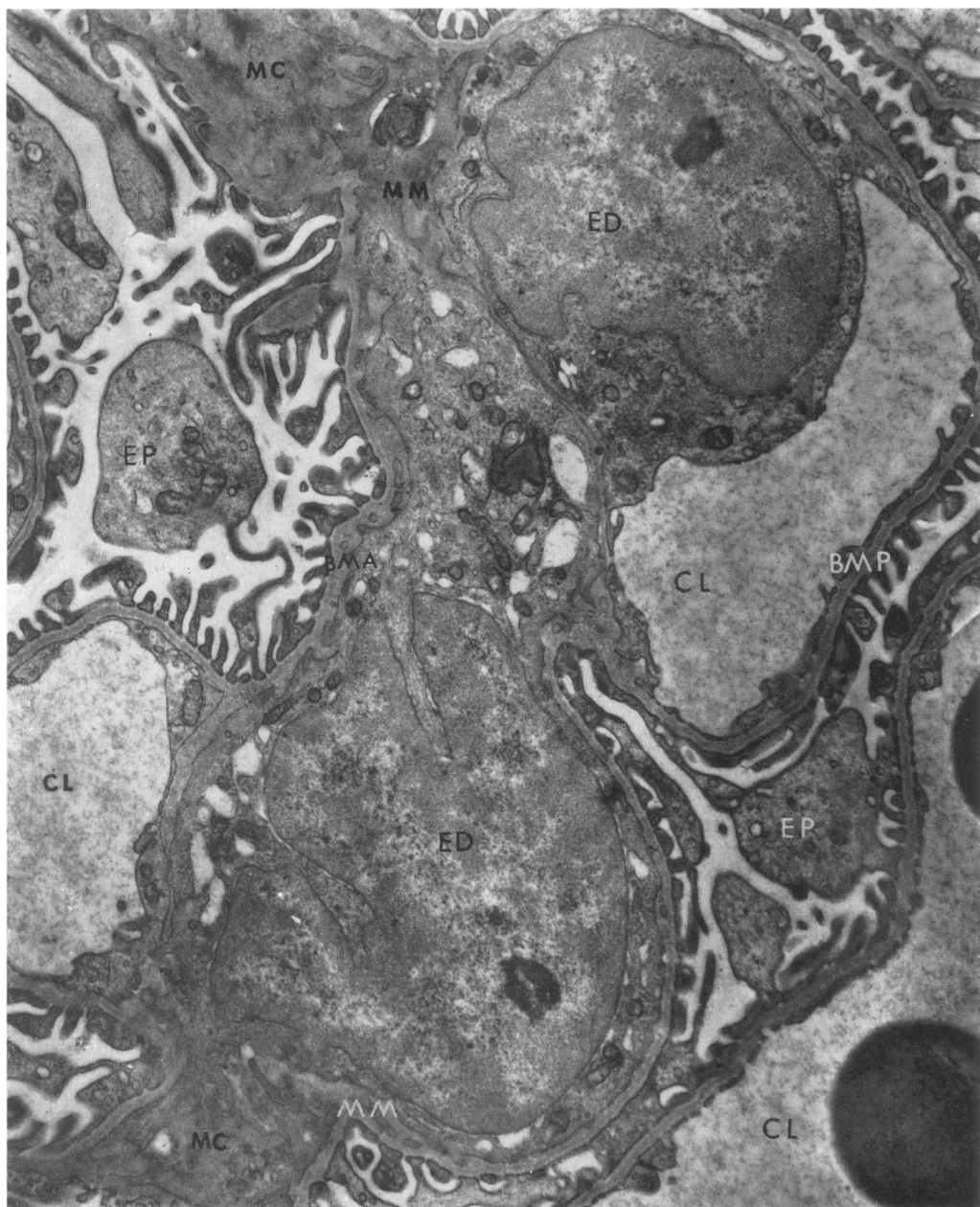


FIG. 15. Amyloidosis. A massive deposit of amyloid appears in the mesangium. Remnants of mesangial cell cytoplasm are indicated by arrows. Basement membrane involvement by amyloid is seen at the top. The axial portion of the basement membrane is completely replaced by amyloid.  $\times 8,000$ .



16

FIG. 16. Habu snake poisoning (2 hours). Vacuolation of the mesangial cell is the only abnormality found.  $\times 14,000$ .

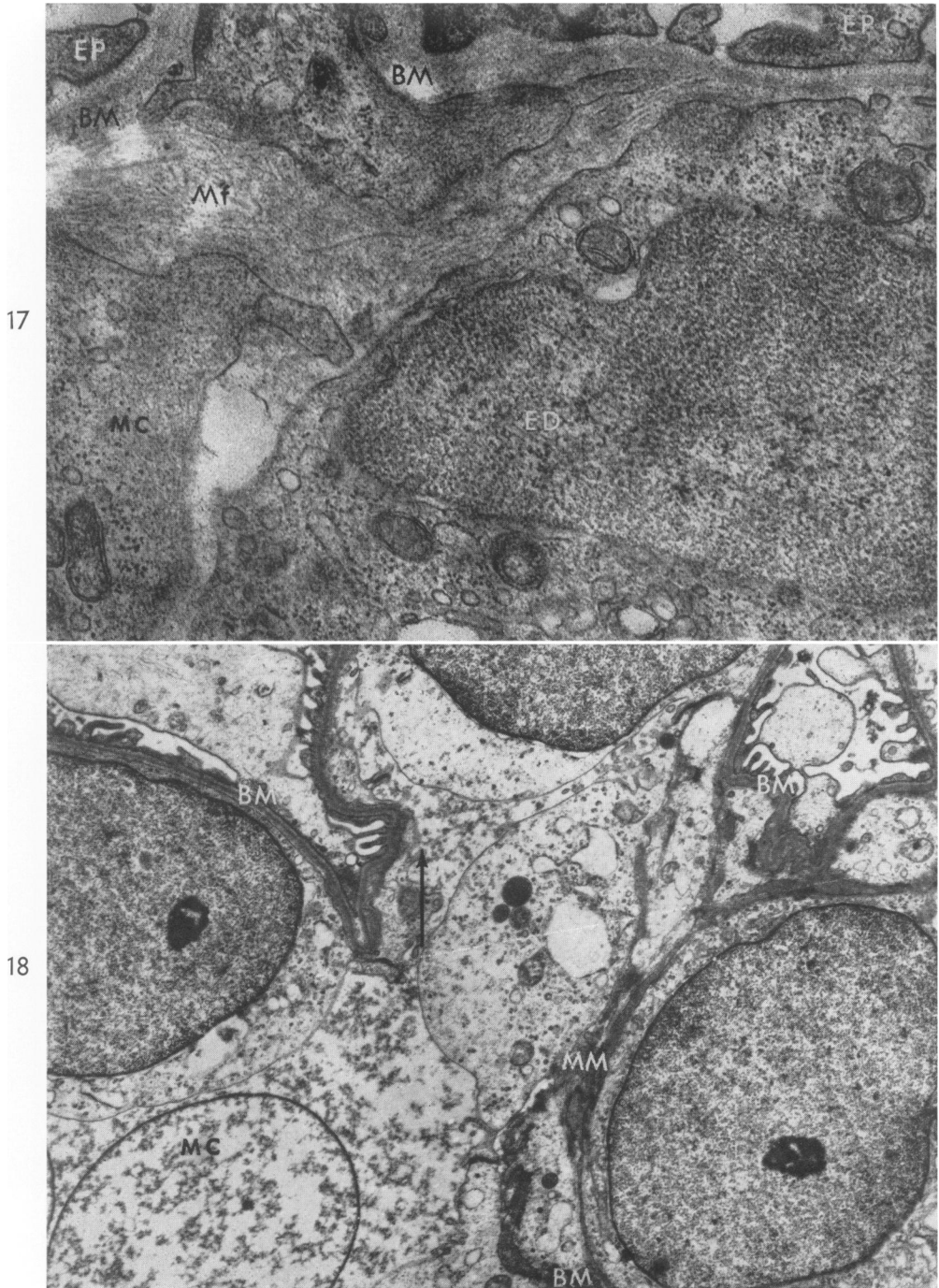


FIG. 17. Habu snake poisoning (2 hours). The mesangial matrix is less opaque and shows prominent fibrils due to edema.  $\times 40,000$ .

FIG. 18. Habu snake poisoning (8 hours). Completely degenerated mesangial cell is evident in the lower left corner. Other cells are partly preserved. The arrow points to degenerating mesangial matrix.  $\times 12,000$ .