

# BRITISH MEDICAL JOURNAL

LONDON SATURDAY MARCH 25 1961

## ASSOCIATION OF THYROTOXICOSIS AND AUTO- IMMUNE THYROIDITIS

BY

W. WATSON BUCHANAN, M.B., Ch.B.  
F.R.F.P.S., M.R.C.P.Ed.

W. D. ALEXANDER, M.B., Ch.B., F.R.F.P.S.  
M.R.C.P.Ed.

J. CROOKS, M.D., F.R.F.P.S., M.R.C.P.  
M.R.C.P.Ed.

D. A. KOUTRAS, M.D.

E. J. WAYNE, M.D., F.R.C.P., F.R.F.P.S.

J. R. ANDERSON, M.D. AND

R. B. GOUDIE, M.B., Ch.B., M.R.C.P.

*The University Department of Medicine, Gardiner Institute, and the University Department of Pathology,  
Western Infirmary, Glasgow*

Roitt and Doniach (1958) have demonstrated that circulating thyroid auto-antibodies are present in a large proportion of patients with auto-immune thyroiditis (Hashimoto's disease). In this paper we show that the application of these immunological tests in patients with symptoms suggestive of thyrotoxicosis is of considerable practical importance, since we have been able to identify two groups in which the correct diagnosis could not otherwise have been made and where mismanagement might have occurred.

In the first group evidence of auto-immune thyroiditis was found in patients with undoubted thyrotoxicosis. Only one fully documented case of this association has been previously described (Doniach and Hudson, 1959; Doniach *et al.*, 1960). We were also able to define a second group of patients who had been referred to the clinic because of suspected thyrotoxicosis and in whom radioiodine tests had appeared to confirm this diagnosis. Further investigations, however, showed that these patients were in fact euthyroid and that the presence of auto-immune thyroiditis explained the abnormal laboratory findings.

### Materials and Methods

The patients were assessed clinically by the procedure described by Crooks *et al.* (1959). By this method a numerical value is given to clinical symptoms and signs; a total value called the "clinical diagnostic index" is thus obtained. When less than 11 this index is normal; between 11 and 19 the diagnosis is equivocal; an index of 20 and above indicates thyrotoxicosis.

Routine radioiodine tests (4-hour and 48-hour gland uptake; 48-hour P.B.I-131) were carried out as described by Ansell *et al.* (1953). The potassium perchlorate discharge tests were done by the method described by Koutras *et al.* (1960). For the thyroxine suppression test 0.2 mg. of thyroxine sodium was administered daily for three weeks. A fall in gland uptake of more than 50% of the initial value indicates suppression in a normally functioning gland (Buchanan *et al.*, 1961).

Serum P.B.I was estimated by the method of Zak *et al.* (1952) as modified by Farrell and Richmond (1961).

Thyroid auto-antibodies were detected by the precipitin and complement-fixation tests (Anderson *et al.*, 1959). The precipitin test was recorded as either negative (-) or positive (+); and the complement-fixation test as negative (-), positive (+), or strongly positive (++) .

### Thyrotoxicosis with Severe Chronic Thyroiditis

The findings in five patients with unequivocal thyrotoxicosis and positive precipitin tests (group 1) are summarized in Table I, and brief case reports are given below. The diagnostic index lay within the thyrotoxic range in every case.

#### Case 1

A woman aged 38 complained of painless thyroid enlargement for one year and of tiredness and loss of 35 lb. (15.9 kg.) in weight. On examination she was extremely nervous and had a sinus tachycardia (120 a minute). A firm, moderately enlarged goitre with a bruit was present and bilateral exophthalmos was noted. The movements were hyperkinetic and there was a fine finger tremor. The skin was warm and moist.

Subtotal thyroidectomy was carried out after preparation with carbimazole and potassium iodide. During the pre-operative preparation the patient gained 14 lb. (6.4 kg.) in weight and became clinically euthyroid.

The excised thyroid tissue weighed 40 g. Microscopy revealed severe and extensive chronic thyroiditis, together with features suggestive of thyrotoxicosis. The chronic thyroiditis consisted of numerous large lymphoid follicles with large germinal centres, and extensive interacinar infiltration with lymphocytes and plasma cells. This latter change varied in intensity in different areas, and occasional small areas amounting to a small proportion of the thyroid tissue remained unaffected. The thyroid epithelium was arranged in small acini or solid clumps, and showed variations in nuclear size, increase of cytoplasm, and eosinophilia, amounting in places to fully developed Askanazy-cell change. Some of these features are illustrated in Figs. 1 and 2. Colloidophagy was present in many of the acini. In some areas, and particularly where chronic thyroiditis was mild or absent, the acini showed features typical of thyrotoxicosis—hyperplastic columnar epithelium forming small acini containing poorly staining colloid with scalloping at the edges (Fig. 3). Three months after the

TABLE I.—Summary of Clinical Details and Results of Investigations in Five Cases of Thyrotoxicosis with Positive Precipitin Tests (Group 1)

Case No.	Age and Sex	Diagnostic Index	Goitre	Eye Signs	Radioiodine Tests				B.M.R. (%)†	P.B.I. (µg./100 ml.)	Thyroid Auto-antibodies		Serum Flocculation Tests	Gamma-globulin	Progress
					4-Hour Uptake (% Dose)	P.B. I-131 (% Dose/1.)	Thyroid Suppression Test	KClO <sub>4</sub> Discharge Test			C.F.T.	T.R.A.			
1	38 F	25	Firm, diffuse, 50 g.*	Bilateral exophthalmos	69.0	0.48			+21		++		Ab-normal	Raised	Hypothyroid 3 months after operation
2	20 F	37	Firm, diffuse, 75 g.	Right-sided exophthalmos	78.5	5.47	Not suppressed	—	+40	12.8	++	+ 1/10,000	Normal	Normal	Euthyroid 1 year after operation
3	36 F	31	Firm, nodular, painful, 75 g.	None	97.0	1.43	„				++		„	„	Hypothyroid 2 months after operation
4	66 F	42	Firm, diffuse, 75 g.	Bilateral exophthalmos	95.0	1.09			+70	10.3	++	+ 1/320	„	„	Required high dose of KClO <sub>4</sub> to produce remission
5	49 F	34	Firm, nodular, 100 g.	None	86.5	4.85	Not suppressed	—		17.9	++	+ 1/640	„	„	Euthyroid 1½ years after I-131 therapy

C.F.T.=Complement-fixation test. T.R.A.=Tanned-red-cell agglutination. \* Assessed gland size is recorded in each case. † Robertson and Reid standards.

operation the patient had gained a further 17 lb. (7.7 kg.) in weight and complained of lethargy and intolerance of cold. The symptoms improved with substitution therapy, and she was well and euthyroid three months later.

### Case 2

A woman aged 20 gave a history of thyroid enlargement and prominence of the eyes of three months' duration. She had also noticed increasing dyspnoea on exertion, palpitations, tiredness, heat intolerance, nervousness, excessive sweating, and an increase in appetite. The goitre was diffuse and firm, with a bruit over both lobes. Exophthalmos, lid retraction and lid-lag, hyperkinesia, and fine finger tremor were present. The skin was hot and moist, and the resting pulse rate was 103.

After pre-operative treatment with potassium iodide subtotal thyroidectomy was performed. The excised thyroid tissue weighed 60 g. Microscopy showed accentuation of the lobular architecture, with rather less than half of the thyroid lobules showing changes typical of thyrotoxicosis with little or no thyroiditis. The remainder of the lobules showed varying degrees of superimposed chronic thyroiditis which included interfollicular infiltration with plasma cells and smaller numbers of lymphocytes, occasional lymph follicles, colloidophagy, and changes in the epithelium from the columnar type typical of thyrotoxicosis to Askanazy-cell type, sometimes with loss of follicular arrangement and aggregation of the cells in small clumps. The degree of these changes varied in different lobules and in different parts of the same lobule. Many lobules were, however, diffusely and severely involved.

### Case 3

A woman aged 36 gave a history of sudden onset of a tender and painful goitre. The pain lasted only a few days, but the goitre progressively increased in size. The patient complained of fatigue, irritability, palpitations, excessive sweating, and heat intolerance. A large, firm, nodular goitre with a bruit was present. There were hyperkinesia, fine finger tremor, warm moist skin, and a sinus tachycardia of 96 beats a minute.

After a pre-operative course of methylthiouracil the symptoms and signs of thyrotoxicosis disappeared and the patient gained 7 lb. (3.2 kg.) in weight.

A subtotal thyroidectomy was performed; the excised thyroid tissue weighed 65 g. and was firm and lobulated. The histological features were complex. The appearance in some areas was that of thyrotoxicosis, with columnar epithelium lining the vesicles, which contained scalloped and poorly staining colloid and showed numerous papillary projections into the vesicles. Marked nuclear pleomorphism

of the thyroid epithelium was seen, and nuclear debris and phagocytes occupied some of the vesicles. The colloid varied greatly in amount and in intensity of staining. Numerous foci of plasma cells and lymphocytes and lymph follicles were present, and some areas of Askanazy-cell changes found. In addition, several foci of necrosis up to 0.5 cm. in diameter were seen in areas which were not adenomatous, and there were also patches of fibrosis with thick-walled vessels, some of which showed acute inflammatory infiltration of the wall and some chronic periarteritis. The appearances were consistent with thyrotoxicosis and superimposed vascular changes and chronic thyroiditis affecting approximately 25% of the thyroid tissue.

Two months after operation the patient developed hypothyroidism, which required treatment with thyroxine sodium.

### Case 4

A woman aged 66 gave a history of protrusion of the eyes with excessive lacrimation and painless thyroid swelling of five years' duration. She complained of dyspnoea on effort, palpitations, excessive tiredness, nervousness, heat intolerance, and excessive sweating. She had lost 28 lb. (12.7 kg.) in weight, despite an increased appetite. On

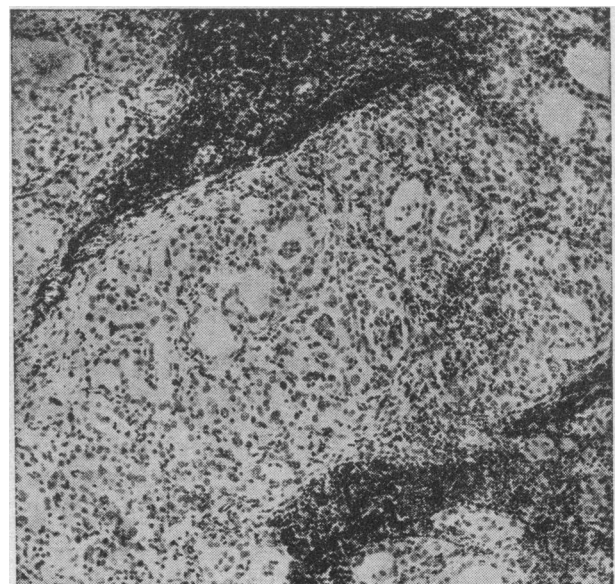


FIG. 1.—Case 1. Area showing chronic thyroiditis with diffuse round-cell infiltration, colloidophagy, and dense lymphocytic aggregates (Haematoxylin and eosin.  $\times 50$ .)

examination the thyroid gland was diffuse, firm, and moderately enlarged, with a bruit. Bilateral exophthalmos, lid retraction, and lid-lag were present. There was ophthalmoplegia for upward movement of the right eye, hyperkinetic movements, and fine finger tremor; the skin was warm and dry. A sinus tachycardia of 95 beats was recorded.

Treatment with potassium perchlorate was begun, and six months later she was euthyroid. When last seen two years later the precipitin test was negative.

**Case 5**

A woman aged 49 had first noticed a goitre five months previously, and for 10 months had complained of excessive tiredness, nervousness, heat intolerance, and loss of weight despite an increased appetite. The thyroid gland was moderately enlarged, firm, and nodular, with a bruit. Exophthalmos was absent, but bilateral lid retraction and lid-lag was noted. Hyperkinetic movements and fine finger tremor were present and the skin was hot and moist. The pulse rate was 87.

She was treated with 16 mc of I-131, followed by a second dose of 12 mc of I-131 five months later. She was well and euthyroid 18 months after the start of treatment and the precipitin test was still strongly positive.

**Auto-immune Thyroiditis Simulating Thyrotoxicosis**

Five patients suspected of thyrotoxicosis on clinical grounds who had radioactive iodine tests consistent with this condition (group 2) are summarized in Table II. The final diagnosis was shown to be euthyroid auto-immune thyroiditis. The case reports are given below. The diagnostic index lay within the equivocal range in every case.

*Case I.*—A woman aged 62 had had thyroid enlargement for six years. For the past two years she had complained of palpitations and tiredness, and had a preference for cold weather. A small, firm, nodular goitre without a bruit was present. There were no eye signs. Movements were hyperkinetic and the hands were warm and moist. No finger tremor was observed and the pulse rate was normal. Her symptoms gradually disappeared. Thyroxine therapy was later prescribed, and with this the goitre diminished in size.

*Case II.*—A woman aged 34 gave a history of goitre, dyspnoea on effort, palpitations, tiredness, preference for cold, and nervousness of three years' duration. On examination a small, diffuse, firm goitre without a bruit was present. The skin was dry and moist and the resting

TABLE II.—Summary of Clinical Details and Results of Investigations in Five Cases of Auto-immune Thyroiditis Presenting as Thyrotoxicosis (Group 2)

Case No.	Age and Sex	Diagnostic Index	Goitre	Radioiodine Tests				P.B.I. (µg./100 ml.)	B.M.R. (%)	Thyroid		Serum Flocculation Tests	Gamma-globulin
				4-Hour Uptake (% Dose)	P.B. I-131 (% Dose/l.)	Thyroid Suppression Test	KClO <sub>4</sub> Discharge Test			Precipitin Test	C.F.T.		
I	62 F	17	Firm, diffuse, 50 g.	45.6	0.41	Suppressed	—	3.3		+	++	Abnormal	Normal
II	34 F	19	Firm, nodular, 50 g.	46.4	0.49	..	—	4.6	+19	—	++	..	Raised
III	48 F	16	Firm, diffuse, 75 g.	50.6	0.42	..	+	5.3	+28	+	++	..	..
IV	63 M	14	Firm, nodular, 75 g.	51.3	0.46	..	+	4.6	+7	+	++	..	..
V	45 F	18	Firm, diffuse, 50 g.	46.2	0.40	..	+	4.2	-2	+	++	..	..

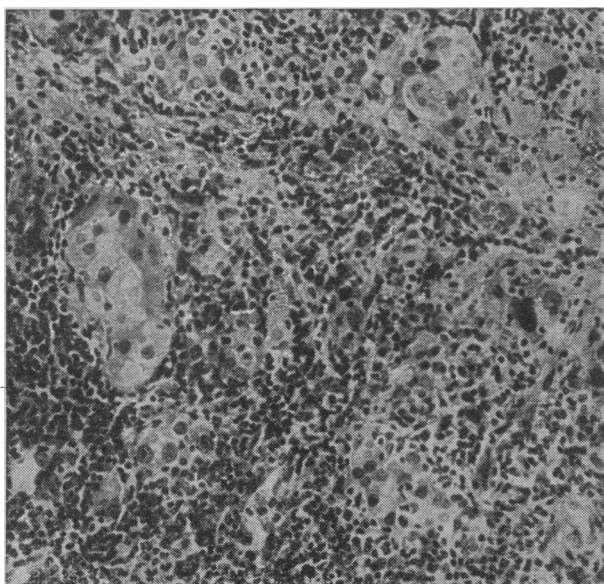


FIG. 2.—Case 1. Severe chronic thyroiditis showing dense and intimate interacinar infiltration with round cells. Thyroid acini are partly destroyed, and those remaining show Askanazy-cell change. (Haematoxylin and eosin. ×110.)

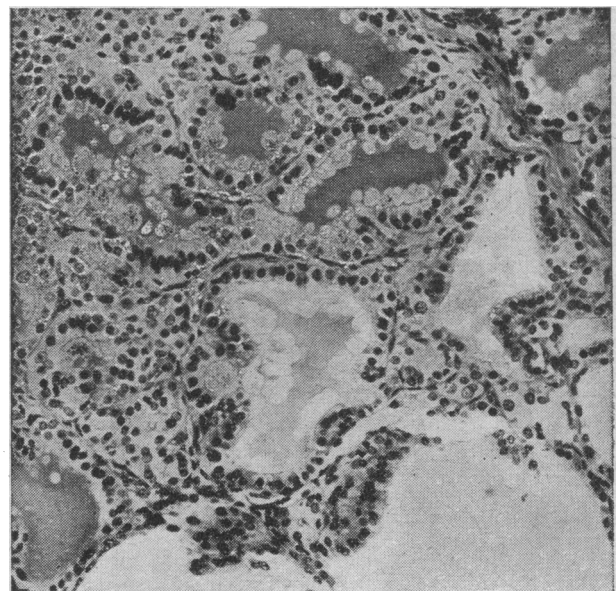


FIG. 3.—Case 1. Area of thyroid showing usual features of thyrotoxicosis. Chronic thyroiditis is absent. Such areas were scanty and small. (Haematoxylin and eosin. ×110.)

pulse rate was 89. A biopsy of the thyroid was carried out. The excised tissue showed widespread chronic thyroiditis, with lymphoid follicles, plasma-cell infiltration, and Askanazy-cell changes. There was also irregular fibrosis. After administration of thyroxine sodium the goitre diminished in size.

*Case III.*—A woman aged 48 had a history of goitre, dyspnoea on exertion, tiredness, nervousness, and loss of weight for two years. On examination the thyroid gland was moderately enlarged, diffuse, and firm. There was no bruit. Bilateral exophthalmos was present, but there was no lid retraction or lid-lag and no hyperkinesis. Fine finger tremor was present and the hands were warm and moist. The resting pulse rate was 112. The results of the investigations (Table II) showed that the patient was euthyroid, with auto-immune thyroiditis. Thyroxine sodium was prescribed and the goitre became smaller.

*Case IV.*—A man aged 63 gave a history of goitre of six months' duration and of increasing dyspnoea on exertion, excessive tiredness, intolerance of heat, and nervousness of one year's duration. A firm, moderately enlarged goitre with a bruit was present. Exophthalmos was noted, but there was no lid retraction or lid-lag. There was no hyperkinesis or fine finger tremor and the skin was cool and moist. The resting pulse rate was 81. The goitre diminished in size with thyroxine therapy.

*Case V.*—A woman aged 45 gave a three-year history of nervousness, excessive sweating, intolerance for heat, and loss of weight. The patient had been aware of a goitre for 11 years. On examination the thyroid was slightly enlarged, diffuse, and firm without a bruit. Slight bilateral exophthalmos was present. There was no hyperkinesis or finger tremor. The skin was hot and dry. The resting pulse rate was 96. The symptoms gradually disappeared and the patient remained well until two years later, when hypothyroidism developed. Thyroxine sodium 0.2 mg. daily was prescribed and the goitre diminished in size.

### Discussion

Before the development of immunological techniques for detecting thyroid auto-antibodies the term Hashimoto's disease was restricted by some (Joll, 1939; Statland *et al.*, 1951; Harland and Frantz, 1956) to diffuse changes of characteristic type occurring in the thyroid. Other workers (Hellwig, 1938; Friedman, 1949; Lindsay *et al.*, 1952) extended the description to include a focal lesion of the same type. Since the introduction of immunological methods thyroid auto-antibodies have been demonstrated in both diffuse thyroiditis and extensive focal thyroiditis (Paine *et al.*, 1957; Roitt and Doniach, 1958; Goudie *et al.*, 1959). Doniach *et al.* (1960) include both conditions under the heading "auto-immune thyroiditis."

All our proved thyrotoxic patients in group 1 had a positive precipitin test. A positive precipitin reaction is almost invariably associated with extensive destructive thyroiditis such as is found in Hashimoto's disease or in some cases of primary hypothyroidism (Roitt and Doniach, 1958; Anderson *et al.*, 1959; Doniach *et al.*, 1960). In three of these patients subtotal thyroidectomy was carried out and histological examination of the gland showed features of thyrotoxicosis and, in addition, focal chronic thyroiditis of far greater extent and severity than is usually seen in a thyrotoxic thyroid. The features were similar to those described by Doniach and Hudson (1959) in their case.

Our cases reveal the interesting coexistence of the histological features of thyrotoxicosis and destructive chronic thyroiditis, but any comment on their relationship must be speculative. It is possible that

thyrotoxicosis predisposes to the occurrence of auto-immune thyroiditis. Alternatively, both conditions might have a predisposing constitutional factor. The first possibility receives some support from the demonstration of enhanced immunological reactions in thyroxine-fed guinea-pigs (Long and Shewell, 1955).

The presence of this type of lymphocytic infiltration in a thyrotoxic gland may have practical significance. Thus it has been shown that when partial thyroidectomy is performed on glands of this type there is an increased liability to the development of post-operative hypothyroidism (Whitesell and Black, 1949; Greene, 1950; Levitt, 1951). Two of our cases developed hypothyroidism with unexpected rapidity after operation, and we would advise the use of more conservative forms of treatment in thyrotoxic patients with positive precipitin tests. Most clinicians have seen examples of hypothyroid patients who give a clear history of previous thyrotoxicosis, and when serological tests are found to be positive it seems likely that these are examples of spontaneous "cure" of the thyrotoxic element with subsequent progress of the auto-immunizing process.

Our second series of cases of auto-immune thyroiditis are interesting for a different reason. Clinically they had all appeared to be thyrotoxic and the radioiodine tests had apparently confirmed the diagnosis. Nevertheless, all were in fact euthyroid, and it was the routine performance of serological tests in our clinic which drew our attention to the true state of affairs. In auto-immune thyroiditis both the uptake of radioiodine by the gland and the level of protein-bound radioactive iodine are often increased and may fall in the range characteristic of thyrotoxicosis. The mechanism of these abnormal radioiodine tests is discussed elsewhere (Buchanan *et al.*, 1961). The patient has a goitre, and if she has symptoms of an anxiety state a mistaken diagnosis can easily occur. To avoid this, too much reliance should not be placed on the results of radioiodine tests, especially if the clinical findings are atypical. The most helpful tests in these cases are the thyroxine or tri-iodothyronine suppression test and the chemical estimation of the P.B.I. When these are not available a precipitin test for thyroid auto-antibodies should be performed. It is even simpler to carry out one of the flocculation tests used in the diagnosis of chronic hepatitis, and this would have given adequate warning in the five cases in this group which we have described.

### Summary

A series of five patients is described in which unequivocal thyrotoxicosis was associated with positive precipitin tests for thyroid auto-antibodies. The thyroid of three of these in which biopsy was performed showed changes consistent with the coexistence of thyrotoxicosis and of a type of extensive thyroiditis indistinguishable from Hashimoto's disease. In a further series of five patients with goitre and symptoms of anxiety, thyrotoxicosis was suspected clinically and the diagnosis was apparently confirmed by radioiodine tests; these patients were subsequently shown to be euthyroid and to have auto-immune thyroiditis. Radioiodine studies in equivocal cases of thyrotoxicosis should be interpreted cautiously. If suitable serological tests were carried out in all cases of overt or suspected thyrotoxicosis some patients would be saved from unnecessary destructive therapy by radioiodine or operation.

The work was supported by grants from the Secretary of State for Scotland on the recommendation of the Advisory Committee of Medical Research, and from the Medical Research Council.

## REFERENCES

- Anderson, J. R., Goudie, R. B., and Gray, K. G. (1959). *Scot. med. J.*, **4**, 64.
- Ansell, G., MacGregor, A. G., Miller, H., and Wayne, E. J. (1953). In *Radioisotope Techniques*, **1**, 52. H.M.S.O., London.
- Buchanan, W. W., Koutras, D. A., Alexander, W. D., Crooks, J., Wayne, E. J., Richmond, M. H., and Macdonald, E. M. (1961). *J. clin. Endocr.* In press.
- Crooks, J., Murray, I. P. C., and Wayne, E. J. (1959). *Quart. J. Med.*, **28**, 211.
- Doniach, D., and Hudson, R. V. (1959). *Proc. roy. Soc. Med.*, **52**, 178.
- and Roitt, I. M. (1960). *Brit. med. J.*, **1**, 366.
- Farrell, L. P., and Richmond, M. H. (1961). To be published.
- Friedman, N. B. (1949). *J. clin. Endocr.*, **9**, 874.
- Goudie, R. B., Anderson, J. R., and Gray, K. G. (1959). *J. Path. Bact.*, **77**, 389.
- Greene, R. (1950). *J. Endocr.*, **7**, 1.
- Harland, W. A., and Frantz, V. K. (1956). *Ibid.*, **16**, 1433.
- Hellwig, C. A. (1938). *Arch. Path. (Chicago)*, **25**, 838.
- Joll, C. A. (1939). *Brit. J. Surg.*, **27**, 351.
- Koutras, D. A., Alexander, W. D., Buchanan, W. W., Crooks, J., and Wayne, E. J. (1960). *Scot. med. J.*, **5**, 331.
- Levitt, T. (1951). *Lancet*, **2**, 957.
- Lindsay, S., Dailey, M. E., Friedlander, J., Yee, G., and Soley, M. H. (1952). *J. clin. Endocr.*, **12**, 1578.
- Long, D. A., and Shewell, J. (1955). *Brit. J. exp. Path.*, **36**, 351.
- Paine, J. R., Terplan, K., Rose, N. R., Witebsky, E., and Egan, R. W. (1957). *Surgery*, **42**, 799.
- Roitt, I. M., and Doniach, D. (1958). *Lancet*, **2**, 1027.
- Statland, H., Wasserman, M. M., and Vickery, A. L. (1951). *Arch. intern. Med.*, **88**, 659.
- Whitesell, F. B., jun., and Black, B. M. (1949). *J. clin. Endocr.*, **9**, 1202.
- Zak, B., Willard, H. H., Myers, G. B., and Boyle, A. J. (1952). *Analyt. Chem.*, **24**, 1345.

## HYPERCHOLESTEROLAEMIC XANTHOMATOSIS

### TREATMENT WITH A CORN-OIL DIET

BY

**E. M. JEPSON, M.B., M.R.C.P.**

Research Assistant, Cardiac Department,  
Westminster Hospital, London

There is much epidemiological evidence for an association between ischaemic heart disease, blood lipids, and dietary factors (Bronte-Stewart, 1959a, 1959b). Fat is the important constituent of the diet in the regulation of blood lipids (Ahrens, 1957), and dietary cholesterol has little influence on the blood level (Keys *et al.*, 1950). Keys (1952) thought that the major factor was the total amount of fat in the diet. Kinsell *et al.* (1952) showed that vegetable fat compared with an isocaloric amount of animal fat produced a significant fall in the blood lipids when fed to normal people.

In 1955 Kinsell and Michaels showed that there was a direct relation between the unsaturated-fatty-acid content of the diet and the effect on blood lipids, which was confirmed by Ahrens *et al.* (1955), Beveridge *et al.* (1955), and Bronte-Stewart *et al.* (1956). Kinsell and Sinclair (1957) postulated that the depressant effect on the serum lipids was due to the essential fatty-acid content, particularly linoleic acid, but this is unlikely (Ahrens *et al.*, 1959).

Other methods have been used to depress the blood lipids. Sitosterol, derived from plant sterols, in high dosage has a temporary effect (Barber and Grant, 1955; Leonard, 1956). Heparin has been used to lower the

blood cholesterol (Calvert, 1953; Soffer and Murray, 1954), but requires prolonged systemic administration and is not without danger. Oestrogens lower the blood cholesterol in hypercholesterolaemic men with coronary artery disease (Oliver and Boyd, 1954), but the unpleasant side-effects, especially feminization, may preclude its extensive trial. Similarly, nicotinic acid in very high dosage depresses the blood lipids in hypercholesterolaemia (Parsons *et al.*, 1956; Galbraith *et al.*, 1959). The effect is small and the side-reactions of the drug may be severe. It is not proposed to examine these methods further in this trial.

Familial hypercholesterolaemic xanthomatosis is a disorder characterized by xanthomata of skin and tendon with raised blood cholesterol and phospholipids (Thannhauser, 1958). The triglycerides (neutral fats) are normal or only slightly elevated. In the related disorder with xanthomata, idiopathic hyperlipaemia, the triglycerides are greatly increased. In hypercholesterolaemic xanthomatosis there is a high incidence of atherosclerosis and ischaemic heart disease (Fox, 1879; Müller, 1939; Cook *et al.*, 1947; Rigdon and Willeford, 1950; Barr *et al.*, 1954). Atherosclerosis is also common in idiopathic hyperlipaemia (Malmros *et al.*, 1954; Soffer and Murray, 1954; Martt and Connor, 1956), although the contrary view is held by Thannhauser (1958).

In attempts to lower the blood cholesterol by dietary modifications, little attention has previously been paid to the patient. Most experiments have been conducted in metabolic wards with formula feeds which are uninteresting, unpalatable, and impractical for patients carrying on a normal life. Observations have been made on changes in the blood lipids, and there is a tendency for the assessment of clinical improvement to be of secondary importance. This is not unexpected, for the investigations have been mainly concerned with the relation of the blood lipids to ischaemic heart disease. Improvement after any biochemical change is likely to take some time before the benefit may be assessed. A palatable diet is then of importance if such experiments are to be continued for some years. Such a diet containing a high proportion of unsaturated fat derived from corn (maize) oil was used in this study. The oil was given in the form of a "margarine," "milk," and "cheese," with supplements of oil for culinary purposes. The patients had familial hypercholesterolaemic xanthomatosis or idiopathic hyperlipaemia in which the incidence of atherosclerosis is high. Observations were made on the management of this diet and the biochemical response was followed during the treatment and a control period.

### Material and Methods

#### Patients Studied

16 patients from 11 families with hypercholesterolaemic xanthomatosis were investigated. One of them ceased to attend half-way through the trial, and another, a girl aged 17, died from myocardial infarction before the treatment began. Three additional patients with idiopathic hyperlipaemia and one with hypercholesterolaemia but no xanthomata were studied.

The clinical manifestations are shown in Table I. All but one of the patients had xanthoma tendinosum or xanthoma tuberosum. The site of these was recorded and the size of each measured with callipers. Measurement was repeated at the end of the control and treatment periods. The numbers which had increased,