

TECHNICAL SECTION:

Technical tutorials, notes and tips

Controlling cement chips in revision arthroplasty

Stephen M Blake, Jonathan Howell, Keith S Eyres

Princess Elizabeth Orthopaedic Centre, Royal Devon and Exeter Hospital, Exeter, UK

The number of revision arthroplasties performed on an annual basis continues to increase as a direct and consequent result of the ever-increasing number of primary arthroplasties. In this unit alone, 215 cases were done in the last financial year (134 revision total hip replacements, 71 revision total knee replacements, and 10 revision shoulder replacements). During revision arthroplasty surgery, it is necessary to remove previously inserted cement. This is often accomplished with the use of an osteotome and mallet, but may be supplemented by additional methods (e.g. pneumatic powered drill and chisels,¹ intracorporeal lithotripter,² and even a laser³). It is important when removing cement with the osteotome that the chips are controlled and not allowed to leave the surgical field. If cement chips were to leave the field, they would have the potential to return contaminated (e.g. ricocheting off a surgeon's mask or a theatre light) or to expose other theatre personnel to potentially high-risk, blood-contaminated material. These risks are reduced when wearing sterile operating suits. The technique described here has the advantages of negligible cost and allows cement chip control while allowing the surgeon a perfect view of the field.

Method

In this technique, a standard, clear splash shield is used (e.g. the MicroAire® 4-inch Splash Shield); alternatively, the prosthesis or ravage tubing container may be used. Prior to commencing cement removal, a small hole is made in the base of the splash

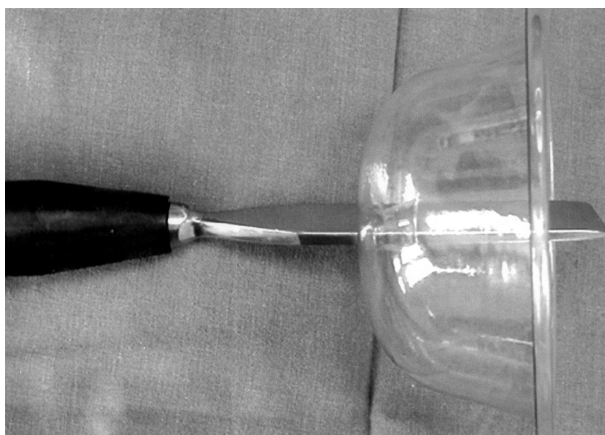


Figure 1 Splash shield with osteotome inserted.



Figure 2 Splash shield advanced down osteotome prior to use.

shield using a scalpel. The required osteotome is then inserted through this hole (Fig. 1). The osteotome is then positioned at the point at which cement removal is to begin. This is easily visualised due to the clear plastic of the splash shield. Following positioning, the splash shield may be advanced down the osteotome so as to minimise the gap of potential cement chip escape (Fig. 2). The use of the osteotome may then commence. In this way, any cement chips that are sprung away from the field simply travel as far as the inside of the splash shield and then return to the operative site. Following sufficient cement removal, the shielded osteotome can be withdrawn and the chips recovered. The process may then be repeated as necessary. In using this technique, the cement chip displacement is controlled, while still allowing an excellent view of the operative field.

References

1. Porsch M, Schmidt J. Cement removal with an endoscopically controlled ballistically driven chiselling system. A new device for cement removal and preliminary clinical results. *Arch Orthop Trauma Surg* 2001; **121**: 274–7.
2. Gardiner R, Hozack WJ, Nelson C, Keating EM. Revision total hip arthroplasty using ultrasonically driven tools. A clinical evaluation. *J Arthroplasty* 1993; **8**: 517–21.
3. Lee CL, Roberts C, Litsky AS. Laser ablation of dyed acrylic bone cement. *Lasers Surg Med* 1997; **20**: 280–9.

Correspondence to: Mr Stephen M Blake, Moss Rose Cottage, Stoodleigh, Tiverton, Devon EX16 9PR, UK
E-mail: stephenblake_uk@yahoo.co.uk

A novel use of a 'DHS-type' plastic vertical isolation drape in spinal surgery

SK Singh, HV Nagesh, M Lock

Department of Orthopaedic Surgery, William Harvey Hospital, Ashford, Kent, UK

Vertical isolation drapes are widely used for draping in dynamic hip screw (DHS) fixation of inter-trochanteric fractures of femur; here, we describe their potential advantages in spinal surgery.

We use Barrier Brand vertical isolation drape (Johnson and Johnson Medical Limited, MBD 527; 320 cm x 240 cm with a central adhesive area of 49 x 49 cm). It has a large pouch which, during DHS fixation, collects blood and wash. It also has two Velcro straps for holding the diathermy and the suction tube. Most manufacturers' vertical isolation drapes are similar.

The patient is positioned prone or lateral on the operating table. The skin around the operative site is prepared, but must be dry before application of the DHS drape.

The adhesive part of the still-folded DHS drape is orientated and held by the surgeon. For a patient in the prone position, we use the drape transversely with the pocket towards the foot end. If the patient is in a lateral position, then we apply the drape longitudinally so that it covers the chest, abdomen and pelvis. In this position, the position of the pouch will vary according to which side the surgeon stands. An assistant removes the backing paper, the drape is applied, and only after it is firmly stuck is it unfolded,

The non-adhesive parts of the drape are elevated and secured with bulldog clips to drip-stands at the head-end to form a screen and left free at the foot-end. The drape is long enough to cover the feet. The pouch that collects spilled blood and wash during DHS fixation can now be used to hold instruments such as the sucker and diathermy forceps. To avoid accidental penetration of the plastic by instruments during the operation and to maintain the patient's modesty, we drape a cotton or disposable abdominal sheet over the buttock. It is placed under the pocket and secured via the Velcro tabs or with adhesive strips just caudal to the proposed incision.

Discussion

The standard spinal surgery draping technique is to use an upper and lower and two-side sheets or non-transparent disposable drapes. The four corners where drapes overlap are secured to the patient's skin with towel clips. A plastic self-adhesive incise drape is used to shut off the operative field. Huss *et al.*¹ have described the use of transparent c-arm drapes to observe foot movement during the Stagnara wake-up test. The transparent drape is used to expose the foot.

Both the standard and Huss draping techniques have disadvantages. First, they are cumbersome as they involve handling of multiple sheets. Second, the anaesthetist needs to lift the drapes to observe, listen to the chest, or to access limbs for various lines. This carries potential risk of compromising the sterile surgical field.

The vertical isolation drape addresses both problems. It is a single, transparent drape with a central adhesive area. This provides a simple, secure, quick and reproducible technique of draping in spinal surgery. We have used this technique for

more than 14 years and have had no episodes of dislodgement, allergy or infection attributable to the drape.

We also use a warm air heater under the polythene sheet in what are often long procedures. The anaesthetist can sit and still observe the operation under the screen rather than peering over it and compromising the sterile field.

Reference

1. Huss GK, Betz RR, Clancy M. A draping technique for spinal surgery using the Stagnara wake up test. *AORN J* 1988; **48**: 530–5.

Correspondence to: M Lock FRCS, Consultant Orthopaedic Surgeon, William Harvey Hospital, Ashford, Kent, UK

Cable ties for pelvic stabilisation

MS Duxbury¹, ND Rossiter², AW Lambert¹

¹Surgical Directorate and ²Department of Orthopaedics, Derriford Hospital, Plymouth, UK

Acute traumatic pelvic ring instability can cause severe pain and haemorrhage. Non-invasive pelvic stabilisation with a knotted bed sheet is a commonly used, readily available, inexpensive, disposable and rapid means of temporary pelvic stabilisation.¹ We report a modification to the technique which we believe facilitates application and minimises patient discomfort.

The ends of a bed sheet, passed around the patient's pelvis, are brought out and crossed anteriorly. The correct tension is applied to the sheet ends, which are fixed with a single twist (Fig. 1) and secured with two cable ties. This modification, using readily available cable ties, easily produces secure, temporary, external pelvic fixation.

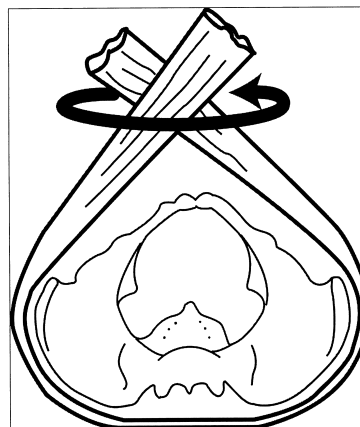


Figure 1 Application of sheet with single twist.

Reference

1. Routt Jr ML, Falicov A, Woodhouse E, Schildhauer TA. Circumferential pelvic antishock sheeting: a temporary resuscitation aid. *J Orthop Trauma* 2002; **16**: 45–8.

Correspondence to: AW Lambert, Surgical Directorate, Derriford Hospital, Plymouth, UK. Tel: +44 1752 517536; Fax: +44 1752 792537; E-mail: anthony.lambert@phnt.swest.nhs.uk

Tear-drop incision for mastectomy to avoid dog-ear deformity

M Mirza, KS Sinha, K Fortes-Mayer

Department of Surgery, Walsall Manor Hospital, Walsall, UK

In mastectomy incisions, the dog-ear deformity can be a problem especially in large-breasted women. The deformity is unsightly and a source of long-term discomfort to the patient.¹ Surgical techniques to correct the deformity include lengthening the scar, excising the excess of underlying subcutaneous tissue,² and a fish-shaped incision. The latter provides adequate exposure to axilla, but at the expense of a Y-shaped scar.³

It was observed that excising dog-ear produces a tear-drop defect and closure of this defect produces a linear scar. We have incorporated this into our practice and perform all mastectomies – regardless of the size, shape and excessive subcutaneous fat – at the axillary fold.

Technique

A tear-drop shaped incision, with the 'point' of the tear-drop medially, is marked over the breast (Fig. 1). The size of the tear-drop incision depends on the amount of breast tissue, site of tumour, and previous scar. The 'broader' segment of the tear-drop includes the axillary fat pad. Mastectomy with or without clearance is performed, and skin is closed using subcuticular sutures after suction drainage.

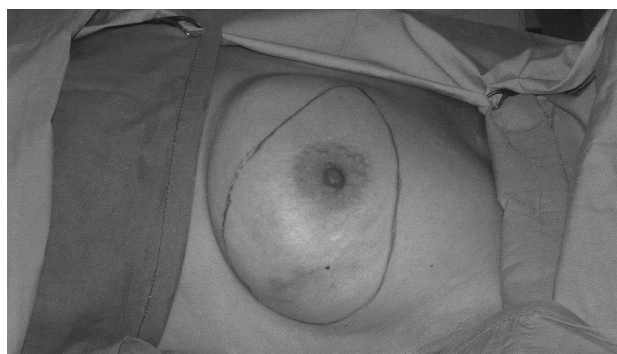


Figure 1 Showing tear-drop marking.

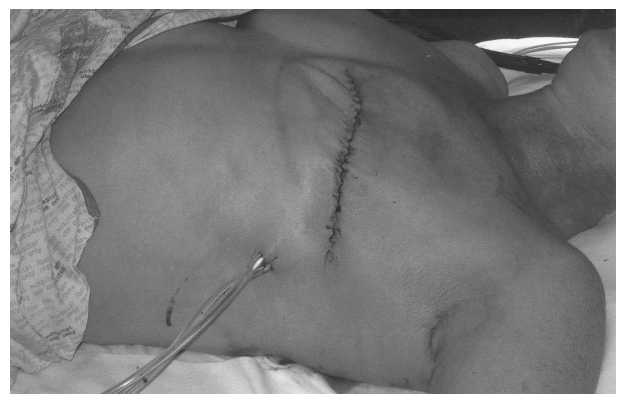

Figure 2 Closure of tear-drop incision produces a flat scar and no dog-ear deformity.

The technique described seldom produces any dog-ear deformity in our practice, and is suitable for both small- and large-breasted women and those with excessive fat along the axillary fold. It incorporates the tumour and provides adequate clearance of the primary lesion and good exposure to axilla. A cosmetically sound and flat scar is obtained (Fig. 2) that is suitable for the new 'stick on' prosthesis.

References

1. Farrar WB, Fanning WJ. Eliminating the dog-ear in modified radical mastectomy. *Am J Surg* 1988; **156**: 401–2.
2. Chretien-Maruet B, Bennaceur S. Dog ear: true and false. A simple surgical management. *Dermatol Surg* 1997; **23**: 547–50.
3. Nowacki MP, Towpik E. A fish shaped incision for mastectomy. *Surg Gynecol Obstet* 1988; **167**: 251–2.

Correspondence to: Mr K Fortes-Mayer, Consultant General & Breast Surgeon, Walsall Manor Hospital, Walsall, UK

A simple technique to avoid inadvertent deep anchorage of surgical drains

A Maury, C Southgate, A John

Department of Orthopaedic surgery, University Hospital of Wales, Cardiff, UK

Surgical drains are used to decrease haematoma formation after wound closure. A complication of their use is inadvertent suturing of the drain to deep tissue.¹ We recommend the following method of placement. The trocar is passed from the wound. The free end of the drain is positioned overlong with 2–3 cm protruding. Closure proceeds away from the free end. The trocar end of the drain is pulled until the protruding end slides under the closed layer. Any resistance indicates accidental anchorage, which may be rectified before the patient leaves theatre.

Reference

1. Kirk RM, Mansfield AO, Cochrane J. *Clinical Surgery in General, The Royal College of Surgeons' Course Manual*, 2nd edn. Edinburgh: Churchill Livingstone, 1996.

Correspondence to: Mr AC Maury, 29 Newcastle Close, Drighlington, Bradford BD11 1DF, UK
E-mail: tmaury@bigfoot.com

A new way of monitoring and nursing patients with melaena

R McGregor, JA Keir, G Wilson, C Dawson

Department of Urology, Edith Cavell Hospital, Peterborough District Hospital NHS Trust, Peterborough, UK

Haematemesis and melaena is a relatively common event accounting for 47,000 hospital admissions each year in the UK.¹ Often, the passage of melaena is associated with incontinence, making it hard to quantify. We have used a 3-way catheter inserted into the rectum with the balloon inflated with 40 ml of water as a collecting system.

This method is well tolerated, with the melaena being collected in a catheter bag and the incontinence controlled. To our knowledge, we are the first to report this technique.

Reference

1. Johnston SJ, Jones PF, Kyle J, Needham CD. Epidemiology and course of gastrointestinal haemorrhage in North-East Scotland. *BMJ* 1973; **3**: 655–60.

Correspondence to: Mr R McGregor, Department of Urology, Edith Cavell Hospital, Peterborough PE3 6QZ, UK

A do-it-yourself vascular anastomosis simulator

AR Weale^{1,2}, DC Mitchell¹

¹Department of Vascular Surgery, Southmead Hospital, North Bristol NHS Trust, Bristol, UK

²Department of Clinical Veterinary Medicine, University of Bristol, Langford, Avon, UK

Surgical simulators have been suggested as a way of learning surgical skills and have been used extensively in laparoscopy training.^{1,2} This article illustrates how a simple, low fidelity, 'do-it-yourself' vascular anastomosis simulator can be created.

The materials required for the simulator can be purchased from DIY stores and borrowed from theatre. Parts from DIY store are: (i) re-enforced rubber hosing – 10 mm internal diameter, 15 mm external diameter; (ii) plastic storage box; (iii) flat drill bit (16 mm diameter) and drill; and (iv) garden hose connectors (optional). Parts available from theatre are: (i) Vygon™ plastic adaptor – double cone straight connectors (10 mm to 7 mm); (ii) scalpel; (iii) forceps; (iv) needle holder; (v) re-sterilised operative 'off cuts' of PTFE-graft material; and (vi) 5/0 prolene suture.

Drill a number of holes in the side of the plastic storage box. Cut the hose into approximate 10 cm lengths and push through the holes. The garden hose connectors can be added optionally to allow connection to a water supply to test the anastomosis. The double cone adaptors are glued into position in the hoses. This

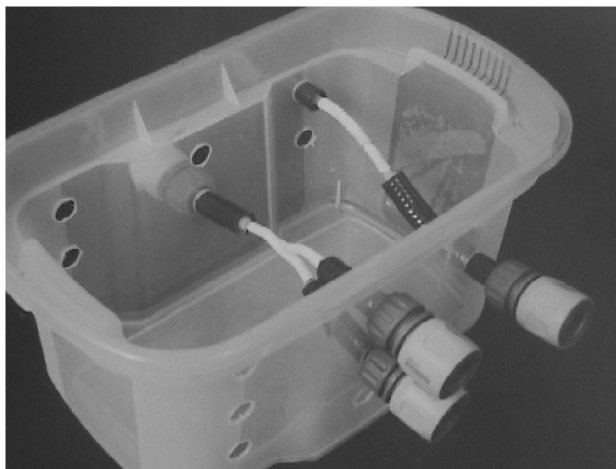


Figure 1 A completed 'do-it-yourself' vascular anastomosis surgical simulator.

allows 6–8 mm pieces of graft material to be used. Varying the positions of the holes and graft lengths allows practice of end-to-side, and end-to-end anastomoses, at different depths. The finished simulator is illustrated in Figure 1.

Discussion

This simple, home-made simulator allows any trainee to practice a vascular anastomosis. Such alternative strategies for acquiring technical skills should complement current training.

References

1. Paisley AM, Baldwin PJ, Paterson-Brown S. Validity of surgical simulation for the assessment of operative skills. *Br J Surg* 2001; **88**: 1525–32.
2. Hamdorf JM, Hall JC. Acquiring surgical skills. *Br J Surg* 2000; **87**: 28–37.

Correspondence to: AR Weale, Royal College of Surgeons of England Research Fellow, Department of Vascular Surgery, Southmead Hospital, Westbury on Trym, Bristol BS10 5NB, UK Tel: +44 117 959 5166; Fax: +44 117 959 5168

Improving the view at flexible cystoscopy

DA Payne, RC Kockelbergh

Department of Urology, Leicester General Hospital, Leicester, UK

During flexible cystoscopy, visualisation of the bladder mucosa can be impaired due to debris, blood or a large residual volume of urine within the bladder. A simple technique using suction applied to the instrument port of the cystoscope can be employed to empty the bladder (Fig. 1). Under direct visualisation of the bladder mucosa, 40–60 Kpa of suction is applied and the bladder gradually emptied. By allowing ingress of air between suction tubing and the cystoscope, the suction pressure can be varied. This technique is simple to perform, avoids traumatic re-instrumentation and prevents unnecessary further visits for rigid cystoscopy.



Figure 1 Suction tubing attached to the instrument port of the flexible cystoscope.

Correspondence to: Mr DA Payne, Department of Surgery, Clinical Sciences Building, Leicester Royal Infirmary, Welford Road, Leicester LE7 2LX, UK. Tel: +44 116 221 3152; Fax: +44 7092 331381; E-mail: dapydoc@yahoo.co.uk