

CHANGES IN THE INCISOR TEETH OF ALBINO RATS WITH VITAMIN A DEFICIENCY AND THE EFFECTS OF REPLACEMENT THERAPY *

ISAAC SCHOUR, D.D.S., Ph.D.; M. M. HOFFMAN, D.D.S., M.S., and
M. C. SMITH, Ph.D.

(From the Department of Histology, University of Illinois College of Dentistry, Chicago, Illinois, and the Department of Nutrition, University of Arizona, College of Agriculture, Tucson, Ariz.)

“The pathology of vitamin A deficiency indicates that the seat of the physiologic disturbances is in the epithelial cells. Chemical rôles are suppressed but proliferative powers are not inhibited; neither are the potentialities of cells lost, as is shown by the return to normal physiologic function when vitamin A is restored to the animal.”—Wolbach.

The classic work of Wolbach and Howe^{1, 2} on the dental changes in vitamin A deficiency stimulated this investigation. The purposes of this study were to repeat some of their work; to study the effects of chronic vitamin A deficiency; to measure the rate of appositional growth of dentin in vitamin A deficiency; and to interpret the findings in the light of the more recent knowledge of the histophysiology of the rat incisor.

REVIEW OF LITERATURE

The dental findings of Wolbach and Howe² may be summarized as follows: (1) The initial effect upon the incisor teeth of rats consisted of an atrophy of the enamel organ which began in the anterior portion and finally extended to the whole length of the tooth. (2) Atrophy and depolarization of the odontoblasts followed the changes in the enamel organ. The odontoblasts showed more severe alterations on the lingual side where the dentin was thin, folded, or absent. The odontoblasts survived longer on the labial side where the dentin was excessively wide. Osteoid tissue and epithelial cells derived from the enamel organ were found in the pulp. (3) Effects of replacement therapy with butter fat were noted within 7 days. Repair began in the region of Hertwig's epithelial sheath and was manifest by a recovery of the enamel organ and resumption of the normal morphology and function of the odontoblasts. Tubular predentin was now

* Aided by grants from Mead Johnson and Company and from the Carnegie Corporation of New York.

Received for publication February 26, 1941.

deposited. The epithelial cells in the pulp were surrounded by dentin, which in turn was surrounded by odontoblasts. Excessive local formation of atypical dentin increased with the recovery period. Morphological recovery was complete in 19 days.

Wolbach and Howe² used a diet that was deficient in vitamins A, C, D and E, but indicated that the lack of vitamins C, D and E was insignificant in respect to complicating the vitamin A-deficiency picture in the rat. They found that the addition of vitamin A alone was sufficient to bring about histological recovery. In a later report Wolbach³ gave the following summary on the teeth in vitamin A deficiency: "The continuously growing incisor teeth of rodents—rats and guinea-pigs—are profoundly affected owing first to atrophy and metaplasia of the enamel forming organ and subsequently to atrophy and cessation of or irregular functioning of odontoblasts. Enamel formation is suppressed, and striking deformities of the dentin result."

Boyle⁴ described, in the tooth germ of a human infant with vitamin A deficiency, changes in the enamel organ which were similar to those found by Wolbach and Howe² in the rat incisor. Mellanby and King⁵ found hyperplasia of the gingivae and periodontal disease in dogs, rabbits and rats placed on a diet deficient in vitamin A. King⁶ confirmed previous findings in dogs, and in addition reported retarded eruption and malposition of the teeth; malformation of the roots associated with hypoplastic changes in Hertwig's epithelial sheath; ill-defined laminae durae; changes in alveolar bone and a tendency to apical hypercementosis. King⁷ also studied the effects of vitamin A deficiency in the rat and emphasized the disturbance in the calcification of dentin in spite of the fact that the animals were given ample amounts of vitamin D, calcium and phosphorus. Smith and Lantz⁸ reported a loss of normal pigment and a dull white, opaque appearance of the incisors of rats placed on a vitamin A-deficiency ration. The teeth were short and blunt. Eruption was markedly retarded. Fridericia and Gudjonsson⁹ also reported progressive retardation in the eruption of the incisors of rats in vitamin A deficiency. Orten, Burn and Smith¹⁰ studied the effects of prolonged incomplete vitamin A deficiency in the incisor of the white rat. They reported tumor growths (odontomata) which arose from the pulp and proliferated in some cases to the point

of replacement of the alveolar bone. Pohto¹¹ found atrophic changes in the odontoblasts that were similar to those found by Wolbach and Howe.² He emphasized the peglike dentin projections and the prominent foldings. The latter were present in the labial as well as the lingual dentin when the vitamin A deficiency was prolonged.

More recently Mellanby¹² reported on the changes in the incisors and molars of young rats whose mothers received a diet deficient in vitamin A for 5 to 7 months. The incisors showed degeneration of the enamel organ and of the ameloblasts and reduction of blood supply. Enamel was lacking in some areas. The odontoblasts degenerated on the lingual side. The dentin was poorly calcified and distorted in outline. The molars also showed defective enamel formation and poor calcification of dentin. The pulp contained ossifying areas. Mellanby emphasized the disturbance in the organizing action of the enamel organ.

For additional references the reader is referred to Wolbach and Howe² and Pohto.¹¹

MATERIAL AND METHODS

This study is based on 199 rats which were placed, at weaning, on a diet deficient in vitamin A for a period of 9 to 81 days. The animals were weaned at 21 days of age.

The diet consisted of:

Cornstarch	66.5 per cent
Casein (Vitamin A free)	18.0 per cent
Brewer's yeast	10.0 per cent
Osborne and Mendel's salt mixture	4.0 per cent
Sodium chloride	1.0 per cent
Irradiated cholesterol	0.5 per cent

The animals were weighed weekly. Vitamin A reserve was considered to be depleted when the animals became stationary in weight and showed early signs of xerophthalmia (21 to 26 days). Twelve animals of the same colony, placed on the normal stock diet, were used as controls. The experimental animals were grouped as follows:

Group I consisted of 70 rats on vitamin A-deficient diet without replacement therapy (Table I). These animals were placed on the deficient diet for a period of 26 to 56 days following weaning. They did not survive longer than 56 days.

TABLE I

Group I. Seventy White Rats Placed on a Vitamin A-Deficient Diet Arranged According to Duration of Survival Period

Sub-groups	Experimental history				Findings		
	Number of animals	Age at beginning of experiment (days)	Age at death (days)	Duration of experiment (days)	Gross	Dental	
						Radio-graphic	Histo-pathologic
A	12	21	45-47	24-26	Sensitive to light; cessation in increase in weight	—	— (+)
B	17	21	55-59	34-38	Xerophthalmia; mild cessation in increase in weight	+	++
C	32	21	65-69	44-48	Severe xerophthalmia; loss in weight	++	+++
D	9	21	73	48-56	Very severe ophthalmia; loss in weight and near death	++++	++++

Number of plus (+) signs indicates degree of severity of changes.

Group II consisted of 34 rats on a vitamin A-deficient diet with replacement therapy consisting of additions of definite amounts of alfalfa or cod liver oil. Twelve animals of this group were fed a vitamin A-deficient diet for 25 days after weaning. Suboptimal rations of alfalfa were then added to the basal diet for 8 weeks. These animals survived longer than those of group I and were sacrificed at the age of 102 days (Table II). Four animals were placed on 1 per cent alfalfa-leaf meal concurrently with the basal vitamin A-deficient diet for 56 days. The remaining animals were given total replacement therapy with cod liver oil after varying periods of vitamin A deficiency.

Group III. Ninety-five albino rats were placed on a complete vitamin A-deficient diet at 21 days of age and given intraperitoneal injections of 0.5 cc. of a 2 per cent solution of alizarin red S at intervals of 4 to 11 days in order to find the rate of apposition of the dentin in the incisor and of the dentin, cementum and

TABLE II
 Group II. Thirty-four White Rats Placed on a Vitamin A-Deficient Diet Plus a Suboptimal or Total Replacement Diet Arranged According to Duration of Survival

Sub-groups	Number of animals	Age at beginning of experiment (days)	Length of experiment prior to giving of replacement (days)	Duration of complete experiment (days)	Duration of replacement diet (days)	Type of replacement	Age at death (days)	Findings		
								Gross	Radiographic	Histopathologic
A	4	21	0	56	56	Alfalfa 1%	77	Normal
B	12	21	25	81	56	Suboptimal alfalfa	102	Xerophthalmia and loss in weight	++++	+++ No signs of repair
C	12	21	29	44-54	15-25	Total replacement with cod liver oil	65-75	Complete recovery from xerophthalmia and weight loss	+	Active reparative processes in proximal half of incisor +
D	6	21	44	54-64	10-20	Total replacement with cod liver oil	75-85	Mild recovery from xerophthalmia and no gain in weight	+++	+++ Reparative process beginning

Number of plus (+) signs indicates degree of severity of changes.

TABLE III
 Part of Group III. Sixty Albino Rats on a Vitamin A-Deficient Diet and the Daily Rate of
 Dentin Apposition in Their Incisor Teeth

Sub- groups	Number of animals*	Age at which alizarin red S was injected	Replacement therapy and ages at which started	Age at death (days)	Average rate of apposition per 24 hours				Approximate ratio between daily rates at midlingual and at midlabial regions
					Mid- labial (μ)	Disto- lingual (μ)	Mesio- lingual (μ)	Mid- lingual (μ)	
1	45	(days) 30, 40 43, 54 47, 57 50, 60 64, 72	None	45	16.14	14.38	13.76	13.42	3:4
			None	73	16.79	13.11	12.48	10.86	2:3
			None	77	17.91	12.85	12.13	9.57	1:2
			None	65	18.68	11.14	10.75	7.84	1:2
			None	77	19.63	11.29	9.01	6.43	1:3
2	8	47, 51	Insufficient suboptimum vitamin A replacement as blue gramma grass at 47 days	52	18.32	12.47	11.83	8.91	1:2
3	7	50, 60 60, 70	Full replacement at 50 days	75	13.12	15.78	15.76	15.81	1:1
			" " " "	75	15.97	15.83	15.80	15.91	1:1

* All rats were placed on vitamin A-deficient diet at 21 days of age (weaning).

TABLE IV
Part of Group III. Thirty-five Albino Rats on a Vitamin A-Deficient Diet and the Effects of Cod-Liver-Oil Replacement on the Rates of Dentin Growth in Their Incisor Teeth

Sub-groups	Number of animals*	Daily units of cod liver oil	Age at beginning of replacement (days)	Age at which alizarin was injected		Age at death (days)	Daily rates of dentin growth		Ratio of midlingual to midlabial
				1st injection (days)	2nd injection (days)		Lingual (μ)	Labial (μ)	
1	5	1	42-48	50	60	65	8.35 ± .74	15.93 ± .08	1:2
2	5	2	42-48	50	60	65	12.54 ± .40	16.66 ± .33	3:4
3	5	3	42-48	50	60	65	12.40 ± .21	16.76 ± .10	3:4
4	5	4	42-48	50	60	65	12.62 ± .13	16.10 ± .16	3:4
5	5	5	42-48	50	60	65	15.52 ± .24	15.91 ± .17	1:1
6	4	1	42	42	52	56	8.46 ± .37	17.80 ± .09	1:2
7	3	2	42	42	52	56	12.11 ± .16	17.08 ± .20	3:4
8	3	5	42	42	52	56	15.75 ± .22	15.95 ± .36	1:1

* All animals were placed on a vitamin A-deficient diet at 21 days of age and carried on the deficient diet until outward symptoms (weight gain and xerophthalmia) appeared.

alveolar bone in the molar. The animals were sacrificed from 5 to 30 days following the initial injections. Fifty animals of this group were given various levels of replacement therapy (Tables III and IV).

Radiographic and Histologic Methods

The dietary experiments and the administration of alizarin red S were carried out in the chemical laboratory at Tucson, Arizona (M. C. S.), where the gross conditions of the living animals were also observed and recorded. After death the animals were decapitated and the heads were fixed in a 4 per cent aqueous solution of formaldehyde and sent to the histologic laboratory of the College of Dentistry, University of Illinois, where the radiographic and histologic studies were carried out.

The heads were split in halves by a midsagittal cut between the left and right incisors. Each half was radiographed by exposure on a dental occlusal film for 5 seconds, 5½ in. from the aperture of the tube casing, without the cone attached. A standard dental X-ray machine was used.

The jaws of groups I and II were washed and then de-

calcified in 5 per cent nitric acid for 24 hours. After dehydration and embedding in celloidin, serial midsagittal (longitudinal) and transverse sections of the incisors were stained with hematoxylin and eosin and mounted. Our studies were based mainly on longitudinal sections which facilitate the ready tracing of events from the basal to the anterior level.

The teeth of the animals that were given injections of alizarin red S were studied in ground as well as in decalcified sections. Transverse sections of upper and lower incisors were prepared by grinding on a medium and then a fine carborundum stone mounted on a dental lathe. Longitudinal ground sections of the uppers were also prepared. The lower incisors, because of the marked twist in their anteroposterior axes, were cut in half at the level of the first molar, and each half was then ground.

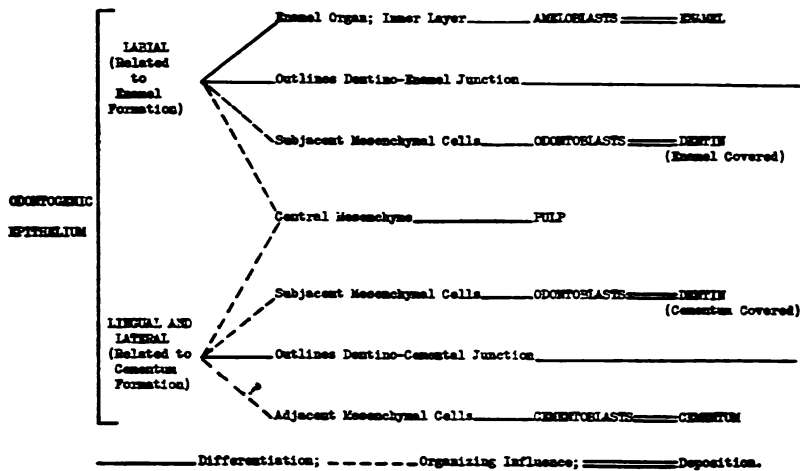
Measurements were made with a filar micrometer eyepiece, standardized to a stage micrometer. By measuring the distance between any two injection effects and dividing this by the time interval the daily rates of apposition were obtained.¹³ The figures on the appositional rates were subjected to statistical evaluation. Transverse and longitudinal ground sections were also prepared of the incisors of representative animals of groups I and II.

HISTOPHYSIOLOGY OF THE RAT INCISOR

Before presenting the findings in the experimental animals, we shall consider briefly those histophysiologic aspects of the incisor of the rat that have a particular bearing on the experimental changes analyzed in this report and that have become clarified during the progress of this study. The development of the incisor of the rat consists of four main stages: growth, calcification, eruption and attrition. For the purposes of this study we are primarily interested in the growth process, which passes successively through the proliferative, differentiative and appositional phases.

Odontogenic Epithelium. The rat incisor develops primarily from an elliptical epithelial base which is situated at the proximal end of the tooth and which proliferates throughout the life of the animal. Because of its function, this base may be called the odontogenic epithelium.¹⁴ It establishes the dentino-enamel and dentino-cemental junctions and thus the size and shape of the tooth. The labial third of the epithelial base overlaps a portion of the lateral surfaces (Fig. 22) and resembles in structure and in function the enamel organ of the human tooth. It establishes the dentino-enamel junction. Its inner layer, the inner enamel

epithelium, differentiates into ameloblasts and, in addition, regulates and activates the subjacent mesenchymal cells facing the ameloblasts to differentiate into odontoblasts. The remaining two thirds of the odontogenic epithelium resembles in structure Hertwig's epithelial sheath and outlines the lingual and the larger portion of the lateral surfaces. It establishes the dentino-cemental junction, activates the subjacent cells of the pulp to differentiate into odontoblasts, and possibly also activates the adjacent cells of the dental follicle to differentiate into cementoblasts (Text-Fig. 1). Thus there is a striking morphologic and functional difference between the labial and lingual aspects of the odontogenic epithelium. This difference is foreshadowed even in the newborn before apposition has begun.¹⁵ For convenience we shall therefore refer to the labial odontogenic epithelium and the lingual odontogenic epithelium. Similarly, we shall distinguish between the labial or enamel-covered dentin and the latero-lingual or cementum-covered dentin, and between the corresponding labial, lateral and lingual odontoblasts.



TEXT-FIGURE 1. The histodifferentiation and organization of odontogenic epithelium.

Ameloblasts and Enamel. The ameloblasts recede peripherally from the dentino-enamel junction up to the point of maximum width of enamel, when they cease their activity in enamel apposition. The ameloblasts retain their columnar shape for approxi-

mately 50 days, when they become reduced and atrophied. In the adult rat (100 days or older) this state is usually reached in the anterior third of the incisor. In the young rat of 25 days of age, on the other hand, the ameloblasts maintain in the upper incisor their columnar shape even up to the gingival crest, because they require only 25 days to reach this level.

Odontoblasts and Dentin. As soon as the peripheral cells of the dental papilla differentiate into odontoblasts, they help form the dentin matrix, recede centrally, and migrate with the eruption of the tooth toward the distal end.

The pulpal recession of a given odontoblast is proportional to the amount of dentin that is laid down. The daily rate of dentin deposition is 16μ in 24 hours.¹³ The forward movement is in proportion to the rate of eruption which is about 2 mm. a week in the upper incisor and 2.8 mm. a week in the lower incisor.

In the incisor of a rat

TABLE V
Maximum Width of Dentin at Various Ages in the Incisor of the Normal Rat and that of the Vitamin A-Deficient Rat

Age (days)	Normal controls				Vitamin A-deficient rats				Age† (days)
	Maximum width at various anatomic locations*				Maximum width at various anatomic locations†				
	Labial (μ)	Mid-lingual (μ)	Mesio-lingual (μ)	Disto-lingual (μ)	Disto-lingual (μ)	Mesio-lingual (μ)	Mid-lingual (μ)	Labial (μ)	
58	504	489	483	497	475	416	309	511	54
60	528	505	507	508	463	421	331	531	57
70	656	587	594	610	492	430	342	658	65
77	727	634	643	678	408	374	350	744	77
100	910	849	875	887	593	541	357	1363	102

* Measurements made from transverse sections at incisal edge.

† Maximum width is attained at a more proximal level.

‡ All vitamin A deficiencies were started on the 21st day of life. Complete depletion of reserve occurs approximately 26 days later.

about 100 days of age the maximum thickness of the labial dentin is found at the incisal end and is approximately 900 μ (Table V). This is associated with the fact that the life span of the odontoblasts is approximately 55 days and the daily rate of apposition is 16 μ . Normally the width of the dentin, though slightly less in the cementum-covered portion, is similar throughout the circumference of the cross section of the incisor so that the ratio between the widths at the midlabial and midlingual levels is essentially 1:1.

Very little is known regarding the mechanism of the formation and calcification of enamel and dentin. There is, however, clear evidence of an intimate interrelationship between these processes. Thus normally the following orderly sequence is observed in the development of the tooth: Proliferation of the ameloblasts, differentiation of the ameloblasts, differentiation of the odontoblasts, formation of dentin matrix, formation of enamel matrix, calcification of dentin, calcification of enamel. An arrest of one step means the omission or disturbance of the subsequent processes (Text-Fig. 1).

For a detailed discussion of other phases of the normal histophysiology of the incisor of the rat the reader is referred to Schour and Steadman,¹⁴ Addison and Appleton,¹⁵ and Schour and Massler.¹⁶

RESULTS

GENERAL GROSS FINDINGS

Group I. The vitamin A body reserves were considered to be exhausted between the 24th and 26th day following the beginning of the diet. This exhaustion was indicated by cessation in gain in body weight and by slight sensitivity to light. Xerophthalmia became evident in a mild form in 34 days. Its severity gradually increased in those groups which survived 45 days or more (Table I). The gross changes in the animals of this series were similar to those reported by Smith and Lantz.⁸

Group II. Those animals which received large doses of alfalfa in their diet together with their basal vitamin A-deficient ration showed no outward changes.

Group III. The gross effects in group III were similar to those of group I. However, on dissection, the bones of the skull

and jaws showed a reddish tint as a result of the alizarin injections.

The normal control rats showed no abnormal outward changes.

RADIOGRAPHIC FINDINGS

The normal controls showed no abnormal radiographic changes (Figs. 1 and 5).

Group I. The rats of subgroup A (Table I), which survived only 26 days, showed no abnormal radiographic changes in the incisors. The rats of subgroups B, C and D showed radiographic disturbances which progressed with the increase in survival length (Figs. 1-8).

The roentgenogram of the incisor of a normal rat presents a curved and partially hollow cylinder. The shadow is practically solid in the distal third and beginning with the middle third splits into nearly equal convex (labial) and concave (lingual) borders which taper in the proximal direction and surround the centrally located pulp (Fig. 1). In contrast, the shadow of the incisor of a rat subjected to vitamin A deficiency shows a striking distortion and gives the appearance of a sickle (Figs. 4 and 8). The convex border which represents the enamel-covered dentin is excessively wide, and at its proximal end makes a sharp bend toward the pulp. The latter is displaced toward the lingual border. The concave border, which represents the lingual dentin, is often not seen in the proximal third of the incisor and appears as a fine line only in the middle third (Figs. 4 and 8). The form of the tooth is thus distorted in a characteristic manner so that it is possible to diagnose the condition of vitamin A deficiency by an examination of the roentgenogram of the incisor of the rat (Figs. 1 to 8).

A more detailed analysis shows the following characteristic changes which permit a diagnosis of vitamin A deficiency on the basis of the roentgenogram (Figs. 2 to 4, 6 to 8):

1. The labial surface is often irregular and is foreshortened at its proximal end. Here it deflects abruptly from the normal curvature of the tooth toward the pulp.
2. The labial alveolar periosteum is widened to about three times the normal.
3. The alveolar bone at the base of the tooth tends to be more distinct and thickened.

4. Enamel hypoplasia is common. In the animals with a longer survival time the proximal end of the enamel is slightly buckled and often presents a picture which simulates that of a vesicle or hollow kernel (Figs. 2, 4, 7 and 8). This differs from the usual picture of hypoplasia in that the crest of this vesicle may extend beyond the height of the enamel surface. Histologic analysis showed that these vesicles were circumscribed areas in which enamel and dentin were defective or absent and the pulp communicated with the labial alveolar periosteum through a perforation by connective tissue (Figs. 10 and 17).
5. The labial dentin is increasingly and abnormally thickened toward the distal end.
6. The pulp is thus displaced lingually.
7. The lingual dentin is very thin in the middle third and often cannot be seen in the proximal third, indicating its absence or its lack of calcification.
8. The width of the periodontal membrane is irregular and narrow, particularly at the midregion.
9. In the upper incisor the extra-alveolar portion is longer than normal and the intra-alveolar portion is shorter than normal (Figs. 1, 4 and 8). The total length of the upper incisor is, however, not longer than normal. It appears as if a portion of the tooth which is normally intra-alveolar in position has become extruded.
10. In the lower incisor the extra-alveolar portion is shorter than normal. The intra-alveolar portion usually extends proximally only as far as the mesial level of the third molar, while normally it extends beyond the third molar toward the sigmoid notch of the ramus of the mandible.
11. The incisal relationship and attrition are abnormal. The incisal bevels show a less acute angle than normal.

Group II. In the group which received minute doses of alfalfa during the last 8 weeks of life, in addition to their vitamin A-deficient basal diet, the changes were more prominent but closely paralleled the findings in subgroup D of group I (Table II, Figs. 2 and 7). Those animals which received larger doses of replacement rations in the form of 1 per cent alfalfa in their basal diet (Table II) showed no radiographic changes.

Group III. A radiographic study was not made.

HISTOLOGIC FINDINGS

Our findings confirm in the main those of Wolbach and Howe.² The emphasis in this report will therefore be placed on those findings which supplement theirs.

Group I. Vitamin A Deficiency Without Replacement Therapy

The alterations seen in the roentgenograms were readily confirmed in the microscopic sections.

Subgroup A. Rats that Were Placed on the Experimental Diet for 24 or 26 Days Subsequent to Weaning. The newly formed lingual dentin was narrower than normal and irregular in its pulpal border. The adjacent odontoblasts were distorted. They were not columnar and had not completed their differentiation from the peripheral pulpal mesenchymal cells. The enamel epithelium was normal except for some minor hypoplastic changes in the proximal portion. The labial odontoblasts and the labial dentin were still normal. The odontogenic epithelium showed no morphologic alterations.

Subgroups B, C and D. Rats that Were Placed on the Experimental Diet for 34 to 52 Days After Weaning. The typical changes described below progressed with the increase in the survival period and varied only in degree. The disturbances were more severe in the proximal than in the distal portions (Fig. 10).

The characteristic alterations in these groups follow. Since there was a sharp difference between the changes in the enamel-covered and the cementum-covered portions of the incisor, the corresponding changes will be described separately.

Enamel-Covered Portions of Incisor

Disturbances in Formation

Enamel Epithelium. The epithelial papillae of the enamel organ showed occasional distortions but the changes were not prominent except in the hypoplastic areas. At the level of the alveolar crest, the papillary arrangement was, as a rule, still present. Sometimes the papillae proliferated and gathered in masses which gave the appearance of peninsulae of stratified squamous epithelium. In such cases the ameloblasts had become low or flattened or had lost their identity. Enamel hypoplasia was quite severe and common. Degenerating epithelial cells which in some instances had undergone calcification were often found in the hypoplastic crypts (Fig. 20). The ameloblasts showed premature atrophy only in the cases of longest experimental survival.

Enamel. The organic enamel matrix, which normally terminates at the distal end of the proximal third of the tooth (about 7.5 mm. from the odontogenic base), was found to terminate between 50 and 200 μ from the odontogenic base (Figs. 9 and 10). In the longer survivals the organic enamel matrix and the corresponding dentin were often buckled and wavy in the extreme proximal portion (Fig. 10).

This picture reminds one of that seen with long survival after hypophysectomy.¹⁷ In hypophysectomy, however, the foldings were deeper and more numerous. Often, concurrently with these violent disturbances, a large vesicular area was observed near the proximal end of the organic enamel matrix (Figs. 10 and 17). This was the vesicle described in the X-ray findings. It communicated with the pulp and was lined peripherally with normal odontoblasts. The lumen was filled with pulpal cells and an occasional island of epithelium and osteodentin.

Labial Dentin. This dentin was wider than normal (Table V), but for the most part normal in structure and in staining reaction. In the proximal region the odontoblasts as a rule showed no morphological disturbances. In the distal region they attained a cuboidal and finally a spheroidal form and resembled osteoblasts. They appeared to have lost their attachment to the dentin and to have migrated toward the center of the pulp. Here, islands of osteodentin with cellular and vascular inclusions were abundant. In some of the animals of longest survival the odontoblasts showed alterations even in the proximal region.

Disturbances in Calcification

In some animals the dentin showed to a marked degree interglobular dentin which was accompanied by an abnormal width of preentin (35 to 50 μ) at the midthird level. It was found that these animals had received a basal diet which was less fortified with vitamin D than usual. These animals showed in addition fibrotic changes in the pulp that resembled scar tissue and that were more prominent than those found in the other experimental animals (Fig. 26).

Cementum-Covered Portion of the Incisor

Disturbances in Formation

Dentin. The normal histologic characteristics of the lingual dentin were lost. In animals of shorter survival the changes were

confined chiefly to the proximal third of the tooth. After longer survival the disturbances extended through the entire length of the lingual dentin (Fig. 10). The dentin was much narrower than normal at any particular level. Thus, at the midlingual level the width was one half the normal width or even less (Figs. 2 and 14, Table V). Its pulpal surface was irregular. The matrix frequently lacked dentinal tubules and resembled osteodentin. It contained scattered cellular inclusions and occasional vascular inclusions. The latter, however, occurred consistently near the cemento-enamel junction (Fig. 12). The odontoblasts were disorganized and showed the most severe disturbances near the proximal end. They often assumed a spheroidal outline. Osteodentin was deposited either along the lingual pulpal wall or in the pulp (Fig. 13). In the more advanced cases the dentino-cemental junction was disturbed (Fig. 12). The proximal end of the lingual dentin was situated more distally than normal (Fig. 10).

Disturbances in Calcification

The normal incremental calcification rhythm was absent (Figs. 11 and 12). The predentin was lacking and the dentin when stained with hematoxylin and eosin often took only the eosin color (Fig. 16).

Pulp. The pulp was displaced lingually, confirming the roentgenographic findings (Figs. 10 to 12). The most striking change was the invasion of epithelium which arose from the lingual odontogenic epithelium. Long cords of epithelium resembling in structure the lingual odontogenic epithelium of Hertwig's sheath extended into the pulp and continued to proliferate distally (Fig. 11). When these cords were cut transversely they gave the appearance of epithelial clusters or glandular acini. The cells were usually low cuboidal but sometimes assumed a columnar shape and arranged themselves radially (Fig. 16). The distal extent of these epithelial proliferations varied with the length of the survival. In some instances definite degenerative changes were observed which simulated thymic corpuscles (Fig. 19) and approached calcification. Osteodentin at times formed about the epithelial islands. The osteodentin was bordered by mesenchymal cells which were cuboidal in structure (Fig. 18). In longer survivals cauliflower-like islands of poorly calcified tissue projected

consistently from the lingual dentin into the pulp. They reminded one of the osteoid proliferations seen in rachitic compensatory hyperplasia. Encircling these islands and often caught in the meshwork of the matrix were found hematoxylin-staining cells which were spheroidal in shape and which differed markedly from the normal columnar-shaped odontoblasts (Figs. 11 and 13). The pulpal wall was very irregular and bayed as a result of the incomplete fusion of these islands. From these bays and irregularities many vascular inclusions dipped inward and penetrated the dentin for quite a distance. These inclusions often branched within the dentin matrix (Fig. 12).

The blood supply of the pulp was prominently reduced on the lingual surface. The connective tissue of the pulp tended to lose its normal embryonic-like character and became more fibrous, especially near the epithelial cords (Fig. 26). Calcospherites were not common.

Cementum. The cementum, which normally assumes a maximum width of 3 to 4 μ , often approached a width of 10 to 15 μ . The staining reaction with hematoxylin was pale. In occasional areas of communication between the pulp and the periodontal membrane the adjacent cementum was excessively wide, as if to compensate for the lack of attachment and cementum at the points of communication. Here, in place of the cementum, fibrous condensations of connective tissue tended to bridge the gap (Fig. 12).

Periodontal Membrane. In the normal rat the outline of the periodontal membrane, both on the cementum and the alveolar side, is fairly regular. Its width varies between 240 and 275 μ in the proximal half and between 100 and 125 μ in the distal half. In vitamin A deficiency the outline of the periodontal membrane was very irregular. The width varied considerably (40 to 200 μ) and in general was narrower than normal (Figs. 9 and 10).

Labial Alveolar Periosteum. The labial alveolar periosteum was considerably widened. It contained subacute inflammatory cells, crystals and fibrinous strands similar to those seen in clotting blood (Fig. 13). With late survival the blood supply of the periosteum seemed to be reduced.

Alveolar Bone. The socket bone (surrounding proximal base) appeared to be thicker than normal. The spicules in the bone

were prominent and very long, with the cementing lines staining readily with hematoxylin. The spicules were arranged regularly and parallel with the long axis of the incisor.

Transverse Sections. In cross sections two prominent and characteristic vascular inclusions extended along the dentinal tubules and coursed from the mesial and distal cemento-enamel junctions to the pulpal wall. It is interesting to note that the greatest disturbances of the tooth were located lingual to these two outstanding vascular inclusions (Fig. 12).

Transverse sections also indicated clearly the extreme distortion of the growth pattern that is characteristic of vitamin A deficiency. The pulpal surface which normally parallels closely the outline of the dentino-enamel and dentino-cemental junctions showed no order or regularity (Fig. 12). The dentino-cemental surface was also distorted and occasionally in localized areas the pulp and periodontal membrane communicated. In these areas fibrous bands of connective tissue tended to bridge the perforation and wall off and separate the pulp from the periodontal membrane. The cementum adjacent to the perforated areas was thickened (Fig. 12).

Group II. Vitamin A Deficiency with Replacement Therapy

Subgroup A. These animals which were given total replacement with 1 per cent alfalfa concurrently with the basal diet showed no abnormal changes in the incisors (Table II).

Subgroup B. The animals in subgroup B which were given replacement with a suboptimal amount of alfalfa during the last 8 weeks, following a period of complete vitamin A deficiency, showed histopathological disturbances which were similar to those observed in subgroups B, C and D of group I. The premature atrophic changes in the enamel organ were more evident in this group than in group I, probably because of the longer survival period.

Subgroups C and D. The teeth of those animals which were given full replacement therapy for 10 to 20 days showed evidence of a resumption of normal histodifferentiation. The peripheral mesenchymal cells of the pulp, which are responsible for dentinogenesis, and the new matrix in the cementum-covered dentin, which appeared since the institution of replacement and

which is found first at the proximal base of the tooth, were normal. The changes which had occurred prior to replacement therapy were still present in the middle and distal thirds of the tooth. These areas, however, showed a greater tendency toward fibrosis of the injured or malformed tissues than in animals at deficiency levels.

In the 10-day-replacement animals a spearlike projection of dentin extended obliquely from the linguo-proximal base into the pulp. This projection of dentin was bordered on the pulpal surface by normal odontoblasts. The dentin and predentin were of normal texture and showed a normal staining reaction (Fig. 24). The width of the dentin was $110\ \mu$. Assuming that it was apposed at the normal daily rate of $16\ \mu$, it was estimated that the new dentin had been apposed for approximately 7 days before death. In other words, apposition of new dentin had begun within the third day of the replacement period.

The form of the ectopic dentin laid down during early replacement depends upon the arrangement of the epithelial islands that had invaded the pulp during the deficiency. In the case of a spearlike epithelial invagination (Fig. 25) the newly formed dentin assumed a spearlike pattern (Fig. 24). Transverse sections of the newly formed dentin showed isolated circular areas of dentin with epithelial cells in the center (Fig. 18). These cells evidently regained their capacity to cause adjacent cells to differentiate into odontoblasts but did not acquire any amelogenic capacity. In no case was enamel or enamel-like tissue found in the pulp.

The changes during the 15 to 20 day repair period were similar to those for the 10 day period but more advanced.

Group III. The Effects of Vitamin A Deficiency Studied by Means of Vital Staining with Alizarin Red S

The data for this group were obtained from ground sections which were necessary for the determination of the rate of apposition since the alizarin effects were lost during decalcification. The findings, other than those due to alizarin, were those characteristic for the corresponding degree and duration of vitamin A deficiency.

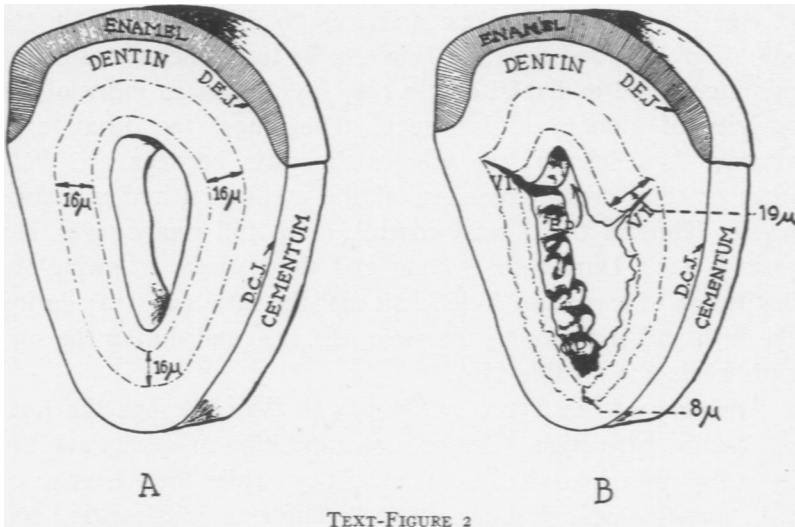
Injections of alizarin red S produced red lines which were superposed on the daily incremental rings which were being ap-

posed at the time of the injections. The rings were more intensely stained, sharp and distinct in the enamel-covered dentin, but wavy and relatively faint in the cementum-covered dentin. The course of the alizarin rings, in cross section, paralleled the outline of the pulpal wall and showed indentations with each vascular inclusion. The distance between the effects of any two injections on the labial aspect, from the cemento-enamel-junction level on the mesial to the corresponding level on the distal portion, was fairly parallel. The distance between the two lines was found to be much smaller immediately lingual to the cemento-enamel junctions, and sharply diminished toward the midlingual region of the tooth, where the distance between the two rings and the entire width of the dentin was narrowest. (Text-Fig. 2, Figs. 22 and 23).

The daily rate of apposition of both the enamel-covered and cementum-covered dentin was found, on the basis of more than 200 measurements on 12 control animals, to range between $15.25 \pm 0.51 \mu$ and $16.12 \pm 0.73 \mu$. These figures were not significantly different from the normal average daily appositional rate of 16μ found in the dentin of normal rats in previous reports.¹³ The differences in the normal daily rates in the labial and lingual portions are very slight, so that the ratio of the thickness of the midlabial and midlingual dentin is 1:1.

The disturbances in the rate of appositional growth were manifest between 9 to 19 days following institution of vitamin A deficiency, long before the cytologic and histologic changes become apparent (Table III). The daily rate of apposition of enamel-covered dentin was found to be greater than normal and increased up to 19.63μ , as the duration of vitamin A deficiency increased (Table III, Text-Fig. 2). The daily rate of apposition of cementum-covered dentin was less than normal and decreased as the survival period increased. In addition to this survival or age gradient, apposition also followed a locus gradient which decelerated uniformly from the cemento-enamel junction where it was relatively highest to the midlingual level where it was lowest (6.43μ) (Table III).

Suboptimal replacement therapy of 4 days' duration did not produce measurable changes in appositional rates. However, full replacement therapy had an immediate effect, causing the normal



TEXT-FIGURE 2

(From Schour, Smith, and Hoffman: *Proc. Soc. Exper. Biol. & Med.*, 1938, 39, 448)

A. Microprojector tracing of section shown in Figure 22 from a normal control rat which was given intraperitoneal injections of 0.5 cc. of a 2 per cent solution of alizarin red S on the 50th and 60th days of life and sacrificed on the 65th day. Note that the alizarin red S effects (dotted lines) are parallel. The outline of the pulpal wall is regular, smooth and closely parallels the outline of the dentino-enamel (D.E.J.) and dentino-cemental (D.C.J.) junctions. The rate of apposition approximates 16μ per day. $\times 71$.

B. Microprojector tracing of section shown in Figure 23 of a vitamin A-deficient rat which was put on the deficiency diet on the 21st day of life; given intraperitoneal injections of 0.5 cc. of a 2 per cent solution of alizarin red S on the 50th and 60th days and sacrificed on the 65th day. Contrast with A and note (1) the greater thickness of the enamel-covered dentin; (2) the narrowness of the cementum-covered dentin; (3) the irregular and distorted pulpal outline with the deep vascular inclusions, V.I., at the cemento-enamel junctions, C.E.J. The pulpal space, E.P., which is next to the enamel-covered dentin, is considerably narrowed in contrast to the pulpal space, C.P., which is next to the cementum-covered dentin. The alizarin red S effects are indicative of a marked gradient resulting from the increased daily rate of apposition in the enamel-covered dentin (19μ) and the decreased rate of apposition on the cementum-covered dentin (8μ). $\times 71$.

rate of dentin apposition (approximately 16μ per 24 hours) to be resumed within a period of 1 to 5 days.

By measuring the total width of dentin at various anatomic locations (Table V) and dividing it by the estimated average daily rate of apposition it was found that while the rate of apposition in rats on vitamin A deficiency differed markedly from the normal, the life span of the formative cells showed little if any differences from the normal. The differences in the total width

of the dentin were thus due primarily to the differences in the rate of growth, and the ratio between the total thicknesses of the midlingual and midlabial dentin may be used as an index of the severity of vitamin A deficiency. The longer the duration of vitamin A deficiency, the greater the ratio between the daily rates or total dentin thickness of the midlingual and midlabial levels. Thus in the normal control, or in full replacement, the ratio is 1:1. During the second and third weeks following the institution of a vitamin A-deficient diet the ratio was 3:4; during the fifth and sixth weeks the ratio was 1:2, and during the seventh week, 1:3 (Table III).

Summary of the Effect of Vitamin A Deficiency on the Rate of Dentin Apposition. The rate of apposition of dentin was selectively altered in vitamin A deficiency, while the life span of the formative cells was not affected. The rate of apposition was accelerated in the enamel-covered portion and decelerated in the cementum-covered portion, with a uniform gradient effect. The extent of the deviation from the normal was in direct proportion to the duration of the vitamin A deficiency and may be expressed in the ratio between the total dentin width or daily rates at the midlingual and midlabial levels.

The Rate of Apposition of Dentin in Vitamin A Deficiency Followed by Graded Replacements. Table IV gives the experimental history and the quantitative findings in animals which were given graded daily replacement doses of cod liver oil following the depletion of the vitamin A reserves. One Sherman unit of vitamin A fed as cod liver oil did not measurably affect the rate of growth of dentin over that of the totally deficient animals (Table III). Two to four units, inclusive, had the effect of reestablishing the labial rates to approximately normal. However, the lingual rates, though higher than in total deficiency, remained at a ratio of 3:4 to the labial rates up to the 23rd day following the institution of replacement. The five-unit replacement showed a resumption of normal rates of growth on both the labial and the lingual dentin by the tenth day following the beginning of replacement therapy.

FINDINGS IN MOLAR TEETH

Histologic Changes. The molar changes resulting from vitamin A deficiency were in direct proportion to the chronologic stage of

development of the tooth at the period when the vitamin A reserves were depleted in the animal. Since in the experimental animals the vitamin A body reserves were not exhausted until about the 45th day when the crowns and a considerable portion of the roots in the molar had completed their formation, the changes were slight in contrast to those observed by Mellanby,¹² in whose animals vitamin A deficiency was instituted in the maternal diet.

In our material the third molar, which is the last tooth to develop, showed a very irregular pulpal outline in the root portion. The odontoblasts were scattered or absent in localized areas. Projections of osteodentin were seen to grow out into pulp at various levels of the root. Epithelial islands were found near the pulp chamber and in the middle third of the root. Cysts were noted in several instances. In the first and second molars an abnormal number of epithelial pearls were present in the apical third of the roots (Fig. 27).

In animals of longer survival period (chronic deficiency) the changes were more severe. The dentin of the apical third as well as the last formed secondary dentin were irregular in their outline and amorphous in character.

Appositional Rates of Cementum and Alveolar Bone. Injections of alizarin red S produced in the first molar sharp, continuous red lines in the coronal and middle thirds, but distorted, irregular and discontinuous lines in the apical third. The irregularity of the alizarin lines in the secondary cementum similarly indicated an abnormal, amorphous formation. Table VI gives measurements of the daily rates of apposition of dentin, cementum and alveolar bone of the first molar. The rates were significantly lower than those in the molar of the normal rat.^{18, 19} The width of the periodontal membrane was narrower than normal except for the fundic portion. The rate of eruption was retarded.

DISCUSSION

Interrelationship Between the Odontogenic Epithelium and the Pulpal Mesenchyme. An analysis of the dental effects of vitamin A deficiency supported by recent studies in tissue culture²⁰ and transplant experiments²¹ has thrown valuable light on the histophysiological interrelationships and interdependencies of the various phases of tooth development. We may now reconstruct the

essential sequences of events and the interesting interplay between the remarkable organizing influence of the odontogenic epithelium and the responsive pulpal mesenchyme. This reconstruction is given in Text-Figure 1 and facilitates an understanding of the sequence of events in vitamin A deficiency.

THE EFFECTS OF VITAMIN A DEFICIENCY ON HISTODIFFERENTIATION

The characteristic dental changes point to the view that in vitamin A deficiency the primary and basic alteration lies in a disturbance of the odontogenic epithelium and specifically in the process of histodifferentiation of these cells. This interpretation is in accord with the view taken by Wolbach and Howe² and more recently by Wolbach.³ Most of the other dental changes, such as the uninhibited proliferative growth of the odontogenic epithelium and the disturbances in appositional growth, may be regarded as secondary effects which are the resultants of a disturbance in histodifferentiation. In vitamin A deficiency the effect on histodifferentiation is evidenced by the following:

TABLE VI
Measurements of Dentin, Cementum and Alveolar Bone Growth, and Rates of Eruption of First Molar for a Period of 50 to 65 Days in 10 White Rats Placed on Vitamin A Deficiency*

	Rates of apposition per 24 hours						Widths				Rates of eruption per 24 hours (μ)	
	Dentin—tooth levels			Alveolar bone		Secondary cementum (μ)	Periodontal membrane			Secondary cementum (μ)		
	Mid-crown (μ)	Cemento Enamel junction (μ)	Mid-root (μ)	Apical third (μ)	Fundus (μ)		Crest (μ)	Root level in thirds				Fundus (μ)
						Cervical (μ)		Middle (μ)	Apical (μ)			
Vitamin A deficient	4.2	3.6	1.7	1.3	4.9	7.2	52	58	104	125-130	52	14.8
Normal	5.2	4.5	2.8	2.4	7.0	11.4	102	118	131	122-129	174	19.7

* These animals were placed on vitamin A deficiency at 21 days of age, injected with alizarin red S on the 50th and 60th days and sacrificed on the 65th day of age.

1. Proliferative growth does not cease completely. Epithelial cells proliferate into the pulp. Wolbach and Howe² recognized the "acquisition of the neoplastic properties." The findings of Orten, Burn and Smith¹⁰ of odontomas in prolonged chronic vitamin A deficiency may thus be explained.
2. The morphologic plan is disturbed. The outline of the dentino-enamel and dentino-cemental junction is distorted and often dysplastic.
3. The morphologic differentiation of the lingual odontogenic epithelium is incomplete.
4. The organizing influence of this epithelium upon the subjacent mesenchyme is thus incomplete.
5. The daily rate of dentin apposition is subsequently altered (increased rate on the labial and decreased rate on the lingual), although the life span of the cells appears to remain normal.

These changes represent experimentally induced accentuations or alterations of the following phases which normally occur in and closely follow histodifferentiation:²²

1. Proliferation ceases. Histodifferentiation marks the end of the proliferative phase of cellular activity.
2. Establishment of the morphologic plan (the dentino-enamel and dentino-cemental junctions).
3. Morphologic differentiation of the cells (differentiation of cells of the inner enamel epithelium into ameloblasts).
4. Organization of adjacent mesenchymal cells by the epithelium.
5. Preparation for apposition which normally proceeds at a definite daily rate of activity during the life span of the cell.

The earliest specific effects upon the odontogenic epithelium are first recognized not in morphologic alterations but in functional behavior. The various functions of the odontogenic epithelium are not disturbed equally. The earliest effect is manifested in the linguo-lateral portion of the odontogenic epithelium which lacks the organizing principle that normally enables it to guide, stimulate and "organize" the mesenchymal cells of the pulp to differentiate into active dentin-forming cells. This capacity to organize mesenchyme is apparently much more severely disturbed in the lingual and latero-lingual portions than in the labial

portion of the odontogenic epithelium. In the latter, the capacity of the inner enamel epithelium to differentiate into ameloblasts is less severely disturbed.

Consideration of the Differences in the Reaction of the Labial and Lingual Dentin. The current knowledge of the normal embryologic and morphologic differences between the labial and lingual portions is not sufficient to explain the selective difference in the effects of vitamin A deficiency on the morphologic alterations and the rate of apposition. Wolbach and Howe² (1933) attributed to the enamel and the enamel organ a protective chemical function for the underlying labial dentin and its odontoblasts. While the decreased rate of apposition of the cementum-covered dentin is in harmony with the decreased body weight in vitamin A deficiency, the accelerated appositional rate of the enamel-covered dentin cannot be readily explained. A teleological consideration suggests that in the presence of a severe disturbance there is a compensatory thickening of the labial dentin which has to carry most of the functional stress in mastication.

Disturbances in Odontoblasts not Merely an Atrophy but a Lack of Normal Differentiation. The fact that in a given case the disturbances in the odontoblasts were more severe in the proximal than in the distal portions may be explained on the basis that the proximal tissue having been formed more recently was subject to the state of more advanced deficiency, associated with the longer survival period. It gives support to the interpretation that the odontoblasts are disturbed not because they have a lack of proper nutrition and thus atrophy, but rather because initially they are not given the opportunity to differentiate properly. The presence of normal odontoblasts in replacement therapy does not necessarily represent a recovery of atrophied odontoblasts. They rather appear to be new and young odontoblasts that have become differentiated from the mesenchymal cells under the influence of the now normally functioning odontogenic epithelium.

Disturbances in the Proliferative Growth of the Odontogenic Epithelium. Normally the proliferative phase of cellular growth becomes limited or ceases upon the assumption of histodifferentiation. It appears that in vitamin A deficiency the proliferative phase of growth of the cells of the odontogenic epithelium

is unchecked in proportion to their inability to reach the subsequent differentiative phase of growth. The lingual odontogenic epithelium shows prominent proliferation and invasion into the pulp. On the other hand, the labial odontogenic epithelium is much less disturbed in its histodifferentiation than is the lingual portion, and also shows relatively less proliferation into the pulp.

The Behavior and Fate of the Epithelial Cells in the Pulp. The continually proliferating epithelium appears to survive readily in the nutritive connective tissue of the pulp. Here it does not become a stratified squamous type of epithelium and shows no tendency to keratinization or cyst formation. On the other hand, there is a characteristic tubular arrangement which is suggestive of a glandular organ and which reminds one of the epithelial cords and rests observed normally in the periodontal membrane. Some of the proliferating epithelium, however, still possesses the chemotactic property to stimulate dentin formation. But this capacity is weak and defective so that the result is not a true dentin product but an irregular, amorphous and unorganized matrix.

In replacement therapy the organizing influence of the epithelium is regained. The adjacent mesenchymal cells become differentiated into odontoblasts and normal dentin is apposed within the pulp. The amelogenic capacity, in contrast, is not manifested even after replacement. The reason for this is probably the fact that the invading epithelium is derived chiefly if not entirely from the lingual odontogenic epithelium which even normally does not possess amelogenic capacity.

The amount of pulpal epithelium increases with the duration of the survival period. In chronic vitamin A deficiency extending over very long periods¹⁰ the epithelium is found in the adjacent tissues. Signs of degeneration of the pulpal epithelium are not frequent although sometimes areas of hyalinization or nests that resemble Hassall's corpuscles (Fig. 19) are seen. The absence of epithelial cyst formation in the pulp and its presence in the periodontal tissue is also interesting. Huggins, McCarroll and Dahlberg²¹ found that when isolated enamel epithelium was transplanted the epithelial cells did not become cystic but formed islands and cords of cells (with epithelial pearl formation).

Atrophy of Ameloblasts. The ameloblasts show less disturb-

ance than the odontoblasts. Premature atrophy of ameloblasts which, according to Wolbach and Howe,² represents the earliest response, was not observed in animals that were placed on vitamin deficiency for less than 60 days. Within this period we were unable to observe any deviation from the normal process. The rate of progress of cytomorphosis in the incisor of the adult rat is such that during normal eruption the normal atrophy and retrogression begin when the ameloblast has reached the incisal third of the tooth.²³ Premature retrogression of the ameloblasts was observed in animals that were on vitamin A deficiency for 82 days. This change, however, is not specific for vitamin A deficiency. It is readily found in vitamin B deficiency,²³ hypophysectomy,¹⁷ parathyroidectomy²⁴ and magnesium deficiency.²⁵ Atrophy may also be found in a relatively more proximal position than normal in cases of retarded eruption. Here the ameloblasts will reach their stage of atrophy within the same approximate 50-day period, but their position in the anteroposterior direction, which is determined by the eruption rate, will be relatively more proximal than normal. In accelerated eruption, such as can be produced by cutting off the exposed portion of the incisors, the atrophy of the ameloblasts is not reached and their tall columnar appearance is retained even at the gingival crest.²⁶

Vascular Inclusions. The vascular inclusions in vitamin A deficiency are characteristic and differ from those seen in parathyroidectomy.²⁴ In the latter condition the vascular inclusions recur at more or less regular intervals and penetrate the dentin in an almost straight line. The vascular inclusions in vitamin A deficiency are more numerous and branch within the matrix of the dentin.

In addition, especially deep vascular inclusions occur consistently at the cemento-enamel junction and represent a most severe alteration in dentin formation. In vitamin A deficiency the cemento-enamel junctions are critical sites where the growth gradients change suddenly from an increased daily rate above 16μ to a decreased daily rate below 16μ . The vascular inclusion appears to be a secondary effect following the premature cessation of odontoblastic growth.

To our knowledge, vascular inclusions in the human teeth at the cemento-enamel junction have not been reported. However,

it is not rare in human teeth to observe a vascular inclusion extending from the growth center to the pulpal horn. The incidence in human teeth and in the molars of the rat of pulpal inclusions below the growth centers may be explained on the basis of greater mechanical crowding of the formative cells with the result that some of them undergo atrophy and become embedded. It is possible that in the rat incisor the characteristic vascular inclusions at the cemento-enamel junction may also be due in part to a greater crowding of the odontoblasts. The cemento-enamel junction as seen in cross sections takes the form of an indentation. The change in the curvature of the dentinal tubules in this area gives further indication of the crowding of the odontoblasts.

The Effects of Replacement Therapy on the Rate of Apposition of Dentin. The findings demonstrate that dentin apposition, which was among the first processes to show manifestation of vitamin A deficiency, was also among the first to respond to replacement therapy. Thus dentin is not only a delicate recorder of alterations in calcium metabolism^{27, 28} but also acts as a growth kymograph.

The findings in Table III show a selective response of the rate of dentin apposition to different degrees of deficiency (on the basis of the survival periods). These findings thus first suggested the possible use of this reaction as a biological method of measuring vitamin A content in foods. To test this possibility, a group of 35 rats was placed on total vitamin A deficiency and then given graded doses of replacement therapy (Table IV). The results showed significant differences in response to the daily administrations of 1 and 5 units of cod liver oil but showed no significant selective response to doses of 2 to 4 units.

It is evident that any attempt to utilize total vitamin A-deficient animals for a quantitative assay method for vitamin A content in foods would not be satisfactory. However, it is possible that a careful quantitative biologic assay for vitamin A content in foods may prove successful if normal animals, which would be put on a vitamin A-deficient basal diet plus graded doses of replacement, were used. It would then be of interest to see whether graded doses produce correlative gradients in appositional growth of dentin.

SUMMARY AND CONCLUSIONS

The effect of vitamin A deficiency upon the development of the incisor and molar teeth of the white rat was studied in 199 animals, in respect to alterations seen in roentgenograms and in histologic sections. Eighty-four of these animals were given various types of replacement therapy; 95 animals were subjected to vital staining with alizarin red S in order to study the rates of apposition of dentin.

The characteristic roentgenologic changes are described.

The histophysiological findings were:

1. The primary effect of vitamin A deficiency is on the histodifferentiation of the odontogenic epithelium.
2. Histodifferentiation, particularly of the lingual odontogenic epithelium, is disturbed and incomplete, with the result that its normal *organizing influence* causing the pulpal cells to differentiate into odontoblasts is ineffective. The earliest response can be recognized in a morphologic and functional alteration of the lingual odontoblasts rather than in any morphologic change of the epithelium itself. The lingual dentin is abnormally thin.
3. Concomitant with the lack of histodifferentiation there is a continuation of the proliferative activity of the odontogenic epithelium. The result is an invasion of the pulp by epithelial cords which arise for the most part from the lingual odontogenic epithelium.
4. The morphologic outline of the tooth is distorted.
5. The rate of dentin apposition is selectively altered. The enamel-covered dentin shows an accelerated and the cementum-covered dentin a decelerated rate of apposition.
6. The pulpal epithelium has an aberrant organizing influence upon the adjacent mesenchyme which forms amorphous dentin.
7. Replacement therapy results in the resumption of the normal rate of dentin apposition and the prompt differentiation of the peripheral pulpal cells into odontoblasts.

Our findings confirm on the whole those of Wolbach and Howe,² although the duration and composition of our experimental diet was different.

The reaction in vitamin A deficiency offers ideal material for the analysis of a number of physiologic processes in tooth development.

REFERENCES

1. Wolbach, S. B., and Howe, P. R. Tissue changes following deprivation of fat-soluble A vitamin. *J. Exper. Med.*, 1925, **42**, 753-777.
2. Wolbach, S. B., and Howe, P. R. The incisor teeth of albino rats and guinea pigs in vitamin A deficiency and repair. *Am. J. Path.*, 1933, **9**, 275-293.
3. Wolbach, S. B. The pathologic changes resulting from vitamin deficiency. *J. A. M. A.*, 1937, **108**, 7-13.
4. Boyle, P. E. Manifestations of vitamin-A deficiency in a human tooth-germ. *J. Dent. Research*, 1933, **13**, 39-50.
5. Mellanby, May, and King, J. D. Diet and the nerve supply to the dental tissues. *Brit. Dent. J.*, 1934, **56**, 538-549.
6. King, J. D. Dietary deficiency, nerve lesions and the dental tissues. *J. Physiol.*, 1936, **88**, 62-77.
7. King, J. D. The development of the teeth of experimental animals. *Brit. Dent. J.*, 1937, **63**, 667.
8. Smith, M. C., and Lantz, E. M. Changes in the incisors of albino rats accompanying a deficiency of vitamin A. *J. Home Econ.*, 1933, **25**, 411-415.
9. Fridericia, L. S., and Gudjonsson, S. V. The effect of vitamin A deficiency on the rate of growth of the incisors of albino rats. *Biologiske Meddelelser*, 1936, **13**, No. 2, 1-18.
10. Orten, A. U.; Burn, C. G., and Smith, A. H. Effects of prolonged chronic vitamin A deficiency in the rat with special reference to odontomas. *Proc. Soc. Exper. Biol. & Med.*, 1937, **36**, 82-84.
11. Pohto, Mauri. Mikroskopische Untersuchungen über die Schneidezähne der Ratten bei der A-avitaminose, der Heilung derselben und der A-hypervitaminose. Medic. Chem. Lab. and Odont. Inst. of Univ. of Helsinki, 1938.

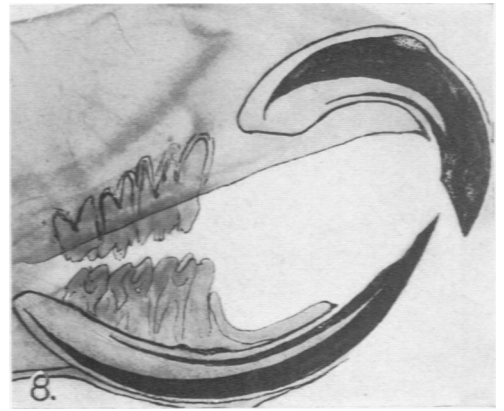
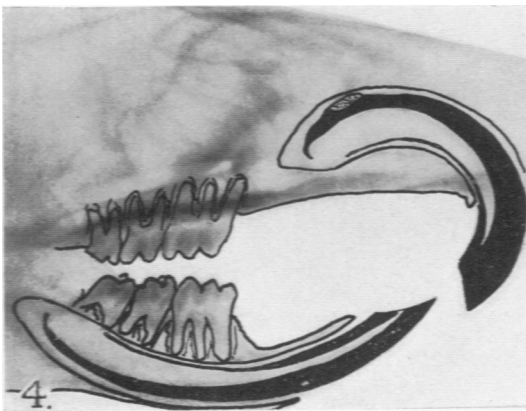
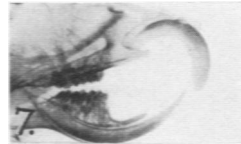
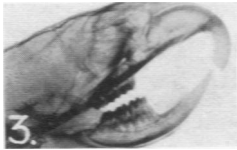
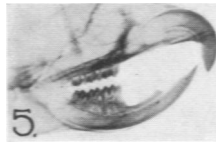
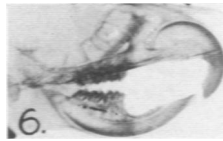
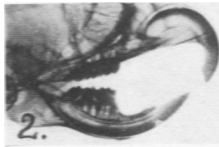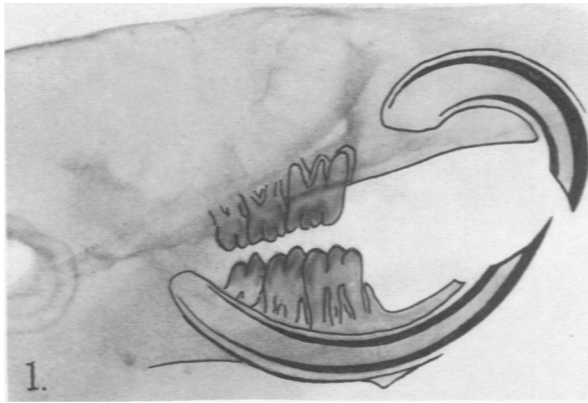
12. Mellanby, Helen. A preliminary note on defective tooth structure in young albino rats as a result of vitamin A deficiency in the maternal diet. *Brit. Dent. J.*, 1939, **67**, 187-194.
13. Schour, Isaac, and Hoffman, M. M. Studies in tooth development. II. The rate of apposition of enamel and dentin in man and other mammals. *J. Dent. Research*, 1939, **18**, 161-175.
14. Schour, Isaac, and Steadman, S. R. The growth pattern and daily rhythm of the incisor of the rat. *Anat. Rec.*, 1935, **63**, 325-333.
15. Addison, W. H. F., and Appleton, J. L., Jr. The structure and growth of the incisor teeth of the albino rat. *J. Morphol.*, 1915, **26**, 43-96.
16. Schour, Isaac, and Massler, M. In: Griffith and Farris, *The Rat in Physiologic Experimentation*. J. B. Lippincott Co., Philadelphia. (In press.)
17. Schour, Isaac, and van Dyke, H. B. Changes in the teeth following hypophysectomy. I. Changes in the incisor of the white rat. *Am. J. Anat.*, 1932, **50**, 397-433.
18. Hoffman, M. M., and Schour, Isaac. Quantitative studies in the development of the rat molar. I. The growth pattern of the primary and secondary dentin (from birth to 500 days of age). *Anat. Rec.*, 1940, **78**, 233-251.
19. Hoffman, M. M., and Schour, Isaac. Quantitative studies in the development of the rat molar. II. Alveolar bone, cementum, and eruption (from birth to 500 days). *Am. J. Orth.*, 1940, **26**, 854-874.
20. Glasstone, S. The development of tooth germs *in vitro*. *J. Anat.*, 1935-36, **70**, 260-266.
21. Huggins, C. B.; McCarroll, H. R., and Dahlberg, A. A. Transplantation of tooth germ elements and the experimental heterotopic formation of dentin and enamel. *J. Exper. Med.*, 1934, **60**, 199-210.
22. Schour, Isaac, and Massler, M. Studies in tooth development: The growth pattern of human teeth. Part I. *J. Am. Dent. A.*, 1940, **27**, 1778-1793.
23. Chase, S. W. The interrelation of maturation and the histogenesis of hypoplasia in dental enamel. *Proc. Dental Centenary Celebration*, 1940, 425-432.
24. Schour, Isaac; Chandler, S. B., and Tweedy, W. R. Changes in the teeth following parathyroidectomy. I. The effects of different periods of survival, fasting, and repeated pregnancies and lactations on the incisor of the rat. *Am. J. Path.*, 1937, **13**, 945-970.

25. Becks, Hermann, and Furuta, W. J. Effect of magnesium deficient diets on oral and dental tissues. I. Changes in the enamel epithelium. *J. Am. Dent. A.*, 1939, 26, 883-891.
26. Hoffman, M. M. Experimental alterations in the rate of eruptions of the rat incisor. Master's Thesis, 1939. Graduate School, Univ. of Ill.
27. Erdheim, J. Über die Dentinverkalkung in Nagezahn bei der Epithelkörpercentransplantation. *Frankfurt. Ztschr. f. Path.*, 1911, 7, 295-342.
28. Schour, Isaac. Calcium metabolism and teeth. *J. A. M. A.*, 1938, 110, 870-877.

DESCRIPTION OF PLATES

PLATE 100

- FIG. 1. Roentgenograms of right half of head of a normal control rat 43 days old. The calcified portions are traced in black. Compare with Figures 4 and 8. $\times 2.75$.
- FIG. 2. Roentgenogram of right half of head of an albino rat which was on a vitamin A-deficient diet for 81 days following weaning and was given 0.0075 gm. of alfalfa daily for the last 56 days. Note extreme thinning of lingual dentin; increased thickness of labial dentin; increased extra-alveolar length of the incisors; wide labial alveolar periosteum especially at basal zone; the sharp bend, pulpally, of the proximo-labial base; bleb on the labial surface of the upper incisor; dulled incisal bevels. Compare with Figures 4 and 8. Natural size.
- FIG. 3. Roentgenogram of right half of head of a rat which was on a vitamin A-deficient ration for 49 days after weaning. Note position of the bleb in proximal zone and compare with Figures 2, 7 and 8 in which the survival was 81 days. The blebs in the longer survivals are located further distally. Natural size. (See Fig. 10.)
- FIG. 4. Enlargement of roentgenogram of Figure 3 in which the calcified dental structures are traced in black. $\times 2.75$.
- FIG. 5. Roentgenogram of right half of head of a rat which was on vitamin A-deficient ration for 56 days, but was given an optimum daily replacement in the form of alfalfa. Picture of roentgenogram is normal. Compare with Figure 1, and contrast with the other figures. Natural size.
- FIG. 6. Roentgenogram of right half of head of a rat which was on a vitamin A-deficient ration for 52 days following weaning. Note characteristic changes referred to in Figure 2. Natural size.
- FIG. 7. Roentgenogram of right half of head of a rat which had a similar history as the animal in Figure 2. Compare with Figure 8. Natural size.
- FIG. 8. Enlargement of roentgenogram of Figure 7, showing semidiagrammatic sketch of the incisor teeth. Note abnormal curvature and characteristic changes referred to in Figure 2. Compare with Figure 1. $\times 2.75$.



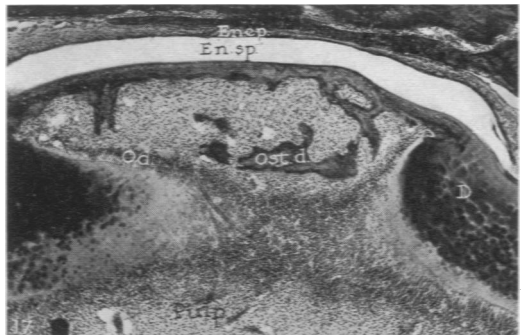
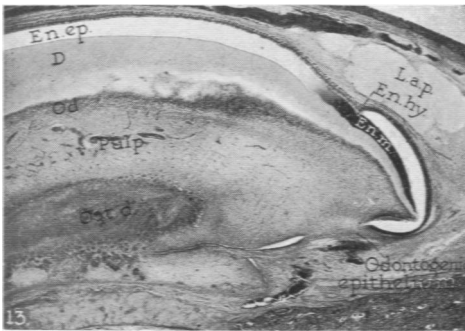
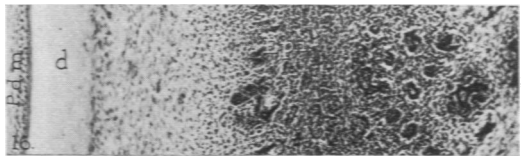
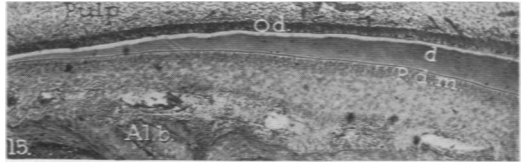
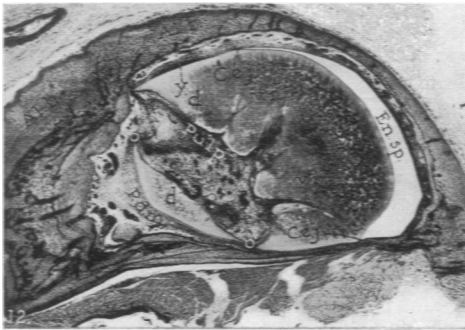
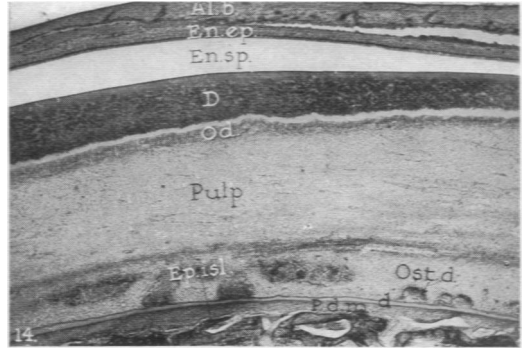
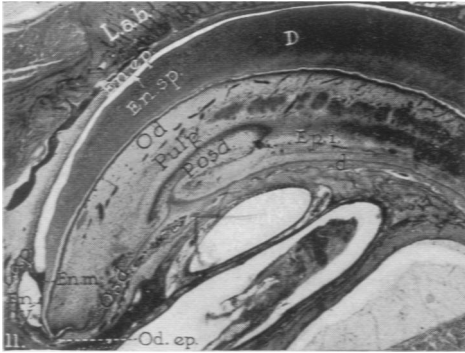
Schour, Hoffman and Smith

Incisor Teeth in Vitamin A Deficiency

PLATE 101

- FIG. 9. A midsagittal section of an upper incisor of a normal rat 65 days old. Note the extension of the pulp to the distal edge and the relative thickness of the labial, D. to the lingual, d. dentin. Alb. = alveolar bone; D = dentin; En.ep. = enamel epithelium; En.m. = organic enamel matrix; En.sp. = enamel space formerly occupied by enamel lost in decalcification; P.b. = proximal base of alveolar bone; P.d.m. = periodontal membrane. $\times 11$.
- FIG. 10. A midsagittal section of an upper incisor of an albino rat, 70 days old, which was on a vitamin A-deficient ration for 49 days after weaning. Note the relative thickness of the labial, D. to the lingual, d. dentin. En.hy. = enamel hypoplasia; En.m. = shortened organic enamel matrix; P.b. = thickened proximal bone; P.d.m. = narrowed periodontal membrane; V = vesicle on labial surface, characteristic for vitamin A deficiency. See Figures 3 and 4. $\times 11$.

- FIG. 11. A midsagittal section of the upper incisor of an albino rat which was on the vitamin A-deficient diet for 81 days after weaning and was given a suboptimum dosage of alfalfa (0.0075 gm. daily) after the vitamin A reserve was depleted (25 days following the beginning of the deficiency diet). The animal was sacrificed at the age of 102 days. En.m. = abnormally shortened organic enamel matrix; En.ep. = enamel epithelium; En.sp. = enamel space; En.hy. = enamel hypoplasia; Ep.i. = epithelial islands which arose from the odontogenic epithelium. od.ep. and proliferated in pulp; L.a.b. = labial alveolar bone; D = interglobular and thickened enamel-covered dentin; L.a.p. = abnormally widened space of proximal labial alveolar periosteum; d = narrowing and abnormal morphology in the cementum-covered dentin; Od. = odontoblasts (lost on lingual); Osd. = osteodentin on lingual wall; P.osd. = peninsula of osteodentin extending into pulp. $\times 20$.
- FIG. 12. A cross section from the proximal third of the lower incisor of a rat which had the same experimental history as the animal in Figure 11. Note the prominent distortion of the tooth and the marked thickening and interglobular nature of the enamel-covered dentin. D. O and O' indicate absence of cementum-covered dentin. Here the pulp communicates with the periodontal membrane. P.d.m., which is abnormally wide at the lingual aspect; v.i. = deep vascular inclusion which runs to the cemento-enamel junction. C.e.j.; Al.b. = alveolar bone; En.sp. = enamel space; d = atypical cementum-covered dentin; y = hypercementosis. $\times 45$.
- FIG. 13. A longitudinal section of the upper incisor of a rat which was on the vitamin A-deficient diet for 52 days after weaning. The animal was sacrificed at the age of 73 days. Note the thickened enamel-covered dentin, D. The organic enamel matrix, En.m., is shorter than normal and shows a definite area of hypoplasia, En.hy. At this level there is no dentin on the lingual to correspond with the formed labial dentin. Instead, a large accumulation of osteodentin, Ost.d., can be seen. (En.ep. = enamel epithelium which is still active in middle third of tooth; En.m. = abnormally shortened enamel matrix; L.a.p. = widened proximal area of labial alveolar periosteum containing large tissue spaces; Od. = odontoblasts of the labial pulpal wall.) No odontoblasts are seen on the lingual wall. $\times 30$.
- FIG. 14. A midsagittal section of the middle third of the upper incisor of a rat which was on a vitamin A-deficient diet for 50 days after weaning. Note interglobular and widened enamel-covered dentin. D; narrowed lingual dentin, d. (contrast with FIG. 15); islands of osteodentin, Ost.d., near lingual wall; epithelial islands, Ep.isl., in pulp near lingual wall; Od., labial odontoblasts. There is no evidence of lingual odontoblasts. Al.b. = alveolar bone; En.ep. = enamel epithelium; En.sp. = enamel space; P.d.m. = abnormally narrowed periodontal membrane for this level. $\times 45$. Contrast with Figure 15.
- FIG. 15. A midsagittal section of the upper incisor of a normal rat illustrating normal cementum-covered dentin, d., and normal periodontal width, P.d.m. Note presence of odontoblasts which are lacking or deficient on the lingual wall in vitamin A deficiency. Contrast these conditions with Figure 14. $\times 90$.
- FIG. 16. A midsagittal section of the upper incisor of a rat with similar history as that used for Figure 12, showing high power field of the proliferating epithelial islands, Ep.i., in the pulp similar to those seen in Figure 11. Abnormal lingual dentin, d. P.d.m. = periodontal membrane. $\times 170$.
- FIG. 17. A midsagittal section of the upper incisor of a rat which was on the vitamin A-deficient diet for 49 days after weaning, illustrating the histology of the vesicle seen in the roentgenograms (Figs. 3 and 4). En.ep. = enamel epithelium; En.sp. = enamel space; D. = interglobular enamel-covered dentin; Od. = odontoblasts; Ost. = osteodentin within vesicle and adjacent to enamel space. $\times 85$.

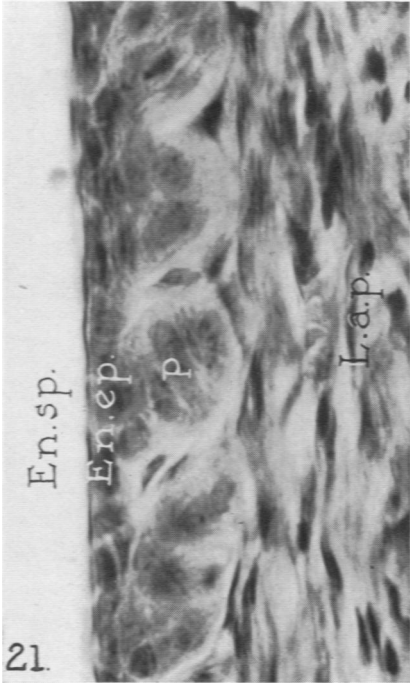
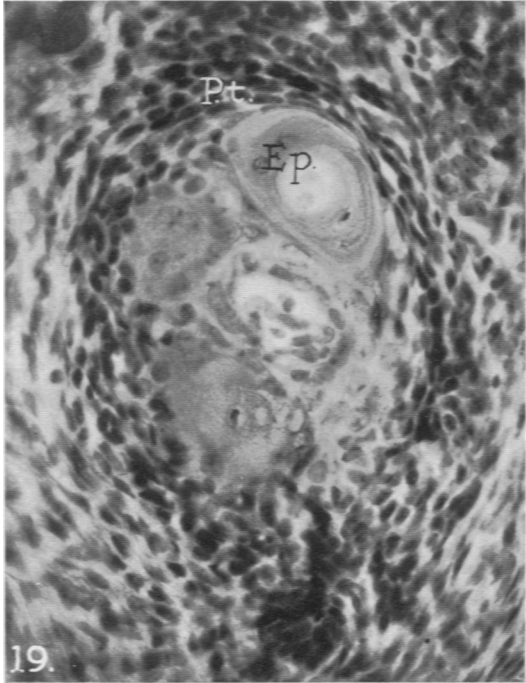
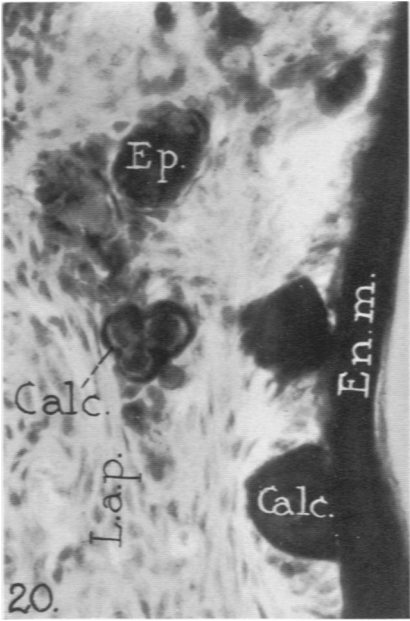
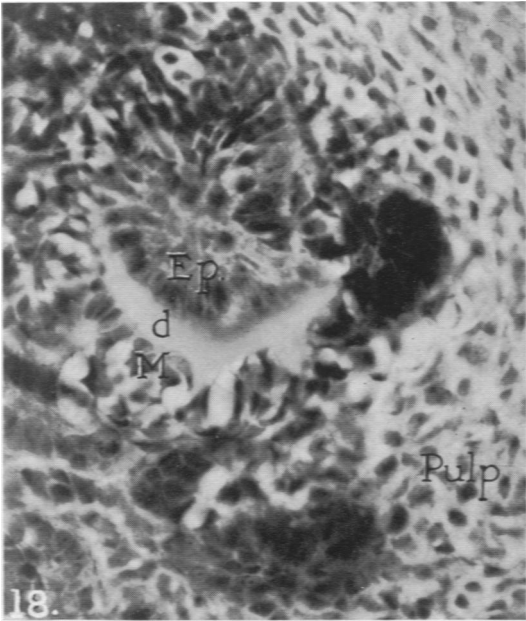


Schour, Hoffman and Smith

Incisor Teeth in Vitamin A Deficiency

PLATE 103

- FIG. 18. A high power field of a section of the distal portion of the pulp of the upper incisor of the same albino rat as seen in Figure 13. A layer of atypical dentin, d. has been deposited by the pulpal cells, under stimulation from the epithelial cells, Ep., which arose from the odontogenic epithelium and proliferated in the pulp. M. = mesenchymal cells which have become only partially differentiated into odontoblasts. $\times 420$.
- FIG. 19. A high power field of the distal portion of the pulp of the upper incisor of a rat which had a similar history as that of Figure 18, showing the dense pulpal tissue. P.t. Some of the epithelial cells, Ep., have degenerated and resemble a Hassall's corpuscle. $\times 420$.
- FIG. 20. Enamel hypoplasia in a field from the proximal area of the upper incisor of a rat which was on vitamin A-deficient ration for 38 days after weaning. Note degenerating epithelium, Ep., which is giving rise to calcified masses or calcospherites. Calc. En.m. = organic enamel matrix; L.a.p. = connective tissue in labial alveolar periosteum. $\times 420$.
- FIG. 21. The distal third of the enamel organ of the upper incisor of a rat which was on vitamin A-deficient ration for 81 days after weaning, illustrating severe atrophic changes in the enamel epithelium. En.ep. The enamel papillae, P., show at this level greater atrophy than is normally present. En.sp. = space formerly occupied by enamel which was lost in the decalcification process; L.a.p. = connective tissue of the labial alveolar periosteum. $\times 700$.

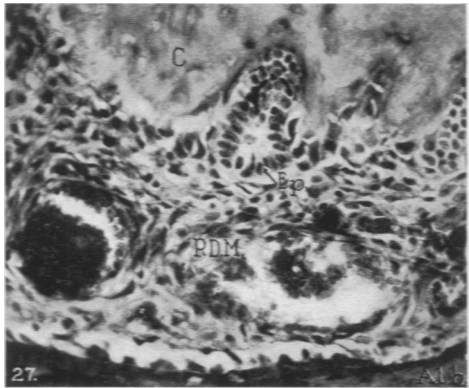
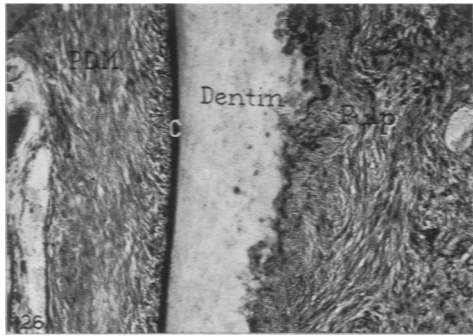
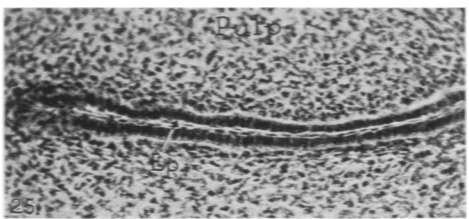
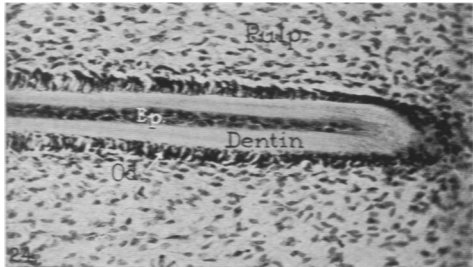
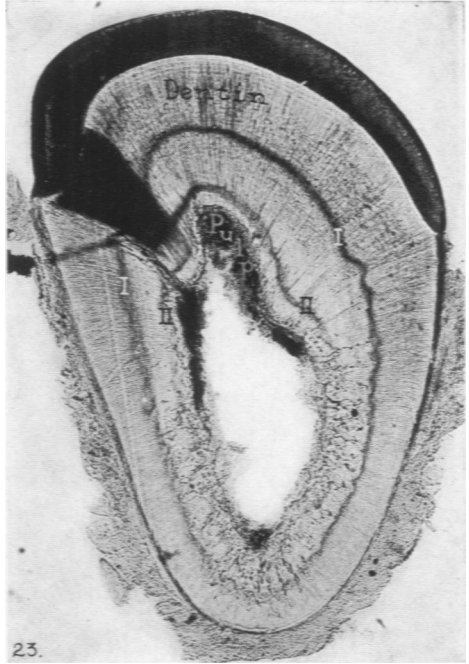
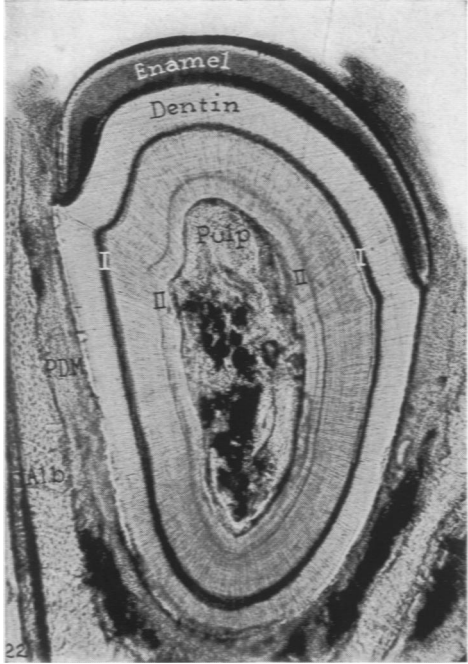


Schour, Hoffman and Smith

Incisor Teeth in Vitamin A Deficiency

PLATE 104

- FIG. 22. A transverse ground section of the lower incisor taken at the level of the mental foramen in a normal albino rat, 65 days old, which was given injections of alizarin red S on the 50th (I) and 60th (II) days. Note injection effects (I and II) and the uniform distance between them. Al.b. = alveolar bone; P.D.M. = periodontal membrane. See Text-Figure 2, A. $\times 90$.
- FIG. 23. A transverse ground section of the lower incisor taken at the level of the mental foramen in an albino rat, 65 days old, which was on a vitamin A-deficient diet since the 21st day of age. Injections of alizarin red S were given on the 50th (I) and 60th (II) days. Note injection effects (I and II) and the unequal distance between them. See Text-Figure 2, B. $\times 90$.
- FIG. 24. A midsagittal decalcified section of the upper incisor of an albino rat, 60 days old, showing the linguo-pulpal area in the proximal region. This rat was on vitamin A deficiency from the 21st to the 50th day and placed on vitamin A therapy from the 50th to the 60th day of age. Note the center core of epithelium, Ep., which arose during deficiency as a pulpal invagination of the lingual odontogenic epithelium, and the dentin, which was deposited as a result of the differentiation of the approximating mesenchymal cells (odontoblasts), Od., following the institution of vitamin A therapy. Replacement effects were noted as early as the third day after the beginning of therapy. Contrast with Figure 25. $\times 280$.
- FIG. 25. A midsagittal decalcified section of the upper incisor of an albino rat, 60 days old, showing a field similar to that in Figure 24. This rat was on a vitamin A-deficient diet since its 21st day. Note the epithelial cord, Ep., which arose as a pulpal invagination of the lingual odontogenic epithelium, and the absence of mesenchymal differentiation and dentin apposition. $\times 280$.
- FIG. 26. The lingual middle third of a midsagittal section of the upper incisor of an albino rat, 65 days old, which was on a vitamin A deficient diet since its 21st day. Note the abnormal fibrotic texture of the pulp which adjoins the amorphous lingual dentin. C. = cementum; P.D.M. = periodontal membrane. $\times 178$.
- FIG. 27. The apex of the distal root of the lower first molar of an albino rat, 65 days old, which was on a vitamin A-deficient diet since its 21st day. Note the abnormally prominent epithelial pearl, Ep., which is being engulfed by the amorphous secondary cementum, C. P.D.M. = periodontal membrane; Al.b. = fundic alveolar bone. $\times 480$.



Schour, Hoffman and Smith

Incisor Teeth in Vitamin A Deficiency