



A SYNDROME CHARACTERIZED BY ECTODERMAL DYSPLASIA, POLYDACTYLY, CHONDRO-DYSPLASIA AND CONGENITAL MORBUS CORDIS

REPORT OF THREE CASES

BY

RICHARD W. B. ELLIS, M.D., F.R.C.P. and S. VAN CREVELD, M.D.

(From the Children's Department, Guy's Hospital, London, and the Paediatric Department, University of Amsterdam)

The association of the four following congenital abnormalities—ectodermal dysplasia affecting the hair, teeth and nails ; polydactyly ; chondro-dysplasia ; and congenital morbus cordis—has been observed in two children in whom the clinical picture is so strikingly similar as to justify its description as a separate syndrome. Although many atypical cases of achondroplasia and chondro-osteodystrophy have been recorded with associated abnormalities, and there is an extensive literature relating to congenital ectodermal dysplasia, we have found no detailed description of the syndrome previously published. McIntosh (1933), however, in the tenth edition of ' Diseases of Infancy and Childhood ' includes illustrations and some clinical particulars of a child who is clearly an incomplete example of the same syndrome. He has kindly furnished a full report on this case, and it is included as case 3 in the present series ; thanks are also due to Dr. S. Levine, Professor of Pediatrics at the New York Hospital, for permission to include subsequent observations made on the same patient.

In Cockayne's (1933) comprehensive review of the literature relating to inherited abnormalities of the skin, there are no examples showing more than two features of the tetrad. One such is that described by Windle (1891). In this instance, a female of a German family from Eisenbach, in whom deficiency of teeth with conical incisors was inherited as a simple dominant, married a man suffering from polydactyly, and had two children with both polydactyly and dental abnormalities. This family is of particular interest in showing how a possible linkage of characters may arise, but this will necessarily be of extreme rarity, since it will require the two characters to be in corresponding chromosomes, the linkage then only occurring by means of a cross-over. (In the present cases neither the dental defect nor the polydactyly was inherited as a mendelian dominant.) Pires de Lima (1923) also records dominant polydactyly and premature eruption of teeth (as seen in case 1 of the present series) occurring separately in several members of a family and united in one member.

There are numerous examples of polydactyly of recessive type being

associated with abnormalities of the skin and its appendages, such as ringed hair and melanoderma described by Meachen (Cockayne, 1933), albinism (Pearson et al., 1913), epidermolysis (Callomon, 1910), and dominant ichthyosis (Hofmann, 1927), but none of these show any close similarity to the present syndrome with the possible exception of Betz's case (Cockayne, 1933), in which recessive polydactyly was associated not only with an ectodermal defect (aplasia cutis congenita) but also with atresia of the pulmonary artery.

Although a variety of congenital abnormalities including hypospadias, spina bifida, defective auricles, cleft palate (Emerson, 1909), herniae, and congenital cystic disease of the kidneys (Porak and Durante, 1905), have been described in association with achondroplasia, there does not appear to be any recognized tendency for achondroplasiacs to suffer from either congenital morbus cordis, ectodermal defect, or polydactyly. The only suggestive case of which an account has been found is that of a 'polydactylous monster' found drowned in the river at Amsterdam and dissected by the anatomist Ruysch. The skeleton was described by Kerckring in his *Spicilegium Anatomicum* in 1670, and it is clear from the description and illustration of both the long bones and skull that the condition was in fact achondroplasia. The infant bore a total of thirty-one digits ('inaudita hactenus foecunditate'), seven on each hand, eight on the right foot and nine on the left. Unfortunately there is no record of either the nails or the heart, but it is tempting to speculate whether it was entirely coincidence that this child should have been described in the same city as that in which case 2 of the present series was observed many generations later.

The following three cases are therefore presented as examples of a hitherto unclassified syndrome. The name 'chondro-ectodermal dysplasia' is tentatively suggested, as emphasizing the association of two outstanding features. (The term 'chondro-dysplasia' rather than 'achondroplasia' has been used in describing the osseous condition in these patients, since it differs in certain respects, which will be discussed below, from the classical picture of achondroplasia.)

Case reports

Case 1. M. C., a girl, aged 20 months, was referred to Guy's Hospital on May 17, 1939, by Dr. H. R. Kidner. She is thought to have been four or more weeks premature, weighing $4\frac{3}{4}$ lb. (2.200 kgm.) at birth. Pregnancy and delivery were uneventful. At birth, it was noted that the nails were defective and that two upper incisor teeth were present. (One of these latter subsequently fell out spontaneously and the other was removed.) The infant sucked, breathed, and cried normally, and had not appeared cyanotic or dyspnoeic at any time. She was fed on dried milk, with the addition of orange juice and cod-liver oil after the age of three months. She had been well throughout infancy, and had gained weight steadily.

The mother and father are both healthy, but are first cousins, the father's mother and mother's mother being sisters. It was only possible to examine the mother, who is normal, but she is well acquainted with a large proportion of her own and her husband's nearer relatives, and knows of no other example of micromelia or ectodermal defect in either family.

Physical examination (May 17, 1939.) A well-nourished infant, weighing 24 lb. (11.64 kgm.). The mentality is normal for age. She is of good colour, with no cyanosis or clubbing. Height 74.5 cm.

ECTODERMAL DEFECTS.—The nails of both hands and feet show an extreme

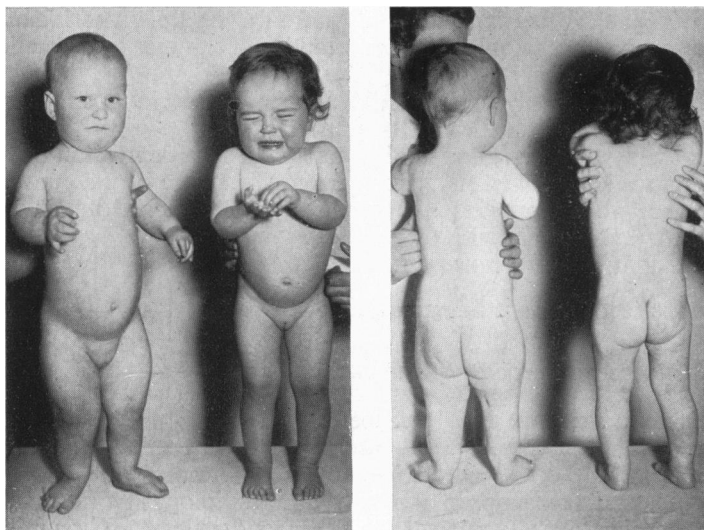


FIG. 1 (a and b).—Front and back view of case 1, aged 20 months, with normal control of same age, showing short limbs, long trunk and paucity of hair.

degree of dysplasia, and are altogether absent from the thumb, index, and sixth fingers of both hands.

The hair is fine, fair, and sparse. (Microscopical examination of a hair showed no abnormality.) The scalp is dry and scaly, but the skin elsewhere appears normal.

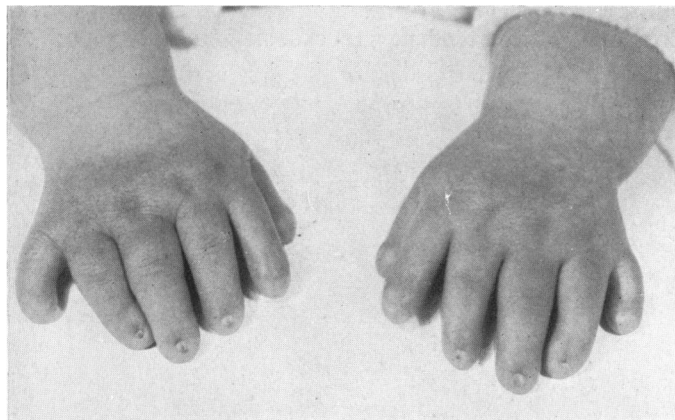


FIG. 2.—Hands (case 1). Polydactyly and dystrophy of nails.

REPORT ON DENTAL CONDITION (Mr. R. E. Rix) :

UPPER JAW. The only teeth erupted are the first and second deciduous molars. They are slightly more conical in shape than are commonly seen. The usual bulbous sides of the teeth are flattened from the cervical margin to the occlusion surface. The cusps and ridges are accentuated and the fissures deep, thus giving a crenated appearance to the occlusal surface.

There are localized swellings of the gum in the region of the deciduous central incisors suggestive of their imminent eruption.

There is no sulcus between the gum pad and the lip. The labial mucous membrane is attached along the ridge in the deciduous incisor and canine regions.

LOWER JAW. The only teeth erupted are the first deciduous molars. They present the same characteristics as the upper molars.

The general level of the gum pad is interrupted by a depression on each side of the deciduous lateral incisor region. From the centre of the gum pad lying between these two depressions a fraenum labii is attached which bifurcates as it passes forward to fuse with the lip.

RADIOLOGICAL EXAMINATION OF JAWS :

Deciduous teeth present but unerupted	$\begin{array}{cc cc} C & A & A & C \\ E & C & C & E \end{array}$
---------------------------------------	---

Permanent teeth in process of calcification	$\begin{array}{c c} 6 & 6 \\ \hline 6 & 6 \end{array}$
---	--

There is no evidence of any other teeth.

In spite of the absence of teeth the jaws are not small, and the antero-posterior relationship of the jaws to each other is normal.

The **SKULL** and face appear clinically and radiologically normal, and do not show the characters typically seen in achondroplasia. Circumference of head 44.7 cm. Intermental measure (over vertex) 30.7 cm. External occipital protuberance to nasion (over vertex) 29 cm.

LIMBS AND TRUNK. The limbs are extremely short in relation to the long trunk, and have the proportions of those of an achondroplasiac, the proximal segments being more reduced than the distal. Owing to the great length of the trunk, however, there is no dwarfing. There are six digits on each hand and five on each foot. The sixth finger (which is situated on the ulnar side of the hand) is well formed and is partially but not completely mobile, interfering to a slight extent with manual dexterity.

RADIOLOGICAL EXAMINATION of the long bones show the short, thick bones of achondroplasia with a tendency to exostosis in the region of the hips.

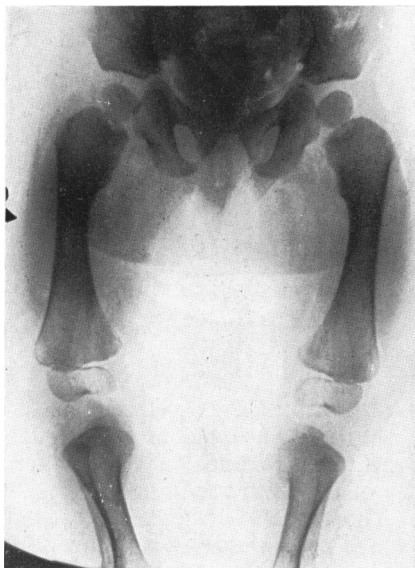

FIG. 3.—Femora (case 1), resembling achondroplasia, with tendency to exostosis in region of hips.

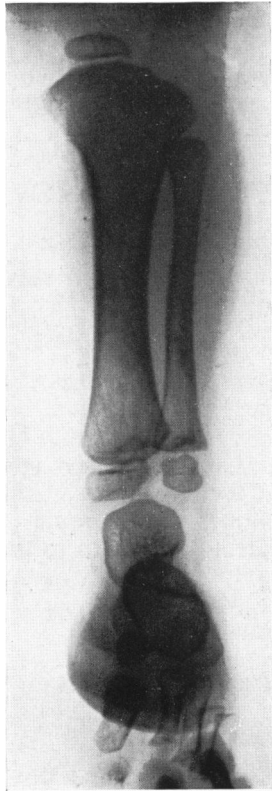


FIG. 4.—Left leg (case 1).

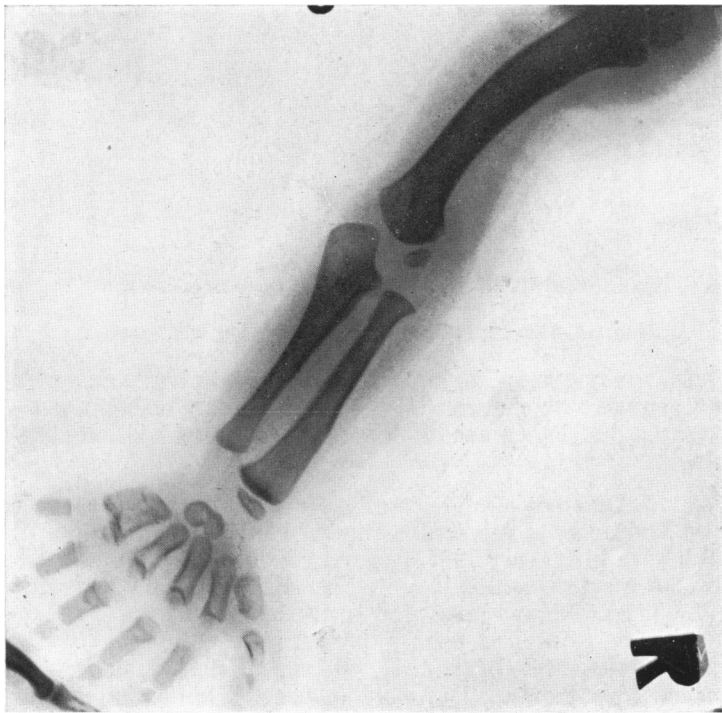


FIG. 5.—Right arm (case 1).

The terminal phalanges of the fingers are poorly developed. A sixth metacarpal bone is present on the left, and there is partial division of the fifth metacarpal on the right. The spine shows no abnormality.

MEASUREMENTS :

Trunk length (seventh cervical to tip of coccyx) 37 cm. (i.e. half the total height).

Circumference of chest (nipple level) 46.5 cm.

Upper extremity :

Acromion to olecranon process 11.5 cm.

Acromion to radial styloid 18.5 cm.

Lower extremity :

Anterior superior iliac spine to mid-patella 16.5 cm.

Anterior superior iliac spine to internal malleolus 28 cm.

Circumference of abdomen (umbilical level) 48.5 cm.

HEART. The area of cardiac dullness extends from one fingerbreadth to the right of the sternum, to the nipple line in the fifth left intercostal space. The rate is 100 to 120 per minute. A loud rough systolic murmur is best heard over the third and fourth intercostal spaces to the left of the sternum, but is conducted over the precordium.

ORTHODIAGRAM : heart : M.T.D. 8.2 cm. Chest : 12.2 cm.

ELECTROCARDIOGRAM normal.

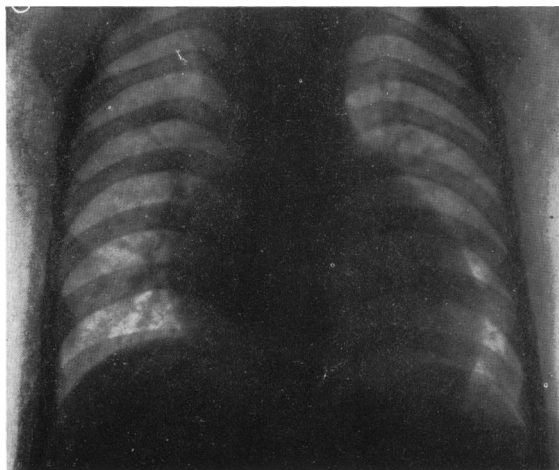


FIG. 6.—Skiagram of heart (case 1), showing enlargement.

OTHER EXAMINATIONS. The lungs, abdomen, central nervous system, special senses and genitalia were normal. The Wassermann reaction was negative. The urine showed a slight trace of albumin in one specimen only but no other abnormality.

Case 2. M. D., a boy aged 4 years 3 months, was admitted to the Paediatric Clinic of the University of Amsterdam on April 5, 1939. He was born spontaneously at full term in January 1935, weighing 5½ lb. (2.5 kgm.). A second child, also a boy, born subsequently, is quite normal. Pregnancy and delivery were uneventful. The child was breast-fed for three months, but growth was impaired from birth. The first teeth appeared after the age of two years, and were of peculiar shape (see below). In 1937 a sixth digit was removed from the ulnar side of both hands. The child contracted whooping cough in 1937

and measles in 1938. The appetite had always been poor, and there had been frequent abdominal complaints.

There is no consanguinity of the parents. The mother suffers from bronchial asthma. No deformities are known on either side the family.

Physical examination (April and June 1939).—The patient is a well-nourished boy weighing 12 kgm. The mentality is normal for age, the child having a great capacity for clowning. The colour is good and there is no cyanosis or clubbing.

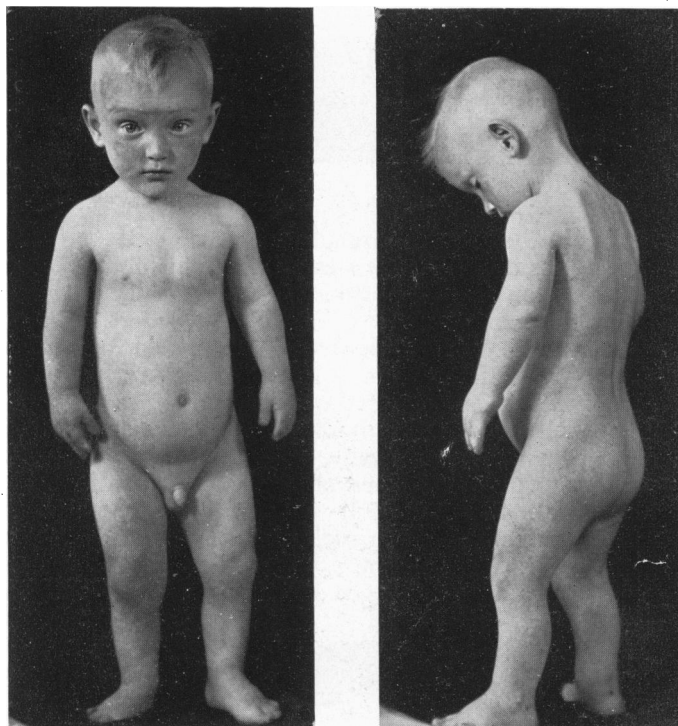


FIG. 7 (a and b).—Front and side view of case 2, showing short limbs, long trunk, facies and paucity of hair.

There is abundant perspiration on the head. Numerous small lymph-glands are palpable in the neck and groins.

ECTODERMAL DEFECTS. The nails of all the fingers and toes are small and dystrophic, resembling small scales. The hair of the head is fair, fine and scanty, especially in the temporal and occipital regions, and the eyebrows are scanty. Microscopical examination of a hair showed no abnormality. The scalp is somewhat dry, but the skin elsewhere is normal with the exception of some eczematous patches on the face.

REPORT ON DENTAL CONDITION (Mr. W. L. van Andel) :

UPPER JAW. On either side, two hypoplastic deciduous molars are present. In addition, there are two conical-shaped canines. One central deciduous incisor has erupted, and one central deciduous incisor is unerupted. The lateral incisors are absent.

LOWER JAW. On either side, two hypoplastic deciduous molars have erupted. There are in addition two conical-shaped canines and two central deciduous incisors, the latter being bell-shaped. The lateral incisors are absent.

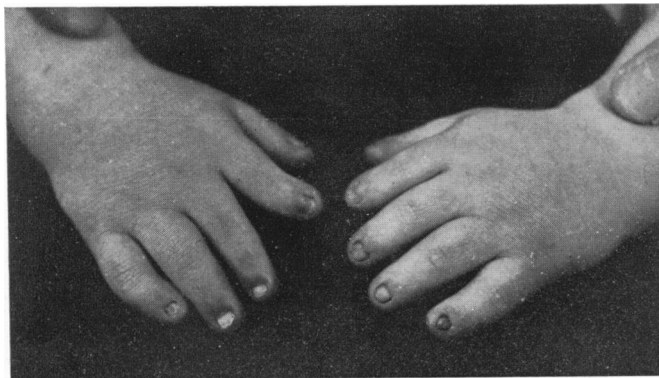

FIG. 8.—Hands (case 2). Dystrophy of nails.

The impression is obtained that the frenulum is as wide as the four deciduous incisors ; on lifting the upper lip, the labial mucous membrane is seen passing over without interruption into the mucous membrane of the palate, the central incisor perforating this membrane.

RADIOLOGICAL EXAMINATION OF JAWS. No permanent incisors are visible in either jaw, but only the first molars ; in the lower jaw, only the first pre-molars and possibly a permanent cuspid can be seen.

SKULL. The skull is clinically and radiologically somewhat enlarged, and the forehead prominent. Clinically, the fontanelle appears closed. The face is small with a pointed chin, and slightly sunken nasal bridge. Radiologically, the anterior fontanelle is still visible and the frontal suture patent. The sella turcica is normal. Changes typical of achondroplasia are absent.

Circumference of head 49·2 cm. ; intermeatal measure (over vertex) 32 cm. ; external occipital protuberance to nasion (over vertex) 31·5 cm.

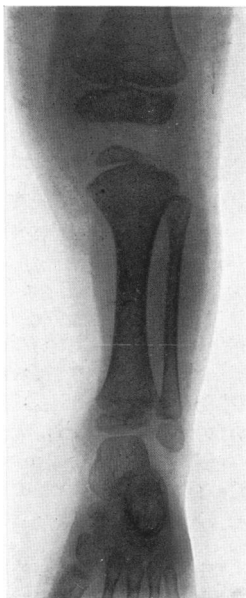


FIG. 9.—Left leg (case 2). Short thick tibia ; lines of arrested growth at lower end of femur.

LIMBS AND TRUNK. The limbs are short in relation to the long trunk, and the proportions are those of an achondroplasiac. On the ulnar sides of both hands a scar shows the site of removal of a sixth digit. There are five digits on both feet. The hands are small and plump, with short and shapeless fingers. The index fingers deviate to the radial side, and the little fingers are slightly curved. The lower limbs are also short and plump, with short digits.

RADIOLOGICAL EXAMINATION. The long bones are short and thick, but do not otherwise show the typical structure of achondroplastic bones. Several lines of arrested growth are visible. The proximal tibial epiphysis on either side is poorly developed. The metatarsal and metacarpal bones are

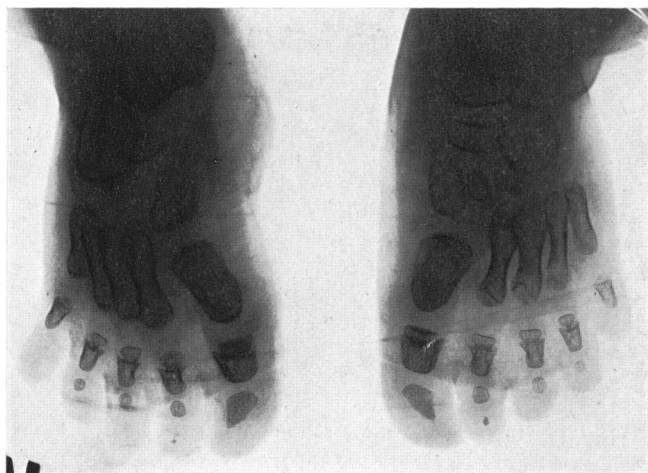

FIG. 10.—Feet (case 2). Thick metatarsals. Dystrophy of terminal phalanges.

more typical of achondroplasia. The terminal phalanges of the fingers and toes are poorly developed. The bones of the wrist show partial synostosis; their number corresponds to the age of the patient. A sixth metacarpal is visible on the left.

MEASUREMENTS :

Height 81 cm. Trunk length (seventh cervical vertebra to tip of coccyx) 40.5 cm. (i.e. half of the total length). Circumference of chest (nipple level) 48 cm. Circumference of abdomen (umbilical level) 48.2 cm.

Upper extremity :

Acromion to olecranon process (left and right) 14 cm.
Acromion to radial styloid 18 cm.

Lower extremity :

Anterior superior iliac spine to mid-patella (left and right) 19.5 cm.
Anterior superior iliac spine to internal malleolus 31 cm.

HEART. The area of cardiac dullness extends from one fingerbreadth to the right of the sternum to the left nipple line in the fifth intercostal space. A loud rough systolic murmur is best heard over the apex. The heart rate is 80 to 110 per minute.

ORTHODIAGRAM. Heart : M.T.D. 10 cm. Chest : 14.6 cm.

ELECTROCARDIOGRAM normal.

LIVER AND SPLEEN palpable $1\frac{1}{2}$ fingerbreadths below the costal margin.

GENITALIA. Penis small ; testicles undescended.

OTHER EXAMINATIONS. Lungs, central nervous system, and special senses normal. The Wassermann reaction was negative, the tuberculin test negative and the urine and stools normal.

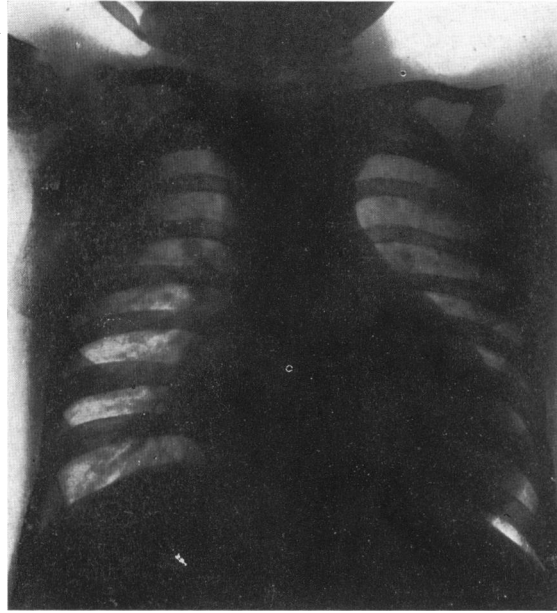


FIG. 11.—Skiagram of heart (case 2), showing enlargement.

BLOOD. No anaemia. Differential blood count normal. Inorganic phosphate 4.4 mgm. per cent. Phosphatase 6.8 units. Serum calcium 11 mgm. per cent.

Case 3. Bernice P. was admitted to Babies Hospital, New York, January 19, 1932, at the age of 4 years 4 months. The complaints were : retarded physical growth, supernumerary digits, and squint.

The father was 29 years of age, living and well, and the mother 27 years of age, living and well. (It was later learned that the father and mother are first cousins.) Both parents are of Jewish stock. There had been two pregnancies : 1, the patient, and 2, a miscarriage, induced, at three months' gestation.

There was no family history of tuberculosis, syphilis, or of any congenital malformations.

The patient was born at term by difficult breech delivery ; weight at birth, 7 lb. 2 oz. (3.235 kgm.). No difficulty in resuscitation.

She was breast fed for three months. Cereals and soup were begun at five months. The rest of her feeding history is not remarkable. Her appetite was never very good, but she had no digestive disturbances and showed no food idiosyncrasies.

She sat up alone at five months ; walked at nine months. First tooth erupted at fourteen months, an upper incisor. For the first year and a half she is said to have gained weight steadily, but at that time it was noticed that her height was small for her age. At two years of age she was 28 inches (71.2 cm.) tall. (She did not attend school until seven years of age, but since that time she has always kept up well with her coevals and has constantly been in the 'honour group.')

No illnesses of note.

Physical examination (January 1932, aged 4 years 4 months). Weight, 13.60 kgm. Height, 84 cm. (33 ins.). Head to umbilicus, 41 cm. ; umbilicus to sole, 45 cm. Circumference of head, 47.5 cm. A well-nourished but short

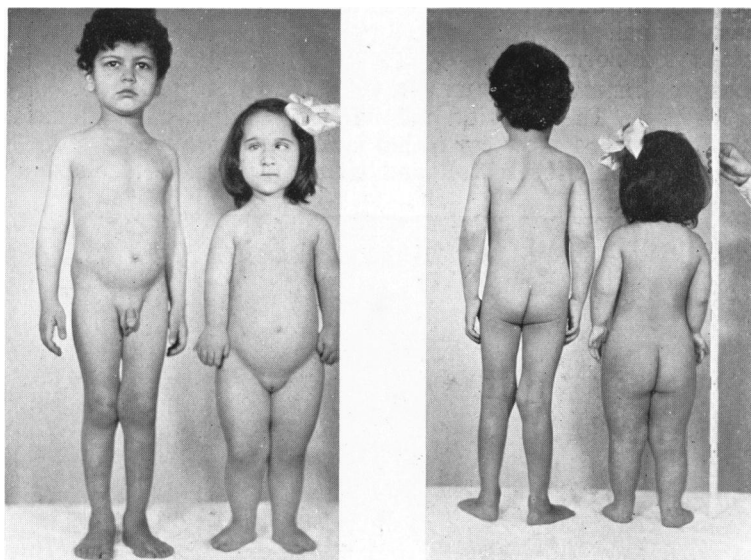


FIG. 12 (a and b).—Front and back view of case 3, aged 4 years 4 months, with normal control of same age. Note short limbs, trunk of normal length, facies.

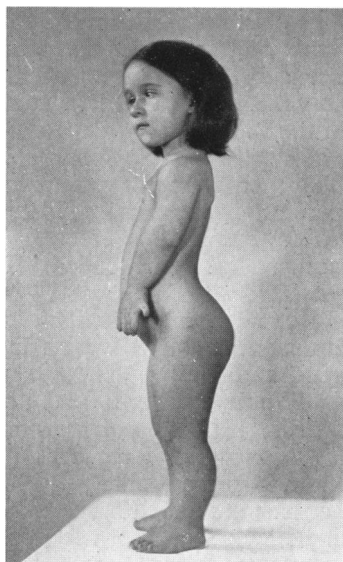


FIG. 13.—Lateral view of case 3 showing prominent frontal region and lordosis.

and abnormally developed girl. All four extremities relatively short. Six fingers on each hand.

Skin normal. Nails hypoplastic (see below).

No lymph-gland enlargement.

Prominent frontal and parietal bossing of skull, symmetrical.

Fixation with right eye. Internal squint of left eye of about 20 degrees of arc. Spasm of left inferior oblique muscle. Conjunctivae, sclerae, pupils and eyegrounds normal.

Ears and nose normal.

REPORT BY DENTAL CONSULTANT. 'This child's teeth are very rudimentary in form. The superior and inferior deciduous lateral incisors are missing. Dental films show congenital lack of the developing tooth buds of the superior and inferior central and lateral incisors. Calcification of the

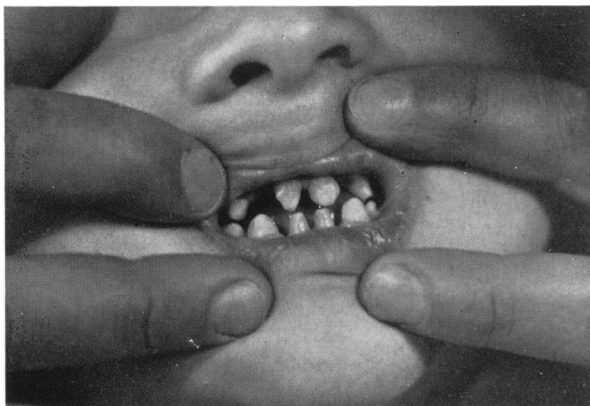


FIG. 14.—Teeth of case 3 (aged $4\frac{1}{2}$ years), showing location and conical incisors.

deciduous teeth seems to be complete. Resorption does not appear to have begun. The developing buds of the rest of the permanent teeth are present and development would seem to be normal for a child of this age. There is some dental caries present. Both right and left lateral roentgenograms show evidence of calcification in the submaxillary glands.'

No other abnormality of buccal cavity or pharynx. Tonsils present.

Thyroid isthmus palpable; enlargement questionable.

Thorax poorly developed but symmetrical. No evidence of abnormality in heart or lungs. Blood pressure 105/85.

Abdomen soft, tympanitic, slightly distended. Liver edge just palpable below costal margin. Spleen not palpable.

Conspicuous shortening of all four extremities. The extra digit on each hand is adjacent to the little finger; it is incapable of independent motion. The hands and feet are broad and stubby. There is marked lumbar lordosis.

BLOOD. Haemoglobin, 14.3 grammes per 100 c.c.; red blood cells, 5.0 million per c.mm.; white blood cells, 13,300; polymorphonuclears, 74 per cent.; lymphocytes, 24 per cent.; monocytes, 1 per cent.; eosinophils, 1 per cent. Red cells and platelets appear to be normal.

URINE. Alkaline; specific gravity, 1020; albumin, 0; reduction 0; acetone, 0; occasional single leukocyte and a few epithelial cells.

TUBERCULIN TEST (Mantoux, 0.1 mgm.), negative.

BLOOD CHEMISTRY. Blood non-protein nitrogen, 35 mgm. per 100 c.c.; sugar, 95 mgm. per 100 c.c. Serum calcium, 11.6 mgm. per 100 c.c.; inorganic phosphate (as phosphorus), 4.1 mgm. per 100 c.c.; cholesterol, 211 mgm. per 100 c.c. Plasma albumin, 5.1 grammes per 100 c.c.; fibrinogen, 0.26 grammes

per 100 c.c.; carbon dioxide combining power, 36.4 volumes per 100 c.c. Kahn test negative.

BASAL METABOLIC RATE, 41.6 calories per sq.m. per hour. Total calories, 23.7 per hour. On account of the abnormal proportions in this child's height measurements, the basal metabolism was calculated by two different standards. Using height and weight according to Dubois, the result is 21.7 per cent. below normal. However, when weight alone is used (Dryer), the result is +0.7 per cent. In this situation, the latter figure is probably the more reliable, since the patient presumably has an unusual surface area as regards her chronological age.

RADIOLOGICAL REPORT. There are extensive multiple abnormalities in the long bones. The metacarpals and phalanges are short. Both hands show six fingers, with fusion of the fifth and sixth metacarpals on the left. The carpal centres are small on both sides and consist of one unusually large bone in the centre of the carpus, with three small centres visible on the left, and one on the right.

The radii and ulnae are short and of bizarre shape. The cortices are not thickened, and bear a practically normal relationship to the medullary cavities. Bone trabeculation does not appear to be definitely altered. The distal ends of the bones have a ragged limiting boundary, but provisional zones of calcifica-

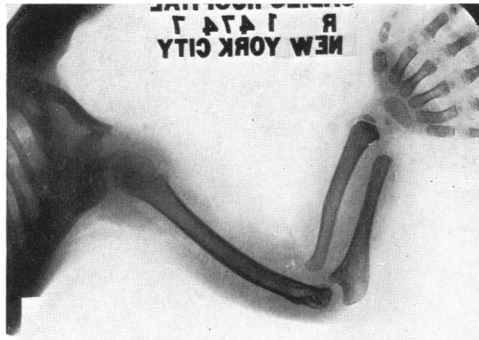


FIG. 15.—Right arm of case 3 (aged $4\frac{1}{3}$ years). Short radius and ulna of abnormal shape; shallow bowing of humerus.

tion are intact and in no way resemble rickets. The humeri show shallow bowing, with convexity directed posteriorly.

In the feet the proximal phalanges are visible in all five toes on each side. In the fifth toe on each side, only the proximal phalanx shows calcification. The same is true of the fourth toe on the right, but a small centre of ossification can be seen on the left representing the middle phalanx. In the third toe the middle phalanx shows some calcification on each side. In the second toe three phalanges can be seen on each side, though the distal phalanx is rudimentary. (The terminal phalanges of the fingers are also small throughout, and the distal phalanges of the fifth and sixth digits show no calcification.) The metatarsals are short and thick. Centres for the semilunar, scaphoid and cuboid bones are visible in each tarsus.

The tibiae and fibulae are both short and heavy. The distal ossification centre of the fibula is unusually large on each side, and there is marked roughening and irregular condensation of bone at the distal ends of both tibiae and in the distal tibial centre of ossification. There is apparently a fusion of the ends of the shaft of the fibulae with the distal ossification centre of both tibiae. At the proximal end of the left tibia, a small exostosis projects downward and medially from the medial aspect of the metaphysis. The proximal ends of the

tibiae are greatly widened and show a small, irregular centre of ossification situated medially. In contrast to this, the distal ends of the femora are approximately normal in the antero-posterior view, with very little deformity of the centres of ossification. There is moderate coxa vara with no dislocation of the hips.

In the lateral view of the skull the clinoid processes are large. The bones seem to be of normal density. There is a moderate increase in the digital markings, but not enough to warrant an interpretation of increased intracranial pressure. At the same time, the suture lines are unusually small for a child of four years, the coronal suture being practically closed. Following the horizontal ramus of the mandible, from the angle through two-thirds of the posterior portion, there is a strip of abnormal density parallel to the bone and situated about 1 mm. away in the soft tissues. This strip consists of multiple small shadows of calcium density, clustered in three main groups. The interpretation of these shadows is uncertain.

This is an interesting combination of bone and cartilage dystrophy, which, while resembling achondroplasia, has many additional changes which hardly

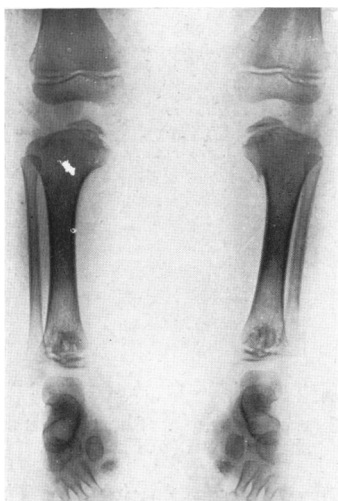


FIG. 16.—Legs (case 3). Short and heavy tibiae, with irregular condensation of bone at distal ends ; exostosis at proximal end of left tibia.

admit such a simple classification. The changes all represent abnormalities of bone growth, with tendency to shortening of all the long bones, and perhaps fusion of the carpal bones, together with spur formation on the left tibia and marked irregularity of the growing ends of the bones throughout. The changes at the distal ends of the tibiae are interesting and difficult to interpret. A descriptive classification of these changes would include chondrodystrophy, polydactylism, and solitary exostosis of the left tibia.

NOTE BY DR. A. A. WEECH (February 3, 1932). ' This child presents a combination of two forms of congenital anomaly, the first affecting skeletal growth and producing the approximate picture of chondrodystrophy, the other affecting several of the tissues of ectodermal origin. The child, though four years old, measures only 33 inches in height, and the central point of the body lies about one-half inch above the navel. The hands hanging at the sides extend approximately as far as the greater trochanter of the femur. The shortening

of the extremities is especially noticeable in the fingers. In addition to the supernumerary digits, which have already been described, one finds an apparent ankylosis of the index fingers of both hands. The nails of both fingers and toes are extraordinarily hypoplastic. They show in general a tendency to convexity in form and are more thickened at the tip than at the base. Several of the nails

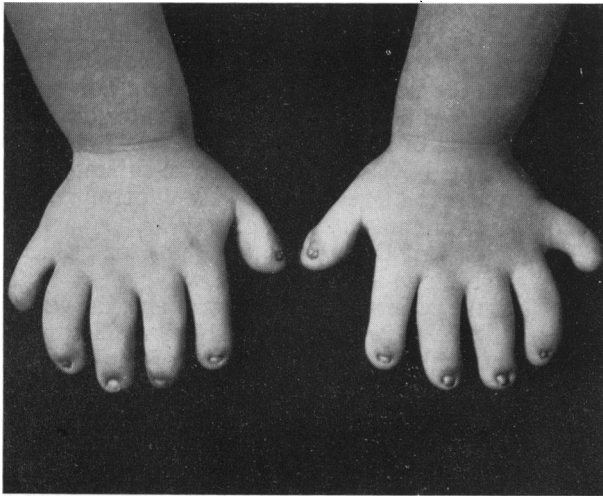


FIG. 17.—Hands (case 3). Polydactyly and dystrophy of nails.

stand out at an angle from the nail bed. The supernumerary digits show no nails. Examination of the other ectodermal tissues discloses a rather fine head of hair with apparently normal eyebrows and eyelashes ; these parts cannot be considered abnormal. The teeth disclose cone-shaped upper and lower

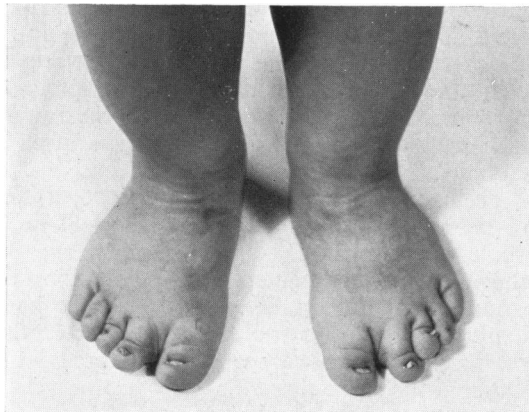

FIG. 18.—Feet (case 3). Dystrophy of nails.

central incisors with absence of the lateral incisors, but aside from caries the teeth in the rear of the mouth are normal. There is no noticeable abnormality of the skin itself ; that is, there are no papular lesions on the face, the vermilion border of the lips is well defined, the sweat and sebaceous glands are both apparently functioning normally, and both mammary glands are normally

developed. There is nothing abnormal in the configuration of the ears, and the conformation of the head is not unusual. The patient presents a left internal strabismus.

'The patient's ectodermal anomalies are interesting in that no hereditary factors have been uncovered, and in the nature of the abnormalities of the teeth and nails. The type of teeth are those which occur in the anidrotic type of ectodermal dysplasia, a group of cases in which the hereditary transmission is sex-linked in character, whereas the nails are similar to those which occur in so-called combined dystrophy of the hair and nails (Clouston, 1929 ; Jacobsen, 1928), a group in which the transmission is mendelian non-sex-linked in type. The presence of factors from both groups tends to show the impossibility of a sharp clinical differentiation of such anomalies into rigid categories.'

PROGRESS. The parents have steadily refused to submit the child to operative correction of strabismus or resection of the supernumerary digits. The tonsils and adenoids were removed in October 1937. Apart from measles at five years of age, complicated by otitis media (left), and chickenpox at nine years of age, there have been no important illnesses.

In May, 1938, when the patient was 10½ years of age, she was studied at New York Hospital. Weight, 23.4 kgm. Height, 114 cm. Circumference of head, 52 cm. She was of normal intelligence. Most of the physical findings are comparable to those given above, but there are additional details in regard to the extremities. Both arms and legs are much shorter than normal and have a contracted, truncated appearance. The soft tissues appear abnormally bulky for the length of the members. Motility of the muscle groups is impaired. Both hands are broad and pudgy, with stubby fingers. There is only one functioning phalangeal joint in each finger, except in the index fingers, both of which are stiff. The supernumerary fingers appear to function as well as the others. In the feet, which are also stubby, the first and third toes on each side override the second toe, which appears shorter than the rest. The nails on all fingers and toes are distorted, tiny brownish structures which project slightly upward. The laboratory tests reported are essentially normal, except that the basal metabolic rate is calculated to be +35 per cent. X-ray examination shows six metacarpals on the right, and an attempt to form six on the left, but the two lateral ones are fused. There is also fusion of the capitate and hamate on both sides. Two of the metacarpals on the right show double epiphyses. The femora are shortened and thickened, with irregular epiphyseal lines and spur formation. No permanent tooth buds are seen in the lower incisor region. The fourth and fifth metatarsal bones on the left are fused proximally, and similar but less marked fusion is seen on the right.

In view of the occurrence of congenital morbus cordis in cases 1 and 2, the patient was re-examined at the New York Hospital in November 1939, at the age of twelve years one month.

The **HEART** showed no enlargement to percussion, the rhythm was regular, and the sounds of good quality. In the supine position only there was a faint systolic murmur, heard just to the left of the sternum. The murmur was inconstant and disappeared entirely when the patient sat up. The blood-pressure was 120/90, and the pulse rate 98.

RADIOLOGICAL REPORT. Film and fluoroscopy of the chest show a symmetrical thorax. The diaphragms are smooth and the angles are clear. The heart is normal in size. There is some fullness of the pulmonary conus. There are no abnormalities of the bony cage.

Analysis of the syndrome

Osseous system. In all three cases, the long bones are short and thick, the radiological changes corresponding more or less closely to the classical

picture of achondroplasia, though the additional changes seen in case 3 make some qualification of the diagnosis necessary. As is usual in this condition, the proximal segments of the limbs tend to be more reduced in length than the distal. Case 1 shows a tendency to exostosis in the region of the hips. Case 3 shows spur formation on the left tibia and irregular condensation at the distal ends of both tibiae, with fusion of the shaft of the fibula with the distal centre of ossification of the tibia on both sides, whilst the distal ends of the radii and ulnae have a ragged limiting boundary. Parsons (1936) has expressed the

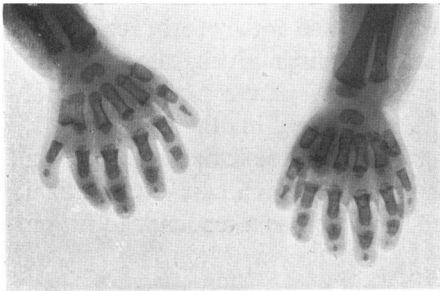


FIG. 19.—Skiagram of hands (case 1). Sixth metacarpal present on right ; fifth left metacarpal partially divided. Dystrophy of terminal phalanges.

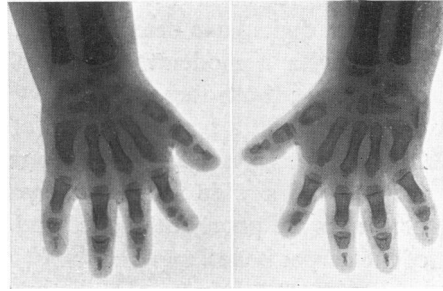


FIG. 20.—Skiagram of hands (case 2). Partial synostosis of carpal bones. Sixth metacarpal present on left. Dystrophy of terminal phalanges.

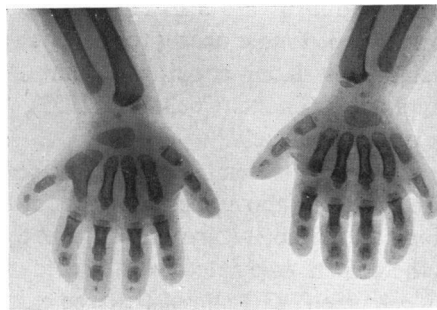


FIG. 21.—Skiagram of hands (case 3, aged 4 years 4 months). Single large carpal bone in centre of carpus. Sixth metacarpal present in right ; fusion of fifth and sixth metacarpals on left. Dystrophy of terminal phalanges.

view that typical achondroplasia should be regarded as only one manifestation of chondrodystrophy (or more correctly, chondrodysplasia) of which hereditary deforming chondrodystrophy, Ollier's disease, and Morquio's disease are further examples. Instances such as case 3, which show features of more than one type of chondrodystrophy, would appear to substantiate this view.

The skull in case 1 does not show the brachycephaly and hydrocephalic appearance commonly (but not invariably) seen in achondroplasia due to premature fusion of the base, and the radiological appearance and facies are normal. Cases 2 and 3, however, do show some enlargement of the skull and

depression of the nasal bridge, although the skiagrams are not altogether typical of achondroplasia.

The trunk in the first two cases appears exceptionally long, not only in relation to the short legs but (in case 1) in comparison with a normal control. In both cases, there is little or no lordosis and, at their present ages, practically no dwarfing. The length of the trunk (seventh cervical vertebra to tip of coccyx) is in both instances almost exactly half the standing height. In case 3, on the other hand, both lordosis and dwarfing are well marked.

Polydactyly. This is remarkably similar in each case, a sixth digit being present on the ulnar side of each hand and the feet being unaffected. In case 2 the extra digits have been removed, but in cases 1 and 3 they form functional fingers with a moderate degree of movement, though giving rise to some clumsiness; both these cases show radiologically a separate sixth metacarpal on the left and a partial division of the fifth metacarpal on the right (fig. 19, 20 and 21). In case 2 there is the remainder of a separate sixth metacarpal on the left and a wide fifth metacarpal on the right. In each case the terminal phalanges are poorly developed and calcified, and there is a tendency to fusion of the carpal bones.

Ectodermal defects. In all three cases the nails and teeth were affected, and in cases 1 and 2 the hair was abnormally sparse, although showing no microscopic abnormality. The sweat glands appeared to function normally in each case, nor was there chronic rhinitis as is frequently seen in the anidrotic type of ectodermal dysplasia.

Weech (above), who examined case 3 in 1932, considered that the abnormality of the teeth corresponded most nearly to that seen in the anidrotic type of ectodermal dysplasia. This latter condition occurs either as a sex-linked recessive, or an incomplete dominant (Cockayne, 1933), 'sparing the females or affecting them as a rule less severely.'

The defect of the nails closely resembles that described by Clouston (1929) and others, Weech's observation (above) being borne out by the fact that cases 1 and 2 show in addition hypotrichosis ('hypotrichosis et dystrophia unguium'), although in none are the defects associated with pigmentation or any evidence of hypothyroidism. Cockayne (1933) shows that the existing figures bear out the assumption that hypotrichosis et dystrophia unguium is a dominant, whilst the great majority of the recorded cases have been of French or French-Canadian origin, if not actually related. In none of the present series, however, is there evidence of French descent or dominance.

The three cases here described appear therefore to belong to a type of ectodermal dysplasia which does not correspond exactly with any one recognized form, either clinically or genetically (see below).

Congenital morbus cordis. In cases 1 and 2, the orthodiagram shows gross cardiac enlargement, particularly to the right, the M.T.D. being 8.2 cm. (chest 12.2 cm.) and 10 cm. (chest 14.6 cm.) respectively. A loud systolic murmur was present in both cases, best heard in case 1 in the third and fourth intercostal space to the left of the sternum, and in case 2 at the apex. In neither case was cyanosis or clubbing observed, and there was no dyspnoea. A patency

of the septum ventriculorum might account for the signs in both cases, though it would be unusual to get such degree of cardiac enlargement without any cardiac symptoms.

The third case was investigated both clinically and radiologically and no evidence of congenital morbus cordis found, if the transient and positional systolic murmur heard to the left of the sternum be disregarded.

Physical development. Two out of the three children were small at birth, case 1 weighing $4\frac{3}{4}$ lb. (2.2 kgm.) and case 2 weighing $5\frac{1}{2}$ lb. (2.5 kgm.). Case 3 was of normal weight (7 lb. 3 oz.). Apart from their deformities, all three children are now robust and in good general health.

Race. The three children are of English, Dutch and Jewish American extraction respectively.

Discussion

The most significant points in the family histories of these three cases are that in two out of three instances the parents were first cousins, and in no case were any of the features of the syndrome known to have existed in relatives. The latter observation is the more likely to be reliable since, with the exception of congenital morbus cordis, any one of the components (ectodermal defects, chondro-dysplasia, and polydactyly) would almost certainly have excited comment in the family. It is therefore strongly suggested that the syndrome had been inherited as a recessive gene or genes and had appeared, apparently *de novo*, on the union of two individuals both carrying the recessive character.

It is impossible at present, in view of the small number of cases observed, to do more than speculate as to the mechanism of appearance of such a bizarre collection of abnormalities. As indicated above, the ectodermal dysplasia must be considered as distinct both from the anidrotic type which occurs as a sex-linked recessive or incomplete dominant, and from hypotrichosis et dystrophia unguium, which occurs as a dominant. Polydactyly may occur as either dominant or recessive, but true achondroplasia is probably an incomplete dominant (Cockayne, 1933), a further reason for describing the osseous condition in these cases not as classical achondroplasia but as 'chondro-dysplasia.' Possibly a linkage of recessive genes such as that postulated in relation to the Laurence-Moon-Biedl syndrome (Cockayne et al., 1935; Sorsby et al., 1939) would account both for the variety of the structures involved and for the extreme rarity of the syndrome. If such were the case, one might expect to find one or more components of the syndrome appearing separately in collaterals.

In addition to the Laurence-Moon-Biedl syndrome, and those examples of ectodermal defect linked with abnormalities of the mesoderm mentioned above, conditions which excite comparison are arachnodactyly, in which the bony abnormalities are frequently associated with congenital morbus cordis and dislocation of the lens; cleido-cranial dysostosis, with associated defects of the teeth (La Chapelle, 1919); and gargoylism (Ellis et al., 1936), in which condition chondro-osteo-dystrophy is linked with a number of more or less

constant abnormalities including congenital opacities of the cornea and hepatosplenomegaly. Each of these conditions therefore shows a combination of mesodermal and ectodermal defects, and it remains to be proved whether they are in fact the result of a linkage of genes, or whether a single gene may be responsible for the whole picture.

Summary

1. A syndrome consisting of ectodermal dysplasia affecting the hair, nails, and teeth ; polydactyly ; chondro-dysplasia, and congenital morbus cordis, is described. No detailed account of this syndrome has been found in the literature.

2. The full syndrome was observed in two children, and a third child showed all the components except hypotrichosis and congenital morbus cordis.

3. Two of the patients were females and one male. They were of English, Dutch and Jewish American race respectively.

4. In two out of the three cases, the parents were first cousins. No similar condition had been observed amongst relatives. The condition is held to be a mendelian recessive, without sex-linkage.

Thanks are due to Dr. Rustin McIntosh and Dr. S. Levine ; and to Dr. E. A. Cockayne for his helpful criticism.

REFERENCES

- Callomon (1910). *Arch. Derm. Syph., Wien*, **104**, 292.
 Clouston, H. R. (1929). *Canad. med. Ass. J.*, **21**, 18.
 Cockayne, E. A. (1933). *Inherited Abnormalities of the Skin and its Appendages*, London.
 —, Krestin, D., and Sorsby, E. (1935). *Quart. J. Med.*, **4**, 93.
 Ellis, R. W. B., Sheldon, W. P., and Capon, N. B. (1936). *Ibid.*, **5**, 119.
 Emerson, C. P. (1909). *Achondroplasia*, Osler and Macrae's *Modern Medicine*, London, **6**, 683.
 Hofmann, E. (1927). *Zbl. Haut-u. GeschlKr.*, **23**, 619.
 Jacobsen, A. W. (1928). *J. Amer. med. Ass.*, **90**, 686.
 Kerckring, T. (1670). *Spicilegium Anatomicum*, Amsterdam.
 La Chapelle, E. H. (1918). Thesis, Leyden.
 McIntosh, R. (1933). Holt and Howland, *Diseases of Infancy and Childhood*, tenth ed., New York, 362.
 Parsons, L. G. (1936). *Achondroplasia*, *Brit. Encyclopaedia of Med. Practice*, **1**, 135. London.
 Pearson, K., Nettleship, E., and Usher, C. H. (1913). *Drapers Co. Res. Mem.*, Biometric Ser. **9**, *Albinism in Man*, London.
 Pires de Lima, J. A. (1923). *Bull. Soc. Anthropol. Paris*, **4**, 71.
 Porak, C., and Durante, G. (1905). *Nouvelle Iconographie de la Salpêtrière*, **17**, 481.
 Sorsby, A., Avery, H., and Cockayne, E. A. (1939). *Quart. J. Med.*, **8**, 51.
 Weech, A. A. (1929). *Amer. J. Dis. Child.*, **37**, 766.
 Windle, B. C. A. (1891). *J. Linn. Soc. (Zool.)*, **23**, 473.