

# CONGENITAL TOXOPLASMOSIS : A REPORT OF TWO CASES

BY

JAMES H. HUTCHISON, O.B.E., M.D., F.R.C.P., F.R.F.P.S.G.

(From the Department of Child Health, University of Glasgow, and the Royal Hospital for Sick Children, Glasgow)

Human infection by the protozoan *Toxoplasma hominis* has been reported quite frequently in the Americas and in continental Europe. The first case proved to be due to toxoplasma was reported in the United States by Wolf, Cowen, and Paige in 1939. In retrospect four earlier cases have been accepted, although the true nature of the infection was not correctly recognized at the time of reporting (Janku, 1923; Torres, 1927; Richter, 1936; and Wolf and Cowen, 1937). The genus toxoplasma has been identified in many animals and birds (Callahan, Russell, and Smith, 1946), and as it has been found in a dog in Great Britain (Heeley, 1948), there is every possibility that the disease in humans may be less uncommon than the rarity of published cases in British medical literature suggests. In fact, it seems reasonable to suppose that an increased awareness of the existence of the disease would lead to its more frequent recognition. The first undoubted case to be described in the United Kingdom was by Jacoby and Sagorin in 1948.

After this paper had been prepared for press four more British cases have been described, two by Farquhar and Turner, (1949), one by Ridley, (1949), and one by A. B. Nutt on July 1st, 1949, at the Annual Meeting of the B.M.A. at Harrogate. Parsons (1946) and Baar (1946) described neonatal cases which resembled toxoplasmosis but as parasites were not found at necropsy a different etiology seems likely. Before reporting two additional British cases it may be helpful to review briefly the main pathological and clinical features.

## Pathology

The parasite is a crescentic organism pointed at one end and rounded at the other, 4-7 $\mu$  long and 2-4 $\mu$  in width. In Wright and Giemsa stains the cytoplasm appears pale blue, and a dark red to purple chromatin mass is visible near the centre or at the rounded end. In tissues the parasites occur singly, or in aggregations, 'pseudocysts,' which may be surrounded by a cyst-wall.

In both the congenital and acquired human infections the parasites may invade many of the

body organs, for example, the brain, for which they appear to have a predilection, the cranial nerves, lungs, myocardium, liver, kidneys, bladder, skeletal muscle, testicles, adrenals, ovaries, and thyroid. The histological changes resulting in these tissues have been described by Sabin (1941), Paige, Cowen, and Wolf (1942), Zuelzer (1944), and Callahan, Russell and Smith (1946) among others. Zuelzer (1944) summarizes the pathological changes as follows:

'They consisted of acute vasculitis, foci of necrosis of tissue followed by inflammatory cell infiltrations, and productive granulomatous changes. . . . The infiltrating elements were chiefly mononuclear cells and plasma cells, but eosinophils were often present. The granulomatous lesions, noted chiefly in the central nervous system, seemed to develop in response to small numbers of parasites.'

At necropsy large areas of necrosis associated with calcification and cysts may be found in the brain. Sometimes there is widespread encephalomalacia (Kean and Grocott, 1948). In patients dying in the early days of life extramedullary haemopoiesis in the liver and spleen is common and is regarded by Zuelzer (1944) as related to the toxoplasma infection.

## Clinical Features

Human toxoplasmosis may take five forms ('Lancet,' 1948): (1) a congenital infection, possibly transmitted via the placenta, less probably reaching the amniotic fluid from the vagina (Paige, Cowen, and Wolf, 1942; Cowen, Wolf, and Paige, 1942); (2) an acquired acute encephalitis in older children (Sabin, 1941); (3) an acute toxoplasmosis in adults with fever, pulmonary signs, and sometimes with a diffuse maculo-papular rash indistinguishable clinically from tick typhus (Pinkerton and Weinman, 1940; Pinkerton and Henderson, 1941; Syverton and Slavin, 1946); (4) a chronic encephalitis in adults (Kean and Grocott, 1945); and (5) a symptomless infection in adults out of which presumably the first type arises during intra-uterine life. Callahan (1945) detected evidence of sub-clinical infection in 2.7 per cent. of individuals in the St. Louis area.

The most characteristic clinical features of the

congenital type are composed of the tetrad, hydrocephalus, intracranial calcification, bilateral macular chorio-retinitis, and disturbances of nervous function.

**Hydrocephalus.** This seems to be an almost constant feature of congenital toxoplasmosis and it may be associated with a large head, a head of normal size, or even with microcephalus. Adams, Adams, Kabler, and Cooney (1948) demonstrated internal hydrocephalus in all of eleven patients although three had microcephalus.

**Intracranial calcification.** This is extremely common although it may not be obvious radiologically during the early days of life. It takes the form of curvilinear streaks of calcification in the region of the basal ganglia or optic thalamus, or of multiple rounded opacities of varying size from 1 mm. in diameter (Dyke, Wolf, Cowen, Paige and Caffey, 1942).

**Chorio-retinitis.** The macular region is chiefly affected and chorio-retinitis is associated with rapidly developing optic atrophy in some cases. It has to be differentiated from the changes seen in (a) pseudoglioma; (b) intra-ocular tumour; (c) traumatic lesions; (d) hereditary macular defects; (2) congenital developmental defects of the choroid and retina (Callahan, Russell, and Smith, 1946). In one of Zuelzer's (1944) cases the typical appearances did not develop until the infant was five months of age.

**Disturbances of nervous function.** Such disturbances as mental deficiency, spasticity, optic atrophy, and convulsions are frequently but not necessarily present. Cowen, Wolf, and Paige (1942) suggest that the mental deficiency is usually mild in degree. One of the patients described by Adams, Adams, Kabler, and Cooney (1948) had a better than average intelligence in spite of marked hydrocephalus. Crothers (1943) and Adams, Horns, and Eklund (1946) have described patients in whom the intelligence was not affected; the latter authors' patient had also marked hydrocephalus which was cured by ablation of the right choroid plexus.

Various other less frequently reported features may be encountered. Neonatal jaundice with enlargement of liver and spleen and with erythroblastemia may simulate haemolytic disease (Zuelzer, 1944; Callahan, Russell, and Smith, 1946). Ocular signs other than chorio-retinitis which have been reported are coloboma of the macula (Janku, 1923), microphthalmos, enophthalmos, ocular palsies, nystagmus, and papilloedema (Paige, Cowen, and Wolf, 1942; Callahan, Russell, and Smith, 1946). Susceptibility to respiratory infections may be related to the toxoplasmic pneumonitis frequently found at necropsy. Diarrhoea and vomiting usher in the disease in some infants. Myocarditis has frequently been reported, usually without obvious clinical evidence of its presence, although one infant described by Cowen, Wolf, and Paige (1942) had oedema. A curiously unstable temperature and a diffuse maculo-papular rash in

the neonatal period were also described by Cowen, Wolf, and Paige (1942). The cerebrospinal fluid in many of the cases reported has been xanthochromic with pleocytosis and a high protein content (Paige, Cowen, and Wolf, 1942; Zuelzer, 1944; Adams, Adams, Kabler, and Cooney, 1948). Rarely toxoplasma has been found in smears (Wolf and Cowen, 1937; Cowen, Wolf, and Paige, 1942).

### Diagnosis

The only certain proof of toxoplasmosis is the recovery of the toxoplasma from the body fluids, especially from the cerebrospinal fluid, by intracerebral and intraperitoneal inoculation of rabbits or mice. This is, however, often unsuccessful even when carried out soon after birth (Zuelzer, 1944; Miller, 1947); and, of course, in older patients the infection may have subsided leaving only the permanent residua.

A test for the demonstration of toxoplasma-neutralizing antibodies in the serum of affected persons has been described in detail by Sabin and Ruchman (1942), Sabin (1942), Cowen, Wolf, and Paige (1942), and Callahan (1945). A positive test in the mother or infant is strong presumptive evidence of toxoplasmosis but a negative result does not at all rule out the possibility of its having been present and subsided (Sabin, 1941; Crothers, 1943; Schwartzmann, Maffia, Crusius, and Brunhoffer, 1948). A more satisfactory test, the cytoplasm-modifying antibody test, has recently been described by Sabin and Feldman (1948); this has been found more useful than the neutralization test because of its simplicity and because the quantitative data obtained permits differentiation between very old and more recent infection.

### Prognosis

The almost invariably fatal outcome in the early reports of cases of congenital toxoplasmosis at first gave the impression that this was a progressive disease. It is, however, now obvious that in some patients with manifest signs of the disease the infection may cause only limited disability or die out altogether. Sabin (1942) found positive neutralizing toxoplasma antibody tests in nine out of ten individuals suffering only from chorio-retinitis of unknown cause. Johnson, Fried, Broadus, and Lamfrom (1946) obtained positive antibody tests in twenty patients with chorio-retinitis in only four of whom was other evidence (intracranial calcification) of toxoplasmosis present. They also describe the interesting case of a woman aged twenty-two years with a positive antibody test in whom a quiescent chorioretinal lesion became activated during each of three pregnancies. The only living child (of the second pregnancy) seemed normal, and the foetus obtained from the third pregnancy by therapeutic abortion showed no evidence of toxoplasmic infection. They further report that two of their four laboratory workers

acquired subclinical toxoplasmosis and that one of these later gave birth to a perfectly normal child. On the other hand, Sabin (1942) obtained positive antibody tests in three out of four mothers who had given birth to stillborn hydrocephalic or microcephalic babies, and also in three out of eight mothers who had given birth to anencephalic monsters.

It would appear, then, that a woman with subclinical toxoplasmosis may produce a foetus so diseased as to be incapable of extra-uterine life, or an infant with manifest congenital toxoplasmosis, or an unaffected normal infant. Furthermore, the infected infant may be either severely disabled or suffer only moderate disability compatible with a useful existence.

### Case Reports

**Case 1.** P.N., a girl aged a year and three months, was admitted to the Royal Hospital for Sick Children, Glasgow, on December 2, 1948, with pneumococcal broncho-pneumonia which quickly recovered on penicillin and sulphamerazine.

She had been a full-time baby weighing 6 lb. 2 oz. at birth. She was breast-fed for six months and gained weight at a normal rate. She sat up unsupported at eight months, started to say a few words at fifteen months, but was not yet walking when she contracted pneumonia.

The mother noted that she had an internal squint of both eyes at birth, and thought that as early as eight weeks the infant failed to see properly in comparison with her previous children at the same age. On July 3, 1948, when she was thirteen months old she was for the first time examined at the Glasgow Eye Infirmary. There was at that time 'a marked disseminated pigmentary choroido-retinitis affecting the maculae' of both eyes. The Wassermann reaction was negative. On July 13, 1948, repeat fundal examination revealed, in addition, a coloboma of the right disc and choroid.

The mother was aged thirty-two years and was healthy. The father was aged thirty-seven years; for some years he had been addicted to drugs and, in fact, he died from an overdose of self-administered chloroform while his child was in the hospital. There are three older children, a boy aged five years, and twin girls aged three years, all of whom are healthy.

On examination after admission the child was seen to be thin, 86 per cent. of the expected weight for her age. The head circumference was  $17\frac{1}{2}$  in. (average normal  $18\frac{1}{2}$  in.). On admission she was profoundly ill, dyspnoeic and cyanotic, although her rectal temperature never rose above  $100^{\circ}$  F. The signs of broncho-pneumonia were present throughout both lungs. There was no evidence of cardiovascular, gastro-intestinal or renal disease.

When she had recovered from the pneumonia it was obvious that she was a high-grade mental defective. There was no spasticity but the knee and ankle-jerks were exaggerated and the plantar

responses were extensor. Her vision was obviously poor and there was a bilateral internal strabismus.

Ophthalmoscopy showed pale discs and narrowed arteries. There was fine pigmentation over the whole of both fundi, and there were atrophic white areas at both maculae with marked surrounding pigmentation. A proliferative pigmented mass obscured the right choroidal coloboma. The appearances were those of bilateral choroido-retinitis.

The following laboratory investigations were carried out:

The Mantoux test (1/5,000) was negative. A blood count showed haemoglobin 11 g. per cent.; red cells 3.95 million per c.mm.; white cells 12,800 per c.mm.

A laryngeal swab produced a heavy growth of pneumococci and scanty coliform organisms on culture.

X-ray examination of the chest showed patchy consolidation of both lungs, and of the skull several areas of calcification in the form of linear streaks in the region of the optic thalamus which were too fine for photographic reproduction.

Examination of the cerebrospinal fluid gave a normal pressure. The Pandy reaction was positive: cells 4 per c.mm.; protein 36 mg. per cent.; chlorides 719 mg. per cent.

The Wassermann reaction was negative.

Several mice and guinea-pigs were inoculated intracerebrally and intraperitoneally both in the Royal Hospital for Sick Children and in the Bacteriological Department of Sheffield University, but none of the animals developed clinical or post-mortem evidence of toxoplasmosis.

A pneumo-encephalogram showed a severe cortical defect of the left cerebral hemisphere. The ventricular system failed to fill with air.

The sera from the patient (P.N.) and her mother (Mrs. N.) were sent to Dr. Sven Gard, of the Statens Bakteriologiska Laboratorium, Stockholm, for the cytoplasm-modifying antibody test of Sabin and Feldman (1948). Both specimens yielded positive results with titres of 1:100 (final dilution 1:200). Dr. Sven Gard, who had used this test on about 300 sera, regarded the results as highly significant and indicative of toxoplasmosis. As the titre usually exceeds 1:200 during the active phase of the infection it is assumed that the process in the child as well as in the mother has subsided.

Professor C. P. Beattie, of the Bacteriology Department, Sheffield University, obtained the following results from a toxoplasma neutralizing antibody test on the sera of P.N. and Mrs. N.:

The sera of P.N. in the first test neutralized 10 to 100 skin doses, and in the second 100 to 1,000 skin doses. That of Mrs. N. neutralized 10 to 100 skin doses.

Serum inoculations intracerebrally and intraperitoneally into mice failed to produce toxoplasma infection.

The mother and three older children were all examined and appeared to be healthy. None

showed the presence of choroido-retinitis or intracranial calcification. The neutralizing antibody tests on the three children were negative (Professor C. P. Beattie).

The patient has been seen as an out-patient on several occasions since discharge from hospital on February 26, 1949. She is in good general health and has not had any recurrence of chest infection.

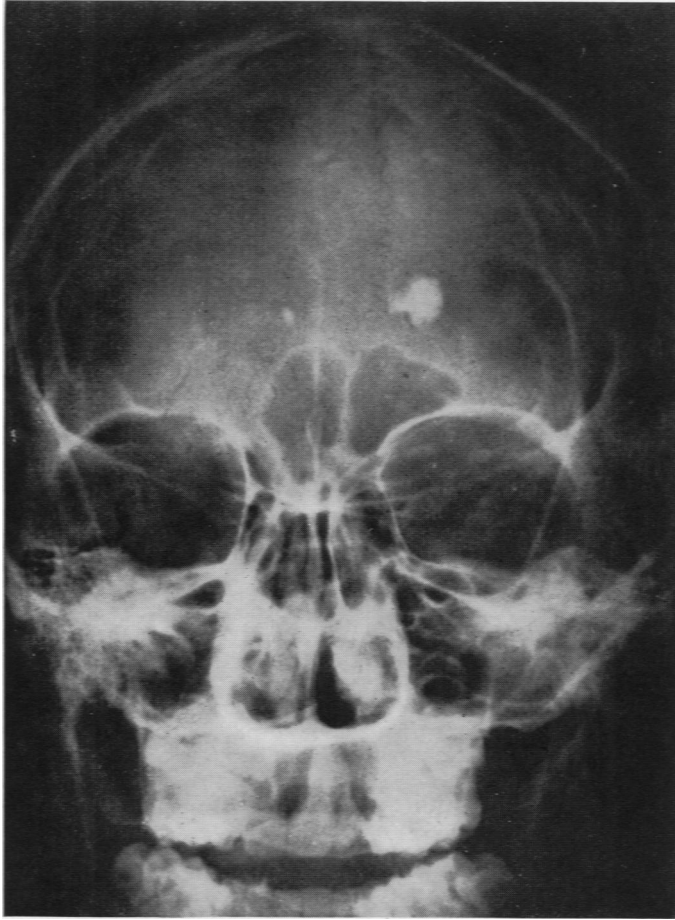


FIG. 1.—Film showing areas of intracranial calcification, two of marked density (Case 2).

**Case 2.** J.W., a boy aged sixteen years, reported to the out-patient department of Glasgow Eye Infirmary on February 12, 1949, complaining of weakness of vision of long standing.

The history obtained later from his mother was as follows. He was her first child, a full-term healthy baby weighing 7 lb. He developed normally, walking at eleven months and talking at twelve months. At the age of six months, however, it was noted that he failed to grasp objects which were near his face. At the age of four years he was examined by an ophthalmologist who reported that

the boy had some retinal abnormality in both eyes and prescribed glasses which were worn thereafter. He left school at the age of fifteen years and works as a general labourer.

The mother was aged forty-one years and the patient's father, who is not the mother's husband, was aged forty-one years. Both are healthy. The mother has since had two healthy children by her husband.

On examination the boy appeared to be a healthy, well-developed youth of low average intelligence. Clinically there was no evidence of organic disease other than in the eyes. (Visual acuity: right eye 6/60; left eye 6/60.) There was limited lateral and upward movement of the eyes and an occasional nystagmoid jerk was seen.

Ophthalmoscopy revealed old, inactive, extensive bilateral choroido-retinitis especially affecting the maculae.

A radiograph of the skull showed several patches of intracranial calcification, two being of large size and marked density (figs. 1 and 2).

The Wassermann reaction was negative.

The sera from the patient and his mother were sent to Dr. Sven Gard for the cytoplasm-modifying test. He reported the presence of toxoplasma antibody in very low concentrations in both specimens, and gave it as his opinion that as the infection in the patient presumably dated sixteen years back the results were compatible with a diagnosis of toxoplasmosis. At the same time he pointed out that similar results are given by 30 per cent. of normal adults with no history to suggest toxoplasmosis.

Professor C. P. Beattie obtained the following results from the toxoplasma neutralizing antibody test on the sera of the patient and his mother (Mrs. W.):

The sera of J.W. neutralized 10 rabbit skin test doses, but that of Mrs. W. showed no neutralization of toxoplasma.

#### Discussion

In case 1 the diagnosis of congenital toxoplasmosis can hardly be in doubt. There was bilateral choroido-retinitis, intracranial calcification, mental deficiency, evidence of pyramidal tract damage, and both the patient and her mother had toxoplasma antibodies in their sera in amounts not to be found in healthy people. The failure to recover toxoplasma by intracerebral and intraperitoneal inoculation of animals with the patient's serum and cerebrospinal fluid in no way precludes the diagnosis,

and seems, in fact, to be the rule rather than the exception (Miller, 1947; Adams, Adams, Kabler, and Cooney, 1948; Jacoby and Sagorin, 1948). As regards prognosis, there would seem to be no reason why this patient should not survive into adult life although obviously her brain must remain seriously damaged. Death, if it should come earlier, would probably be by way of respiratory infection to which sufferers from toxoplasmosis appear to be especially susceptible (Callahan, Russell, and Smith, 1946).

In case 2 the diagnosis of toxoplasmosis is open to doubt. The presence of toxoplasma antibodies in very low concentrations, although compatible with a diagnosis of toxoplasmosis, is not helpful because many supposedly normal people give similar results. None the less, the toxoplasmic infection in this patient was of sixteen years' duration, because symptoms were noted during the first year of life, and a high concentration of antibodies would hardly be present at the time of examination. Sabin (1941), Syverton and Slavin (1946), and others have found that antibodies may disappear within six to ten weeks after infection by toxoplasma.

Levin and Moore (1942) describe an infant with the typical clinical features of congenital toxoplasmosis in whom at the age of one year the neutralizing antibody test was negative although Sabin found the complement fixation test to be positive. Heidelman (1945) obtained positive antibody tests in 63 per cent. of cases of congenital chorio-retinitis in which toxoplasma might reasonably have been suspected as the causal agent, and of nine patients with congenital chorio-retinitis and other evidence of toxoplasmosis, only five had antibodies in their sera. Heidelman states:

'Therefore it would appear that the demonstration of the neutralizing antibody should be considered a factor of moderate diagnostic value only in patients with congenital chorio-retinitis.'

Furthermore, Crothers (1943) states:

'It has been my experience that the suggestion of toxoplasmosis should arise when the ophthalmologist is puzzled by the presence of chorio-retinitis. If calcification of the brain occurs in addition the presumption is strong.'

The fact that the second patient was in good general health apart from inactive chorio-retinitis and intracranial calcification only provides further evidence to support the view of several workers

(Sabin, 1942; Crothers, 1943; Callahan, 1945; Heidelman, 1945; Johnson, Fried, Broaddus and Lamfrom, 1946; Plaut, 1946; Adams, Adams, Kabler, and Cooney, 1948) that a patient may survive infection without serious disability even when the brain and eyes are involved, and that only one or two of the cardinal manifestations of the disease may be present.

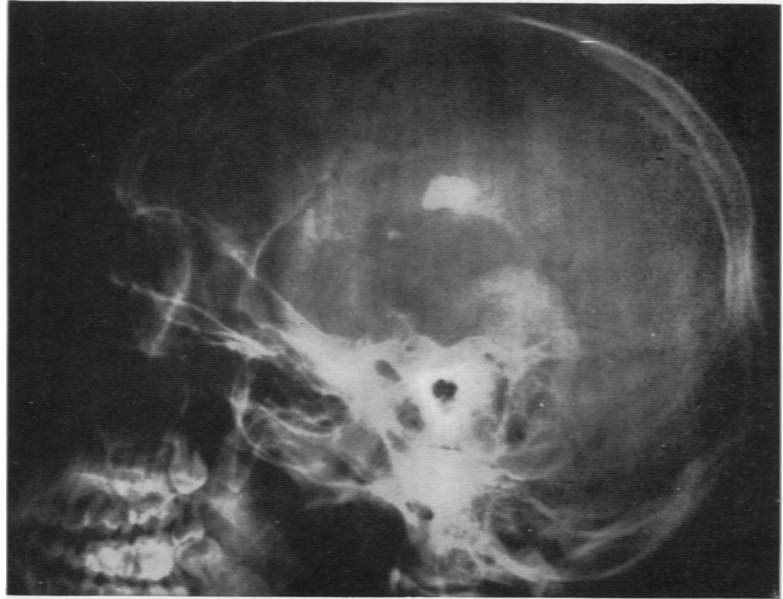


FIG. 2.—Film showing that calcification is in the region of the basal ganglia (Case 2).

I understand that in ophthalmological practice in Great Britain bilateral chorio-retinitis is not an extremely rare condition, and that when cases due to syphilis and tuberculosis are excluded there remains a number for which no cause can be found. It seems probable that if facilities for the performance of toxoplasma antibody tests were more generally available toxoplasmosis in this country would be shown to be not very uncommon. Affected patients are most likely to reach either the paediatrician, because of visual defects, mental abnormalities, abnormal heads, or as gravely ill newborn infants, or the ophthalmologist with chorio-retinitis.

#### Summary

The etiology, pathology, clinical and serological diagnosis, and prognosis of congenital toxoplasmosis are briefly reviewed.

Two probable cases occurring in the United Kingdom and not noted in the literature are described and discussed.

Thanks are due to Dr. J. Pendleton White, visiting surgeon, Glasgow Eye Infirmary, for permission to report case 2, and to Dr. Sven Gard,

of Stockholm, and Professor C. P. Beattie, of Sheffield for carrying out the toxoplasma antibody tests.

## REFERENCES

- Adams, F. H., Adams, J. M., Kabler, P., and Cooney, M. (1948). *Paediatrics*, **2**, 511.
- , Horns, R., and Eklund, C. (1946). *J. Pediat.*, **28**, 165.
- Baar, H. S. (1946). *Brit. med. Bull.*, **4**, 178.
- Callahan, W. P. (1945). *Proc. Soc. exper. Biol. Med.*, **59**, 68.
- , Russell, W. O., and Smith, M. G. (1946). *Medicine*, **25**, 343.
- Cowen, D., Wolf, A., and Paige, B. H. (1942). *Arch. Neurol. Psychiat.*, **48**, 689.
- Crothers, B. (1943). *Arch. Neurol. Psychiat.*, **49**, 315.
- Dyke, C. G., Wolf, A., Cowen, D., Paige, B. H., and Caffey, J. (1942). *Amer. J. Roentgenol.*, **47**, 830.
- Farquhar, H. G., and Turner, W.M.L. (1949). *Arch. Dis. Childh.*, **24**, 137.
- Heeley, D. M. (1948). Quoted by Jacoby and Sagorin.
- Heidelman, J. M. (1945). *Arch. Ophthl.*, **34**, 28.
- Jacoby, N. M., and Sagorin, L. (1948). *Lancet*, **2**, 926.
- Janku, J. (1923). *Čas. Lék. Čes.*, **62**, 1021.
- Johnson, L. V., Fried, N., Broaddus, C. C., and Lamfrom, H. (1946). *Arch. Ophthl.*, **36**, 677.
- Kean, B. H., and Grocott, R. G. (1945). *Amer. J. Path.*, **21**, 467.
- (1948). *J. Amer. med. Ass.*, **136**, 104.
- Lancet* (1948). *Leading Article*, **2**, 934.
- Levin, P. M., and Moore, H. (1942). *J. Pediat.*, **21**, 673.
- Miller, M. C. (1947). *J. Pediat.*, **30**, 201.
- Nutt, A. B. (1949). *Brit. med. J.*, **2**, 174.
- Paige, B. H., Cowen, D., and Wolf, A. (1942). *Amer. J. Dis. Childh.*, **63**, 474.
- Parsons, Sir L. G. (1946). *J. Obstet. Gynec.*, **53**, 1.
- Pinkerton, H., and Henderson, R. G. (1941). *J. Amer. med. Ass.*, **116**, 807.
- , and Weinman, D. (1940). *Arch. Path.*, **30**, 374.
- Plaut, A. (1946). *Amer. J. Path.*, **22**, 427.
- Richter, R. (1936). *Arch. Neurol. Psychiat.*, **36**, 1085.
- Ridley, H. (1949). *Brit. J. Ophthl.*, **33**, 397.
- Sabin, A. B. (1941). *Journ. Amer. med. Ass.*, **116**, 801.
- (1942). *Proc. Soc. exp. Biol.*, **51**, 6.
- , and Feldman, H. A. (1948). *Science*, **108**, 660.
- , and Ruchman, I. (1942). *Proc. Soc. exp. Biol.*, **51**, 1.
- Schwartzman, J., Maffia, A., Crusius, M. E., and Brunhoffer, A. (1948). *J. Pediat.*, **33**, 66.
- Syverton, J. T., and Slavin, H. B. (1946). *Journ. Amer. med. Ass.*, **131**, 957.
- Torres, C. M. (1927). *R. Soc. Biol., Paris*, **97**, 1778.
- Wolf, A., and Cowen, D. (1937). *Bull. neurol. Inst. N. Y.*, **6**, 306.
- , —, and Paige, B. H. (1939). *Amer. J. Path.*, **15**, 657.
- Zuelzer, W. W. (1944). *Arch. Path.*, **38**, 1.