

Two Brothers with Hæmophilia.

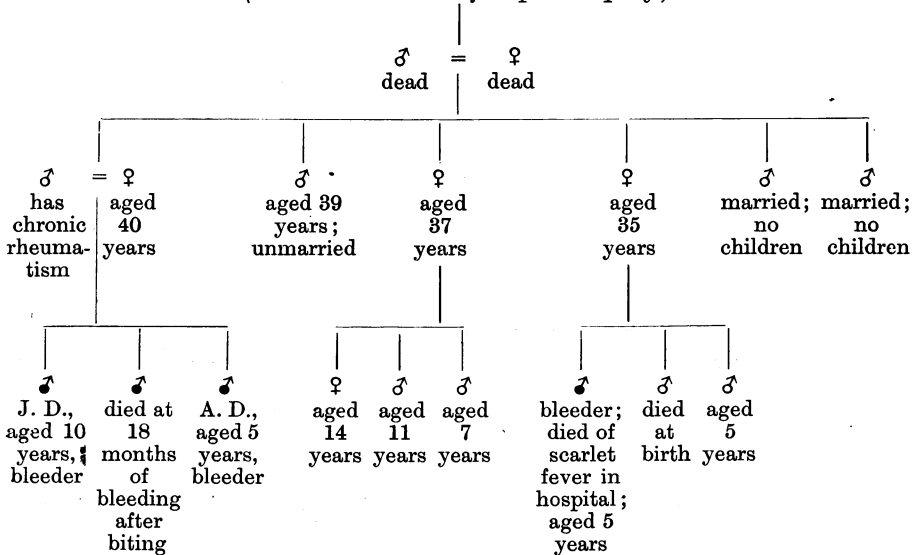
By THEODORE THOMPSON, M.D.

J. D., AGED 10 years, a thin, poorly nourished boy. Symptoms noticed since infancy. Frequent bruising on very slight trauma. Bleeds for one hour if he scratches his hand. Sometimes there is slight bleeding from the mouth, in which there are several carious teeth. On one occasion there was severe hæmorrhage from the gums (1908). For several years has had attacks of pain and swelling in the knees. The left knee was first affected and is now enlarged, and the synovial membrane thickened. The right knee is swollen by synovial effusion. No gastro-intestinal hæmorrhages. Coagulation time (Wright's method), five minutes (normal, three minutes).

A. D., aged 5 years. Stout and well nourished. Extensive bruising of the skin and deeper structures occurs on very slight injury. No bleeding from mouth, nose, or intestines. The only family history of bleeding is on the mother's side.

HISTORY OF BLEEDING IN THE PAST GENERATIONS.

(No details obtainable after special inquiry.)



Dark circles = bleeders.