

DIFFUSE PROGRESSIVE INTERSTITIAL FIBROSIS OF THE LUNGS IN CHILDHOOD

BY

H. S. BAAR and FRANCES BRAID

From the Children's Hospital, Birmingham

(RECEIVED FOR PUBLICATION DECEMBER 27, 1956)

Hamman and Rich reported three cases of diffuse fibrosis of the lungs in 1935, and when they met a fourth case after a lapse of nine years (1944) they described in detail this condition under the title 'Acute Diffuse Fibrosis of the Lungs'. Since then it has been referred to as the 'Hamman-Rich syndrome'. The authors stated that the clinical picture—progressive dyspnoea and increasing evidence of myocardial insufficiency—was new to the physician and the anatomical picture new to the pathologist. They considered the disorder as a definite clinico-pathological entity of unknown origin. Clough (1954) and Bradley (1956) collected from the literature 25 similar cases in addition to 20 doubtful or incompletely investigated patients. Some had a subchronic and others a chronic course, the shortest duration being 31 days, the longest nine years. The name 'diffuse progressive interstitial fibrosis of the lungs', which was proposed by Beams and Harnos (1949), appears therefore more appropriate than that originally suggested. The age of the reported patients varied between 21 and 68 years, except for the girl recently reported by Bradley (1956) who was 9 years old at the time of her death. In the British literature, Heppleston (1951) reported one adult case and Sloper and Williams (1955) described another example in an adult. It seems, therefore, that the condition is not well known in this country, and that so far it has not been recognized in early childhood. The case which we now report is that of a boy, 2½ years of age, who presented in a quite unusual clinical picture, features described as characteristic of the Hamman-Rich syndrome, namely a chronic illness with progressive dyspnoea, tachypnoea, cyanosis, increasing evidence of pulmonary hypertension and the development of right ventricular failure.

Case History

A boy, born on February 20, 1953, was under the care of one of us (F.B.) from July 5, 1955, until his death on

March 18, 1956 (eight and a half months). He was the third child in a family of three, who lived with their parents and grandparents in overcrowded conditions in a poor area. Most of the members of the household had 'coughs'. His birth weight was 6 lb. 6 oz. He grew in length but had always been thin; he learned to walk and talk at the normal age. At the age of 7 months he had whooping-cough and from that time had attacks of 'bronchitis' at intervals of four to six weeks, each attack lasting about four days. Between attacks he was not free from cough. Because of a more severe attack, he was admitted to hospital on July 5, 1955.

He was an intelligent but very apprehensive child and detailed examination was at first difficult. The general nutrition was poor (weight 26½ lb.) but he was of normal length for his age. The skeletal muscles were poorly developed and hypotonic; the head seemed relatively large and he had prominent though not exophthalmic eyes; the radial epiphyses were enlarged but there was no radiological evidence of rickets; the thorax was flat and the lower costal margins were indrawn; the respiratory rate was 35/min., pulse rate 110-140/min. and the temperature normal. There were remarkably few abnormal signs in the lungs but he had a dry, 'brassy' cough. The heart sounds at this time were closed and of normal intensity. Because of his excitability he was given phenobarbitone and with this his respiration rate fell to between 20 and 30/min. but the pulse rate remained high. Radiological examination showed a diffuse mottling of the lungs with a denser shadow on the right side, medially (Fig. 1).

For two weeks there was little change in his general condition but on July 18 he suddenly became very ill, the respiratory rate rising to 60/min., and he became cyanosed; when he coughed or cried this became intense and the superficial veins became distended; the temperature rose to 99° F. The distress was as great as is seen in acute asthma but the picture as a whole was not that of asthma. Presuming a secondary infection, he was given aureomycin (300 mg. daily for one week). Oxygen was not tolerated. On the third day the respiratory rate fell to 30/min. and the temperature to 98° on the fifth day. By the end of a week, his general condition was better than it had been since his admission and he went home on August 12. He was seen in the Out-patient

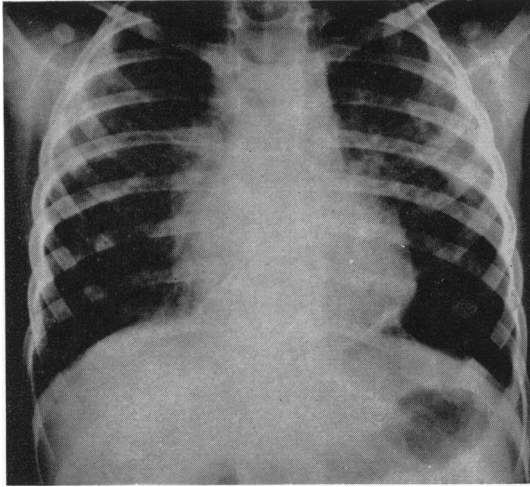


FIG. 1.—Radiograph of the chest.

Department on September 12 when he was fairly well, and had gained a little weight. He was reported to have had one short, severe attack of dyspnoea but it passed so quickly that a doctor was not called. He was seen again on October 12 and was then readmitted. He had lost weight, was less well in general and the respiratory rate was 50/min. A few moist sounds were heard scattered over both lungs; the heart sounds were closed but it was now noted that the pulmonary second sound was markedly accentuated. His general condition had not changed much and he was brighter and more friendly. Apart from the tachypnoea he seemed to feel quite well and he sat up and took interest in his surroundings. The respiratory rate was constantly about 60/min. and did not vary during sleep. The pulse rate varied a great deal, even during sleep, from 90 to 150/min. The temperature rose to 99° F. occasionally and on November 15 to 103°. Then he had more severe dyspnoea and the respiratory rate was 60-80 per minute. On aureomycin the temperature fell to normal but the respiratory rate remained high. When he coughed or cried an almost constant cyanosis became much worse and there was a general distension of the superficial veins. There was now some finger clubbing.

He was usually quiet and contented, willing to talk and usually ready to smile. Sometimes he cried out as if in pain. He preferred to sit up, and usually leaned forwards a little in a squatting position. He made no attempt to stand up in his cot and he expressed no desire to be taken out of his cot. His progress varied a little, sometimes he seemed to feel better, but he had attacks of severe dyspnoea from which he recovered in a surprising manner; there was a steady gradual general deterioration.

The physical signs in the lungs were remarkably few, but at times fine crepitations could be heard over small areas. His cough became paroxysmal. After a short course of cortisone which produced a very temporary improvement, the temperature reached a higher level and remained above normal.

In the end of February he developed various small 'haemangiomas' in the skin of the trunk and limbs and, on the anterior abdominal wall, small ulcers. Early in March, signs of right heart failure became gross; oedema, enlargement of the liver and signs of oedema of the lungs. With 'digoxin' and 'mersalyl', there was slight improvement. He died quite suddenly on March 18.

Laboratory Investigations. Repeated radiological examinations showed little change. The first electrocardiogram, taken on November 23, 1955, showed a mild degree of right ventricular dominance, though this was little more than might be expected at this age. However, by February, 1956, the degree of dominance had increased, suggesting that right ventricular strain was greater and that this was secondary to the pulmonary changes.

The haemoglobin level varied between 87 and 100% (Haldane). The total white cell count was usually between 6,000 and 9,000; the highest on one occasion was 17,000 per c.mm. That coincided with a rise in temperature and was probably related to superadded infection. At no time was there an eosinophilia. Pancreatic function was normal and fat absorption was 94.4%. The sweat salt content was normal. Mantoux and Wassermann tests were negative.

Treatment. Treatment was quite ineffective in the control of the disease although antibiotics had some influence on what was thought to be superadded infection. Oxygen was not tolerated. Cortisone produced temporary improvement in well-being but probably hastened the downward trend of the illness.

Clinical Diagnosis. The whole clinical picture was one not previously observed and a tentative diagnosis of the 'Hamman Rich syndrome' was made by exclusion of the more familial post-whooping cough bronchiectasis, pulmonary fibrosis associated with pancreatic fibrosis, chronic lung disease associated with tuberculosis or syphilis, primary congenital heart disease and idiopathic pulmonary haemosiderosis. The exact diagnosis depends on histology and is discussed in detail later.

Post-mortem Findings. Necropsy was performed 29 hours after death. Apart from small ulcers of the skin which were covered by blackish-red crusts and a mild clubbing of fingers and toes, the pathological findings were limited to the lungs and the heart. These were as follows:

There were extensive greenish-yellow membranes of fibrino-purulent exudate loosely adherent to the pulmonary pleura of the left lung and a smaller amount of similar exudate was also present on the right side, mainly in the interlobar space between the middle and lower lobes. The lungs were uniformly firm in consistency. On the cut surfaces a greyish-white network and greyish-red spots were seen, uniformly distributed throughout all lobes of both lungs. Only the upper lobe of the right lung showed a more uniformly consolidated area, dove-grey in colour not unlike the appearance of carnification.

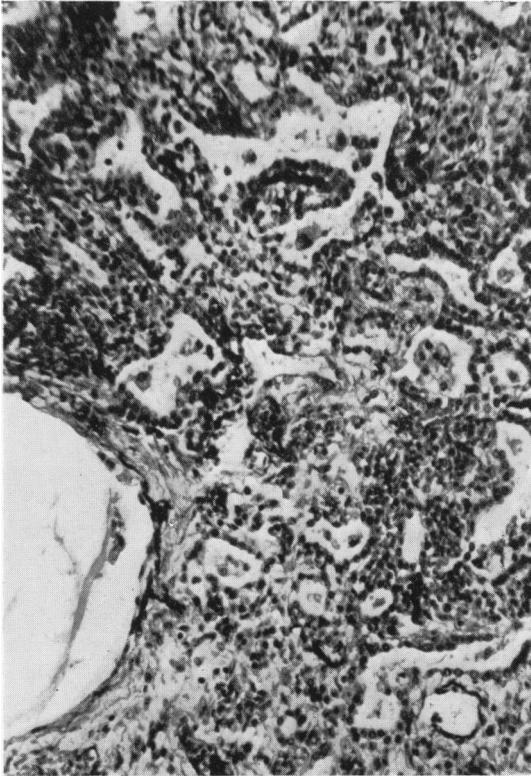

FIG. 2.—Broadening of the interstitial tissue of the lung. Van Gieson plus Weigert's elastic tissue stain. $\times 120$.

When examined with the help of a lens the lungs had the appearance of solid pinkish-grey and greyish-white tissue with numerous holes as if pierced with the tip of a needle. The tracheo-bronchial, paratracheal and other mediastinal lymph nodes were all enlarged, greyish-red and soft. None of them showed any circumscribed lesions, nor any evidence of caseation or calcification. The epicardium of the right auricle was dull in appearance and showed grey and greyish-red spots. The heart was moderately enlarged and the enlargement was due to an eccentric hypertrophy of the right ventricle. The valves, septa and great vessels were normal.

Histological Findings. The submesothelial connective tissue of the lungs is oedematous, shows many distended capillaries and a loose infiltration with polymorphonuclear leucocytes and lymphocytes. The most conspicuous finding is the broadening of the interstitial tissue (Fig. 2). This is most marked in the interalveolar septa and decreases in a proximal direction, being minimal around the larger bronchioles and bronchi. The broadening is due to a variable cellular infiltration and/or fibrosis. Some interalveolar septa are very cellular, show numerous large mononuclear cells and lymphocytes with a few plasma cells and an occasional polymorphonuclear leucocyte (Fig. 3). Capillaries of the septa are often

dilated but apparently not increased in number. Fibroblasts are scanty in the cellular areas of interstitial tissue but more numerous in other parts and in such areas a fair number of van Gieson-positive fibres is seen (Fig. 4). In all interalveolar septa an abundance of argentaffine fibres is demonstrable (Fig. 5). Mast cells and eosinophilic leucocytes are absent. The fibrosis is particularly marked in subpleural areas. The alveoli are lined by cuboid epithelium (Figs. 2 and 3). They are compressed, usually circular, but in areas of more advanced fibrosis they form often narrow, occasionally slit-like, tortuous tubules, not unlike those seen in bronchiectatic lungs (Fig. 6). Alveoli, alveolar ducts, bronchioli and bronchi are either empty or they contain groups of large mononuclear cells with a frequently foamy cytoplasm and a few lymphocytes. In some air spaces an acellular pale eosinophilic oedema fluid is seen. Alveolar ducts are sometimes, and respiratory and terminal bronchioles

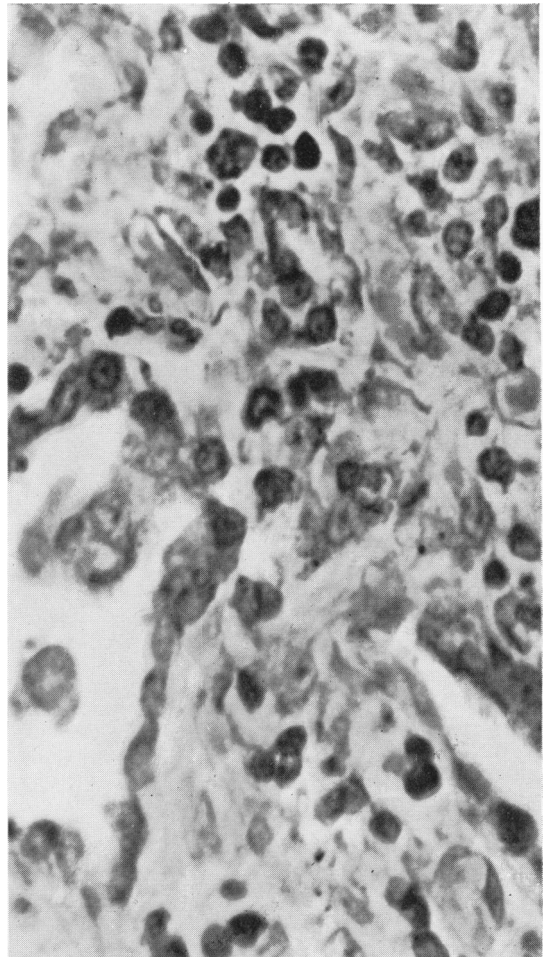


FIG. 3.—Intra-alveolar septum showing large mononuclear cells and lymphocytes with a few plasma cells and an occasional polymorphonuclear leucocyte. Giemsa. $\times 625$.

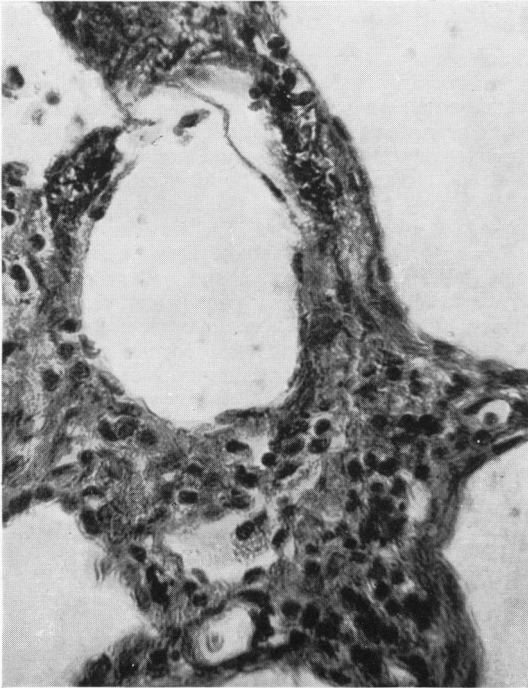


FIG. 4.

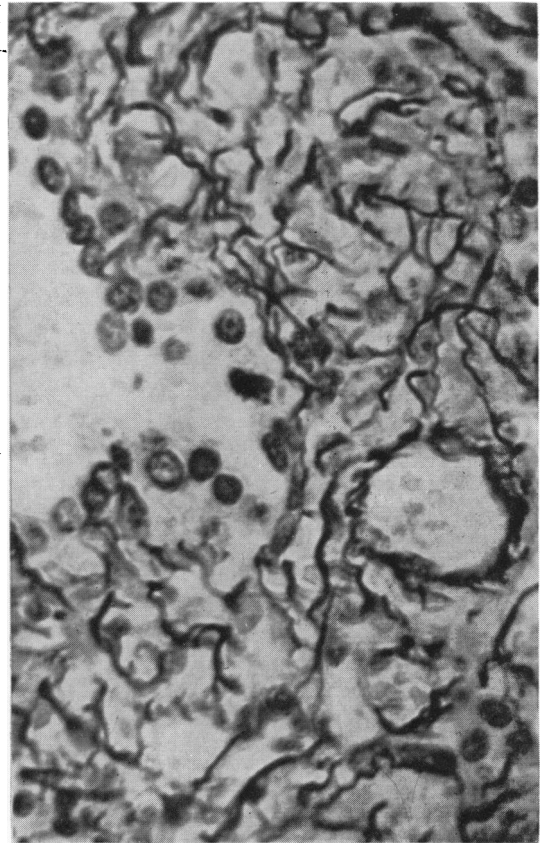


FIG. 5.

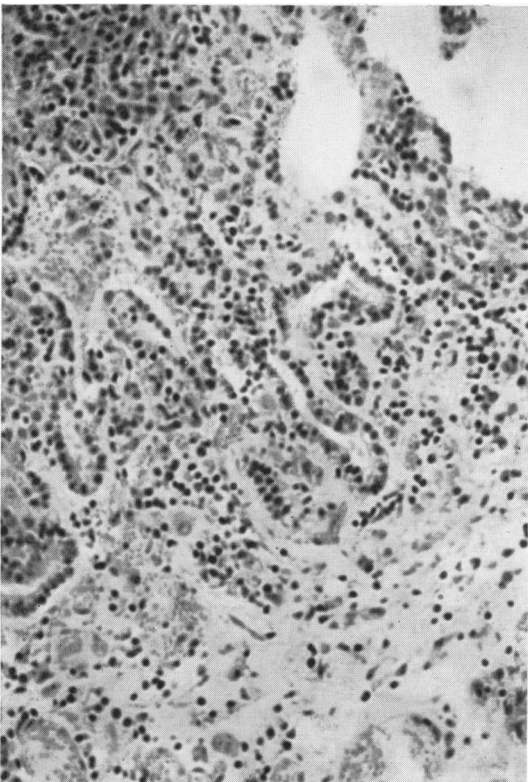


FIG. 6.

FIG. 4.—Interstitial areas of lung stained with Van Gieson plus Weigert's elastic tissue stain. $\times 192$.

FIG. 5.—Interalveolar septum of lung showing argentaffine fibres. Laidlaw. $\times 625$.

FIG. 6.—Alveoli formed into narrow tubules similar to those found in bronchiectasis. Haematoxylin and eosin. $\times 120$.

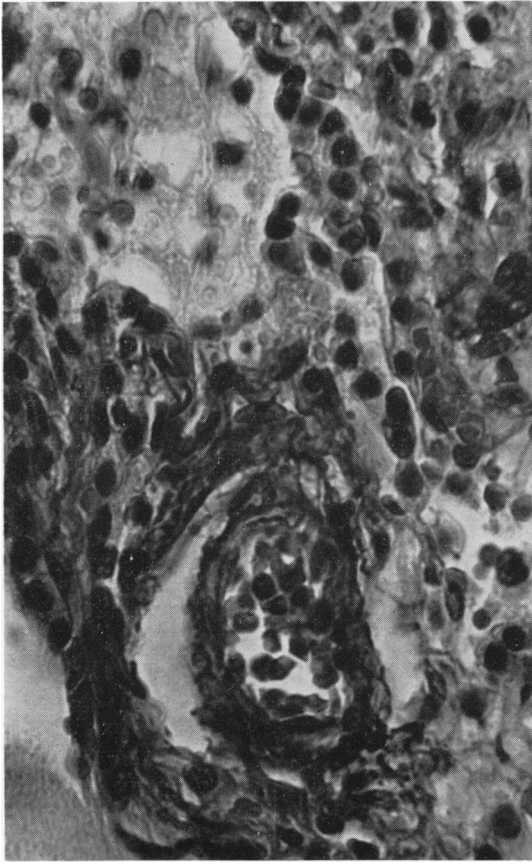


FIG. 7.—Pulmonary arterioles showing muscular media. Van Gieson plus elastic tissue stain. $\times 466$.

often, distended. A few terminal air spaces are partly lined by a hyaline membrane. This is deeply eosinophilic, engulfs sometimes flat cells or is covered towards the lumen by a continuous layer of extremely flattened cells. Fibrin is nowhere demonstrable by Weigert's fibrin-stain or by phosphotungstic acid-haematoxylin, but by acid picro-Mallory deeply red fibres are seen in the interstitial tissue, none within the air spaces. Nowhere is organization of alveolar exudate or a continuity between the alveolar contents and the tissue of the interalveolar septa demonstrable, and cellular infiltration or fibrosis of interalveolar septa shows no relationship to the presence or absence of cells or of eosinophilic material in the air spaces. The bronchi and bronchioli show no ulceration and there is no lymphoid hyperplasia, such as commonly seen in bronchiectasis. Frozen sections stained with Sudan-black showed sudanophil material in many cells of the interalveolar septa and also within the air spaces. With scarlet-red (Herxheimer) considerably less lipids were demonstrable and these were mainly present within the air spaces. No sudanophil material was demonstrable in paraffin sections.

Okatomo's reaction for phospholipids (Ueda, 1952) and that with copper-phthalocyanine (Pearse, 1955) were both negative but the Smith-Dietrich method stained a few alveolar macrophages black. With Nile-blue sulphate on frozen sections some of the cells in the air spaces stained dark blue but none red. With the benzidine reaction haemoglobin was demonstrable only in the red cells of the blood vessels. Haemosiderin was present in small amounts in groups of mononuclear cells within the air spaces and only occasionally in interalveolar septa. Treated with P.A.S. the ground substance of the interstitial tissue stained pale pink and a strong reaction was present only in some of the foamy macrophages. This reaction was blocked by acetylation and reversible by KOH treatment. Acid mucopolysaccharides were demonstrable by Rinehart's modification of the Hale method only in a few epithelial cells lining bronchi and bronchioli. None were demonstrable with mucicarmine. With coupled tetrazonium the pale eosinophilic material in some of the air spaces stained pale reddish-brown. Only in a very few places Gram-positive cocci were demonstrable. Pulmonary arterioles of less than 100μ diameter showed a distinct muscular media (Fig. 7) and those of 200μ external diameter had a wall of 50μ in thickness (Fig. 8) (external to internal diameters 2:1 instead of normal 1.2-1.4:1). Elastic fibres in the interalveolar septa were even for this age scanty and a few were fragmented. The elastic membranes of pulmonary arteries were normal.

A bacteriological examination, which included cultures on Sabouraud's medium, gave the following results:

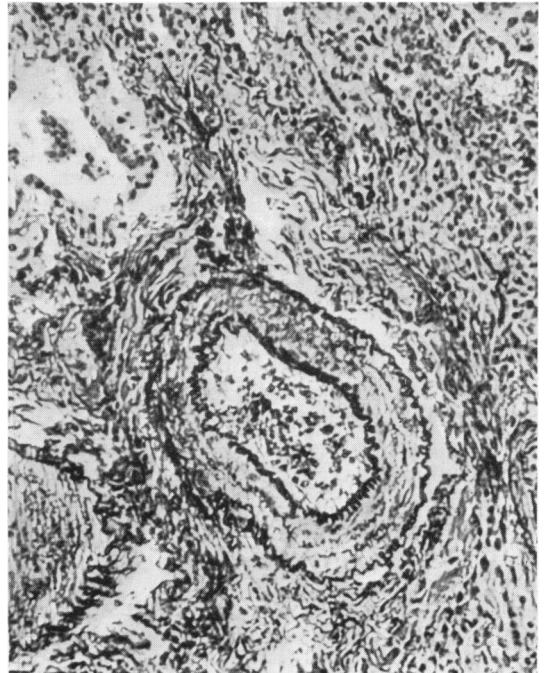

FIG. 8.—Pulmonary arteriole of 200μ diameter showing muscular wall of 50μ diameter. Van Gieson plus elastic tissue stain. $\times 625$.

(1) Pleura, sterile; (2) lungs, a very mixed growth with viridans streptococci, *Proteus*, haemolytic streptococci and *E. coli*, mostly type 086; (3) tonsil, many *Proteus*, *Staphylococcus aureus* and a few *E. coli*, half of which were 086; (4) spleen, a few haemolytic streptococci, *E. coli* and viridans streptococci. After 48 hours a few moniliae were grown from lungs, tonsil and spleen, but none from the pleura. The haemolytic streptococci were not of the Lancefield group A. Virus investigations on the lungs obtained at necropsy were all negative.

The skin of the abdomen was deeply ulcerated with necrotic squamous epithelium, altered blood and pyogenic granulation tissue on the floor but little haemosiderin; the heart showed hypertrophy of muscle fibres of the right ventricle; mediastinal lymph nodes, sinus catarrh; the liver, vacuolation of cytoplasm of the liver cells and congestion with centrilobular haemorrhagic necroses, and the kidneys a few hyaline casts in the collecting tubules.

Discussion

The clinical course of the disease and the histopathological findings fulfil all the criteria described by Hamman and Rich. Reviewing the literature and our own case we would summarize the characteristic findings as follows: The onset is sometimes acute but more often insidious and preceded by a productive or non-productive cough of some duration. Fever is in the beginning usually absent and the main symptom is increasing respiratory distress followed by cyanosis. Clubbing of fingers and toes was present in the majority of cases. The physical findings over the lungs are strikingly scarce, they may be absent or scattered rales may be heard but dullness is absent. In most cases there develops an enlargement of the heart associated with an accentuation of P_2 . According to Peabody, Peabody, Hayes and Hayes (1950) the more acute the case the greater the tendency for cor pulmonale to develop. A radiological examination reveals a diffuse mottling or a striking reticulation of both lung fields, not unlike that seen in pneumoconiosis. The symptoms increase progressively and all the reported cases have died after a duration of a few weeks to several years except for the identical twin-sister of a fatal case described by Peabody *et al.* (1950)—who showed suggestive clinical symptoms but was still alive at the time of publication. Pathologically there is a diffuse involvement of all lobes of both lungs although there are differences in the age of the lesion in various areas. Younger and older lesions are irregularly distributed throughout both lungs, except possibly that subpleural lesions appear older. Changes differing in age merge into each other and are never sharply demarcated. Everywhere there is a broadening of the interstitial tissue which is more severe in the interalveolar septa

than in the peribronchiolar and peribronchial areas, apparently decreasing in a centripetal direction. The broadening in the younger lesions is due to infiltration with large mononuclear cells, lymphocytes and plasma cells. In older lesions there is a fibroblastic proliferation. Argentaffine fibres are everywhere in the interstitial tissue abundant and collagenous fibres are frequently present in the interalveolar septa. A lymphocytic peribronchial infiltration is inconstant and not conspicuous, and follicle formation rare. The alveoli are lined by a cuboid modified epithelium; they are either empty or contain alveolar macrophages. Fibrin and organized intra-alveolar exudate may be absent or scanty and there is no relationship between the interstitial fibrosis and the presence or degree of organization of intra-alveolar exudate. Inflammatory changes in the bronchi and bronchioles, including ulceration and mural cellular infiltration, may be absent and are never a conspicuous feature. Hyaline membranes, mainly in the terminal bronchioles, were present in almost all cases. Their absence is mentioned occasionally. Here and there bronchioles may be dilated without destructive changes in the walls. These may be interpreted as minute traction bronchiectases. Vascular changes characteristic of pulmonary hypertension were repeatedly described. In our case they consisted of the development of a muscular media in arterioles less than 100μ in diameter. This change was recently studied by Heath and Whitaker (1956) in mitral stenosis (Heath and Whitaker, 1955a), patent ductus arteriosus (Heath and Whitaker, 1955b), Eisenmenger's complex (Brown, Heath and Whitaker, 1955), septal defect (Heath, Brown and Whitaker, 1956a) and idiopathic pulmonary hypertension (Heath, Brown and Whitaker, 1956b). According to these authors 'the earliest signs of pulmonary hypertension in the pulmonary vasculature is the appearance of a muscular media in pulmonary arterioles which normally show no distinct media in human lung'. In addition there was in our case a definite muscular hypertrophy of somewhat larger pulmonary arteries. Proliferation of the subendothelial connective tissue of the intima was absent but is occasionally mentioned in the literature.

The reports in the literature correspond principally to this description and vary mainly in inflammatory changes in bronchioles and the presence of organized exudate in the alveoli which may form 'Masson-like bodies'. An exception is the 35-year-old man reported by Callahan, Sutherland, Fulton and Kline (1952). Here the photomicrographs show in addition to interstitial fibrosis the air spaces filled with honeycombed material like that seen in

pneumocystis pneumonia. It is possible that this is a rare example of pneumocystis infection in an adult; on the other hand the infant described by Donohue (1956) as interstitial plasmacellular pneumonia, where the author stressed the absence of the characteristic pneumocystis masses, may be an example of early progressive interstitial fibrosis of the lungs in childhood, although the author does not mention the presence of fibroblasts or collagenous fibres in the broadened interalveolar septa.

It appears to us that as long as the aetiology of the disorder is unknown, progressive interstitial fibrosis of lungs should be separated from chronic organizing pneumonia. Usually the latter condition is lobar or lobular and not diffuse, affecting uniformly

both lungs. Exceptionally, however, the clinical syndrome may be undistinguishable from that described by Hamman and Rich and the post-mortem examination may reveal a uniform affection of both lungs. However, most alveoli are filled with an organized exudate which frequently is connected by a pedicle with the fibrotic interalveolar septum (Fig. 9). We had the opportunity of seeing two such cases (both in adults), one studied by Dr. Kurrein (1956), the other by Professors Arnott and Orr (1956). It is possible that Case 1 of Schechter (1953) is also an example of a chronic diffuse pneumonia with organization of intra-alveolar exudate.

The differentiation of progressive interstitial fibrosis of the lungs from the majority of pulmonary diseases in childhood will rarely present difficulties. Bronchiectasis will be readily diagnosed with the help of x-ray examination and bronchography. It is lobar or segmental, the bronchi are dilated or collapsed, filled with purulent exudate and surrounded by conspicuous yellowish-white rings of peribronchial infiltration. There is extensive atelectasis, areas of fibrosis replacing destroyed lung parenchyma and lymphoid hyperplasia with formation of follicles with large germinal centres. The bronchi show ulceration and mural infiltration.

Pulmonary haemosiderosis can be easily differentiated by the presence of anaemia, frequently with splenic enlargement, haemoptysis, and, in the post-mortem examination, by the brown induration of lungs, masses of macrophages laden with haemosiderin and fragmentation of elastic fibres. Pneumocystis pneumonia is usually a disease of young infants aged 2-6 months. It mainly affects premature infants. The demonstration of the parasite in histological sections and particularly in imprints is decisive. Nowhere in progressive interstitial fibrosis of the lungs are such masses of P.A.S.-positive material seen as in pneumocystis pneumonia. Monocytic interstitial pneumonia is a common disease of young infants, particularly in congenital heart disease, and is often diagnosed only by histological examination. Syphilitic pneumonia alba, which affects exclusively newborn infants, will be easily diagnosed by the presence of other syphilitic manifestations and the demonstration of *Treponema pallidum*. 'Atypical pneumonia' is a comparatively benign disease, and does not show the progression characteristic of the 'Hamman-Rich syndrome' or the development of cor pulmonale and finger clubbing. The histological changes were studied on a large amount of material by Golden (1944). The most characteristic lesion consisted of frank pus, desquamated cells of the mucous membranes,

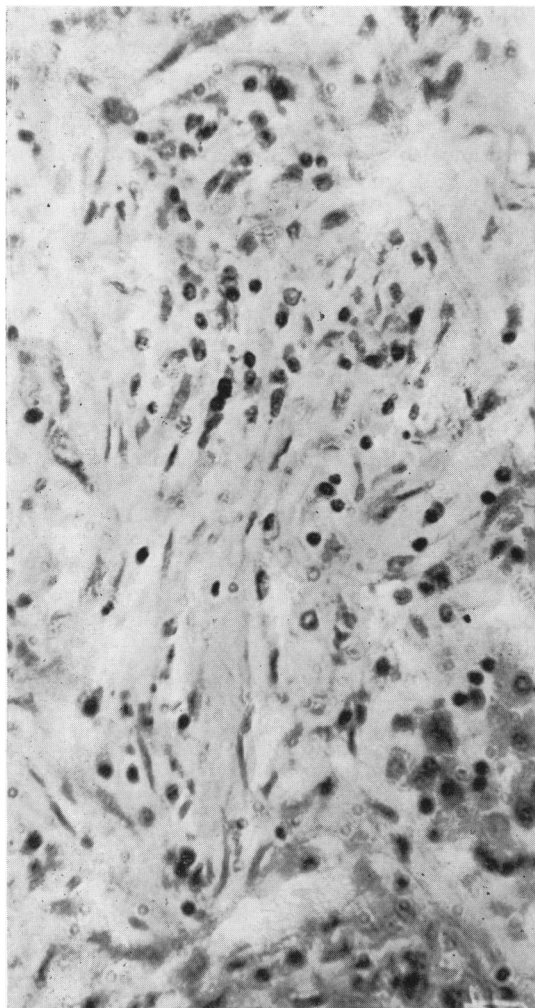


FIG. 9.—Diffuse organizing pneumonia (Dr. Kurrein's case). Haematoxylin and eosin. $\times 192$.

cellular debris and mucoid fluid in the bronchiolar lumina. The bronchiolar walls were constantly ulcerated. The interstitial changes were centrifugal from peribronchiolar tissue into the interalveolar septa. The atypical bronchopneumonia studied by Kneeland and Smetana (1940) showed in the early stages haemorrhagic exudate in the alveoli with normal septa and a tendency to organization of this exudate. The interstitial bronchopneumonia described by Cole and McCallum (1918) complicates fatal cases of influenza, measles and whooping cough. It has been likened by McCordock and Muckenfuss (1933) to the pulmonary changes in rabbits which were intrapulmonally injected with vaccinia virus. In human material of fatal whooping cough the changes consist mainly of mural bronchitis, peribronchitis and peribronchiolitis as described by Feyrter (1927) with less constant and marked involvement of interalveolar septa. In measles there are in addition epithelial giant cells (not pathognomonic). In this disease and some cases of atypical pneumonia acidophilic inclusion bodies may be found. The changes in fibrocystic dystrophy of the pancreas (which is clinically easily differentiated) differ from those in fatal whooping cough only by the greater tendency to the formation of peribronchial abscesses.

A rare disease which may simulate progressive interstitial fibrosis of the lungs is carcinoma of the thymus with retrograde lymphogenous spread into the lungs (Baar, 1954). A radiological examination will often, but not always, reveal the thymic tumour. The morbid anatomical diagnosis will present no difficulty. Lungs may be involved in reticulosis of the Letterer-Siwe type, in sarcoidosis and also in Hodgkin's disease, but manifestations from organs other than the lungs will rarely present clinical diagnostic difficulties and the histological appearance of each of these diseases is entirely different from that of progressive interstitial fibrosis of the lungs.

Changes very similar to those of progressive interstitial fibrosis of the lungs are seen in 'rheumatic pneumonia' and pulmonary manifestations of rheumatoid arthritis (Ellman and Ball, 1948). Rheumatic pneumonia is in most instances not a specific disease but a bronchopneumonia which develops in atelectatic lungs, mainly in the lower lobe of the left lung, in the presence of cardiac failure. Masson bodies may represent organized intra-alveolar exudate but in some instances they develop in the interalveolar septa and are associated with fibrinoid necrosis of connective tissue and accompanied by interalveolar fibrosis. According to Gouley (1938) and to Neubuerger, Grieves and

Rutledge (1944) the rheumatic pneumonia develops in three stages: (1) fibrinoid necrosis of collagen in the interalveolar septa, (2) infiltration with round cells, plasma cells and giant cells, (3) fibroblastic proliferation and fibrosis.

Great difficulties may be encountered in the clinical differential diagnosis between progressive interstitial fibrosis of the lungs on one hand and cardiac disease or 'idiopathic pulmonary hypertension' on the other. Silverman and Talbot (1953) made the definite diagnosis *in vivo* with the help of a lung biopsy.

The aetiology of the disorder is at the present time a matter of speculation. Most writers favour a virus aetiology (Spain, 1950) but a non-inflammatory disease related to collagen diseases has also been suggested. Golden and Bronk (1953) consider a 'progressive diffuse alveolar hypertrophy of reticulo-angiotic type' as characteristic. No vascular proliferation was present in our case. It appears by no means certain that there is always the same cause. Different causes are suggested by the case reported by Callahan *et al.* (1952), where, in addition to interstitial fibrosis, there were intra-alveolar masses suggestive of *Pneumocystis carinii*. Proliferative changes in the interalveolar septa are in this condition often reported in the continental European literature. It is therefore possible that the progressive interstitial fibrosis of the lungs is a clinico-pathological but not an aetiological entity.

Summary

The second example of progressive interstitial fibrosis of the lungs in a child and the first in early childhood is described. The differential diagnosis, the morbid anatomical and histopathological differences between progressive interstitial fibrosis of the lungs and clinically and/or histologically similar disorders and finally the possible aetiology are discussed.

We wish to thank Dr. K. B. Rogers for the haematological and bacteriological investigations, Dr. Clifford Parsons for the electrocardiographic examination, Dr. R. Astley for the x-ray reports, Mr. A. R. Detheridge for technical help and Mr. J. G. Williamson for the photographs.

REFERENCES

- Arnott, W. M. and Orr, J. (1956). Personal communication.
 Baar, H. S. (1954). *Öst. Z. Kinderheilk.*, 10, 2.
 Beams, A. J. and Harnos, O. (1949). *Amer. J. Med.*, 7, 425.
 Bradley, C. A. (1956). *J. Pediat.*, 48, 442.
 Brown, J. W., Heath, D. and Whitaker, W. (1955). *Brit. Heart J.*, 17, 273.
 Callahan, W. P. Jr., Sutherland, J. C., Fulton, J. K. and Kline, J. R. (1952). *Arch. intern. Med.*, 90, 468.
 Clough, P. W. (1954). *Ann. intern. Med.*, 40, 641 (Editorial).
 Cole, R. and McCallum, W. G. (1918). *J. Amer. med. Ass.*, 70, 1153.
 Donohue, W. L. (1956). *Lab. Invest.*, 5, 97.
 Ellman, P. and Ball, R. E. (1948). *Brit. med. J.*, 2, 816.

- Feyrter, F. (1927). *Frankfurt. Z. Path.*, 35, 213.
- Golden, A. (1944). *Arch. Path. (Chicago)*, 38, 187.
- and Bronk, T. T. (1953). *Arch. intern. Med.*, 92, 606.
- Gouley, B. A. (1938). *Amer. J. med. Sci.*, 196, 1.
- Hamman, L. and Rich, A. R. (1944). *Bull. Johns Hopk. Hosp.*, 74, 177.
- Heath, D., Brown, J. W. and Whitaker, W. (1956a). *Brit. Heart J.* 18, 1.
- , —, — (1957). *Ibid.* 19, 83.
- and Whitaker, W. (1955a). *J. Path. Bact.*, 70, 291.
- , — (1955b). *Ibid.*, 70, 285.
- , — (1956). *Circulation*, 14, 323.
- Heppleston, A. G. (1951). *Thorax*, 6, 426.
- Kneeland, Y. Jr. and Smetana, H. F. (1940). *Bull. Johns Hopk. Hosp.*, 67, 229.
- Kurrein, F. (1956). Personal communication.
- McCordock, H. A. and Muckenfuss, R. S. (1933). *Amer. J. Path.*, 9, 221.
- Neuburger, K. T., Geever, E. F. and Rutledge, E. K. (1944). *Arch. Path. (Chicago)*, 37, 1.
- Peabody, J. W., Peabody, J. W. Jr., Hayes, E. W. and Hayes, E. W. Jr. (1950). *Dis. Chest.*, 18, 330.
- Pearse, A. G. E. (1955). *J. Path. Bact.*, 70, 554.
- Schechter, M. M. (1953). *Amer. Rev. Tuberc.*, 68, 603.
- Silverman, J. J. and Talbot, T. J. (1953). *Ann. intern. Med.*, 38, 1326.
- Sloper, J. C. and Williams, E. (1955). *Lancet*, 2, 533.
- Spain, D. M. (1950). *Ann. intern. Med.*, 33, 1150.
- Ueda, M. (1952). *Hyogo J. med. Sci.*, 1, 117.