

Localization and retention of mycobacterial antigen in lymph nodes of leprosy patients

U. Barros, U. Ladiwala, T.J. Birdi and N.H. Antia

The Foundation for Medical Research, 84-A, R.G. Thadani Marg, Worli, Bombay-400018, India

Received for publication 18 December 1986

Accepted for publication 16 April 1987

Summary Although leprosy, a chronic disease caused by *M. leprae*, primarily affects skin and peripheral nerves, pathological changes and granulomas have been observed in lymph nodes which are: (a) present in tuberculoid lymph nodes in the absence of acid-fast bacilli and (b) persistent in lepromatous patients even after prolonged treatment.

We detected substantial amounts of mycobacterial antigen in 16 leprosy lymph nodes using anti-BCG by the peroxidase anti-peroxidase method. The load and distribution of antigen varied along the spectrum and with the duration of treatment.

Tuberculoid and long-term treated lepromatous lymph nodes had a similar distribution of antigen in clusters of cells giving a 'speckled' appearance. The untreated lepromatous had a 'diffuse' staining of antigen in foamy histiocytes whereas lepromatous lesions with a lower bacillary load had a mixed pattern of 'diffuse' and 'speckled'.

Antigen was also detected in a number of plasma cells along the spectrum but predominantly in lepromatous lymph nodes.

Our observations indicate that: (a) antigen exists in lymph nodes despite prolonged chemotherapy which may be responsible for the persistent granuloma and (b) antigen is not confined to any particular anatomical compartment of the lymph node.

Keywords: leprosy, lymph nodes, mycobacterial antigen, immunoperoxidase

Leprosy, a chronic disease caused by *M. leprae* is characterized by a clinico-immunopathological spectrum ranging from the high resistance paucibacillary tuberculoid leprosy, through a range of borderline forms, to a low resistant multibacillary lepromatous form. Though the primary manifestations of this disease are seen in skin and nerve lesions, pathological changes have also been observed in lymph nodes of these patients (Desikan & Job 1966; Turk & Waters 1971).

The lymph node plays a central role in the immune response. It provides an efficient network where antigen and immunologi-

cally relevant cells can meet and initiate the induction of immunity (Fossum & Ford 1985). Simultaneously, excess antigen is removed from circulation thus preventing tolerance. The lymph node is also involved in the induction and maintenance of memory (Klaus *et al.* 1980). Thus any pathology in the lymph node would have far reaching consequences on the individual's immune response.

In leprosy, the pathology in the lymph nodes has been correlated mainly with the acid-fast bacillary load and the clinico-immunological status of the patient (Turk &

Waters 1971). There has however been no explanation for the persistence of the granuloma in patients with prolonged anti-leprosy treatment where no acid-fast mycobacterial material can be detected. Neither has an attempt been made to correlate the persistent lymph node pathology with the long lasting anergy of lepromatous patients to *M. leprae*. Recently, a number of studies on skin and nerve lesions have demonstrated the presence of abundant *M. leprae* antigen cross-reacting with anti-BCG, in the absence of demonstrable acid-fast bacilli (Mshana *et al.* 1983; Ridley 1983; Antia *et al.* 1985; Barros *et al.* 1987). The presence of similar antigen in the lymph nodes may partially explain the persistence of granulomas in long-term treated 'cured' patients. Besides, in treated patients this antigen(s) may participate in the induction and maintenance of memory.

Since the pathways of lymphocyte migration through the lymph node are intricate, a granuloma within may also disrupt lymphocyte traffic and result in sequestration of lymphocytes. The persistence of antigen not detected by acid fast staining may provide one possible explanation for the continued lymphocyte sequestration seen in lepromatous leprosy by Bullock (1976).

Thus, the study of detecting *M. leprae* antigens not visualized by acid-fast staining in lymph nodes from patients at both ends of the spectrum, and especially in treated cases, gains increasing importance. This study was therefore designed to detect the presence and localization of antigen in lymph nodes, not stained by the standard Carbol-Fuchsin stain, using anti-BCG antibody by the immunoperoxidase technique.

Materials and methods

Patients were classified according to the Ridley and Jopling classification (Ridley & Jopling 1966), based upon a combination of clinical findings, lepromin, skin smears and, skin histology. The duration of the disease and the treatment varied as shown in Table 1. The patients had undergone a thor-

ough clinical examination and investigations including a chest X-ray.

A total of 21 lymph nodes were included in this study. Eight nodes were from seven patients in the tuberculoid part of the spectrum while nine nodes were from the same number of patients in the lepromatous part. Four lymph nodes from individuals without any mycobacterial infection, served as controls. In addition a human plasmacytoma biopsy, was also used as a control.

All biopsies had been fixed in Formal Zenker solution and processed as for routine histology. Sections 4–5 μm thick were cut and stained for acid-fast bacilli by the modified Triff method of Ridley (1977). Adjacent sections of the same thickness were stained for the detection of antigen with anti-BCG, by the immunoperoxidase method. The peroxidase-anti-peroxidase (PAP) method of Sternberger *et al.* (1970), was modified as follows. On dewaxing, endogeneous peroxidase was blocked with 3% hydrogen peroxide (H_2O_2) and non-specific receptor binding by normal swine-serum (DAKO Cat. No. X901). The sections were then incubated overnight at 4°C with rabbit anti-BCG (DAKO-B124) in a dilution of 1:100. On washing with Tris-HCl buffer, the sections were treated with a 1:50 dilution of unlabelled swine anti-rabbit serum (DAKO-Z-196), washed again and incubated with a 1:50 dilution of PAP complex (DAKO Z-113), for 30 min. After a thorough wash, the colour reaction was developed using 3,3'-diaminobenzidine (DAB), with H_2O_2 as substrate. All DAKO reagents were obtained from DAKOPATTS-Denmark.

Sections incubated with irrelevant antibody (Rabbit anti-sheep red blood cells) instead of the primary antibody (anti-BCG), served as an experimental control.

Results

Controls

The four lymph nodes of non-lepromatous individuals showed no evidence of anti-BCG

Table 1.

Sr. No.	Classification	Age	Sex	Lepromin	Skin smears	Duration of disease	Duration of treatment
1	TT/BT	25	M	6 mm	-ve	12 years	1 month
2	BT	35	M	8 mm	-ve	2 years	2 months
3	BT	50	M	Not read	-ve	6 years	1 year
4	BT/BB	11	M	4 mm	-ve	1.5 years	1 year
5	BT/BB	18	M	3 mm	-ve	5 years	3 years
6	BT/BB	19	M	5 mm	-ve	7 years	Untreated
7	BB/BT	11	M	5 mm	-ve	1 year	4 months
8	BL/BB	14	F	4 mm	-ve	5 years	5 years
9	BL	17	M	Not read	+ve	1 year	1 year
10	BL	40	M	-ve	-ve	24 years	24 years
11	BL	50	M	-ve	+ve	30 years	15 years
12	BL	51	M	-ve	-ve	28 years	20 years
13	BL	21	M	-ve	+ve	8 years	8 years
14	BL	26	M	-ve	+ve	2 years	1.5 years
15	BL/LLs	24	M	-ve	+ve	9 years	2-3 years
16	LLs	23	M	-ve	+ve	20 years	3 years

TT Tuberculoid leprosy. BT Borderline tuberculoid. BB Mid-borderline. BL Borderline lepromatous. LLs Lepromatous subpolar.

activity. The plasmacytoma as well as the controls with irrelevant antibody, revealed the absence of brown precipitate thus ruling out non-specific staining.

Tuberculoid lymph nodes

Almost all the lymph nodes showed the presence of infiltrate, mainly in the paracortical regions, as discrete granulomata of epithelioid cells. These were usually separated by broad strands of lymphocytes. In some nodes, Langhans' giant cells were present in the infiltrate. In the nodes of patients closer to the borderline spectrum, some of the cells were less typical; they appeared only slightly epithelioid, the nuclei being more oval and the cytoplasm less elongated with well defined borders.

In one case where there was an absence of infiltrate, the paracortex was wide and densely populated by lymphocytes (case 1).

The general architecture of these lymph nodes was otherwise quite unremarkable,

in that the lymphoid follicles did not show any proliferation; nor were plasma cells increased in the medullary cords. The subcapsular and medullary sinuses did contain moderate numbers of cells—mainly lymphocytes, monocytes and macrophages.

Although no acid-fast bacilli were seen in any of these lymph nodes, immuno-peroxidase staining using anti-BCG demonstrated the presence of antigen in all the lymph nodes (Table 2).

This antigen appeared to be localized in individual cells or in small clusters of three to seven cells evenly distributed all over the section and not confined to any particular anatomical compartment, giving a 'speckled' appearance to the lymph node (Fig. 1).

Each such cluster consists of central membrane bound antigen surrounded by positively stained cells (Fig. 2). It was difficult to determine the identity of the central cell or the precise cellular location of this antigen.

The overall anti-BCG positivity of the lymph node varied with duration of treat-

Table 2. Tuberculoid lymph nodes

Patient	1	2a (d)	2b (n.d.)	3	4	5	6	7
Overall positivity	+	+++	+	+++	+	+	+++	++
Subcapsular sinus	-	±	-	-	-	-	+	-
Follicles								
(a) Mantle	+	++	+	+	+	+	++	+
(b) G.C.	±	++	±	+	-	+	±	±
Paracortex	+	++	+	++	+	++	++	++
Medullary cords	+	+	±	+	+	+	+	+
Medullary sinus	-	-	-	-	-	-	-	-

GC Germinal centre. d Draining. n.d. Non-draining.

ment, the maximum being in the untreated patient (case 6).

Greater numbers of positive clusters were present in the paracortex, in the periphery of germinal centres and the surrounding mantle of the lymphoid follicles. In the medulla

although a few clusters were present, most of the positivity was seen to be intracellular, in scattered single plasma cells.

In case 2 where both draining and non-draining lymph nodes were biopsied, the antigenic load was significantly higher in the

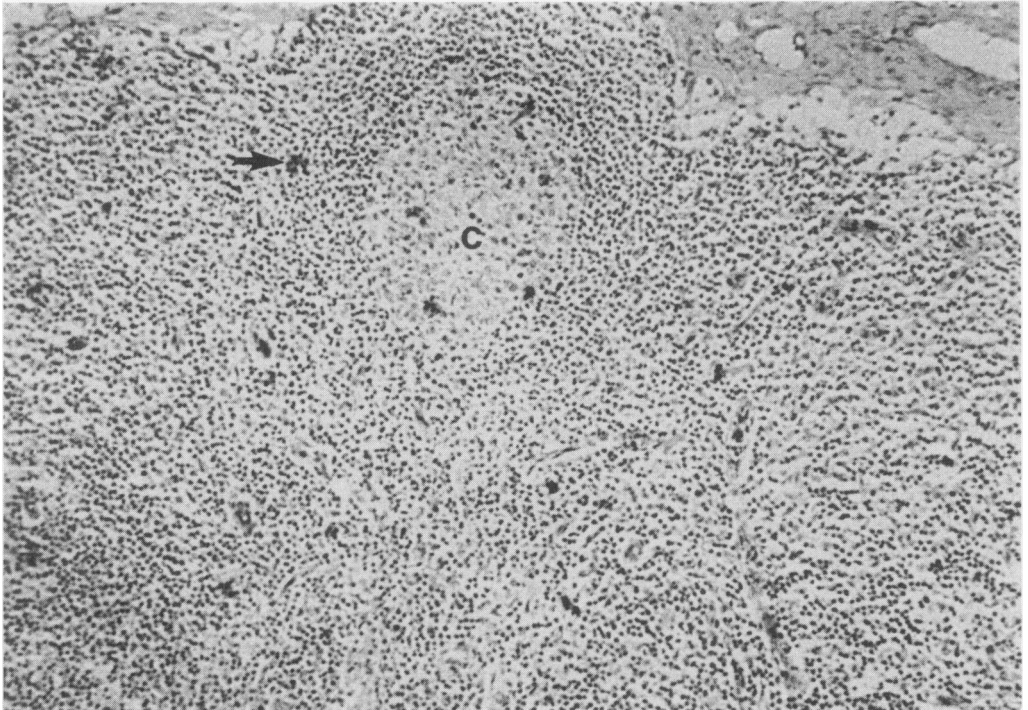

Fig. 1. A tuberculoid leprosy lymph node showing deposits of antigen (→) dispersed throughout the section in a 'speckled' appearance. Note the presence of antigen in the germinal center (C). $\times 130$.

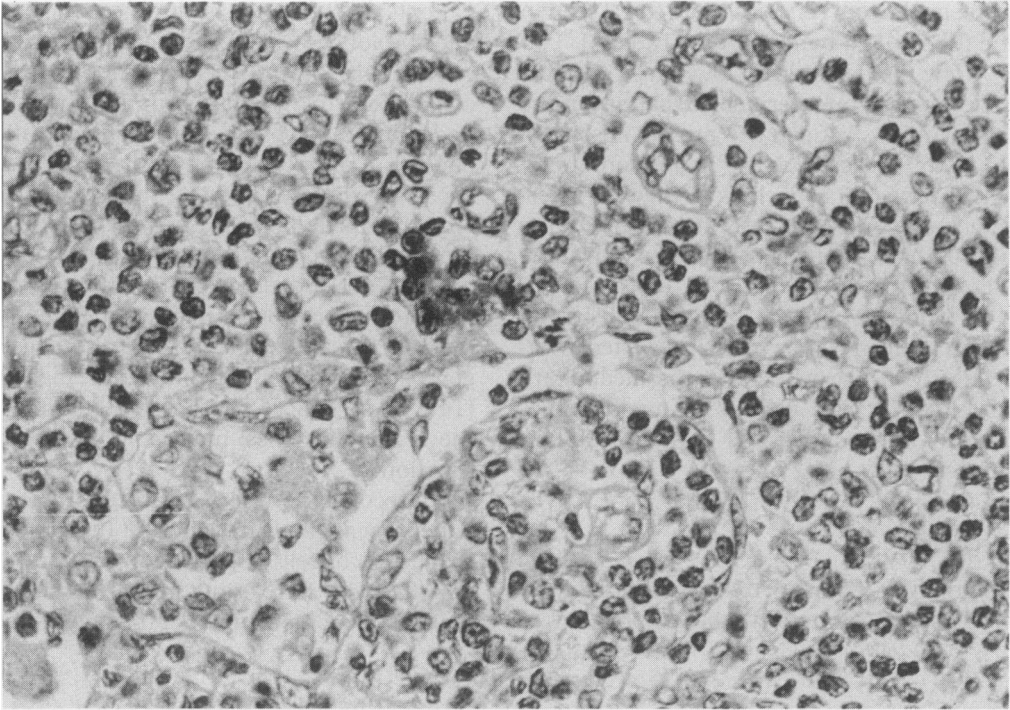


Fig. 2. A higher magnification of a single cluster of cells with antigen whereas surrounding cells are clear. $\times 630$.

draining lymph node although the pattern of antigen distribution was similar in the non draining one.

Lepromatous lymph nodes

Foamy histiocytes, which are characteristic of lepromatous leprosy, formed sheets infiltrating vast areas of the paracortex, sometimes extending upto the lymphoid follicles in the cortex, or down to the deeper regions of the medulla, in these lymph nodes. A few lymphocytes were diffusely scattered between the foamy histiocytes.

Patients who had received prolonged anti-lepromous therapy, showed typical cells with large vacuoles, many of which were multinucleated giant cells.

Lymphoid follicles in most cases were not enlarged or increased in numbers. However, there was usually, a moderate increase in the

numbers of medullary plasma cells.

Acid-fast bacillary load varied in these lymph nodes. Bacilli were usually present in the foamy histiocytes as solid forms, singly or as globi, and at times fragmented. A few macrophages containing AFB were seen occasionally in the subcapsular sinuses. It was remarkable that even in those cases where successful treatment had resulted in complete bacterial clearance, the histiocytic granuloma persisted in these lymph nodes.

In the bacillary positive lepromatous cases intense immuno-peroxidase staining was seen in the foamy cells of the infiltrate, usually corresponding to the acid-fast bacillary load (Fig. 3)—a pattern we designated as 'diffuse', as opposed to 'speckled'—seen in patients where efficacy of treatment had resulted in bacterial clearance. In these bacteriologically negative lymph nodes, antigen was surprisingly seen outside the infil-

trate, in clusters very similar to those seen in the tuberculoid lymph nodes (Table 3).

A few patients with a low bacteriological index showed an intermediate pattern in the lymph nodes. Antigen was present in some of the foamy cells (probably those containing acid fast bacilli) as well as in the characteristic lymphocyte clusters described in the histopathology of tuberculoid lymph nodes (Fig. 4).

In contrast to the tuberculoid lymph nodes, antigen was frequently detected intracellularly in plasma cells in the medullary cords (Fig. 5), as well as in macrophages within the subcapsular and medullary sinuses.

Discussion

A significant feature of the present study was the presence of antigen in the lymph nodes of

patients at both ends of the spectrum even after prolonged anti-leprosy treatment. It is conceivable that this persistence of antigen could be due to the continuous influx into the node but our observation of the relative paucity of antigen bearing cells in the subcapsular sinuses, refutes this possibility. Since the medullary sinuses were also free of antigen, it is apparent that the antigen laden cells are not actively migrating through the lymph node but appear to be fixed. Retention of antigen is also known to contribute to the generation and maintenance of memory (Tew *et al.* 1980). The antigen detected in these lymph nodes may serve a similar function.

A second pertinent feature in these patients was the localization of this antigen in clusters of cells scattered throughout the lymph node. It was not restricted to any anatomical compartment of the lymph node

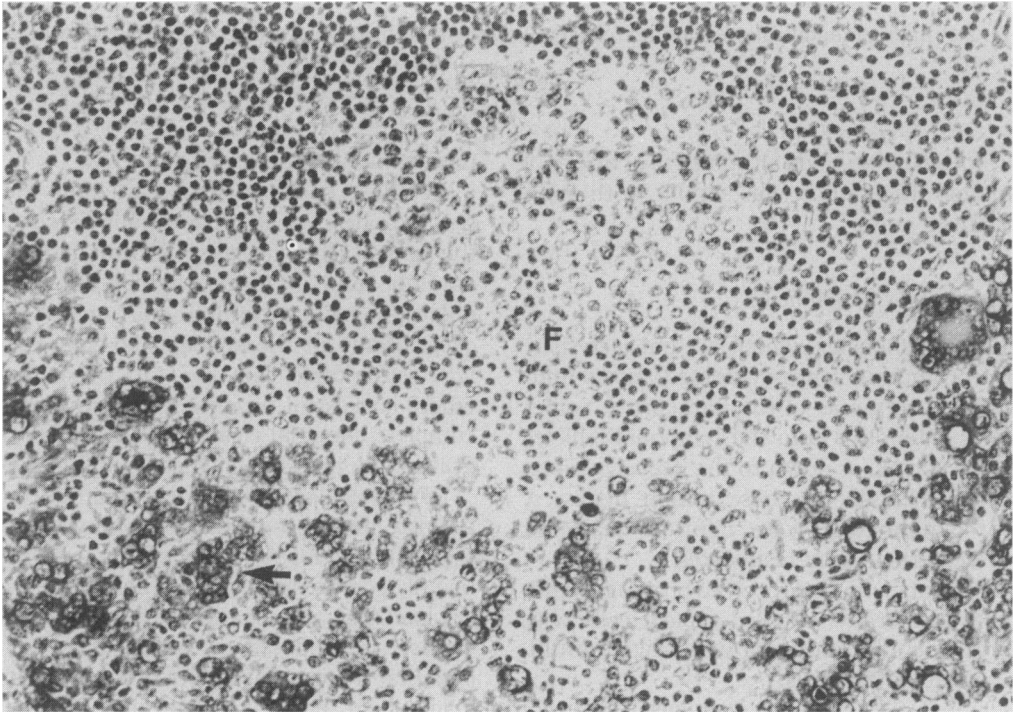


Fig. 3. A lepromatous lymph node showing antigen present in foamy histiocytes (→) in a 'diffuse' pattern. Antigen is absent in the follicles (F), $\times 312$.

Table 3. Lepromatous lymph nodes

Case No.	8	9	10	11	12	13	14	15	16
Overall D	-	+++	-	+	-	+++	+++	-	+++
positivity S	++	-	+++	++	++	+	+	+	+
Subcapsular sinus	±	+	-	+	-	+	+	-	+
Follicles									
(a) Mantle	+	-	++	+	+	++	-	+	+
(b) G.C.	+	-	+	(±)	+	+	-	-	-
Paracortex I	-	+++	-	+	-	+	++	-	++
OC	+	-	++	+	++	+	+	+	+
Medullary cords	+	+	++	+	+	+	+	++	+
Medullary sinus	+	-	+	-	-	+	+	-	+

D Diffuse. S Speckled. I Infiltrate. GC Germinal centre. OC Other cells.

and was seen in both T- and B-cell areas. This study does not provide direct evidence whether the antigen detected by anti-BCG is capable of stimulating lymphocytes. However, in the event that it does, then the well

spread distribution may indicate that T- and B-cells are equally stimulated.

Studies carried out in tolerant animals by (Humphrey & Frank 1967) emphasize the requirement of antibody for follicular locali-

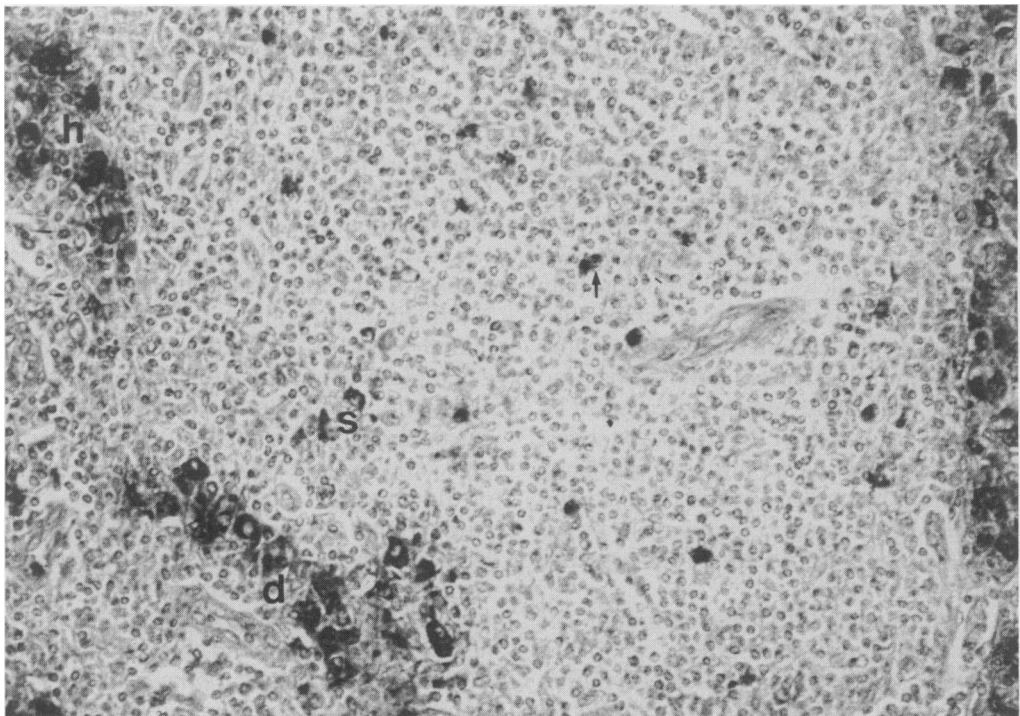


Fig. 4. A short-term treated lepromatous lymph node showing presence of antigen in foamy histiocytes (h) and in cell clusters (→) giving a mixed pattern of 'diffuse' (d) and 'speckled' (s). × 312.

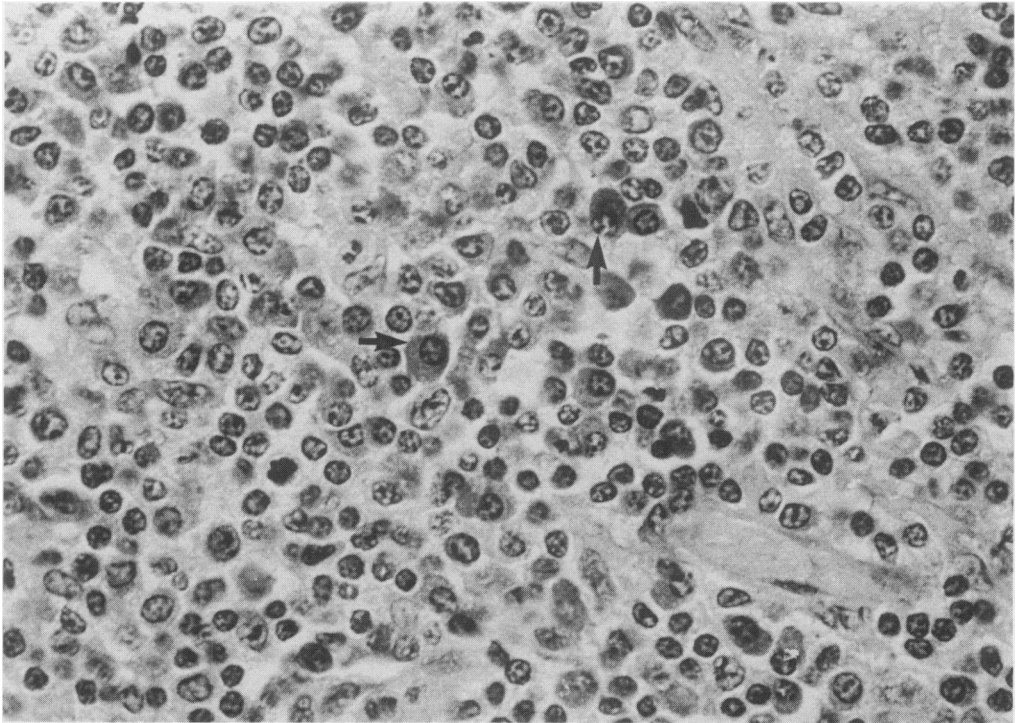


Fig. 5. A lepromatous lymph node with antigen localized in plasma cells (→) of the medulla. $\times 630$.

zation of antigen. In the absence of a humoral response in tolerant animals, no antigen was detected within the follicles. Within this context therefore our findings of antigen free follicles, in bacteriologically positive lepromatous patients is remarkable, particularly since excessive antibody production is a hallmark of lepromatous leprosy and also since the follicles appear surrounded by antigen bearing cells of the histiocyte series. This may imply a role for antibody specificity in dictating the type of antigen retained and presented by antigen presenting cells or the absence of opsonization due to the presence of excessive antigen.

It is conceivable that depending upon the nature of the antigen presenting cell, different antigens are retained and hence lymphocytes of varying specificities are stimulated. The present use of heterologous serum does not allow us to address this question but such

studies are in progress. However, our studies have implicated four cell types involved in the handling of *M. leprae* antigens. Although we must extend our studies to more precise markers for Follicular dendritic cells and Interdigitating dendritic cells, the well dispersed 'speckled' staining nature of the antigen and the appearance that it may be in the extracellular space in association with a cell cluster indicates the possibility that the antigen could be associated and retained by cells of the dendritic cell lineage. Various other studies have also recorded antigen trapping by dendritic cells for prolonged periods in chronic disease states (Klaus *et al.* 1980). In tuberculoid and bacteriologically negative lepromatous patients the absence of antigen in the cells of the macrophage lineage was significant. It appears that while these cells may be important in other functions they are not involved in the long term retention of

mycobacterial antigens. Antigen in these cells is seen only in bacteriologically positive lepromatous patients.

Antigen was also detected within 'plasma cells' with cart-wheel nuclei. At this stage it is difficult to comment on the antigen presenting potential of these positive cells. Generally, the function of antigen presentation is related to Ia expression. Terminally differentiated plasma cells do not express Ia whereas activated B-cells do. We have not identified the differentiation stage of this cell and hence the role of this intracellular antigen remains unclear.

To emphasize, the single most important observation has been the presence of antigen in lymph nodes of long-term treated leprosy patients. Whether this antigen contributes to the generation of memory and/or in the faulty trafficking of cells is under further study.

Acknowledgements

We wish to thank Harish Poojari for skilful technical assistance and Venu Nair for typing of the manuscript. We gratefully acknowledge the financial assistance provided by LEPROA.

References

- ANTIA N.H., BARROS U. & SHETTY V.P. (1985) Demonstration of *M. leprae* and *M. leprae* antigens in nerves of tuberculoid patients. *IRCS Med. Sci.* **13**, 914-915.
- BARROS U., SHETTY V.P. & ANTONIA N.H. (1987) Demonstration of *Mycobacterium leprae* antigen in nerves of tuberculoid leprosy. *Acta Neuropath.* In press.
- BULLOCK W.E. (1976) Perturbation of lymphocyte circulation in experimental murine leprosy. II. Nature of the defect. *J. Immunol.* **117**, 1171-1178.
- DESIKAN K.V. & JOB C.K. (1966) Leprous lymphadenitis—Demonstration of tuberculoid lesions. *Int. J. Leprosy*, **34**, 147-154.
- FOSSUM S. & FORD W.L. (1985) The organization of cell populations within lymph nodes: their origin, life history and functional relationships. *Histopathology*, **9**, 469-499.
- HUMPHREY J.H. & FRANK M.M. (1967) The localization of non-microbial antigens in the draining lymph nodes of tolerant, normal and primed rabbits. *Immunology*, **13**, 87-100.
- KLAUS G.G.B., HUMPHREY J.H., KUNKL A. & DONGWORTH D.W. (1980) The follicular dendritic cell: Its role in antigen presentation in the generation of immunological memory. *Immunol. Rev.* **53**, 3-28.
- MANDEL T.E., PHIPPS R.P., ABBOTT A. & TEW J.G. (1980) The follicular dendritic cell: Long-term antigen retention during immunity. *Immunol. Rev.* **53**, 29-59.
- MSHANA R.N., HUMBER D.P., HARBOE M & BELEHU A. (1983) Demonstration of mycobacterial antigens in nerve biopsies from leprosy patients using peroxidase-anti-peroxidase immunoenzyme technique. *Clin. Immunol. Immunopathol.* **29**, 359-368.
- RIDLEY D.S. & JOPLING W.H. (1966) Classification of leprosy according to immunity a five-group system. *Int. J. Leprosy*, **34**, 255-273.
- RIDLEY D.S. (1977) The Biopsy and its preparation. In *Skin Biopsy in Leprosy—Histological Interpretation and Clinical Application*. Basle: Documenta Geigy. Ciba-Geigy Limited. pp. 13-15.
- RIDLEY M.J. (1983) The degradation of *Mycobacterium leprae* by a comparison of its staining properties. *Int. J. Leprosy*, **51**, 211-218.
- STERNBERGER L.A., HARDY P.H., CUCULIS J.J. & MEYER H.G. (1970) The unlabelled antibody enzyme method of immunohistochemistry. Preparation and properties of soluble antigen-antibody complex (horse radish peroxidase-anti-horse radish peroxidase) and its use in the identification of spirochetes. *J. Histochem. Cytochem.* **18**, 315-333.
- TEW T.G., PHIPPS R.P. & MANDEL T.E. (1980) The maintenance and regulation of the humoral immune response: Persisting antigen and the role of follicular antigen-binding dendritic cells as accessory cells. *Immunol. Rev.* **53**, 175-201.
- TURK J.L. & WATERS M.F.R. (1971) Immunological significance of changes in lymph nodes across the leprosy spectrum. *Clin. exp. Immunol.* **8**, 363-376.