

# Inhibition of Granuloma Formation Around *Schistosoma mansoni* Eggs

## V. "Hodgkin's-like Lesion" in SJL/J Mice

Kenneth S. Warren, MD

HODGKIN'S DISEASE has been described as "a peculiar histological alteration of lymphoid tissue that is usually classified as one of the types of malignant lymphoma."<sup>1</sup> Unusual aspects of this neoplastic disease are the occurrence of complicating bacterial, viral, and fungal infections, and an impairment in delayed hypersensitivity.<sup>1,2</sup> A reticulum cell sarcoma has been described in aged SJL/J mice which bears a remarkable morphologic resemblance to the Hodgkin's lesion,<sup>3,4</sup> but as yet we are unaware of any reports of major alterations in immunologic activity in these animals. The present study demonstrates a marked impairment in the ability of SJL/J mice with advanced Hodgkin's-like disease to form granulomas around schistosome eggs, a phenomenon analogous to delayed hypersensitivity.<sup>5</sup>

### Materials and Methods

Female SJL/J "old breeder" mice approximately 40 weeks of age were received from Jackson Memorial Laboratories. Prior to experimentation these animals were maintained an additional 12 weeks, until the first animal died and the postmortem examination revealed the presence of a Hodgkin's-like lesion. A total of 21 animals were studied, as will be described below, in three successive experiments over the next 2-month period; their ages at the time of study ranged between 52 and 60 weeks.

Schistosome eggs were isolated by a method previously described, from the livers of Swiss albino female mice infected for 8 weeks with a Puerto Rican strain of *Schistosoma mansoni*.<sup>6</sup> Each SJL/J mouse was given an injection of 1,000 eggs via a tail vein; 16 days later the lungs were removed, preserved in 10% buffered formalin, sectioned 5  $\mu$  in thickness, and stained with hematoxylin and eosin.<sup>6</sup> From each animal, three sections at least 250  $\mu$  apart, were searched for eggs. The diameters of the eggs and of the reactions around them were measured with a Vicker's A. E. I. image-splitting microscope eyepiece. The mean granuloma diameter for each animal was determined. At the time of lung removal a postmortem examination was performed on each mouse, and the following measurements were

---

From the Departments of Preventive Medicine and Medicine, Case Western Reserve University School of Medicine and University Hospitals, Cleveland, Ohio.

Supported in part by Grants AI 08163-02 and 5K03-A131814, NIH, US Public Health Service.

Accepted for publication May 6, 1969.

Address for reprint requests: Dr. Kenneth S. Warren, Department of Preventive Medicine, Wearn Research Bldg, Case Western Reserve University, Cleveland, Ohio 44106.

recorded: body weight, liver and spleen weights, and the degree of thymus and lymph node enlargement. Serum specimens were collected from all of the animals, and parts of the above-mentioned organs were preserved in 10% buffered formalin for the preparation of tissue sections. The degree of Hodgkin's-like disease, as determined by the above observations, was then correlated with the mean granuloma diameter found in each animal. Antibody formation to schistosome eggs was determined by a passive hemagglutination method, developed by Dr. D. L. Boros in this laboratory, using glutaraldehyde-fixed sheep red blood cells which were sensitized with antigens extracted from *S. mansoni* eggs.<sup>7</sup>

The effect of Friend virus leukemia on granuloma formation around schistosome eggs was then studied in DBA/2 female mice obtained from Jackson Memorial Laboratories. The experiment consisted of four groups of 6 mice each: one group was not exposed to the virus while the others were inoculated with 1000 leukemia-producing doses of Friend virus at 28, 19, and 7 days prior to removal of the lungs, which terminated the study. Each group of mice had received injections of 1000 schistosome eggs 16 days before lung removal. Thus, the three groups of animals with Friend virus leukemia were exposed to the virus 12 and 3 days prior to, and 9 days after, injection of schistosome eggs into the lungs.

## Results

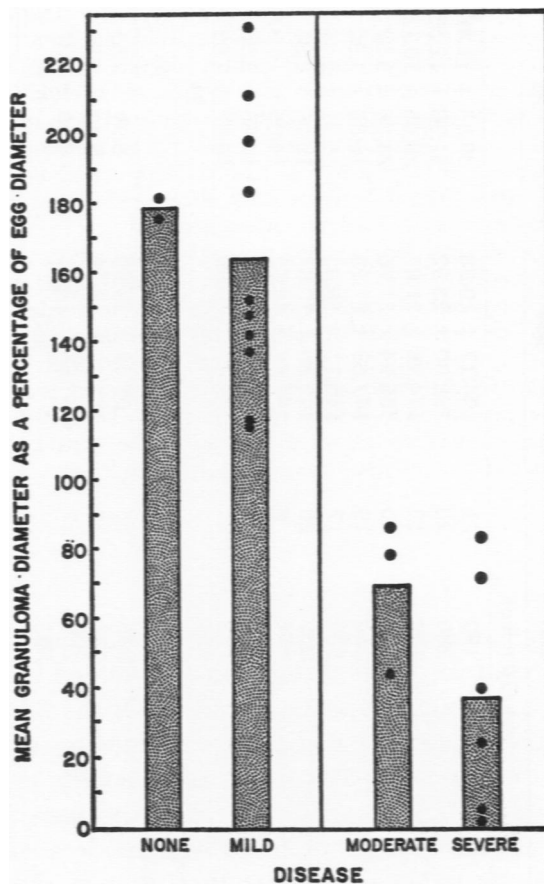
### Hodgkin's-like Disease

Gross pathologic examination of the mice revealed marked variability in the extent of Hodgkin's-like disease, as determined by the degree of spleen, thymus, and lymph node enlargement. Of the 21 animals, 2 had no detectable disease, but 10 had mild, 3 moderate, and 6 advanced disease (Table 1). The latter 6 animals had strikingly enlarged mesenteric lymph nodes. Marked emaciation was not seen in any of the groups; the mean body weight of those with moderate and advanced disease was actually somewhat higher than that of those with no or mild disease, this difference apparently being due to the splenomegaly and generalized lymphadenopathy (Table 1).

Microscopically, sections from the lymph nodes of the mice with severe Hodgkin's-like disease revealed many of the characteristics of the murine lesion. A form of reticulum cell sarcoma characterized by frequent mitotic figures, moderate numbers of plasma cells and eosinophils, some giant cells, and some degree of fibrosis was seen (Fig 1). The sections from the nodes of animals with no gross signs of disease showed a normal arrangement of lymphocytic and reticular cells (Fig 2). Neoplastic tissue was found in the livers of several of the mice with advanced disease (Fig 3).

### Granuloma Formation

The correlation between the stage of the murine Hodgkin's-like lesion and the degree of granulomatous reaction to *S. mansoni* eggs can be



TEXT-FIG 1. Granuloma formation around *Schistosoma mansoni* eggs injected into the lungs of SJL/J mice in different stages of Hodgkin's-like disease.

seen in Table 1. The lungs were removed 16 days after egg injection when the granulomas are usually at their peak in unsensitized animals. In animals with no detectable disease, the mean granuloma diameter was  $164 \mu$ . Since the eggs, as measured in the tissues, had a mean diameter of  $59 \mu$ , the mean lesion diameter was 180% the diameter of the egg alone (Text-fig 1). The measurements in the animals with mild disease were similar to those in the normals. The 3 animals with moderate disease had a mean granuloma diameter of  $100 \mu$ , and the 6 with advanced disease about  $80 \mu$ , which was only slightly greater than that of the egg alone. Two of the animals in the latter group formed virtually no granulomas at all (Text-fig 1). A granuloma representative of the mean diameter of the lesion in the animals with no disease is compared

Table 1. Correlation Between Degree of Hodgkin's-like Neoplasia and Size of Granulomas Around Schistosome Eggs Injected Intravenously into lungs of SJL/J Mice

Body weight (g)	Enlargement			Spleen weight (mg)	Eggs measured (No.)	Mean granuloma diameter $\pm$ SE ( $\mu$ ) <sup>a</sup>	Mean granuloma volume $\times 10^{-4} \pm$ SE (cu mm)
	Mesenteric lymph node	Thymus	Other lymph nodes				
<b>No Disease (2 mice)</b>							
25	-	+	-	140	17	165.86 $\pm$ 16.67	23.89 $\pm$ 7.20
26	-	-	-	170	40	162.73 $\pm$ 16.44	22.56 $\pm$ 6.84
Mean				155		164	23
<b>Mild Disease (10 mice)</b>							
26	++	-	+	190	21	194.17 $\pm$ 19.38	38.33 $\pm$ 11.48
29	++	+	+	230	20	182.80 $\pm$ 23.92	31.98 $\pm$ 12.55
24	++	-	+	190	13	174.98 $\pm$ 21.07	28.05 $\pm$ 10.13
22	++	+	+	260	20	166.94 $\pm$ 21.76	24.36 $\pm$ 9.52
24	+	+	-	170	19	147.68 $\pm$ 27.23	16.86 $\pm$ 9.32
27	++	+	++	320	17	145.13 $\pm$ 16.33	16.01 $\pm$ 5.40
24	++	+	++	250	25	142.65 $\pm$ 19.87	15.20 $\pm$ 6.35
24	++	-	++	290	5	138.96 $\pm$ 52.32	14.05 $\pm$ 15.87
24	+	+	-	130	28	127.61 $\pm$ 13.92	10.88 $\pm$ 3.56
24	++	++	++	300	21	127.38 $\pm$ 15.80	10.82 $\pm$ 4.03
Mean				233		155	21
<b>Moderate Disease (3 mice)</b>							
26	+++	+	+	230	15	109.64 $\pm$ 18.60	6.90 $\pm$ 3.51
32	-	+++	++	280	25	105.42 $\pm$ 16.33	6.13 $\pm$ 2.85
27	++	++	+	250	21	84.66 $\pm$ 12.21	3.18 $\pm$ 1.37
Mean				253		100	5
<b>Advanced Disease (6 mice)</b>							
24	+++	++	++	310	25	107.52 $\pm$ 8.79	6.51 $\pm$ 1.60
25	+++	++	++	190	23	101.42 $\pm$ 16.87	5.46 $\pm$ 2.73
25	+++	+++	+++	205	27	82.25 $\pm$ 7.69	2.91 $\pm$ 8.16
29	+++	+++	+++	490	20	72.71 $\pm$ 7.01	2.01 $\pm$ 0.58
25	+++	+++	+++	240	9	61.81 $\pm$ 5.55	1.24 $\pm$ 0.33
28	+++	++	+++	490	21	60.08 $\pm$ 4.42	1.14 $\pm$ 0.25
26	+++	++	+++	321		81	3

<sup>a</sup> Mean diameter of schistosome eggs in the tissue sections: 59  $\mu$ .

to one representative of that seen in those with severe disease in Fig 4. As the granuloma is a three-dimensional structure, usually spherical in form, the mean granuloma volume may be calculated from the mean granuloma diameter. As shown in Table 1, the mean volume of lesions in the animals with no disease and mild disease was more than five times that in mice with moderate and advanced disease. Statistically, this difference was highly significant:  $p = <0.0001$ .

Although antibody to egg antigen was detected by a passive hemagglutination test in serums from control mice infected for 8 weeks with *S. mansoni*, it was not found in the serum of any of the SJL/J mice given injections of eggs alone—no matter what the stage of the disease. It should be pointed out, however, that the injection of eggs leads to very low antibody titers at 16 days, even in young mice.<sup>8</sup>

#### Friend Virus Leukemia and Granuloma Formation

The young DBA/2 control mice used in these experiments formed larger granulomas than the aged SJL/J mice. The animals with early Friend virus leukemia (they were inoculated with virus 9 days after egg injection) reacted in a manner similar to the controls (Table 2). The two groups with advanced leukemia, as evidenced by marked splenomegaly (they received the virus 12 and 3 days before the eggs), actually formed significantly larger granulomas at 16 days than did the control mice (Table 2).

#### Discussion

In a recent review on the Hodgkin's-like reticulum cell neoplasm in laboratory animals, Dunn and Deringer pointed out that the lesions found in mice bear the closest resemblance to the human lesion.<sup>4</sup> Of the several different inbred mouse strains that develop this neoplasm, the lesion in the SJL/J strain is most similar morphologically to that

Table 2. Correlation in DBA/2 Mice Between Splenomegaly Induced by Friend Virus Leukemia and Granuloma Formation Around Schistosome Eggs Injected Intravenously into Lungs 16 Days Previously

No.	Type	After virus inoculation (days)	Mice (No.)	Mean spleen wt $\pm$ SE (mg)	Mean granuloma diameter ( $\mu$ ) $\pm$ SE
1	Control	—	6	94 $\pm$ 6	226 $\pm$ 9.1
2	Friend virus	7	6	185 $\pm$ 25	233 $\pm$ 8.4
3	Friend virus	19	6	1377 $\pm$ 128	278 $\pm$ 9.7
4	Friend virus	28	6	1360 $\pm$ 72	261 $\pm$ 9.2

Statistical significance: 1 vs 2: NS; 2 vs 4:  $p < 0.025$ ; 1 vs 3, 1 vs 4, 2 vs 3:  $p < 0.005$ .

seen in man, including eosinophilic infiltration, binuclear cells that closely resemble the Sternberg-Reed cell, and areas of fibrosis.<sup>4</sup> In addition, the lesions are variable from animal to animal and even in different areas of the body of individual animals. In contradistinction to the human disease, however, the murine disease occurs only in older mice, and there is a strong genetic influence.<sup>4</sup> In addition, serum protein changes have been observed, Wanebo *et al* finding  $\alpha_1$  and  $\alpha_2$  paraproteinemias<sup>9</sup> and McIntire and Law demonstrating elevations in the serum immunoglobulins.<sup>10</sup> It should be mentioned that it is relatively difficult to transplant the Hodgkin's-like neoplasm among inbred animals.<sup>4</sup>

The marked morphologic resemblance of the reticulum cell neoplasm in SJL/J mice to human Hodgkin's neoplasm already has led to studies utilizing this mouse strain as a model for the human disease. Rubin investigated the spread of the lesion and the effect of prophylactic irradiation.<sup>11</sup> Yumoto and Dmochowski claimed to demonstrate by electron microscopy leukemia type C virus particles in the mouse lesions.<sup>12</sup>

One of the most interesting aspects of Hodgkin's disease apparently has not been studied as yet in this experimental model. Patients with advanced Hodgkin's disease lose their delayed skin reactivity to intradermal antigens and are not sensitized by contact allergens.<sup>1,2,13</sup> In addition, skin graft rejection is prolonged.<sup>14</sup> Production of circulating antibody following immunization, however, is usually unimpaired.<sup>1,2,13</sup>

The failure to investigate these anergic aspects of Hodgkin's disease in the SJL/J mice may be due to the prolonged maintenance necessary prior to the appearance of the lesion, and to the belief that the mouse is a relatively poor model for studying delayed skin reactions. Recently, a new and quantifiable delayed hypersensitivity type of reaction has been reported to occur in the mouse: granuloma formation around *S. mansoni* eggs injected intravenously into the lungs. This reaction is specifically accelerated and augmented on secondary exposure and is transferrable by cells but not by serum.<sup>5</sup> In addition, the primary reaction is markedly inhibited by procedures which suppress delayed hypersensitivity, such as neonatal thymectomy<sup>15</sup> and the administration of antilymphocyte serum.<sup>16</sup> In the present study, SJL/J mice with moderate and advanced Hodgkin's-like disease showed markedly diminished granuloma formation around schistosome eggs, the mean reaction being one-fifth the volume of that seen in mice with no overt disease or mild involvement. Two mice with advanced disease actually formed no granulomas whatsoever. It should be pointed out that none of the animals in this study were emaciated. Furthermore, mice with advanced Friend virus leu-

kemia, which has been shown to depress the formation of circulating antibody,<sup>17-19</sup> actually formed significantly larger granulomas than did control animals. Chronic X-irradiation, which also depresses antibody formation, did not inhibit granuloma formation around schistosome eggs.<sup>7</sup>

In conclusion, the demonstration that granuloma formation is markedly diminished in mice with advanced Hodgkin's-like lesions not only provides further evidence that the schistosome egg granuloma is a form of delayed hypersensitivity but suggests that the reticulum cell neoplasm in the SJL/J mouse is a suitable animal model of Hodgkin's disease.

### Summary

The SJL/J mouse develops a reticulum cell sarcoma which bears a remarkable morphologic resemblance to the neoplasm of human Hodgkin's disease. The present study reveals that mice with advanced Hodgkin's-like lesions also resemble humans with Hodgkin's disease in respect to an impairment in a delayed hypersensitivity type of reaction. The granulomas which form around schistosome eggs injected into the lungs of mice with moderate and advanced Hodgkin's-like lesions were less than one-fifth the volume of those seen in normal mice and in those with only mild lesions. Even the animals with advanced neoplasia were not in an emaciated terminal state. In contrast to the mice with the Hodgkin's-like lesion, mice with advanced Friend virus leukemia actually formed granulomas significantly larger than those observed in controls.

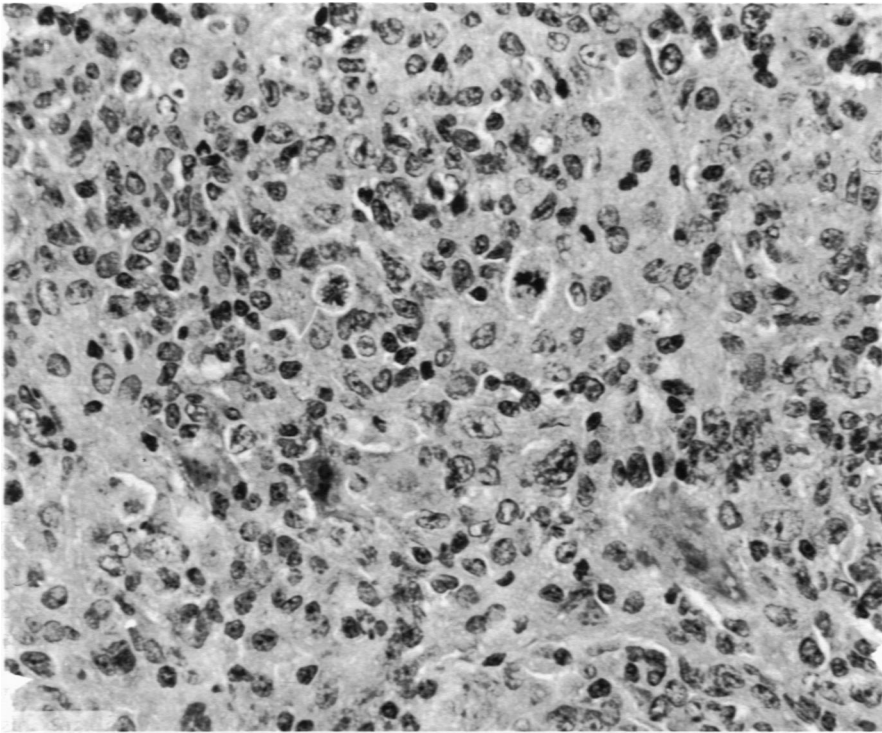
### References

1. PERRY, S., THOMAS, L. B., JOHNSON, R. E., CARBONE, P. P., and HAYNES, H. A. Hodgkin's disease. Combined clinical staff conference at the National Institutes of Health. *Ann Intern Med* 67:424-442, 1967.
2. AISENBERG, A. C. Hodgkin's disease—prognosis, treatment and etiologic and immunologic considerations. *New Eng J Med* 270:508-514, 565-570, 617-622, 1964.
3. MURPHY, E. D. SJL/J, a new inbred strain of mouse with a high early incidence of reticulum-cell neoplasm. *Proc Amer Ass Cancer Res* 4:46, 1963.
4. DUNN, T. B., and DERINGER, M. K. Reticulum cell neoplasm, type B, or the "Hodgkin's-like lesion" of the mouse. *J Nat Cancer Inst* 40:771-821, 1968.
5. WARREN, K. S., DOMINGO, E. O., and COWAN, R. B. Granuloma formation around schistosome eggs as a manifestation of delayed hypersensitivity. *Amer J Path* 51:735-756, 1967.
6. VON LICHTENBERG, F. Host response to eggs of *S. mansoni*. I. Granuloma

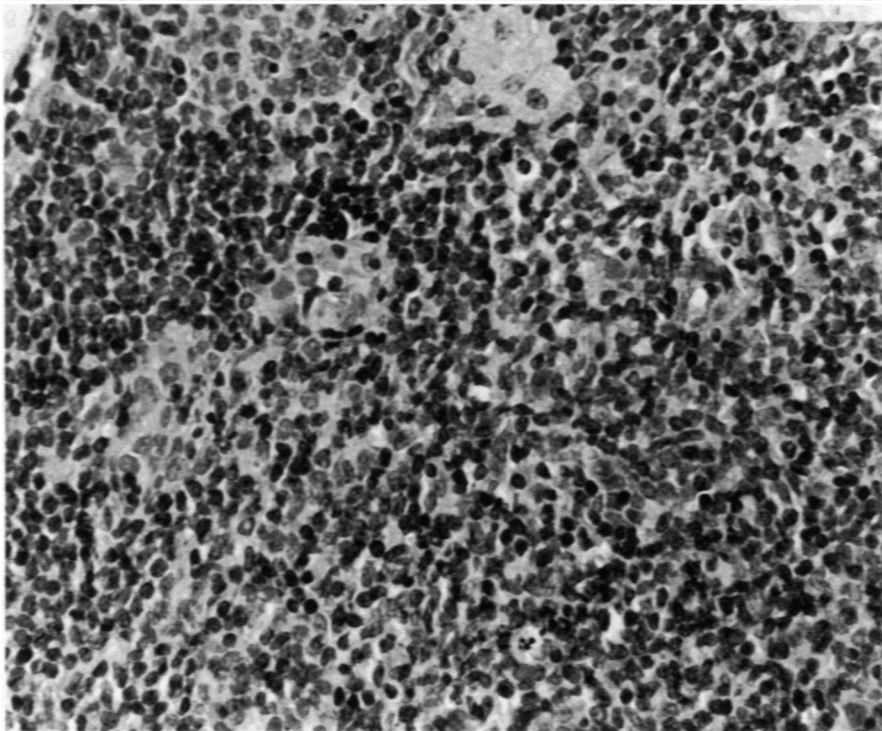
- formation in the unsensitized laboratory mouse. *Amer J Path* 41:711-731, 1962.
7. PERROTTO, J. L., and WARREN, K. S. The inhibition of granuloma formation around *Schistosoma mansoni* eggs. IV. X-irradiation. *Amer J Path* 56:279-292, 1969.
  8. VON LICHTENBERG, F., SADUN, E. H., and BRUCE, J. I. Host response to eggs of *Schistosoma mansoni*. III. The role of eggs in resistance. *J Infect Dis* 113:113-122, 1963.
  9. WANEBO, H. J., GALLMEIER, W. M., BOYSE, E. A., and OLD, L. J. Para-proteinemia and reticulum cell sarcoma in an inbred mouse strain. *Science* 154:901-903, 1966.
  10. MCINTIRE, K. R., and LAW, L. W. Abnormal serum immunoglobulins occurring with reticular neoplasms in an inbred strain of mouse. *J Nat Cancer Inst* 39:1197-1211, 1967.
  11. RUBIN, P. Hodgkin's-like reticulum cell sarcoma in SJL/J mouse. An animal model of lymphoma to solve clinical problems. *Radiol Clin N Amer* 6:25-44, 1968.
  12. YUMOTO, T., and DMOCHOWSKI, L. Light and electron microscopic studies of organs and tissues of SJL/J strain of mice with reticulum cell neoplasms resembling Hodgkin's disease. *Cancer Res* 27:2098-2112, 1967.
  13. BROWN, R. J., HAYNES, H. A., FOLEY, H. T., GODWIN, H. A., BERARD, C. W., and CARBONE, P. P. Hodgkin's disease Immunologic, clinical and histologic features of 50 untreated patients. *Ann Intern Med* 67:291-302, 1967.
  14. KELLEY, W. D., LAMB, D. L., VARIO, R. C., and GOOD, R. A. An investigation of Hodgkin's disease with respect to the problem of homotransplantation. *Ann NY Acad Sci* 87:187-202, 1960.
  15. DOMINGO, E. O., and WARREN, K. S. The inhibition of granuloma formation around *Schistosoma mansoni* eggs. II. Thymectomy. *Amer J Path* 51:757-761, 1967.
  16. DOMINGO, E. O., and WARREN, K. S. The inhibition of granuloma formation around *Schistosoma mansoni* eggs. III. Heterologous antilymphocyte serum. *Amer J Path* 52:613-631, 1968.
  17. SALOMAN, M. H., and WEDERBURN, N. The immunodepressive effect of Friend virus. *Immunology* 10:445-458, 1966.
  18. CEGLOWSKI, W. S., and FRIEDMAN, H. Immunosuppressive effects of Friend and Rauscher leukemia disease viruses on cellular and humoral antibody formation *J Nat Cancer Inst* 40:983-995, 1968.
  19. BENDINELLI, M. Haemolytic plaque formation by mouse peritoneal cells, and the effect on it of Friend virus infection. *Immunology* 14:837-850, 1968.

The author would like to thank Dr. Austin Weisberger for suggesting the search for an animal model of Hodgkin's disease, and Dr. E. F. Wheelock for help with Friend virus leukemia. He would also like to acknowledge the expert technical assistance of Pierre A. Peters and Earlene H. Moss.





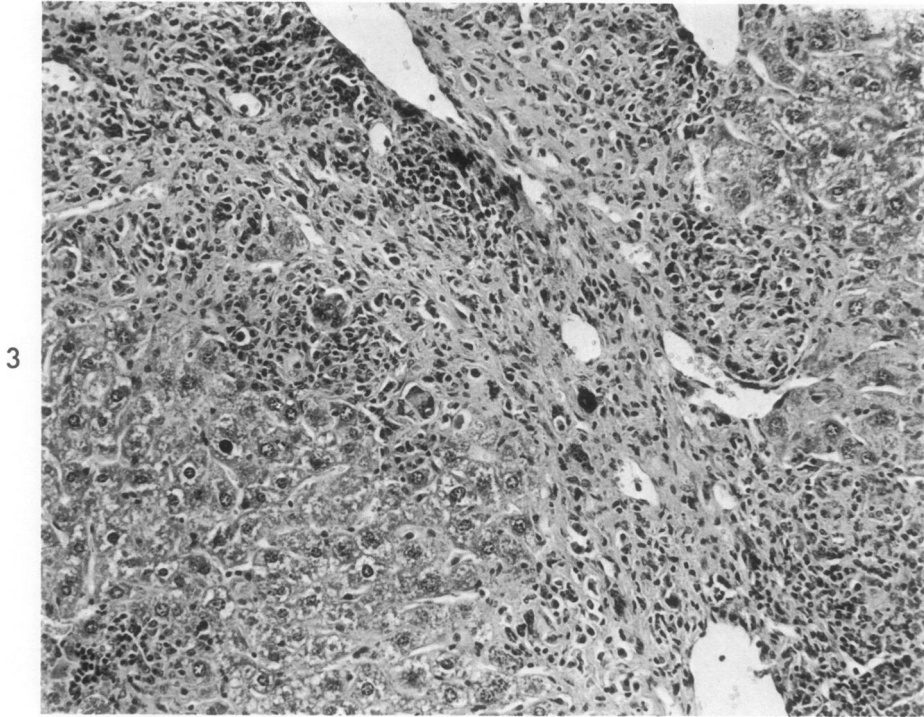
1



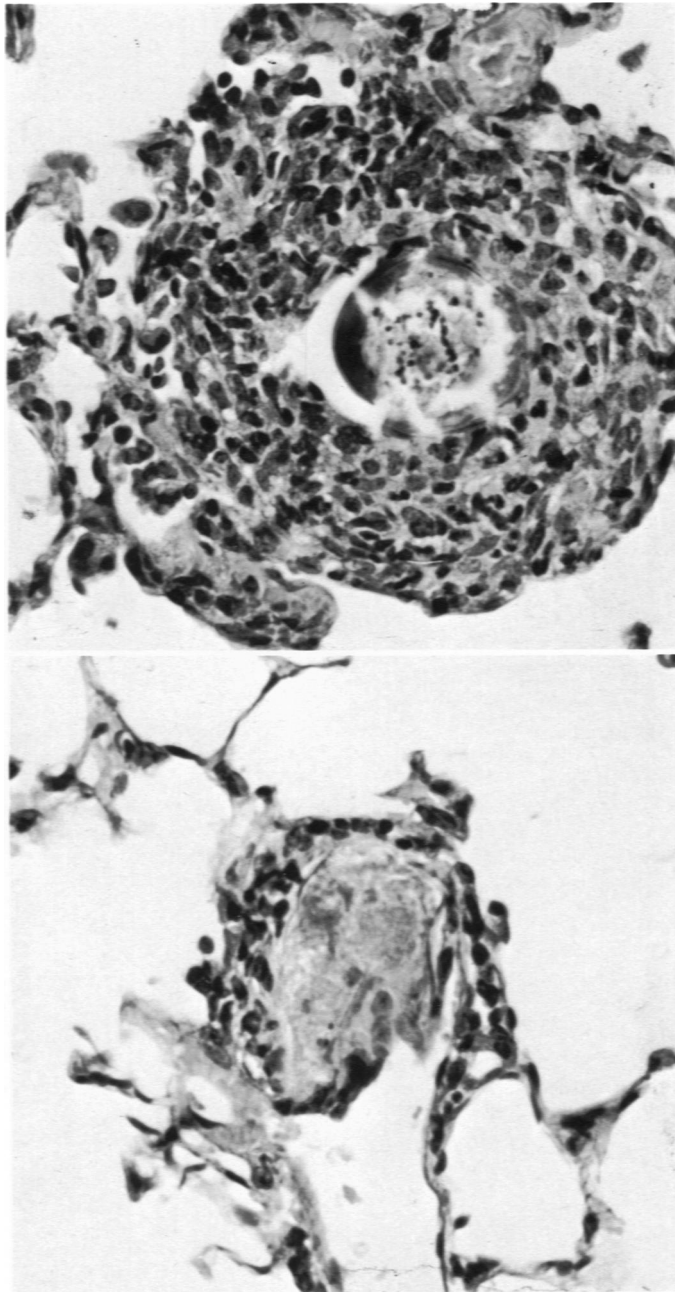
2

**Fig 1.** Section of a lymph node from an SJL/J mouse with advanced Hodgkin's-like lesions. Note the mitotic figures, reticular cells with macronucleoli, giant cells, and plasma cells. Many of the polymorphonuclear cells are eosinophils. Hematoxylin and eosin.  $\times 435$ .

**Fig 2.** Section of a lymph node from an SJL/J mouse with no gross evidence of Hodgkin's-like lesions. Note the normal arrangement of lymphocytic and reticular elements. Hematoxylin and eosin.  $\times 435$ .



**Fig 3.** Section from the liver of an SJL/J mouse with advanced Hodgkin's-like lesions. Note periportal fibrosis and giant cells. Hematoxylin and eosin.  $\times 150$ .



**Fig 4.** Representative granulomas from mice with no detectable Hodgkin's-like lesions (*top*) and mice with severe lesions (*bottom*), 16 days after the IV injection of *S. mansoni* eggs into their lungs. Hematoxylin and eosin. X 435.