

WHAT TO CALL HYPOPLASTIC KIDNEY?*

BY

PIERRE BOISSONNAT

From Hôpital Necker-Enfants Malades, Paris,

Among the congenital abnormalities of the urinary tract, the term hypoplastic kidney is one of the least well defined and also one of the most widely used. Certain abnormal structures are sometimes called hypoplastic kidneys and certain abnormal kidneys which we term hypoplastic are called by some aplastic (even agenetic) kidneys, dysplastic, congenital atrophic, miniature, or infantile kidneys, doll's kidneys, dwarf or dwarfed kidneys.

If the term hypoplastic is to be retained it should be reserved only for those kidneys which are underdeveloped due to some deficiency, both quantitative and qualitative, in their fundamental components.

Among hundreds of bizarrely-shaped or odd-looking kidneys, all diminutive in size, some seem to answer this definition and present a set of common anatomical features suggesting that they may result from similar embryonic defects. They all present themselves as more or less functional kidneys, diminutive in size and weight, because of a quantitative and a qualitative deficiency in their ureteric and metanephric primordia. Their minor calices are both less numerous and less developed than normal, so that in consequence the pyramids, lobes and successive generations of nephrons that have grown from them are scarce and underdeveloped. When the defect is unilateral such a kidney is unable to sustain life without the help of a mate; when bilateral they prove sooner or later to be fatal. Histologically, such structures necessarily contain more or less differentiated nephrons; otherwise they would not be kidneys.

Whether or not the term hypoplastic is to be kept and reserved for this family is one question. There is a second more important question, however: 'Should some small kidneys of bizarre shape be ranged under one unique family name?'—whether this name be hypoplastic, meroplastic, ateleplastic, elleipoplastic, or any better term from Greek, until the right word springs from aetiopathogenesis through histology or embryology?

Embryology

Normally, the distal end of the ureteral bud, when about to reach the metanephrogenic blastema, enlarges in the future pelvis and grows two buds (primordia of the two major calices). These in turn grow secondary buds which themselves give off further new buds and so on. Finally, as many as 12 to 20 generations of successive buds are formed, i.e. the future tubules. A metanephrogenic cap is carried in with and surrounds the tip of each tubule to form the corresponding glomerule.

In those abnormal kidneys in this paper which seem to group themselves under the one heading of hypoplastic kidney (Figs. 1, 2, 3, 4) it appears as if the distal end of the ureteral bud (pelvic enlargement) had only been able to grow scanty caliceal buds, and these in turn, not having had enough strength to grow more than a few generations of successive buds, resulted in an insufficient number of pyramids, lobes and consequently rare nephrons. These abnormal kidneys, which appear to be underdeveloped, should properly be called hypoplastic in the full meaning of the word.

The aetiology underlying hypoplastic kidneys was mainly based on a hypothetical congenital deficiency in the development of the blood supply to the foetal kidney, the abnormal organ thus being atrophic. What seems more likely today is that a hypothetical deficiency occurs at a much earlier embryonic stage, either in the ureteral bud itself (being since its beginning either incomplete or unable to grow a complete set of buds or accidentally lacking sufficient induction to do so), or in the metanephrogenic blastema (being deficient in similar ways), or from a defective union of the two.

Anatomical Types of Hypoplastic Kidneys

The anatomical features which this paper proposes as criteria of family identity are based upon gross appearance and pyelographic pictures. Three types may be distinguished.

Type I or Upper Polar Type. As this type is the most severe, it is also the most simple and typical

* A paper read at a meeting of the British Association of Paediatric Surgeons in Stockholm, September 1961.

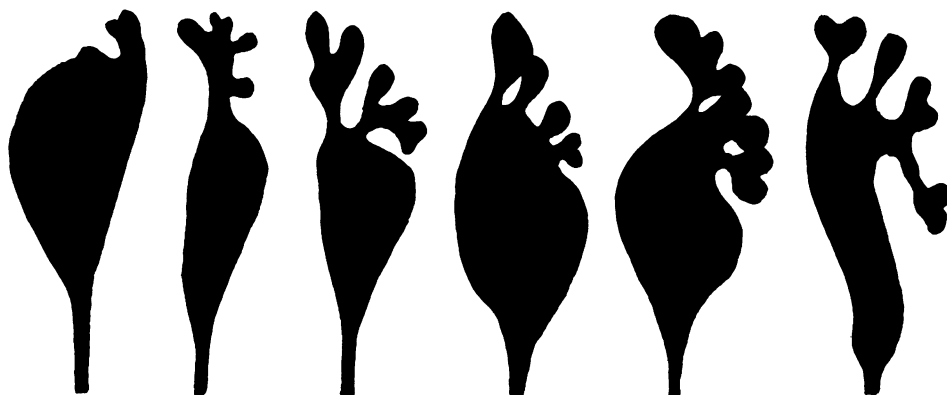

FIG. 1.—Hypoplastic kidneys type I or upper polar type. A few ill-formed minor calices have grown only from the upper pole of the kidney pelvis.

(Fig. 1). It shows the most striking quantitative as well as qualitative stigmata of hypoplasia. Quantitatively, no major caliceal bud had been able to form, and only the upper area of the rudimentary pelvis could grow a few calices of the minor type (from one to four), so that these kidneys represent nothing but a poor upper caliceal budding. For this very reason, their rudimentary pelvises are in line with the ureter, they lie close to the spine in a high internal lumbar location and necessarily take the classical triangular carrot shape which, therefore, is not an accidentally freakish shape. Qualitatively, the few minor calices being underdeveloped show the classical bizarre or club shape, while the corresponding renal lobes are not only scarce, but also underdeveloped, the poor successive buddings having probably stopped after bringing forth a few generations of nephrons.

Because of secondary changes and/or technical details, these features are not evident on every radiograph or even removed specimen, and may be easily overlooked when not purposely sought for on selected pictures.

Histology. Every small structure looking more or less like a kidney is not a hypoplastic kidney.

Some of the worst formed ones are not kidneys at all because they only contain fatty or mesenchymal tissues such as cartilage or striated muscle, and no metanephric elements. In fact, the upper end of the ureter, often atretic, very seldom shows a pelvic sort of enlargement and most exceptionally calix-like formations.

As a rule, when there are recognizable pelvis and calices, as in the tracings of Fig. 1, more or less differentiated metanephric elements are to be found; the microscopic findings roughly parallel the gross appearance. From recent studies it is now well established that the so-called proglomerules and primitive ductules (resemb-

ling epididymis) do not represent remnants of pronephric or mesonephric primordia but immature metanephric elements. These are found in extremely hypoplastic kidneys, though often nephrons, fairly normal but fewer in number, have grown around the better developed calix or calices, while immature elements are found round the ill-formed ones. They are also found in better developed hypoplastic kidneys in areas where calices are lacking.

When there are only primitive ductules (grown from the ureteral bud) and no glomerules at all because of complete lack of metanephrogenic blastema, the anomaly represents nothing but a variety of renal agenesis. When metanephric elements are intermingled with tissues foreign to the normal kidney, the term hypoplastic or dysplastic is inadequate, and histologists should coin a new term.

Type I is found on the *left* side in more than 90% of the cases. It is also more common in *boys* (about 75%) than in girls.

Type II or Bipolar Type. Kidneys of this type are far less common than the preceding ones and less typical at first glance, because they possess major calices more or less developed; but they are also diminutive in size and weight because of the small number of their minor calices (five at most). Three varieties may be described, depending on the distribution of these minor calices between the two poles (Fig. 2a, b, c).

(a) In addition to an upper polar caliceal system, often grown from one major calix, there is an incipient budding towards a lower polar formation.

(b) There are two more or less developed major calices, and the minor calices are either equally distributed between them or slightly more numerous at the lower pole, while the upper major calix is generally better developed.




FIG. 2.—Hypoplastic kidneys type II or bipolar type. A few ill-formed minor calices have grown from both poles of the kidney pelvis. Depending on the distribution of these calices between the two poles, three varieties can be described (a, b, c).

(c) There are two major calices, but the upper one has grown only one or two very ill-formed minor calices, while the lower polar system is better provided (sometimes, as in (d), this last variety seems to be an attempt towards a pure lower polar type, that probably has never been formed).

In the three varieties, there is a frequent but unsuccessful attempt towards a middle minor calix formation, which never succeeds as it does in type III.

Histology. In type II (as well as in the following type III) the fact that they are kidneys is not questioned. All contain nephrons quite normal or fairly differentiated, though proglomerules may be found in some areas and only connective tissue in areas widely lacking minor calices.

Type II is four times less common than type I in

unilateral cases. *Girls* are affected more often (66.7%) than boys. About 80% of this type affect the *left* side.

Type III or Pseudominature Type. Kidneys of this type seem to be the least typical and so different from one another as to make any systematization impossible (Figs. 3 and 4). All have few minor calices and these are poorly developed and badly shaped. But, as these calices came from the whole external pelvic area (generally without any major caliceal formation), they are spread over a rather wide space, so that when overdistinguished their wide rounded tips superimposed on one another look like a complete set of calices, although this set never exceeds six in number.

The adjectives 'miniature' kidneys and 'infantile'




FIG. 3.—Hypoplastic kidneys type III or pseudominature type. A few ill-formed minor calices have grown from the whole external periphery of the kidney pelvis.



FIG. 4.—Bilateral hypoplastic kidneys. They show the same features as either one of the unilateral types, together with peculiar additional characteristics (see text).

kidneys were probably first given to kidneys similar to these. On reflection, such adjectives are quite inadequate. A miniature is a finished masterpiece, tiny in size, but perfectly completed in every detail, not to be compared with a rough sketch or a caricature. It is the same for an infant: a healthy infant with healthy kidneys cannot be compared with a childish drawing with clumsy head, limbs and belly, or no belly at all.

Type III or pseudominiature (or childish) type is less common in unilateral than in bilateral cases. In our series, 13 unilateral type III belong to *girls* and two belong to boys; 12 are on the *left* side.

Coexistent Anomalies

This paper deals only with the cases in which renal hypoplasia has occurred alone or is the major anomaly.

It is often said that renal hypoplasia is a frequent accompaniment of other malformations in the urinary tract (ureterocele, ureteral ectopia, etc.). In our series, this was rare compared with simple secondary changes (hydronephrosis, uretero-hydronephrosis, etc.). In the very rare instances where the kidneys, associated with other urinary anomalies, appeared congenitally ill formed, renal dysgenesis was far more common than hypoplasia.

It is also generally said that, in duplications of the upper urinary tract, the 'upper kidney' is frequently hypoplastic. As a rule, only the ureter and pelvis are concerned with duplication, merely resulting in the unequal distribution of a complete set of minor calices between the two systems; the upper caliceal system generally possesses a few minor calices, the normal complement being found in exact number or corresponding value in the lower system. Of course, histologically, the parenchyma constituting the upper pole is sometimes hypoplastic. This is far less common than simple secondary changes due to impaired excretory function.

When renal hypoplasia has occurred alone, the pelvis and ureter may be either normal or abnormal in varying degrees. If hypoplastic kidneys result from some initial deficiencies during the formation and/or development of the ureteral bud, a continuous series can be traced from anomalies affecting only the caliceal set to those affecting the entire ipsilateral tract.

In many hypoplastic kidneys, the pelvis and ureter appear to be anatomically and functionally normal. It is well known that, except for their exceedingly small daily output of urine, hypoplastic kidneys are often normal in every other respect, urea and phenol-sulphonphthalein concentrations in-

cluded. Such kidneys may give neither trouble nor symptoms.

Sometimes infection occurs in adults, due rather less to a hypothetical proneness to pyelonephritis than to a possible mild deficiency in the caliceal, pelvic and ureteral musculature, resulting eventually in stasis and inflammatory changes. Sooner or later these infected kidneys become sclerosed, with vascular lesions often leading to hypertension (in children with unilateral hypoplastic kidneys, hypertension was found only when there were, in addition, congenital anomalies, mainly stenosis, of the renal artery itself). After a long-standing infection, these kidneys become contracted and, classically, distinction is often impossible from originally normal-shaped kidneys contracted by atrophic pyelonephritis. It seems doubtful that a normal-sized kidney could contract to less than one-fourth its original size; probably most of the so-called sclero-atrophic kidneys were originally diminutive because of hypoplasia. Proof of this can often be obtained on removed specimens by counting the minor calices with the help of a forceful pyelography; a direct counting of the pyramids is always awkward and difficult even by means of serial sectioning.

In other hypoplastic kidneys the pelvis appears more or less 'hydronephrotic' at urography, although after removal, when it is empty, it may look almost normal. Filled with liquid it sometimes becomes enormously distended and its wall becomes translucent. The uretero-pelvic junction generally seems to be the site of the main functional deficiency, although histological demonstration can seldom be obtained.

Cases are less common in which the ureter is also distended and kinked due to a possible deficiency at the vesico-ureteral junction level.

Cases with reflux are not uncommon. Reflux may be due either to congenital gaping or deficiency of the ureteral meatus and valve-like mechanism, or to changes consequent on infection.

Atretic and congenitally unpatent ureters in our series never coexisted with true metanephric elements in the kidney-like structures, these always belonging to the dysgenetic type.

Histologically, apart from secondary changes due to long-standing infection, the pathological findings in the pelvis and ureter are mainly concerned with deficiency in the smooth muscle fibres. Little can be said with regard to ganglion cells, as these are also present or absent in very large areas of perfectly normal ureters.

The contralateral kidney almost always shows evidence of compensatory hypertrophy. When it does not, in infants and children, bilateral hypoplasia

should be suspected, because it is generally agreed that hypoplastic kidneys are incapable of functional hypertrophy.

In our series there is the unique instance of a boy aged 9 with a left hypoplastic kidney (type III) and urethral stenosis following on surgical correction of penoscrotal hypospadias. Urography revealed that the right kidney had been silent for three years, while the left one had markedly increased in size, maintaining azotaemia at 55 mg./100 ml. In these last six months, azotaemia quickly rose to 115 mg./100 ml.

Bilateral Hypoplastic Kidneys

Bilateral cases need a special and somewhat different study, out of place here, so that only their anatomical features (Fig. 4), together with some additional ones, will be pointed out. Except in extreme hypoplasia leading to death soon after birth, bilateral hypoplastic kidneys have to perform an active excretory function, which is avoided by unilateral ones. Probably because of polyuria (due to parenchymal deficiency) through deficient pelves and ureters, the original morphology of bilateral hypoplastic kidneys is quickly modified by secondary changes and becomes very difficult to recognize, while it is most important regarding the fatal prognosis and hence the dangerous futility of any kind of surgery.

Bilateral hypoplastic kidneys possess the same criteria as either one of the unilateral types, together with peculiar additional characteristics:

(1) Frequently the right kidney is the more defective, often assuming type I or II (when, in the great majority of unilateral cases, the hypoplastic kidney is on the left side), while the opposite kidney generally assumes type III.

(2) Associated caliceal diverticula, more or less typical, are frequent (32.7% in our series).

(3) Girls are more often affected (62.6%) than boys.

(4) Failure to grow and gain weight, together with osteodystrophy (renal dwarfism) are constant. The time of their clinical evidence (from 1 to 11 years of age) depends on the degree of the congenital renal defect.

(5) Renal failure is also constant. Its onset depends on the degree of the congenital renal defect, but also on complications arising mainly from secondary infection due to congenital deficiencies in the ureter or uretero-pelvic junction. Infection being absent or successfully treated, blood urea begins to rise at about the age of 12 at the latest, then quickly increases and death occurs within an average of two to eight years. In our series no case had gone beyond 20 years of age.

(6) In half the cases, severe hypertension is also present, at least in the terminal period.

Discussion

Nowadays it is important, when studying case reports or statistical data on congenital abnormalities, pyelonephritis or hypertension, to understand exactly what the author means by a 'hypoplastic' kidney where he gives no further details or description. Clinically, it is even more important to be able to decide whether certain more or less functional odd-looking kidneys can be cured or improved by surgery or, if they are hopelessly ill formed, underdeveloped, and hypoplastic whether they should be removed when the defect appears to be unilateral or left alone when the defect is bilateral.

For more than half a century many papers on or about hypoplastic kidneys have been published. All agree that a hypoplastic kidney is a congenitally small organ so diminutive that it is unable to sustain life by itself. However, all those small structures which more or less resemble kidneys are not hypoplastic kidneys; some of them are not even kidneys.

Recent histological studies have revealed the many histological degrees of immaturity (or hypoplasia) of the nephron. But immature nephrons are found in certain ectopic, horseshoe, 'double' or hydronephrotic kidneys, as well as in hypoplastic ones. Hence, the modern advance in histology paradoxically has led to a temporary increase in confusion. Instead of being clarified, the simple terminology and elementary nosography needed for practical use (before surgery or autopsy) have become more confused than before.

Nosography should first start from the gross appearance, then advance following histological study.

The anatomical features this paper proposes as criteria in order to define the hypoplastic kidney may no doubt seem over simple (if not disputable) when dealing with such a difficult and debatable matter. Of course, the number of minor calices varies greatly from one normal kidney to another. Even in perfectly sound organs this number may be very low, because of compound papillae corresponding to two or sometimes three pyramids. However, scarce minor calices which are ill formed, narrow, elongated, with irregularly rounded tips, when seen in small abnormal kidneys are presumably not rich multivalent fornices, but underdeveloped simple ones lacking papillary cuppings.

All these anatomical features, with many others, are to be found scattered in the literature, and this paper has attempted to select and bring together

some of them as practical criteria for clinical presumption of renal hypoplasia.

Summary

Among renal abnormalities the hypoplastic kidney is one of the least well defined, both nosographically, due to lack of any precise morphological definition and, terminologically, because of wide gaps in aetio-pathogenetic knowledge.

From hundreds of bizarrely-shaped and odd-looking kidneys, diminutive in size, some seem to be isolated from the rest and show a set of common anatomical features suggesting that they belong

more or less to the same family, possibly as a result of similar embryological defects. Their minor calices are both less numerous and less developed than is normal, so that the pyramids, lobes and successive generations of nephrons that have grown from them are consequently scarce and underdeveloped.

Whether or not these abnormal kidneys can be systematically ranged under one unique family name is the most important question. Secondly, until we get the right word from histology or embryology, should the term hypoplastic be kept for this group?