

abnormal in 8 out of 13 patients. However, the bromsulphthalein excretion and the percentage of esterified serum cholesterol were normal. Since these two tests are more specific, the possibility of misinterpretation of deranged protein metabolism as evidence of liver disease rather than as an integral feature of systemic scleroderma needs no emphasis.

The hepatic fibrosis observed at operation in our first patient defies ready explanation, since there was no evidence of malnutrition, previous hepatic or biliary disease, generalized passive venous congestion, small intestinal defect, or ulcerative colitis. Though not subject to proof, it may be a direct manifestation of the viscerosclerodermatous process. Massimo (1954) seems to have been the first clear advocate of this view. He pointed out that both the liver and the spleen are rich in mesenchymal tissue, and he claimed priority in reporting hepatosplenomegaly in association with scleroderma. In his patient, a 54-year-old woman, splenectomy was performed and a histological diagnosis of fibroadenie of Banti's type was established. This same histological pattern of what we prefer to call congestive splenomegaly was confirmed in both of our patients. By contrast, Massimo made no mention of portal hypertension, the theme of our communication. The importance of the prompt recognition of this vascular complication, which has not hitherto received special attention, is self-evident.

Eventual hepatic fibrosis is a recognized sequel to congestive hepatomegaly from cardiac and pulmonary scleroderma and might also be expected to occur in some patients with sclerodermatous haemorrhagic colitis, especially if there were concomitant steatorrhoea as exemplified in our second patient. Her "silver stool" was regarded as a product of these abnormalities. It is, however, equally admitted that the hepatic fibrosis and its complications in our two patients might be independent of the sclerodermatous process.

Finally, we suggest that the possibility of the presence of oesophageal varices, as witnessed in both our patients, should be entertained during the standard radiological studies of visceral scleroderma.

#### Summary

Two illustrative cases, both in women, of scleroderma and hepatic fibrosis are fully reported. In each patient the salient feature was portal hypertension, including oesophageal varices, which led to recurrent haematemesis, an aspect apparently not previously described.

The first patient survived a palliative subcardiac portoazygos disconnexion and remained well five years later, with no subsequent haematemesis. The second patient, whose illness was further complicated by a combination of sclerodermatous haemorrhagic colitis and steatorrhoea to produce the "silver stool" sign, was treated conservatively for repetitive haematemesis. After prolonged invalidism she died in coma, as a result of haemorrhage from an oesophageal varix, some 20 months after her first haematemesis.

The scant literature on hepatic fibrosis in systemic scleroderma is reviewed and the causation of such hepatic lesions is briefly discussed in relation to the observations on our two patients.

Our thanks are due to Mr. N. C. Tanner for permission to refer to the operative details in Case 1; to Mr. K. Moore for similar authority in relation to Case 2; to Dr. R. Kempthorne, Dr. N. Whittaker, and Dr. A. L. Jacobs for permission to report the clinical observations; to Dr. F. E. Camps, reader in forensic medicine, London Hospital Medical College, for his detailed necropsy report and histological sections relating to Case 2, which Dr. W. B. Purchase, H.M. Coroner, has sanctioned; to Professor C. V. Harrison for his expert comments on the histology; to the honorary editor of the *Proceedings of the Royal Society of Medicine* for permission to report the details of the second patient more fully. This case was shown at the Clinical Section, December 9, 1955, for Dr. N. Whittaker.

#### REFERENCES

- Beigelman, P. M., Goldner, F., jun., and Bayles, T. B. (1953). *New Engl. J. Med.*, 249, 45.  
 Boyd, J. A., Patrick, S. I., and Reeves, R. J. (1954). *A.M.A. Arch. Intern. Med.*, 94, 248.  
 Calkins, E., and Bauer, W. (1955). *Med. Clin. N. Amer.*, 39, 325.  
 Cullinan, E. R. (1953). *Proc. roy. Soc. Med.*, 46, 507.  
 Gil, J. R. (1951). *Ann. intern. Med.*, 34, 862.  
 Goetz, R. H. (1945). *Clin. Proc.*, 4, 337.  
 Harvey, A. McG., and Bordley, J., III (1955). *Differential Diagnosis. The Interpretation of Clinical Evidence*, p. 612. Saunders, Philadelphia.  
 Leinwand, I., Duryee, A. W., and Richter, M. N. (1954). *Ann. intern. Med.*, 41, 1003.  
 Massimo, C. (1954). *Minerva Med. (Torino)*, 45, 63.  
 Ogiwicz, H. (1955). *Brit. med. J.*, 1, 208.  
 Piper, W. N., and Helwig, E. B. (1955). *A.M.A. Arch. Derm. Syph.*, 72, 535.  
 Rothman, S., and Walker, S. (1949). *Med. Clin. N. Amer.*, 33, 55.  
 Talbott, J. H., and Ferrandis, R. M. (1956). *Collagen Diseases*, p. 137. Grune and Stratton, New York.  
 Tanner, N. C. (1950). *Proc. roy. Soc. Med.*, 43, 147.  
 — (1954). *Ibid.*, 47, 476.  
 Walker, S. A., and Benditt, E. P. (1948). *Proc. Soc. exp. Biol. (N.Y.)*, 67, 504.  
 Wiener, K. (1955). *Systemic Associations and Treatments of Skin Diseases*, p. 85. Kimpton, London.

## GANGRENE OF THE LEGS IN DISSEMINATED LUPUS ERYTHEMATOSUS

BY

**E. C. B. KEAT, M.C., M.D., M.R.C.P.**

*Consultant Physician, Brighton, Lewes, and Mid-Sussex  
Group of Hospitals*

AND

**J. H. SHORE, M.D.**

*Lecturer in Morbid Anatomy, Charing Cross  
Hospital Medical School*

Disseminated lupus erythematosus has been recognized as a generalized disease since Kaposi drew attention to the systemic manifestations of lupus erythematosus in 1872 and Osler's later description in 1895. The clinical syndrome of facial erythema in the classical butterfly distribution, arthritis, involvement of serous membranes, lymphadenopathy, leucopenia, and fever are now well known, but we have been unable to find a record of any case in which gangrene of the legs was due to involvement of large arteries in this disease.

#### Case Report

A girl aged 14 was admitted to hospital in September, 1953, having developed an erythematous, itchy eruption on the face and hands in July, and for the past month had noticed pain in the left calf on walking, severe enough to make her stop. Four days before admission she awoke to find her left foot cold and numb, becoming painful, and later swollen. There was no relevant history apart from chilblains.

On examination her temperature was 101° F. (38.3° C.) and pulse 120. There was erythema of the face and bridge of the nose in a butterfly distribution, with a shiny erythema at the bases of the finger-nails. The left foot was cold and swollen. The calf muscles were firm and tender. Femoral arterial pulses were present and equal, and both popliteal arteries were easily palpable. The dorsalis pedis and the posterior tibial arteries could not be felt on the left side. Joint sense of the left big toe was diminished and there was some loss of light touch sensation. The urine was free from albumin. The erythrocyte sedimentation rate was 82 mm. (Westergren) in one hour. Other systems were normal. The haemoglobin was 84%, colour index 1. There was a moderate leucocytosis, with 83% polymorphs. L.E. cells were present.

Cortisone orally produced much improvement, but a small area of gangrene developed at the tip of the big toe. The rest of the foot became warm and dorsalis pedis pulsation returned. A fortnight after admission she awoke with the left foot cold and numb up to the mid-calf with loss of pulses in the foot and further sensory impairment over the toes. Intra-arterial papaverine anticoagulants and a sympathetic block had some success, and, following the latter, the foot became warmer. An arteriogram demonstrated an adequate vascular supply to the foot, although there was some narrowing of the anterior tibial artery. The E.S.R. fell to 10 mm. in one hour, but changes in the temperature of the foot from day to day continued and the foot gradually became cold for longer periods. A lumbar sympathectomy performed five weeks after admission did not improve the condition. Her general condition deteriorated, gangrene spread, and amputation of the left leg was performed on December 18, 4 in. (10 cm.) below the tibial condyles.

Dissection of the amputated leg and foot showed the arteries to be occluded by recent thrombus. Small areas of necrosis were seen in skeletal muscle adjacent to the posterior tibial artery. The upper end of the peroneal artery was practically obliterated by an organized thrombus and there was fibrosis in the wall of the artery.

Any attempt to lower the dose of cortisone was followed by a flare-up of the disease and it was decided to add *para*-aminobenzoic acid by mouth. Zarafonitis *et al.* (1948) had reported promising responses to this drug in disseminated lupus erythematosus, and it was given in increasing dosage up to 2 g. eight times a day and cortisone was given in doses of 25 mg. eight-hourly. There was a favourable response to this treatment and cortisone was gradually discontinued, on this occasion without untoward effect. The E.S.R. was 16 mm. in one hour; L.E. cells became absent by the 24-hour-clot method. The patient was discharged to convalescence walking with the aid of a crutch and taking *para*-aminobenzoic acid, 2 g. four times daily.

She remained well until November, 1954, when she was readmitted to hospital with polyarthritis affecting the small joints of the hands, wrists, elbows, right knee, and right ankle. A week later pain developed in the right calf followed by coldness and numbness of the right foot. The arteries below the right femoral artery were impalpable, the foot became cyanosed, and later a patch of gangrene appeared. Despite conservative treatment amputation again became necessary; but her condition deteriorated, she developed mental changes and generalized convulsions, and died eight days after operation.

*Post-mortem Findings.*—Internally bilateral bronchopneumonia and pulmonary congestion were found. All chambers of the heart were dilated and the myocardium was soft and pale. There were no vegetations on the valve cusps or endocardium. The left coronary artery appeared narrowed. No occluding lesion was found in the femoral or popliteal arteries other than could be accounted for by the amputations with subsequent organization. The lymph nodes were rather prominent and the spleen was congested and a little enlarged (weight 300 g.). No other abnormality was found.

### Histology

Vascular lesions were found in the anterior and posterior tibial arteries of the amputated right leg, in the left coronary artery, and in many small arteries and arterioles in the liver, kidneys, skeletal muscles, appendix, ovary, connective tissues, and nerve sheaths. The left coronary artery showed perivascular fibrosis, irregular thinning of the muscle coats, and focal interruption of the internal elastic lamina with its replacement by fibrous tissue. There was a thick layer of fibrous tissue beneath the intima which had greatly narrowed the lumen of the artery. No inflammatory cells were present (see Fig.).

The anterior and posterior tibial arteries from the amputated right leg showed much narrowing of their lumina by subintimal fibrosis. There was also some recent mural thrombus, with early organization, in the anterior tibial

artery; this thrombus had nearly closed the lumen. The subintimal fibrosis was not associated with destruction of the muscular and elastic tissue as it was in the left coronary artery, although there was some irregular thinning of the internal elastic lamina. Some of the venae comites contained recanalized thrombus, but the walls showed no evidence of damage.

In the small arteries the changes consisted of perivascular fibrosis, fibrous replacement of muscle and elastic tissue for part of the circumference of the vessel, subintimal fibrosis, and occasional foci of fibrinoid necrosis in the media. In the arterioles there were hyaline thrombi with which was associated a variable amount of intimal proliferation. Histiocytes, lymphocytes, and plasma cells were present in both these types of lesion; there were few polymorphonuclear leucocytes, and eosinophils were rarely seen. A lesion of the necrotizing type was seen in an arteriole in the wall of the appendix and there was also acute suppurative appendicitis with peritonitis.

Concentric fibrosis round the splenic arterioles was present, but not to a marked extent. Wire-loop thickening of the glomerular capillaries was not seen in the kidneys. No abnormality was found in the pulmonary arteries.

Occasional small collections of large mononuclear cells, which resembled an early rheumatic lesion, were seen near many small arteries and capillaries which were not themselves abnormal. These lesions were most frequent in the muscles.

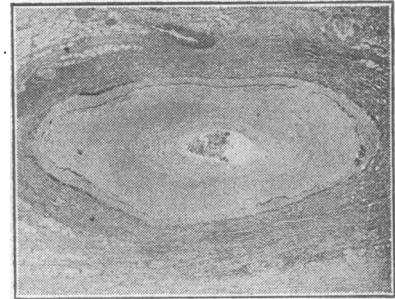
### Discussion

The unusual feature of this case was the involvement of large arteries, which had caused gangrene of each leg in turn, the line of demarcation in both being typical of that produced by occlusion of the popliteal arteries. In the early stages there were probably periods of arterial spasm which was relieved temporarily by sympathetic block, and it is likely that this spasm was caused by small necrotizing lesions in the arterial walls. Later these lesions were complicated by thrombosis, and these thrombi subsequently organized. This final stage was seen in the vessels of the amputated legs. Gangrene seems to be a very rare complication of disseminated lupus erythematosus, although Raynaud's phenomenon has been reported by Dubois (1953) and Jessar *et al.* (1953).

Involvement of a main coronary artery also appears to be a rare event, although lesions in the small branches of these vessels have been described (Harvey *et al.*, 1954).

The remaining lesions in the small arteries and arterioles are as described in these vessels by Gold and Gowing (1953), and the absence of wire-loop lesions in the glomerular capillaries has been noted by many writers.

There was no evidence of active inflammation in the left coronary artery or in many of the smaller affected vessels. On the other hand, many small arteries and arterioles showed fibrinoid necrosis and active inflammation in their walls; these were plainly progressive lesions, while the former were those which had undergone organization. In between these extremes were many lesions showing intermediate stages of healing. The natural tendency of the vascular changes is to heal by organization, and it is likely that this process continues during remissions induced by cortisone therapy.



Left coronary artery showing interruption of the internal elastic lamina, extensive subintimal fibrosis, and perivascular fibrosis. (Verhoeff's elastic stain and van Gieson.  $\times 12$ .)

Little attention seems to have been given to the effects of cortisone treatment upon the appearance of the vascular lesions in this condition. In the present case both active and old organized foci were found at necropsy. Brunsting *et al.* (1951) stated that there was little alteration in the tissue changes following cortisone treatment. We conclude that by prolonging life it is likely that a greater proportion of organized lesions will be found at necropsy. No changes in the arteries so impressive as those found in polyarteritis nodosa after cortisone treatment by Baggenstoss *et al.* (1951) or after adrenocorticotrophic hormone by Symmers (1953) were to be seen, although the arterial lesions in the two diseases are in many ways alike, particularly when large vessels are affected.

### Summary

A case of disseminated lupus erythematosus is described in which gangrene affected both legs in turn.

Widespread, active, necrotizing vascular changes were found and many similar lesions which had undergone organization. Arterial thrombosis had occurred in the legs.

The effects of systemic cortisone treatment upon the vascular changes in this disease are briefly commented upon.

We wish to thank Dr. R. A. Hickling and Dr. B. Fowler for permission to publish this case.

### REFERENCES

- Baggenstoss, A. H., Shick, R. M., and Polley, H. F. (1951). *Amer. J. Path.*, 27, 537.  
 Brunsting, L. A., Stocumb, C. H., and Dicoct, J. W. (1951). *A.M.A. Arch. Derm. Syph.*, 63, 29.  
 Dubois, E. L. (1953). *Ann. Intern. Med.*, 38, 1265.  
 Gold, S. C., and Gowing, N. F. C. (1953). *Quart. J. Med.*, 22, 457.  
 Harvey, A. McG., Shulman, L. E., Tumulty, P. A., Conley, C. L., and Schoenrich, E. H. (1954). *Medicine (Baltimore)*, 33, 337.  
 Jessar, R. A., Lamont-Havers, R. W., and Ragan, C. (1953). *Ann. Intern. Med.*, 38, 717.  
 Kaposi, M. K. (1872). *Arch. Derm. Syph. (Wien)*, 4, 36.  
 Osler, W. (1895). *Amer. J. med. Sci.*, 110, 629.  
 Symmers, W. St. C. (1953). *J. Path. Bact.*, 66, 109.  
 Zarafonitis, C. J. D., Grekin, R. H., and Curtis, A. C. (1948). *J. Invest. Derm.*, 11, 359.

## CHRONIC NEPHRITIS DUE TO INGESTION OF LEAD-CONTAMINATED FLOUR

BY

VOJSLAV DANILOVIĆ, M.D.  
Belgrade

An unusually high incidence of chronic nephritis has been noted among the inhabitants of villages situated along the River Kolubara in Serbia. In an effort to find a cause for this my colleagues and I (Danilović *et al.*, 1957a, 1957b) investigated 12 families living in the village of Sopić, which seems to be the worst affected. During the last 15 years 37 members of these 12 families have died from chronic nephritis. Of the 44 members now living, 23 are suffering from nephritis, the 21 healthy members including mostly children and young adults.

The results of bacteriological investigation, including examination of throat swabs, determination of serum antistreptolysin titres, agglutination tests, and urine examination, were negative (Djurisić). The fact that a number of patients gave a history of attacks of lead colic prompted a search for a possible source of lead contamination, and the flour used in the district came under suspicion. This was ground at an ancient water-mill from corn grown by the peasants themselves. Analysis of samples of the flour showed the content

of lead to be five to ten times above the safety margin (Mokranjac). When the grindstones through which the corn passed were examined they were found to contain large quantities of lead; large amounts were also present in the material used for repairing holes in the stones. Further investigation showed four to five times more lead in the flour than in the original corn. No traces of lead were found in samples of the earth in which the corn was grown, in the water, or in the containers used for storage.

### Clinical and Laboratory Findings

The clinical picture in the affected cases was characteristic. Patients gave a history of a feeling of lassitude, repeated headaches, vague abdominal pains accompanied by constipation, and pains in muscles and joints. Four patients had suffered from lead colic. The blood pressure was raised in 20 cases. Signs of lead poisoning were seen in the gums in two cases. There was pallor, and in most cases haematological examination revealed a mild hypochromic anaemia with an erythrocyte count of 3-4 millions per c.mm. Two cases had punctate basophilia, the proportion of stippled cells being greater than three per thousand erythrocytes. The leucocyte count was normal. In 19 cases there was azotaemia, with a blood urea of more than 50 mg. per 100 ml. The lead content of the blood was high, amounting to 100-200 µg. per 100 ml. or more, in seven cases. Proteinuria occurred in 16 cases; the urinary content of coproporphyrin was increased in all cases. Changes in the fundus oculi were present in three cases.

### Post-mortem Examination

In one case in which death in uraemic coma occurred during the course of the investigation a diagnosis of nephrosclerosis arteriosclerotica saturnina was established at necropsy, the histological picture being that of "nephrosclerovascularis of the type nephrosclerosis arteriosclerotica-nephritis saturnina (Ignjačev)." The liver was found to contain 600 µg. of lead per 100 g. of tissue, and the kidneys and spleen 320 µg. per 100 g.; in the scalp hair there was 4 mg. and in the axillary hair 10 mg. Pb per kg., as compared with a normal content of 0.2-0.6 mg. per kg.

### Discussion

Our experience has shown that chronic nephritis following the continuous absorption of small quantities of lead through the alimentary tract is manifested by lassitude, headaches, abdominal pain with constipation, and pains in the muscles and joints. These are accompanied by an increase in arterial tension, a mild hypochromic anaemia, and a slight increase in blood urea (50-100 mg. per 100 ml.). A rise in the blood level of lead and an increased urinary excretion of coproporphyrin also occur and are significant findings. The disease may exist for many years in an apparently mild form, but when the blood urea rises above 100 mg. per 100 ml. the patient's condition becomes serious and death may supervene within a matter of months or at most one or two years. The disease has characteristic anatomic-pathological and histological features, and involves predominantly the cardiovascular system.

Our investigations have been extended to include other villages where the flour ground at the water-mill at Sopić is used. In our view the chronic nephritis here described is of more than local significance, and it is hoped that our continued investigations will throw further light on the pathogenesis and the clinical and anatomic-pathological features of this form of the disease.

### Summary

The frequency of chronic nephritis in a Serbian village has led to an investigation of 12 affected families, 37 of whose members have died from the disease in the last 15 years. Of the 44 members now living 23 suffer from