

Virus-Induced Animal Model of Osteosarcoma in the Rat

Morphologic and Biochemical Studies

Harry M. Olson, DVM, and Charles C. Capen, DVM, PhD

Osteosarcomas were produced by the intratibial inoculation of New Zealand black rats with Moloney sarcoma virus (MSV) at 1 day and 4 days of age. Radiographic evidence of osteosarcoma development was first demonstrated at 10 to 15 days postinoculation in both groups. Subsequent radiographic and light and electron microscopic evaluation of tumor-bearing rats demonstrated that osteosarcomas in rats inoculated at Day 4 of age were more osteoproliferative osteosarcomas than those in rats inoculated on Day 1. Rats inoculated at 4 days of age lived longer, had more slowly growing osteosarcomas, and developed a consistent tumor-associated cachexia compared to tumor-bearing rats inoculated at Day 1. Both groups of rats had a 93% metastasis rate involving either sublumbar lymph nodes, lungs, or both. Tumor-bearing rats inoculated at 4 days of age had consistent elevations in both urinary hydroxyproline excretion (HOP/CR) and serum alkaline phosphatase levels, and in serum calcium levels at some time points. The high tumor incidence after a short latent period and the morphologic and biochemical similarities between the MSV-induced murine osteosarcoma and the osteosarcoma in human beings makes this discrete tumor a valuable animal model for the evaluation of new therapeutic regimens. (*Am J Pathol* 86:437-458, 1977)

OSTEOSARCOMA is an important neoplastic disease in young adults, characterized by a rapid progression with the development of metastases and a very low survival rate. Recent reports have suggested a viral etiology for human osteosarcoma,^{1,2} but no viruses have been isolated from human osteosarcoma tissue. Osteosarcomas have also occurred in children following ²²⁴Ra therapy for tuberculosis and other diseases³ and have been associated with high plasma somatomedin levels.⁴ Current therapeutic regimens have been moderately successful in offsetting the high mortality associated with this disease. Surgical ablation accompanied by radiotherapy has produced a 5-year survival rate of only 20%.⁵ Preliminary results indicate that immunotherapy of osteosarcoma does not substantively increase the survival rate.⁶ At the present time, surgical ablation followed by chemotherapeutic regimens to destroy metastatic foci provides the best therapeutic result.^{7,8} These clinical results suggest that a

From the Department of Veterinary Pathobiology, College of Veterinary Medicine, The Ohio State University, Columbus, Ohio.

Supported in part by Grants GM-1052 and RR-05463 from the National Institutes of Health and by Fellowship CA-00549 from the National Cancer Institute.

Accepted for publication September 3, 1976.

Address reprint requests to Dr. Harry M. Olson, Department of Veterinary Pathobiology, College of Veterinary Medicine, The Ohio State University, 1925 Coffey Road, Columbus, OH 43210.

well-characterized and reproducible animal model of osteosarcoma would be useful in a) further understanding the biologic behavior of this neoplasm and b) developing new therapeutic regimens for osteosarcoma.

Bone tumors characterized as osteosarcomas have been produced by viruses,^{2,9-12} chemicals,^{13,14} and radiation^{12,15} in several species. Most of these have been induced by the intravenous or intraperitoneal instillation of the inciting agent, resulting in multicentric osteosarcomas,^{9-12,15} unlike the typical situation in man. Some of these tumor systems are also characterized by the concurrent development of sarcomas in tissues other than bone^{9,10,13,14} and by long latent periods.^{9,12,15} We produced osteosarcomas by the intratibial instillation of Moloney sarcoma virus (MSV) in neonatal rats, as reported by Ikemoto *et al.*¹⁶ In a preliminary report,¹⁷ we noted an age-related susceptibility to MSV-induced osteosarcomas in the rat and indicated that rats inoculated at 4 days after birth (compared to 1 day) develop more osteoproliferative bone neoplasms. The objective of this investigation was to characterize the MSV-induced osteosarcoma in rats inoculated at 1 day and 4 days of age by macroscopic, radiographic, light, and electron microscopic parameters and by selected biochemical indices reportedly altered in human osteosarcoma.

Materials and Methods

Animals and Virus Preparation

One-day-old (<24 hours) and 4-day-old New Zealand black (NZB) rats from a breeding colony (kindly supplied by Mr. Clarence Reeder, Drug Research and Development Branch, National Cancer Institute) were inoculated by intratibial instillation of a partially purified preparation of MSV (courtesy of Dr. David Howell, Viral Oncology, National Cancer Institute). The inoculum or standard viral preparation (SVP) consisted of the MSV (Lot MSV-B-77, from BALB/c mice), titered at $10^{6.7}$ to $10^{6.8}$ focus-forming units/ml, diluted 1 : 7 with a diluent consisting of 2% inactivated fetal calf serum and 1% antibiotics without Mycostatin in sterile physiologic saline. Rats received a constant volume (either 0.025 or 0.05 ml) of SVP in one or both tibias. Control rats received an equal volume of diluent with citrate buffer approximating the concentration in the SVP by intratibial instillation.

Experimental Design and Sample Preparation

Pathogenesis Experiment and Survival Study

Rats inoculated at 1 (4 litters, 32 rats) and 4 (5 litters, 38 rats) days of age were monitored for the development of osteosarcomas by palpation and radiography. Rats were palpated daily from 5 days postinoculation (PI) until Day 30 PI and were radiographed on Days 8, 10, 12, 15 and 20 PI, and thereafter at 10-day intervals until Day 100 PI. Radiographs were taken with a General Electric Model 11AA-3A x-ray unit (25 or 30 kV, 5 mA, 10 or 12 sec/exposure) and Kodak no-screen medical X-ray film (Ready Pack NS 2T). Tumor-bearing rats (18 rats from Day 1, 14 rats from Day 4) were then monitored on a

daily basis for mortality rates. Cumulative mortality data were tabulated, and rats were necropsied for evaluation of the occurrence of metastatic disease.

Tumor-Associated Cachexia, Tumor Development, and Biochemical Studies

Beginning at 30 days PI tumor-bearing and control rats were weighed at 10-day intervals on a Mettler P 1000 N top loading balance. At Days 25 and 30 PI and subsequently at 10-day intervals, tumor-bearing and control rats were placed in metabolism cages to collect 24-hour urine samples under toluene. Aliquots of urine were assayed for total urinary hydroxyproline (HOP)¹⁸ and creatinine (CR).¹⁹ Final values were expressed as a HOP/CR ratio to correct for variations in urine concentration. At these same time intervals, tumors were measured in three dimensions (length, width, and thickness) with Helios stainless steel calipers, and the average tumor diameter computed.

Serum samples were collected at 10-day intervals from Day 30 PI under light ether anesthesia from the retroorbital sinus or terminally from the abdominal aorta. Serum calcium was determined by atomic absorption spectrophotometry (Perkin-Elmer model 303) and alkaline phosphatase by the method of Hausamen *et al.*²⁰ Statistical analyses of data were performed using Student's *t* test²¹ and 2 × 2 contingency tables.²²

Light and Electron Microscopic Study

Tissues were collected from rats that died and from rats that were killed at specific time points after inoculation. At necropsy, sections of osteosarcoma, sublumbar lymph node, lung (including bronchial lymph nodes), thymus, spleen, liver, kidney, intestine, and thyroid were fixed in 10% neutral buffered formalin, decalcified where necessary for 7 days in 10% buffered EDTA, embedded in paraffin, sectioned at 6 μ , and stained with hematoxylin and eosin (H&E). Multiple sections from the osteosarcomas (Day 1, 10 tumors; Day 4, 6 tumors) of killed rats were minced immediately under fixative into 1 cu mm blocks, fixed in cold 3% glutaraldehyde with 0.1 M sodium cacodylate buffered at pH 7.4, postfixed in 1% osmium tetroxide in *s*-collidine, dehydrated in graded ethanols, transferred to propylene oxide, and embedded in "hard" Epon (Shell Chemical Company, New York, N.Y.). Thin sections were cut with a diamond knife on an LKB ultramicrotome and floated on a water bath buffered at pH 7.4 to prevent demineralization. Sections were stained with uranyl acetate and lead citrate and were examined with a Philips 200 electron microscope.

Results

Pathogenesis Experiment

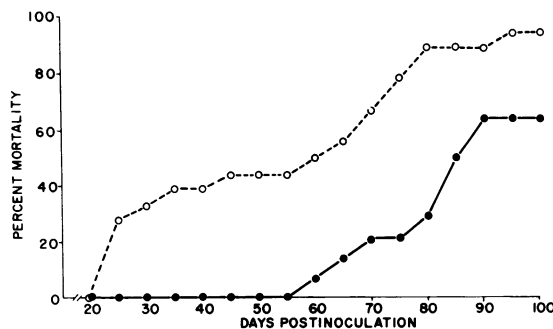
Initiation and development of osteosarcomas in rats inoculated with the SVP at 1 day of age (<24 hours old) were observed radiographically as early as 10 to 12 days PI (11/12 rats). A small radiodense zone was observed with focal lysis of the tibial diaphysis (Figure 1A). Neoplastic cells appeared to arise from the endosteal surface proliferating within the metaphysis and diaphysis at Day 14 PI with infiltration and disruption of the tibial cortex (Figure 1B). Many osteosarcomas grew rapidly, producing disruption of the tibial cortex and compression of the adjacent musculature. At Day 20 PI the osteosarcomas had attained an average diameter of more than 1 cm. Radiographs showed both radiolucent zones and irregular dense spicules (Figure 1C) in the osteosarcomas. The densely cellular sarcomatous proliferation was surrounded by a prominent chon-

droid border (Figure 1D). Not all osteosarcomas developed this rapidly in rats inoculated at Day 1 of age. Daily palpation and periodic radiographs of many inoculated litters of rats indicated that the latent period was occasionally greater than 12 days, and sometimes palpable tumors were not observed until Day 23 PI (6% of inoculated rats).

Rats inoculated at Day 4 after birth developed palpable and/or radiographic evidence of tumor development as early as the 12th day after inoculation. Most tumors were palpable by Day 15 PI (6 of 8 rats), but some tumors did not appear until as late as Day 24 PI (3% of inoculated rats). Radiographically, the osteosarcomas that developed early were similar to those described following inoculation at Day 1 of age, but at Day 20 PI they were histologically more differentiated neoplasms with considerable mineralized matrix.

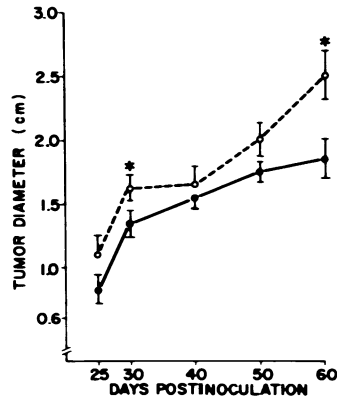
Survival and Tumor Development Study

Tumor-bearing rats inoculated at 4 days of age lived significantly longer than rats inoculated at 1 day of age (Text-figure 1). Litters of rats inoculated at 1 day (4 litters) and 4 days (5 litters) of age were observed for 100 days PI. By 25 days PI, 25% of tumor-bearing rats inoculated at 1 day of age had died, whereas the earliest death observed in rats inoculated at 4 days of age was at Day 60 PI. By Day 100 PI, 95% of rats inoculated at 1 day of age had died, compared with 64% of rats inoculated at 4 days of age. No control rats of either group died during the same periods of observation. Tumor growth was rapid during the early weeks in both groups of inoculated rats (Text-figure 2). The degree of variability in tumor size was considerable in both groups of rats. Nonetheless, the mean diameters of osteosarcomas in rats inoculated at Day 1 was consistently



TEXT-FIGURE 1—Cumulative mortality data for tumor-bearing rats inoculated intratibially with MSV on Day 1 (*open circles*) and Day 4 (*solid circles*) of age. The mortality incidence of rats inoculated at Day 1 ($N = 18$) is significantly greater (at $P > 0.05$ level or greater) than for rats inoculated at Day 4 ($N = 14$) at all time points after Day 20 PI except at 90 days PI ($P > 0.05$).

TEXT-FIGURE 2—Rate of tumor growth in rats inoculated with MSV on day 1 (*open circles*) and day 4 (*solid circles*) of age. The *bars* indicate standard error of the mean and the *asterisks* indicate significant difference of means at $P < 0.05$ or greater.



greater than for rats inoculated at Day 4. The difference was significant at Days 30 and 60 PI. Striking differences were also observed in the radiodensity and gross consistency of the tumors in the two groups. Osteosarcomas in rats inoculated on Day 4 of age were radiodense, firm and contained abundant mineralized stroma. Conversely, rats inoculated on Day 1 of age developed osteosarcomas with large radiolucent zones that were fleshy and contained extensive areas of necrosis.

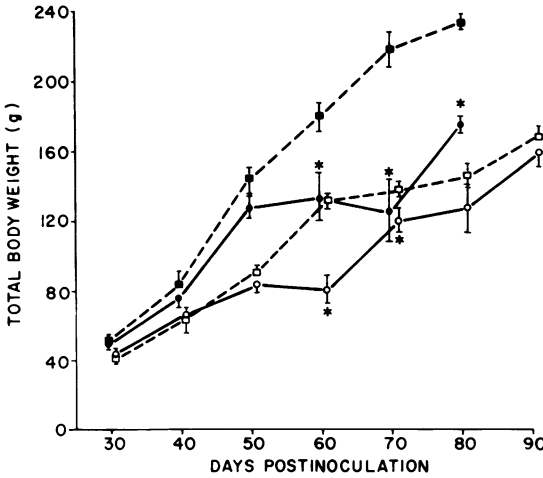
Tumor-Associated Cachexia

The development of rapidly growing osteosarcomas was commonly accompanied by progressive wasting. Tumor-bearing rats failed to achieve the weight gains of their respective controls (Text-figure 3). Male ($N = 10$) and female ($N = 17$) tumor-bearing rats inoculated at 1 day of age had significant weight loss compared to their respective controls on Days 60 and 70 PI, and tumor-bearing males at Day 80 PI. At Days 80 and 90 PI, the mean weight of female rats with tumors was less than that of control female rats, although the differences were not significant. Few rats of either sex with tumors lived beyond Day 80 PI.

Text-figure 4 shows the cachexia developing in tumor-bearing male ($N = 13$) and female ($N = 12$) rats inoculated 4 days after birth compared to that of controls. Female rats with osteosarcoma developed a significant loss in body weight by 40 days PI. Thereafter, both male and female tumor-bearing rats consistently failed to match the weight gains of their respective controls throughout the time period evaluated (up to Day 90 PI).

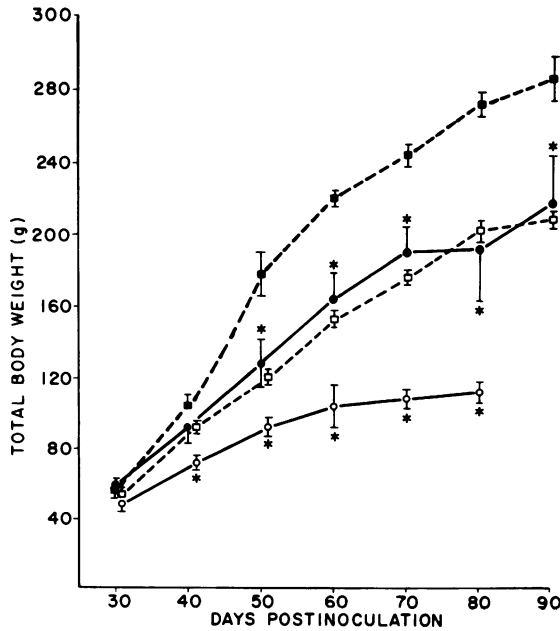
Radiographic and Light and Fine Structural Features of Osteosarcomas

Radiographic and histologic evaluation of osteosarcomas produced after inoculation of rats at 1 day and 4 days of age revealed the development of



TEXT-FIGURE 3—Tumor-associated cachexia in tumor-bearing male (*solid circles*) and female (*open circles*) rats inoculated with MSV < 24 hours after birth. Age-matched control male (*solid squares*) and female rat (*open squares*) mean weights are shown. The bars represent standard error of the mean and the asterisks indicate significant difference of means at $P < 0.05$ or greater.

markedly different bone neoplasms in these two groups. Neoplasms in rats inoculated with the SVP on Day 1 were radiolucent tumors with fine interspersed radiodense spicules. They were densely cellular and composed of pleomorphic tumor cells with large, prominent (occasionally multiple) nuclei with coarsely clumped chromatin and a vacuolated cy-



TEXT-FIGURE 4—Tumor-associated cachexia in tumor-bearing and control male and female rats inoculated at 4 days of age. Symbols as in Text-figure 3.

toplasm (Figure 2). Smaller isomorphic cells resembling osteoblasts and fibroblasts were interspersed throughout the neoplasm. Occasional fine spicules of osteoid or chondroid matrix were observed in the tumors (Figure 3) as well as in broad zones of central necrosis. In some areas of the osteosarcoma, large giant cells containing 20 or more evenly distributed nuclei were observed either in association with bone matrix or located within the densely cellular areas of the tumor. Areas of chondroid differentiation (Figures 1D and 3) were most often seen at the periphery of the rapidly growing neoplasms during the early weeks of development.

Rats inoculated with MSV on Day 4 after birth developed more uniformly radiodense osteosarcomas with only small lucent zones. These tumors were characterized histologically by the presence of an abundant osteoid stroma. Some areas of chondroid were present, but osteoid differentiation was more commonly observed. Pleomorphic tumor cells were interspersed between well-differentiated osteoblasts lining the osteoid stroma (Figure 4). Multinucleated osteoclasts also were observed in the osteosarcomas that developed in rats inoculated at 4 days of age.

Histologic evaluation of sublumbar lymph nodes and lungs revealed 94% (17 of 18) of rats inoculated at Day 1 and 93% (13 of 14) of tumor-bearing rats inoculated at Day 4 had metastatic lesions. Although metastases were composed of similar types of cells as in the primary neoplasm, they infrequently produced an osteoid matrix. Tumor cells were observed within vascular channels in the lungs and occasionally large metastatic nodules compressed adjacent pulmonary tissue (Figure 5). Most metastatic lesions were occult, depending upon microscopic examination for detection; however, sublumbar lymph nodes with metastases were sometimes grossly enlarged. When osteosarcomas developed unilaterally, metastatic lesions were present only in the ipsilateral sublumbar node. Evaluation of other major organs in tumor-bearing rats revealed no evidence of metastases, except in 2 rats where histologically benign proliferative lesions were present in the mandible and ribs. In addition, no other neoplasms developed in any control or MSV-inoculated rats during the period of observation (until death or Day 150 PI).

Ultrastructural evaluation of osteosarcomas from rats inoculated at Days 1 and 4 after birth revealed a spectrum of tumor cell types. Many neoplastic cells were poorly organized with an irregular villous cell membrane and one or more irregular, eccentrically located nuclei. Most of the cells had scattered mitochondria, dilated rough endoplasmic reticulum, a large Golgi apparatus, and clusters of free ribosomes (Figure 6). These cells were most frequently observed in osteosarcomas from rats inoculated at 1 day of age. Other tumor cells resembling osteoblasts had a large

nucleus with condensed nuclear chromatin and an irregular cytoplasmic outline (Figure 7). Their abundant cytoplasmic area was filled with rough endoplasmic reticulum, mitochondria, and a few homogeneous electron-dense bodies. These osteoblastic tumor cells were surrounded by osteoid (Figure 7). Many neoplastic cells had prominent dilated endoplasmic reticulum filled with a finely granular proteinaceous material. In some neoplastic cells, this proteinaceous material was condensed in a circular or branching pattern in the dilated cisternae (Figure 8). Occasional tumor cells in all neoplasms evaluated by electron microscopy had intercellular tight junctions or zonulae occludentes (Figure 9). Microtubules and microfilaments (Figure 10) were seen frequently interspersed throughout the cytoplasm in tumor cells.

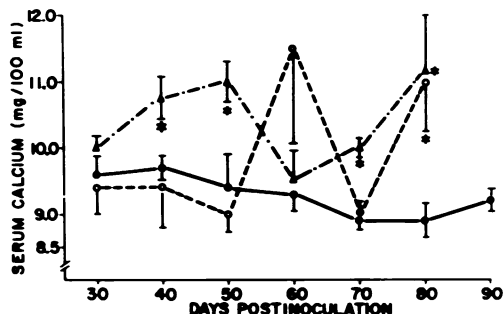
Ultrastructural evaluation of osteosarcomas from rats inoculated at 4 days of age revealed many well-differentiated osteoblasts surrounded by a fibrillar osteoid stroma with a mineralization front (Figure 11). The majority of cells observed in these tumors were ovoid or fusiform, with abundant profiles of endoplasmic reticulum, mitochondria, and lysosomal bodies within the cytoplasm (Figure 11). The nuclei each had a smooth nuclear membrane and a single prominent nucleolus. Cytoplasmic processes extended into the adjacent osteoid stroma, which contained foci of mineralization (Figure 11). Giant cells with multiple nuclei distributed throughout the cell were observed in tumors from both groups of rats. They contained abundant mitochondria interspersed throughout the cytoplasm, and perinuclear Golgi apparatus. Most giant cells observed ultrastructurally were not associated with mineralized matrix.

C-type viral particles were frequently observed budding from the plasma membrane of all types of cells within these osteosarcomas (Figure 12). Virus particles often were observed between the cytoplasmic interdigitations of tumor cells. Viral budding also was observed from the plasma membrane of superficial osteocytes (Figure 12, inset) into the lacunar space, which contained numerous mature C-type particles. A-type virus particles were seen frequently within dilated cisternae of rough endoplasmic reticulum in neoplastic cells.

Biochemical Investigations

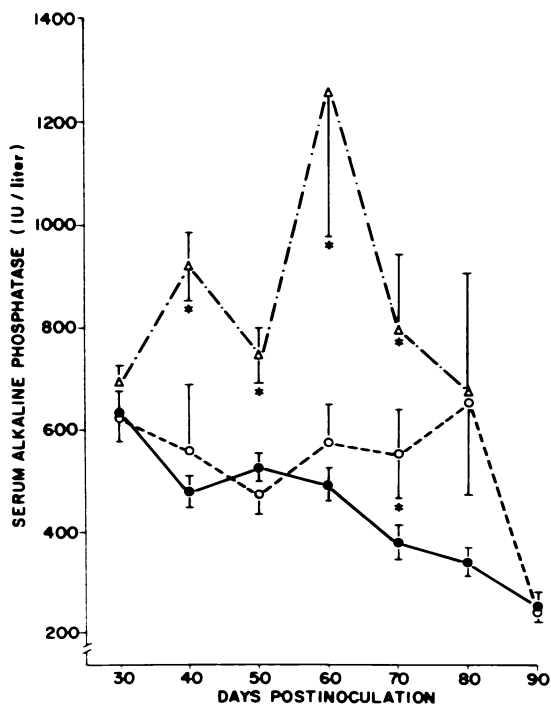
Rats inoculated with the SVP on Day 4 of age developed significant elevations of serum calcium (Text-figure 5) and alkaline phosphatase levels (Text-figure 6) (N = 9) when compared to those of controls (N = 7). Conversely, significant elevations in both parameters were observed infrequently in rats inoculated 1 day after birth (N = 7) (Text-figures 5 and 6). On Days 40, 50, and 70 PI, both serum calcium and alkaline phosphatase

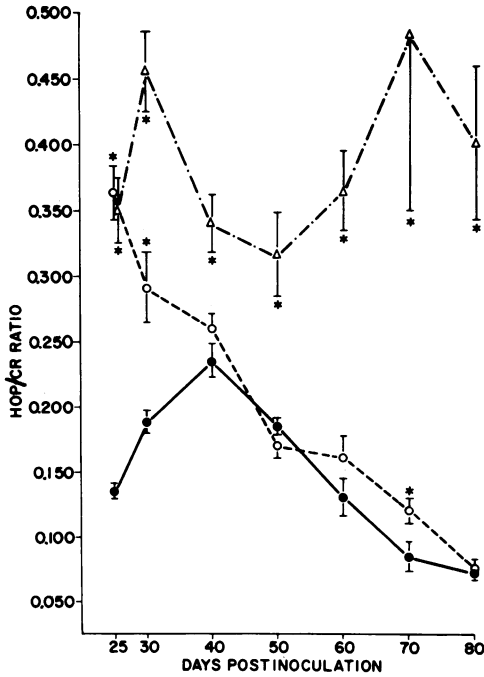
TEXT-FIGURE 5—Total serum calcium in control (*solid circles*) rats, and tumor-bearing rats inoculated at 1 day of age (*open circles*) and 4 days of age (*open triangles*). Bars indicate standard error of the mean, and the *asterisks* indicate significant difference of means at $P < 0.05$ or greater.



tase levels in rats inoculated on Day 4 were significantly elevated over corresponding control values, and alkaline phosphatase was also significantly elevated at Day 60 PI. Serum calcium but not alkaline phosphatase was significantly elevated at Day 80 PI in rats inoculated on Day 4. At Day 60 PI the mean serum calcium value from tumor-bearing rats inoculated on Day 1 was greater than corresponding control values, resulting from hypercalcemia as high as 15.7 mg/100 ml serum in 1 rat. These differences were not significantly different from control rats evaluated at Day 60 PI.

TEXT-FIGURE 6—Serum alkaline phosphatase in control (*solid circles*) rats, and tumor-bearing rats inoculated at 1 day of age (*open circles*) and 4 days of age (*open triangles*). Symbols as in Text-figure 5.





TEXT-FIGURE 7—Urinary hydroxyproline excretion (HOP/CR) in control (solid circles) rats and tumor-bearing rats inoculated at 1 day of age (open circles) and 4 days of age (open triangles). Symbols as in Text-figure 5.

Urinary hydroxyproline excretion (expressed as HOP/CR) was significantly elevated in both groups of tumor-bearing rats compared to controls at Days 25 and 30 PI and again at Day 70 (Text-figure 7). Sustained high levels of hydroxyproline excretion were observed for rats inoculated at Day 4 of age ($N = 9$) compared to controls ($N = 5$) at all time points evaluated. For tumor-bearing rats inoculated at Day 1 of age ($N = 10$), no other data points were significantly different from corresponding controls ($N = 5$).

Discussion

In this investigation, we report the pathogenesis and the morphologic, biochemical and tumor-associated characteristics of the intratibial MSV-induced osteosarcoma in the rat. As opposed to other published models of osteosarcoma, either spontaneous²³⁻²⁵ or induced,^{9-15,24,25} this animal model combines the advantages of reproducibility and high tumor incidence with a brief latent period. These discrete osteosarcomas can be subjected to numerous evaluation procedures including palpation, measurement, biopsy, and surgical excision. In addition, other neoplasms arising in conjunction with or as a result of the inoculation of MSV were not observed, thus providing an uncomplicated *in vivo* tumor system.

In previous communications^{17,26} we reported an age-related tumor incidence of MSV-induced murine osteosarcoma. Age susceptibility to viral transformation also has been demonstrated with Gross virus-induced lymphoma in rats.²⁷ While osteosarcomas in our studies occurred with a similar high incidence in rats inoculated at 4 days of age compared to rats inoculated at Day 1, the former group had consistently more osteoproliferative neoplasms on the basis of radiographic, gross, and microscopic evaluation.¹⁷ These findings suggested that the age of the rat at inoculation of the MSV may be significant in the subsequent development of different types of osteogenic sarcomas. The exposure of a more differentiated population of bone cells in older rats (Day 4 of age) to the MSV may be related to the subsequent development of more osteoproliferative bone tumors compared to rats inoculated at 1 day of age.

The results of the pathogenesis study indicated an average latent period of 10 to 12 days in rats inoculated on 1 day of age. These findings are compatible with results recently reported by Friedlaender *et al.*²⁸ In observations of rats up to 150 days PI, we have noted that rats inoculated intratibially either develop palpable tumors by 30 days PI or do not develop osteosarcomas at all. We have further defined the neoplasm as arising from the endosteal surface of bone following inoculation of MSV in the marrow space. Fujinaga *et al.*²⁹ reported the periosteal proliferation of multicentric MSV-induced osteosarcomas in hamsters and rats following intraperitoneal inoculation. This may be explained on the basis of a vascular distribution following inoculation of the virus. We hypothesize that the viral transformation of osteoprogenitor cells in rats inoculated on Day 1 gives rise to poorly differentiated osteosarcomas with minimal osteoid formation. Rats inoculated at 4 days of age had a slightly longer latent period (10 to 15 days) and developed more typically osteoproliferative bone tumors. This may be the result of MSV-induced transformation and subsequent proliferation of more differentiated, osteoblastic cells capable of forming abundant osteoid.

Osteosarcomas in both groups of rats were very rapidly growing. Despite some variability in tumor size within each group, the mean tumor diameter of rats inoculated at 1 day of age was consistently greater than that of rats inoculated at 4 days of age. This suggests that osteosarcomas may grow more rapidly in rats inoculated at an earlier age. In a previous report,¹⁷ we indicated that 14% of rats inoculated with 0.05 ml of MSV at 10 days of age developed palpable osteosarcomas. These tumors averaged only 0.8 cm in diameter at 50 days PI. We observed that by Day 60 PI, many rats inoculated with MSV at Day 1 of age had large osteosarcomas which impeded functional utilization of the limb, compared to the smaller

neoplasms in the rats inoculated at 4 days of age. In addition, tumor necrosis was frequently observed in the group inoculated at 1 day of age by 60 days PI but was rarely seen in tumors of rats inoculated on Day 4.

Tumor-associated cachexia, as evaluated by significant weight loss in comparison to age and sex-matched controls, was observed in both groups of rats at several time points in both sexes. Patients with osteosarcoma and other neoplastic diseases often have cachexia which is hypothesized to be related to anorexia, tumor necrosis, water and electrolyte abnormalities, increased basal metabolic rate, and severe derangement of host metabolic patterns.³⁰

Light microscopic study of osteosarcomas in rats inoculated at 1 day of age was similar to previously published investigations of virus,^{9-12,16,28,29} chemical,^{13,14} and radiation-induced^{12,15} experimental osteosarcomas. We did observe a consistently high incidence (93%) of metastases either within sublumbar lymph nodes, lungs, or both in tumor-bearing rats. Those rats in which no microscopic evidence of metastatic disease was observed usually had small or very slowly growing neoplasms, and may have been "regressors"²⁸ or rats in which osteosarcoma growth ceased at some point as a result of either cell-mediated or humoral immune response against the neoplasm. A recent study investigating the immunologic responsiveness of rats to osteosarcomas induced by intratibial inoculation of MSV reported both cell-mediated immunity (CMI) and serum factors capable of augmenting or decreasing the *in vitro* CMI response. In another investigation the humoral immunologic response was greatest in rats with regressing neoplasms.³¹ These findings are significant in the light of recent reports of a tumor-specific immune response in patients with osteosarcoma,³² and suggest a basic immunologic similarity between this model and the natural human neoplasm.

Recent reports of human osteosarcoma³³⁻³⁶ described the spectrum of cell types in these neoplasms and evaluated their fine structural features. In our investigations, tumors from rats inoculated at Day 1 of age were composed predominately of poorly differentiated bone cells. Large cells with poorly differentiated cytoplasmic organelles resembled osteoprogenitor cells. In more differentiated osteoblast-like cells, an extensive network of endoplasmic reticulum was seen which often contained finely granular or condensed flocculent material in dilated cisternae similar to that described in human osteosarcomas.³³⁻³⁷ The nature of the branched material is not known,³⁶ although the production of an abnormal matrix protein has been postulated.³⁷

Intercellular tight junctions were frequently seen between well-differentiated neoplastic cells, similar to those described between osteoblasts and osteocytes in normal bone.³⁸ These zonulae occludentes in normal

bone are considered to be associated with the intercellular transport of nutrients and electrolytes and have been described both in human osteosarcoma³⁸ and in a recent ultrastructural study of canine osteosarcoma.³⁹

Osteosarcomas in rats inoculated at Day 4 of age were composed predominantly of well-differentiated osteoblastic cells, frequently surrounded by partially mineralized osteoid matrix, similar to human osteogenic sarcomas.^{33,34} Primitive cells and bone cells in varying stages of differentiation also were present but were considerably less numerous than in tumors from the Day 1 group. Budding and mature C-type virus particles were observed frequently and were similar to those described in other MSV-induced osteosarcomas.^{10,29} Viral particles were seen between interdigitating plasma membranes of anaplastic tumor cells, as well as along plasma membranes of neoplastic osteoblasts and osteocytes in both groups of rats. Microfilaments and microtubules were observed within the cytoplasm of neoplastic cells from all tumors and appeared similar to those described in human osteosarcoma cells.^{33,36}

Additional evidence for the development of two types of osteosarcomas with different biologic characteristics is indicated by the sustained increased excretion of urinary hydroxyproline (HOP/CR) only in tumor-bearing rats inoculated at Day 4. This indicates a more rapid turnover of bone matrix,⁴⁰ compared to both tumor-bearing rats (Day 1 group) and to controls. Elevated HOP excretion has been reported in the majority of human osteosarcoma patients.⁴¹ This is in agreement with our histologic and ultrastructural observation that tumors in rats inoculated on Day 4 are primarily osteoproliferative, with production and breakdown of osteoid matrix. Further support for these differences between osteosarcomas in rats inoculated at Day 1 and 4 of age was seen with the elevated serum alkaline phosphatase and calcium values. Alkaline phosphatase was elevated in rats inoculated at 4 days of age with more osteoblastic neoplasms that released this enzyme into the serum. Murine osteosarcomas have been reported to elaborate alkaline phosphatase, which is released into the culture medium.⁴² Preliminary findings in our laboratory demonstrate that the bone isoenzyme constitutes the major fraction in rats in the Day 4 group with marked serum alkaline phosphatase elevations.

Hypercalcemia associated with malignancy has been described in numerous neoplastic disorders but is not consistently observed in human osteosarcoma. The hypercalcemia in this model is sporadic but occurs in some rats of both groups at certain time points. Many factors may be responsible for the hypercalcemia of malignancy⁴³ and its control may have a direct bearing on prognosis of the osteosarcoma.

There has been considerable interest recently in the development of

animal models for osteosarcoma since this is a serious disease of young adults and current therapeutic measures to manage its progression have been only moderately successful. This report presents a murine model of osteosarcoma which features a discrete, manipulable neoplasm produced with a high incidence after a short latent period with significant differences in biologic activity and effects on the host depending upon time of viral inoculation. The MSV-induced osteosarcoma should be a valuable animal model to investigate the biologic behavior of osteosarcoma and to evaluate new therapeutic regimes.

References

1. Morton DL, Malmgren RA: Human osteosarcomas: Immunologic evidence suggesting an associated infectious agent. *Science* 162:1279-1281, 1968
2. Pritchard DJ, Reilly CA Jr, Finkel MP: Evidence for a human osteosarcoma virus. *Nature (New Biol)* 234:126-127, 1971
3. Spiess H: ²²⁴Ra-induced tumors in children and adults. *Delayed Effects of Bone-Seeking Radionuclides*. Edited by CW Mays, WSS Jee, RD Lloyd, BJ Stover, JH Dougherty, GN Taylor. Salt Lake City, University of Utah Press, 1969, pp 227-247
4. McMaster JH, Scranton PE, Drash AL: Growth and hormone control mechanisms in osteosarcoma: Evidence for a new therapeutic approach. *Clin Orthop* 106:366-376, 1975
5. Stein JJ: Osteogenic sarcoma (osteosarcoma): Results of therapy. *Am J Roentgenol* 123:607-613, 1975
6. Eilber FR, Townsend C, Morton DL: Osteosarcoma: Results of treatment employing adjuvant immunotherapy. *Clin Orthop* 111:94-100, 1975
7. Jaffe N, Frei E III, Traggis D, Bishop Y: Adjuvant methotrexate and citrovorum-factor treatment of osteogenic sarcoma. *N Engl J Med* 291:994-997, 1974
8. Cortes EP, Holland JF, Wang JJ, Sinks LF, Blom J, Hansjurg S, Bank A, Glidewell O: Amputation and adriamycin in primary osteosarcoma. *N Engl J Med* 291:998-1000, 1974
9. Diamandopoulos GT: Induction of lymphocytic leukemia, lymphosarcoma, reticulum cell sarcoma, and osteogenic sarcoma in the Syrian golden hamster by oncogenic DNA simian virus 40. *J Natl Cancer Inst* 50:1347-1365, 1973
10. Soehner RL, Dmochowski L: Induction of bone tumors in rats and hamsters with murine sarcoma virus and their cell-free transmission. *Nature* 224:191-192, 1969
11. Finkel MP, Biskis BO, Jinkins PB: Virus induction of osteosarcomas in mice. *Science* 151:698-701, 1966
12. Finkel MP and Biskis BO: Experimental induction of osteosarcomas. *Prog Exp Tumor Res* 10:72-111, 1968
13. Pelfreney A, Mirvish SS, Gold B: Induction of malignant bone tumors in rats by 1-(2-hydroxy-ethyl)-1-nitrosourea. *J Natl Cancer Inst* 56:445-446, 1976
14. Yamada M: Experimental studies of bone tumors induced in mice by 20-methylcholanthrene. *Excerpta Med* 13:989, 1965 (Abstr)
15. Janes JM, Higgins GM, Heirick JF: Beryllium-induced osteogenic sarcoma in rabbits. *J Bone Joint Surg* 36B:543-552, 1954
16. Ikemoto K, Yamamoto T: Induction of rat osteosarcoma by inoculation of murine sarcoma virus into bone marrow. *Gann* 63:141-142, 1972
17. Olson HM, Capen CC: Intratibial Moloney sarcoma virus-induced osteosarcoma in the rat: Tumor incidence and pathologic evaluation. *J Natl Cancer Inst* 1977 (In press)

18. Kivirikko KI, Laitinen O, Prockop DJ: Modifications of specific assay for hydroxyproline in urine. *Anal Biochem* 19:249-255, 1967
19. Clarke JT: Colorimetric determination of urinary creatinine and creatine. *Clin Chem* 7:371-383, 1961
20. Hausamen TU, Helger R, Rick W, Gross W: Optimal conditions for the determination of serum alkaline phosphatase by a new kinetic method. *Clin Chim Acta* 15:241-245, 1967
21. Steel RGD, Torrie JH: Principles and Procedures of Statistics, New York, McGraw-Hill Book Co, Inc, 1960
22. Finney DJ, Latscha R, Bennett BM, Hsu P: Tables for Testing Significance in a 2×2 Contingency Table. Cambridge, Cambridge University Press, 1963
23. Brodey RS, Riser WH: Canine osteosarcoma: A clinicopathologic study of 194 cases. *Clin Orthop* 62:54-64, 1969
24. Owen LN: Transplantation of canine osteosarcoma. *Eur J Cancer* 5:615-620, 1969
25. Thurman GB, Mays CW, Taylor GN, Keane AT, Sissons HA: Skeletal location of radiation-induced and naturally occurring osteosarcomas in man and dog. *Cancer Res* 33:1604-1607, 1973
26. Olson HM, Capen CC: Moloney-sarcoma virus (MSV)-induced osteosarcoma in the rat: Ultrastructural and histopathologic studies. *Lab Invest* 34:328-329, 1976 (Abstr)
27. Joachim HL, Cali A, Sinha D: Age-dependent transplantability in rats of virus-induced thymic lymphoma cultured in vitro. *Cancer Res* 25:132-139, 1965
28. Friedlaender GE, Mitchell MS: A laboratory model for the study of the immunobiology of osteosarcoma. *Cancer* 36:1631-1639, 1975
29. Fujinaga S, Poel WE, Dmochowski L: Light and electron microscope studies of osteosarcomas induced in rats and hamsters by Harvey and Moloney sarcoma viruses. *Cancer Res* 30:1698-1708, 1970
30. Theologides A: Pathogenesis of cachexia in cancer: A review and a hypothesis. *Cancer* 29:484-488, 1972
31. Evans DL, Barnett JW, Dmochowski L: Immunological responsiveness in rats infected with the Soehner-Dmochowski murine sarcoma virus (MSV-SD). *Tex Rep Biol Med* 32:449-460, 1974
32. Gainor BJ, Forbes JT, Enneking WF, Smith RT: A method of immunologic assay in human osteosarcoma: Specific antigen stimulated lymphocyte proliferation in osteosarcoma. *Clin Orthop* 111:83-93, 1975
33. Ghadially FN, Mehta PN: Ultrastructure of osteogenic sarcoma. *Cancer* 25:1457-1467, 1970
34. Kay S: Ultrastructure of an osteoid type of osteogenic sarcoma. *Cancer* 28:437-445, 1971
35. Williams AH, Schwinn CP, Parker JW: The ultrastructure of osteosarcoma. *Lab Invest* 32:440, 1975 (Abstr)
36. Paschall HA, Paschall MM: Electron microscopic observations of 20 human osteosarcomas. *Clin Orthop* 111:42-56, 1975
37. Brown GA, Cooper RR, Maynard JA, Bonfiglio M: Endoplasmic reticulum size and morphology in bone disorders: Relation to protein synthesis and malignancy. *Clin Orthop* 101:278-285, 1974
38. Holtrop ME, Weinger JM: Ultrastructural evidence for a transport system in bone. Calcium, Parathyroid Hormone and the Calcitonins. Edited by RV Talmage, PL Munson. Chapel Hill, N.C., Excerpta Medica, 1972, pp 365-374
39. Pool RR, Wolf HG: An unusual case of canine osteosarcoma. *Cancer* 34:771-779, 1974
40. Weiss PH, Klein L: The quantitative relationship of urinary peptide hydroxyproline excretion to collagen degradation. *J Clin Invest* 48:1-10, 1969

41. Radom S, Zulawski M, Golebiowska D: Urinary hydroxyproline, serum alkaline phosphatase, calcium and phosphorus in patients with bone neoplasms. *Pol Med J* 11:809-814, 1972
42. Amitani K, Nakata Y: Establishment and alkaline phosphatase activity of clonal cell lines of murine osteosarcomas: A preliminary study. *Clin Orthop* 113:164-167, 1975
43. Tashjian AH: Tumor humors and the hypercalcemias of cancer. *N Engl J Med* 290:905-906, 1974

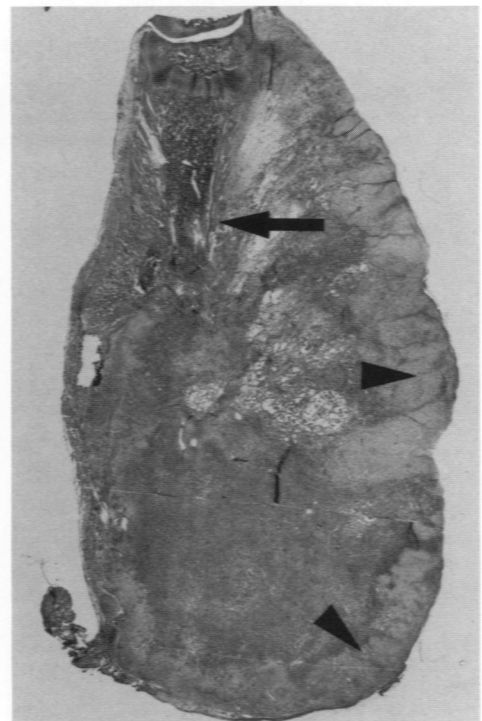
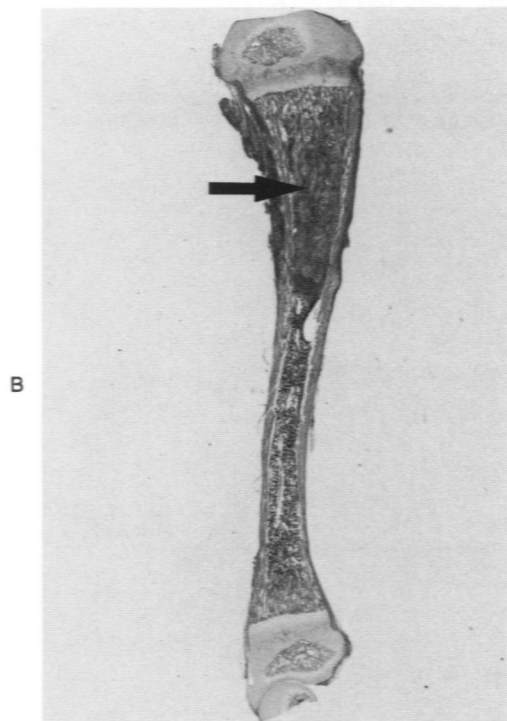
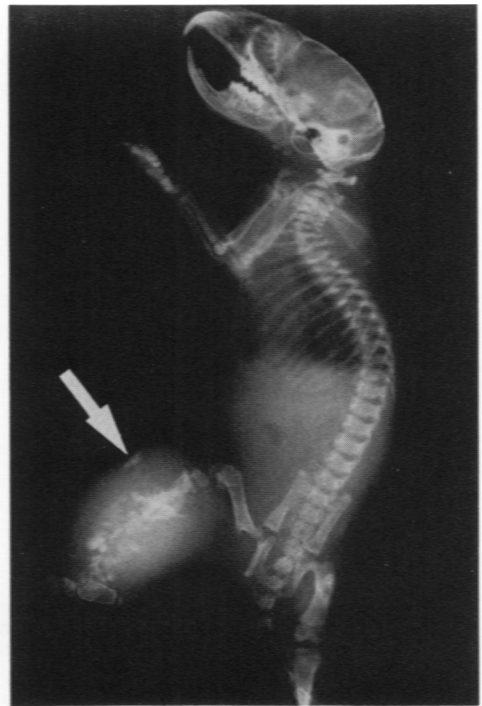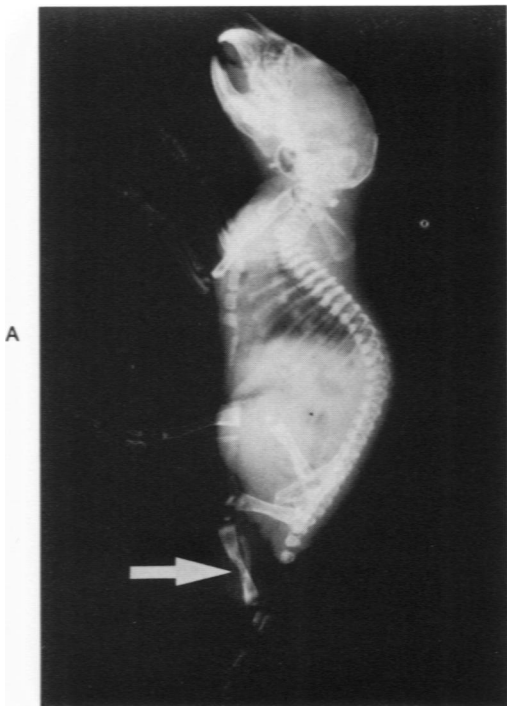


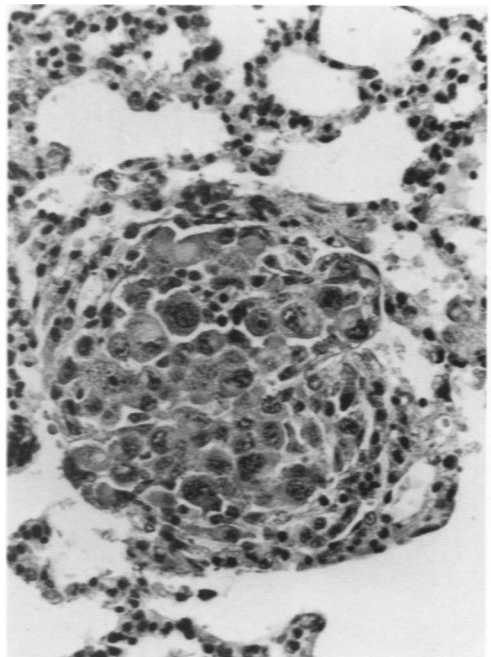
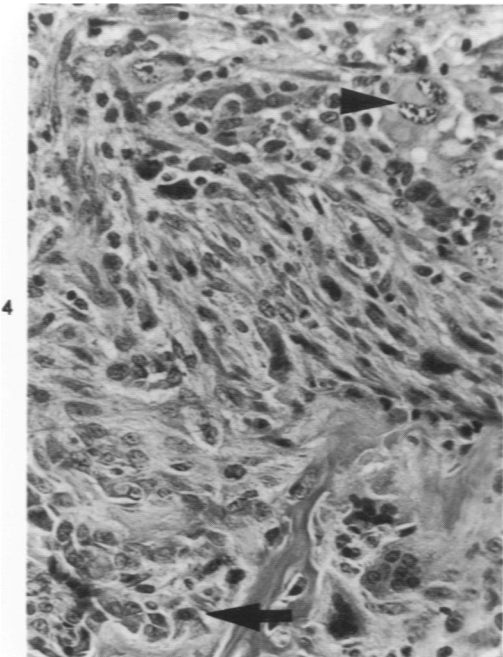
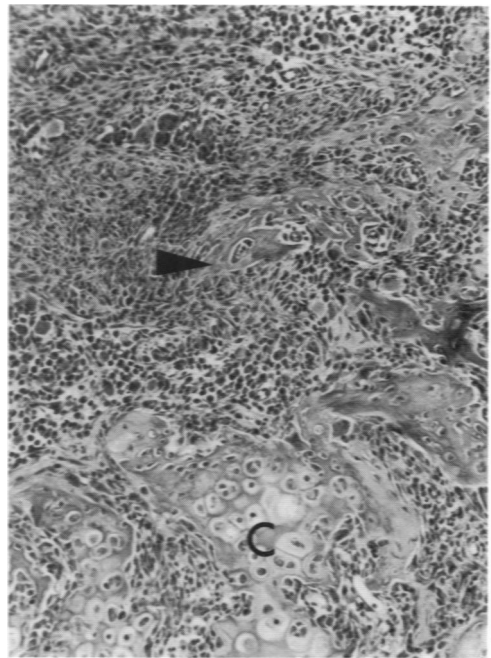
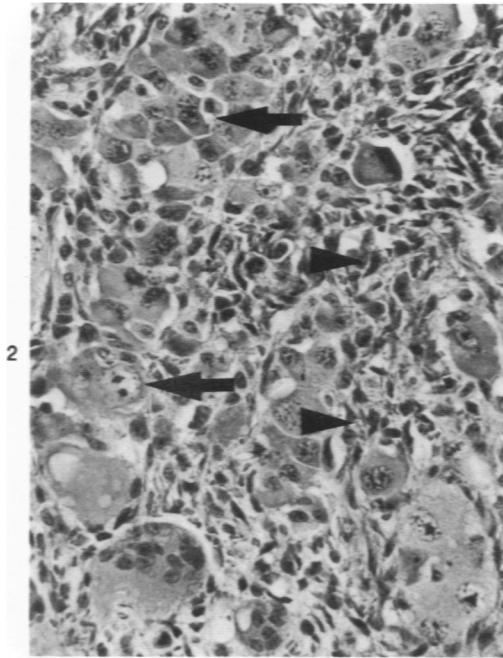
Figure 1—Radiographic and macroscopic features of developing MSV-induced osteosarcoma in young rats inoculated 1 day after birth. **A**—Radiodense zone with lysis of left tibial cortex (*white arrow*) at 12 days PI ($\times 1$). **B**—Metaphyseal proliferation of neoplastic cells (*arrow*) at 14 days PI. There is also neoplastic infiltration of adjacent cortex. (H&E, $\times 6.3$) **C**—Lytic destruction of right tibia and irregular radiodense spicules (*white arrow*) at 20 days PI. ($\times 1$) **D**—Disruption of tibial cortex (*arrow*) by osteosarcoma at 20 days PI. Note prominent chondroid border (*arrowheads*). (H&E, $\times 5.6$)

Figure 2—Osteosarcoma from rat inoculated at 1 day of age, Day 60 PI. Pleomorphic ovoid neoplastic cells with single or multiple nuclei (*arrows*) and multinucleate giant cells, and a smaller, isomorphic cell population (*arrowheads*). (H&E, × 315)

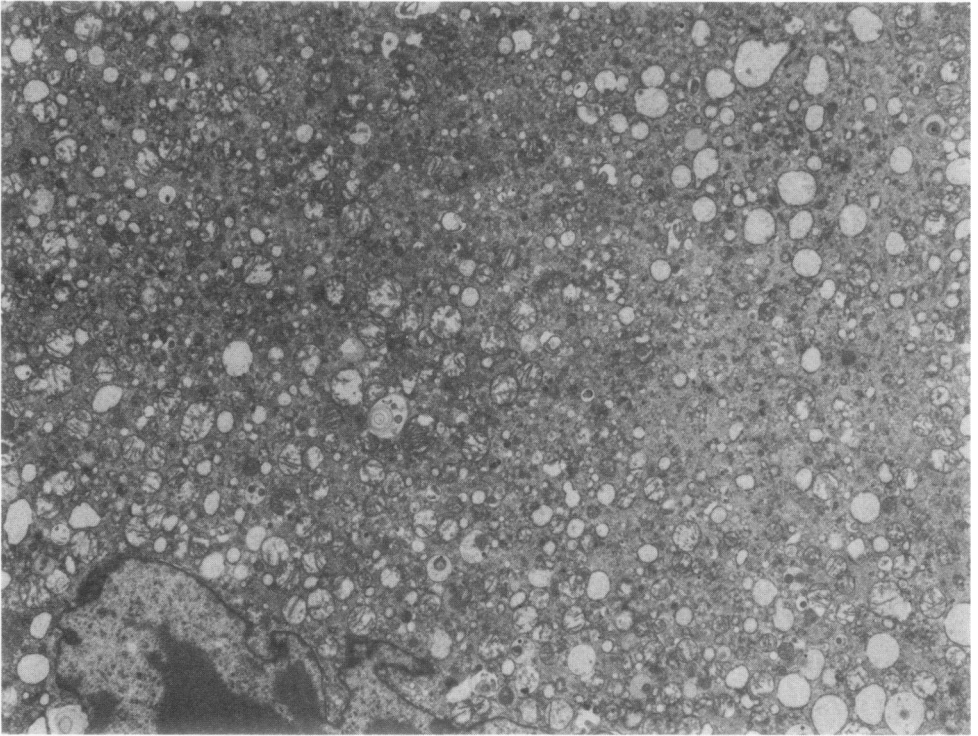
Figure 3—Osteosarcoma from rat inoculated at 1 day of age, Day 30 PI. Broad zones of chondroid matrix (*C*) and osteoid spicules (*arrowhead*) adjacent to cellular area. (H&E, × 125)

Figure 4—Osteosarcoma from rat inoculated at 4 days of age, Day 50 PI. An area of fusiform cells separates osteoblastic cells lining osteoid matrix (*arrow*) from pleomorphic tumor cells with prominent nuclear chromatin (*arrowhead*). (H&E, × 315)

Figure 5—A nodule of neoplastic cells within a vascular space in the lung of a rat inoculated with MSV on Day 4 of age, Day 70 PI. Tumor cells with large prominent nuclei are compressing the adjacent pulmonary parenchyma. (H&E, × 315)



6



7

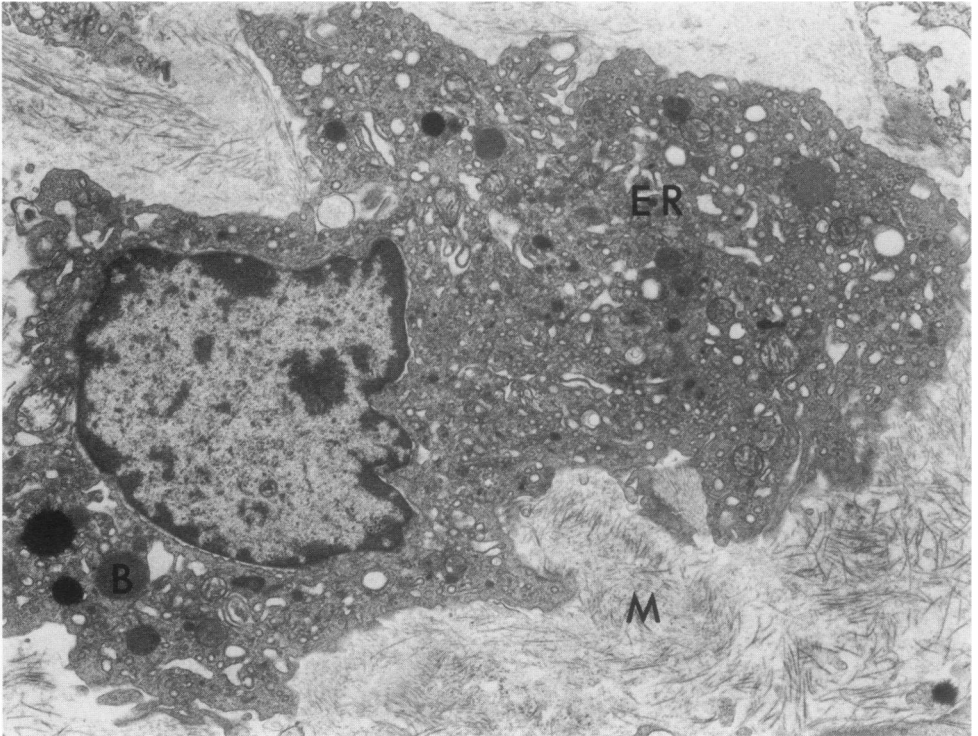
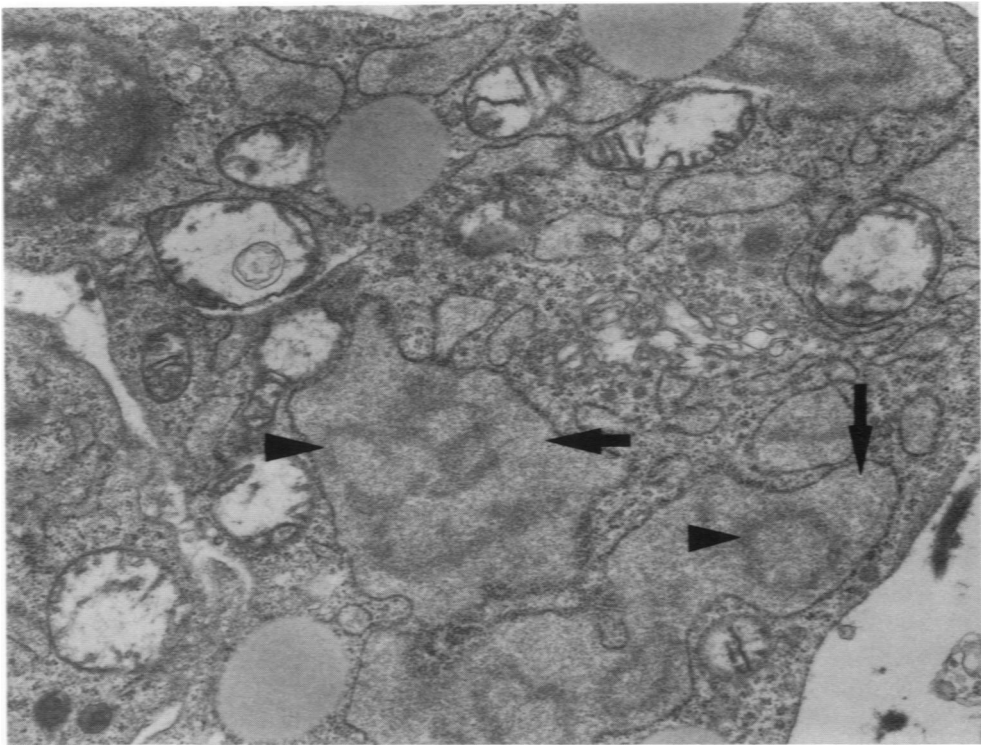
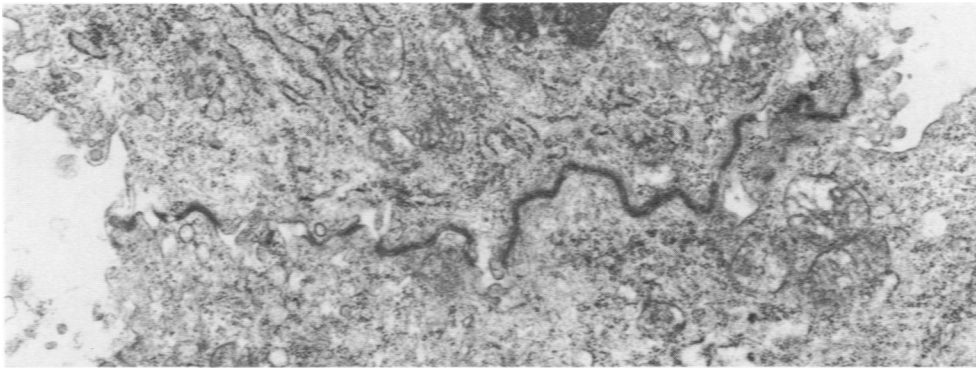


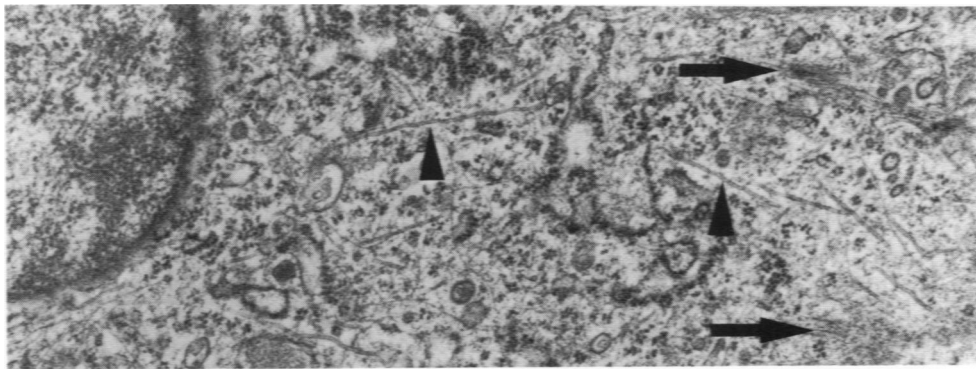
Figure 6—Electron micrograph of a portion of a large, poorly organized neoplastic cell from osteosarcoma (inoculated Day 1 of age, Day 60 PI). There is an irregular convoluted nuclear membrane, and the cytoplasm is composed of a homogeneous granular matrix with mitochondria, free ribosomes, and dilated profiles of endoplasmic reticulum. ($\times 6500$) **Figure 7**—Osteoblast-like cell from osteosarcoma in a rat inoculated at Day 1 of age, Day 60 PI. There is a prominent irregular nucleus, several electron-dense bodies (B) and mitochondria, dilated profiles of endoplasmic reticulum (ER) and a convoluted plasma membrane. An abundant fibrillar matrix (M) with collagen fibers surrounds the cell. ($\times 10,600$)



8



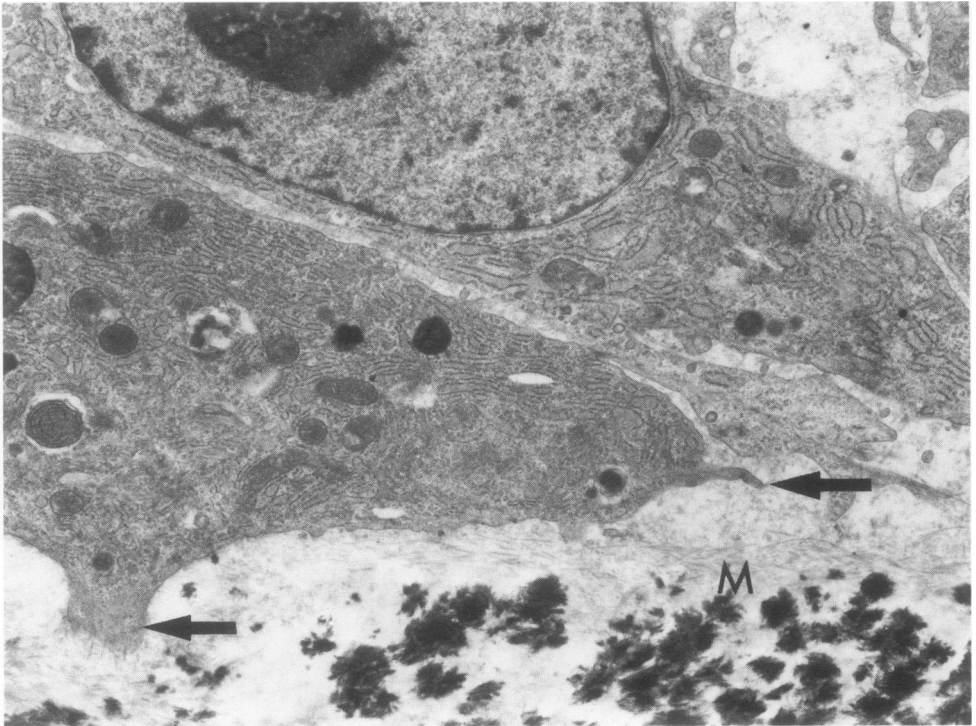
9



10

Figure 8—Portion of an osteoblast-like cell from osteosarcoma in rat inoculated at Day 1 of age, Day 60 PI. Cisternae of dilated endoplasmic reticulum filled with a finely granular matrix (*arrows*) and a branched and circular electron-dense material (*arrowheads*) are seen. ($\times 20,000$) **Figure 9**—Zonula occludens between tumor cells in an osteosarcoma from rat inoculated at Day 1 of age, Day 30 PI ($\times 15,800$). **Figure 10**—Microtubules (*arrowheads*) and microfilaments (*arrows*) scattered throughout the cytoplasm of a neoplastic cell. N = nucleus. ($\times 25,000$)

11



12

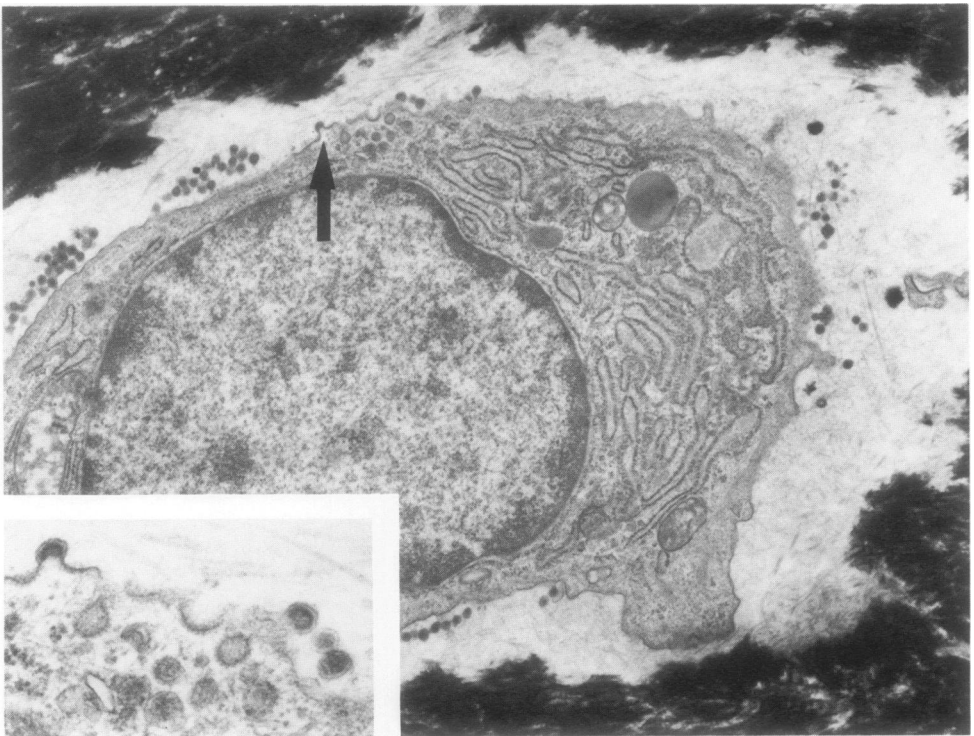


Figure 11—Osteosarcoma from rat inoculated at 4 days after birth, Day 37 PI. Two well-differentiated osteoblasts with prominent arrays of endoplasmic reticulum, lysosomal bodies, mitochondria, and a prominent ovoid nucleus. Cytoplasmic extensions (*arrows*) are surrounded by fibrillar osteoid matrix, with adjacent foci of mineralization (*M*). ($\times 9400$) **Figure 12**—Osteocyte with virus particles (*arrow*) budding into lacunar space in an osteosarcoma from a rat inoculated at Day 1 of age, Day 30 PI ($\times 13,500$). **Inset**—Typical morphology of C-type virus particles is seen along plasma membrane ($\times 34,500$).