

The American Journal of PATHOLOGY

MARCH 1977 • VOLUME 87, NUMBER 3

Primary Myocardial Disease in the Cat

A Model for Human Cardiomyopathy

Lawrence P. Tilley, DVM, Si-Kwang Liu, DVM, PhD,
Steven R. Gilbertson, DVM, Bernard M. Wagner, MD, and
Peter F. Lord, MRCVS

Thirty-four cats with primary myocardial disease were studied. The cats were divided into two groups, depending on the clinical, hemodynamic, angiocardiographic, and pathologic findings. Group A consisted of those cats with hypertrophic cardiomyopathy and Group B consisted of those cats with congestive cardiomyopathy. Similarity in the characteristics of cardiomyopathy in the human and cat was found. Both Group A and Group B consisted predominantly of mature adult male cats. The most common presenting signs were dyspnea and/or thromboembolism, systolic murmurs with gallop rhythms on auscultation, cardiomegaly with (Group A) or without (Group B) pulmonary edema, abnormal electrocardiograms, elevated left ventricular end diastolic pressures, and angiocardiographic evidence of mitral regurgitation with left ventricular concentric hypertrophy (Group A) or left ventricular dilatation (Group B). Some cats in Group A also had evidence of left ventricular outflow obstruction. The principal pathologic findings in these cats were left atrial dilatation, symmetric hypertrophy or asymmetric septal hypertrophy of the left ventricle (Group A), and dilatation of the four cardiac chambers (Group B). Aortic thromboembolism was commonly observed in both groups. These clinical and pathologic findings indicate that cardiomyopathy in the cat is similar to the two most common forms of cardiomyopathy in the human (hypertrophic cardiomyopathy, with and without obstruction, and congestive cardiomyopathy). (Am J Pathol 86:493-522, 1977)

PRIMARY MYOCARDIAL DISEASE is the term used to describe an abnormality in the heart muscle rather than in the valves or some other part of the heart. Primary myocardial disease in man has been reviewed in numerous publications.¹⁻¹²

Hurst in 1974 classified myocardial disease into five subgroups:¹³ a)

From the Departments of Medicine, Pathology, and Radiology, The Animal Medical Center, and the Department of Pathology, Beekman Downtown Hospital and the Columbia University College of Physicians and Surgeons, New York, New York.

Accepted for publication October 26, 1976.

Address reprint requests to Dr. Lawrence P. Tilley, The Animal Medical Center, 510 East 62nd Street, New York, NY 10021.

myocarditis, b) congestive cardiomyopathy, c) idiopathic concentric hypertrophy (hypertrophic cardiomyopathy without obstruction), d) obstructive cardiomyopathy (idiopathic hypertrophic subaortic stenosis, IHSS),¹⁴ (hypertrophic obstructive cardiomyopathy, HOCM),¹⁵ (asymmetric septal hypertrophy, ASH),^{16,17} e) restrictive cardiomyopathy. He felt that the two subgroups, concentric hypertrophy without obstruction and obstructive cardiomyopathy, could be the same disease and were differentiated only by a "function of duration."¹³

Cardiomyopathy in the cat had previously been considered only in association with aortic thromboembolism.¹⁸⁻²⁰ The term thromboembolism has been used to describe the commonly found antemortem clots observed in the terminal aorta of cardiomyopathic cats. The etiology and pathogenesis of these lesions remain unknown.

The lesions of cardiomyopathy in 218 consecutive cats at necropsy were reviewed by Liu in 1974²¹ and classified into three groups based on pathology: a) endomyocarditis, in 17 of 218 cats; b) endomyocardial fibrosis, left ventricular hypertrophy, and atrial hypertrophy in 148 of 218 cats (hypertrophic cardiomyopathy); and c) myocardial fibrosis, biventricular dilatation and atrial dilatation in 53 of 218 cats (congestive cardiomyopathy).²¹ Aortic thromboembolism occurred in all three groups, with a higher prevalence in the hypertrophic and congestive forms. Thromboembolism was present at necropsy in 96 of 218 affected cats (44%).

The clinical, electrocardiographic, and radiographic manifestations of cardiomyopathy in cats have recently been described.²²⁻²⁹ Angiocardiographic and hemodynamic studies were performed on 14 of 61 cats.²⁶ Twelve of the 14 cats had a thick left ventricular wall and small end systolic volume due to concentric muscle hypertrophy (hypertrophic form), while the 2 remaining cats had normal left ventricular wall thickness with an enlarged chamber (congestive form).

It is the purpose of this report to review the clinical, hemodynamic, angiocardiographic, and pathologic findings in a group of cats with primary myocardial disease and to firmly establish the syndromes of spontaneous feline hypertrophic cardiomyopathy and spontaneous feline congestive cardiomyopathy.

Materials and Methods

Thirty-four cats with primary myocardial disease were studied. These animals were selected from 358 cases of cardiomyopathy at necropsy based on our requirement of having at least a physical examination, electrocardiography, radiography, and/or angiocardiographic hemodynamic studies. These cases were considered to be typical examples of the disease entity. The lesions of cardiomyopathy in the other 324 cats at necropsy were classified according to the review by Liu.²¹ There were 28 males and 6 females in this study. The age range of the cats varied from 8 months to 13 years, with a mean age of 5.5

years. Cats were of the following breeds: domestic shorthair (28), Siamese (4), and Persian (2).

The criteria used by Fowler for the clinical diagnosis of human myocardial disease have been modified and were applied to these cats:³⁰ 1) cardiomegaly due to left ventricular or biventricular enlargement with/without cardiac decompensation, 2) presence of an abnormal electrocardiogram, 3) presence of a third or fourth sound gallop rhythm or both, 4) absence of primary valvular heart disease (acquired or congenital), and 5) absence of sufficient pulmonary dysfunction to cause cor pulmonale. Criteria 1, 4, and 5 were considered essential, while criteria 2 and 3 were not considered essential in the diagnosis.

A chemistry profile (SMA 12/60 Autoanalyzer, Technicon Instrument Corp., Tarrytown, N. Y.) and complete blood count were done on each cat. Phonocardiographic studies were done on only 17 of the 34 cats because of the inability to control the behavior of some cats during the procedure. Phonocardiograms were obtained with a microphone (Electronics for Medicine, Model PSA) and were routinely recorded (Model DR-8) over the cardiac base and cardiac apex along the left thorax. The output was filtered through a heart-sound amplifier (Electronics for Medicine, Model TPD), and the appropriate filters used were low, medium, and high. Hemodynamic and angiocardigraphic studies were done on only 19 of 34 cats because of the clinical condition of the cats.

Electrocardiograms were done with all cats in right lateral recumbency using standard bipolar (I, II, III) and augmented unipolar (aVR, aVL, aVF) limb leads. The techniques and normal standard values for electrocardiography and phonocardiography have been previously described.^{19,31-33} Normal standard values for the precordial leads have not been established in the cat. Normal electrocardiographic standard values for the cat are presently being studied in our laboratory.³⁴

Thoracic radiographs were taken with the cat in both left lateral and dorsoventral positions. The cardiac silhouette was evaluated for cardiac chamber enlargement in both views.³⁵

Cardiac catheterization and angiocardiology were done under a light plane of anesthesia with sodium thiamylal and maintained with halothane, nitrous oxide, and oxygen. Cardiac catheters were introduced into the left and right ventricle through a carotid artery and jugular vein cutdown under image intensification fluoroscopy. Left ventricular and aortic pressures were recorded on a recorder (Electronics for Medicine) utilizing a Statham P23Db strain gauge. Left ventriculograms were taken using an Elema-Schönander roll film changer at a rate of 6 frames/sec. Water-soluble contrast medium (3 to 5 ml of Hypaque M-75) was rapidly injected by hand into the left or right ventricle.

At necropsy, the organs of all affected cats were weighed and carefully examined. Length and body weight of the cat were recorded. The heart, aorta, and major arteries were opened and examined carefully. The right ventricle was opened by extending an incision from the pulmonary trunk through the pulmonic valve to the apex of the right ventricle. The left ventricle was opened from the apex up through the aortic valve. The thickness of the left ventricular free wall behind the lateral leaflet of the mitral valve, the thickness of the interventricular septum midway between aortic valve and apex, and the circumferences of the valve rings were measured.²⁸

Normal examples are illustrated in the text for the standard and unipolar leads of an electrocardiogram, dorsoventral projection of a thoracic radiograph, left ventricular pressure tracing, left ventricular angiogram in systole and diastole, and the left ventricle at necropsy.

The entire heart and tissue of other organs were fixed in neutral 10% formalin. The heart sections included a longitudinal section of the septum and aortic valve, a portion of the aorta, and left ventricular free wall with papillary muscle, a lateral leaflet of the mitral valve and the left atrium, and a right ventricular free wall with lateral leaflet of the tricuspid valve and atrium.

The cats were divided into two groups by the clinical, hemodynamic, angiocardigraphic, and pathologic findings as previously described. Group A included 27 cats with

Table 1—Clinical and Radiographic Findings in 34 Cats With Cardiomyopathy

	Group A	Group B
Cases		
Number	27	7
Male/female	23/4	5/2
Youngest (mons)	8	24
Oldest (yrs)	13	11
Average age (yrs)	5.15	5.85
Symptoms		
Dyspnea	21	5
Thromboembolism	14	2
Anorexia	9	3
Physical examination*		
Systolic murmur	9	2
S ₃ +	3/13	3/4
S ₄ +	11/13	2/4
Chest radiographs		
Cardiomegaly	27	7
Pulmonary edema	18	0
Pleural effusion	5	4

* Thirteen phonocardiograms were done in Group A and 4 phonocardiograms were done in Group B.

+ Two cats, 1 from each group, had an S₃-S₄.

hypertrophic cardiomyopathy, while Group B included 7 cats with congestive cardiomyopathy. The data on these cats are summarized in Tables 1 to 5.

Results

Age and Sex

The 34 cats examined ranged in age from 8 months to 13 years. There were 28 males and 6 females. The cats in Group A ranged in age from 8 months to 13 years (mean, 5.15 years). The cats in Group B ranged in age from 2 years to 11 years (mean, 5.85 years).

Symptomatology

The most frequent signs on presentation were recorded in all cats. One cat from Group B was asymptomatic. Dyspnea was the most common sign occurring in 21 of 27 cats in Group A and 5 of 7 cats in Group B. The nonspecific sign of anorexia was found in 9 of 27 cats in Group A and 3 of 7 cats in Group B. Thromboembolism was the second most common sign in Group A, with 14 of 27 cats affected. Thromboemboli were found in 2 of 7 cats in Group B. The aortic bifurcation was the most common site for thromboemboli, with accompanying acute onset of posterior paralysis, absence of femoral pulses, and coldness of extremities. One cat had sign of a thromboembolus to the foreleg.

Physical Examination

Auscultation proved to be a most valuable tool in diagnosing primary myocardial disease. Nine of the 27 cats in Group A and 2 of the 7 cats in

Group B had systolic murmurs (Text-figure 1A). The systolic murmur was sometimes short in duration and most prominent during mid-systole. A low intensity systolic murmur was the most common finding (Text-figure 1A). A fourth heart sound was recorded in 11 of 13 cats in Group A and 2 of 4 cats in Group B (Text-figure 1A). A third heart sound was recorded in three of 13 cats in Group A (Text-figure 1B). A summation gallop was recorded in 2 cats, 1 cat from Group A, and 1 cat from Group B (Text-figure 1C).

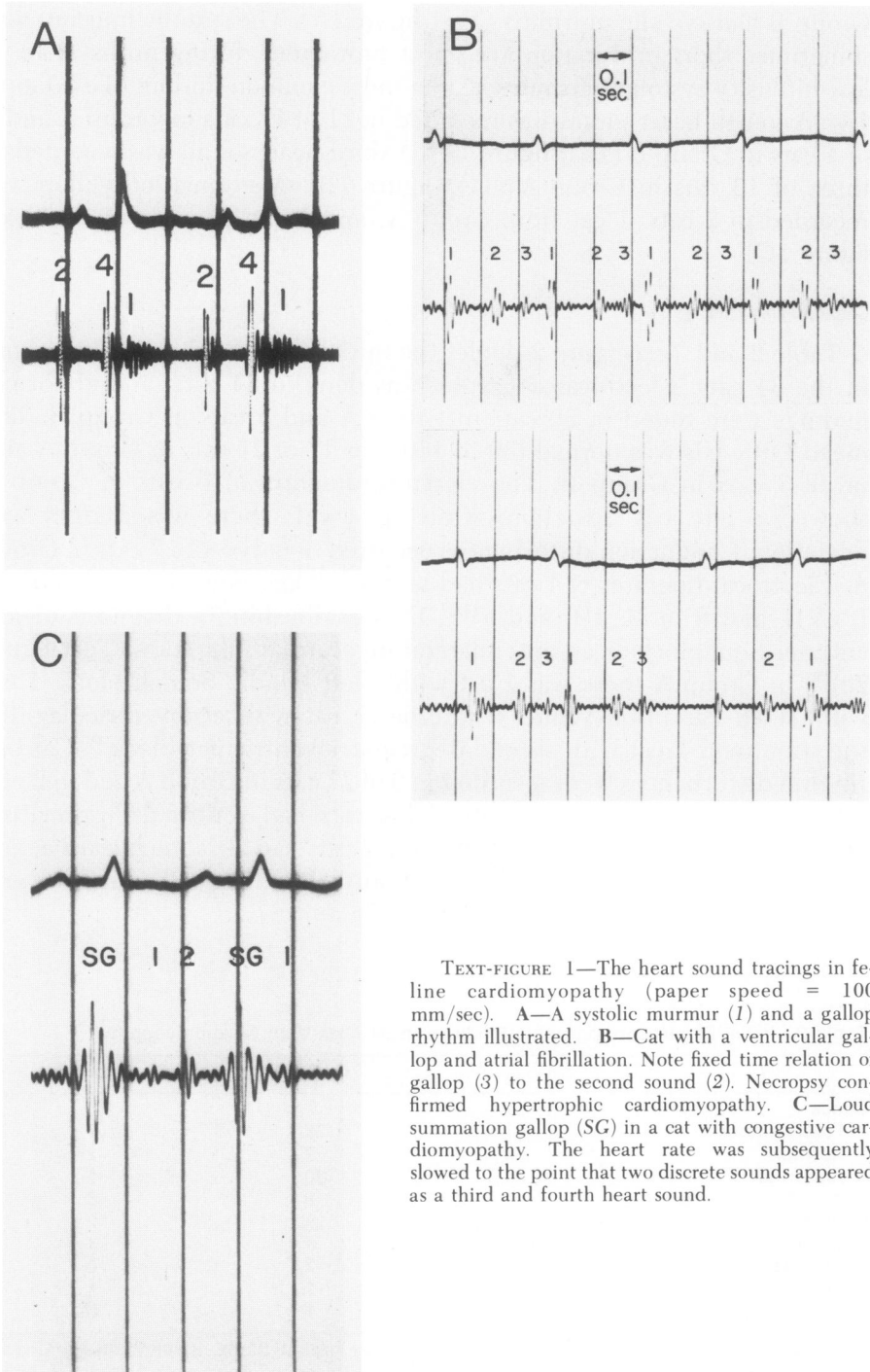
Cardiographic Findings

Table 2 and Text-figure 2 depict the initial electrocardiographic findings in the 34 cats. Electrocardiography was done in 34 cats, and abnormal findings were found in 20 cats in Group A and 5 cats in Group B. The mean QRS axis was normal (30 to 100°) in 17 of 27 cats in Group A and in all 7 cats in Group B. The electrocardiogram of 6 cats in Group A showed a left axis deviation, while in 4 cats there was a right axis deviation. Conduction disturbances occurred in only 8 of 27 cats in Group A. Electrocardiograms of 4 cats had severe left axis deviation with a qR in I, aVL, and S in II, III, and aVF, thus establishing a diagnosis of left anterior hemiblock or an anterolateral myocardial infarction (Text-figure 2c).³⁶ In Group A there was 1 cat with a left bundle branch block, 1 cat with Wolff-Parkinson-White syndrome, 1 cat with atrioventricular dissociation, and 1 cat with second degree atrioventricular block.³⁶ Cardiac rhythm disturbances were recorded in 9 of 27 cats in Group A and in 2 of 7 cats in Group B (Text-figure 2b). Nine cats had ventricular premature contractions, 2 cats had atrial fibrillation, 2 cats had atrial tachycardia, and 1 cat had ventricular tachycardia. Abnormalities in QRS duration and deflections were recorded (Text-figures 2c and 3).

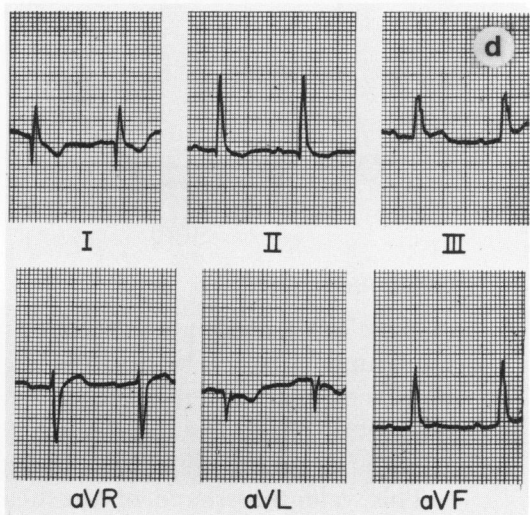
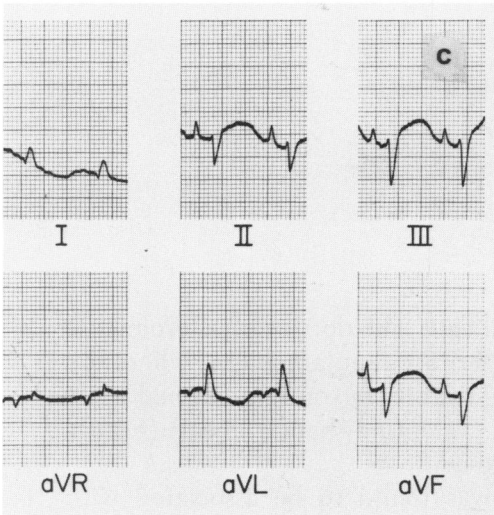
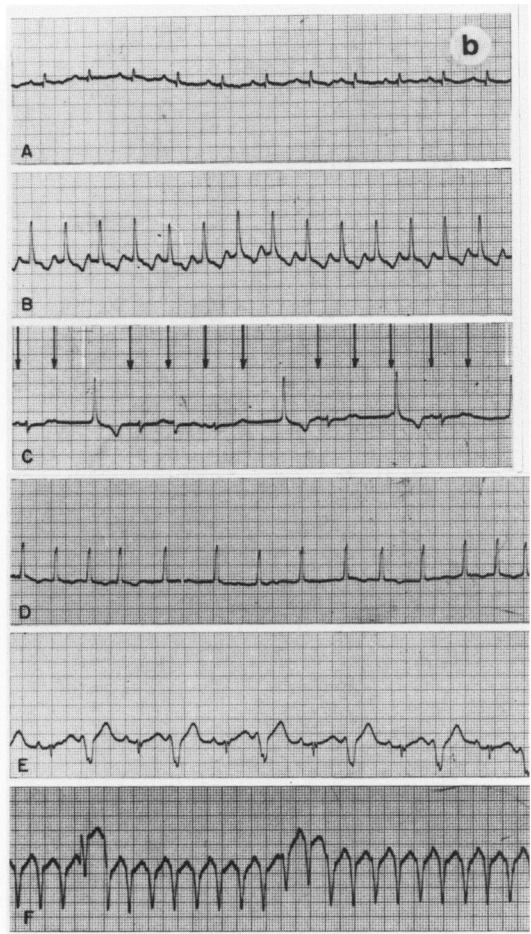
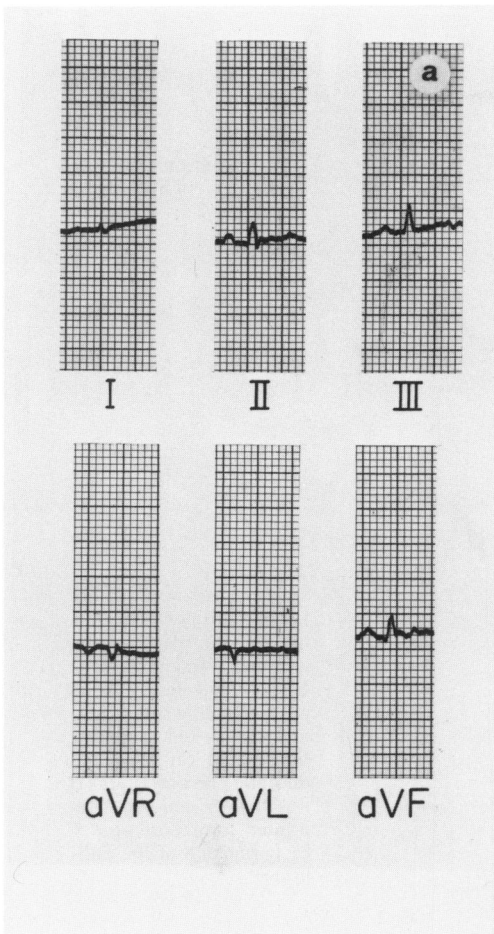
Table 2—Initial Electrocardiographic Findings in 34 Cats With Cardiomyopathy

	Group A	Group B
Cases		
Total number	27	7
Normal	7	2
Abnormal	20	5
Conduction disturbances	8*	0
Rhythm disturbances	9	2
Ventricular premature contractions	8	1
Atrial fibrillation	2	0
Atrial tachycardia	1	1
Ventricular tachycardia	1	0

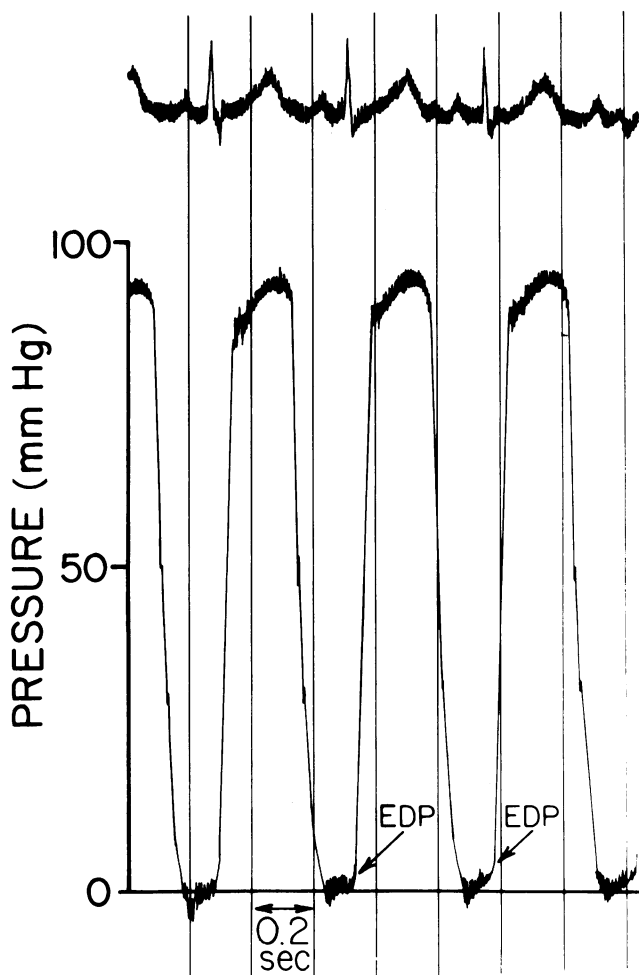
* Four with left anterior hemiblock, 1 with left bundle branch block, 1 with Wolff-Parkinson-White syndrome, 1 with atrioventricular dissociation, 1 with second degree atrioventricular block.



TEXT-FIGURE 1—The heart sound tracings in feline cardiomyopathy (paper speed = 100 mm/sec). A—A systolic murmur (1) and a gallop rhythm illustrated. B—Cat with a ventricular gallop and atrial fibrillation. Note fixed time relation of gallop (3) to the second sound (2). Necropsy confirmed hypertrophic cardiomyopathy. C—Loud summation gallop (SG) in a cat with congestive cardiomyopathy. The heart rate was subsequently slowed to the point that two discrete sounds appeared as a third and fourth heart sound.



TEXT-FIGURE 2—The electrocardiogram in feline cardiomyopathy. Lead II rhythm strips, paper speed = 50 mm/sec; 1 cm = 1 mV. (Tracings have been retouched.) a—Electrocardiogram from a normal cat for comparison with abnormal electrocardiograms. Note the normal “small” amplitude of complexes in all leads. b—Rhythm disturbances in feline cardiomyopathy. A—Normal sinus rhythm for comparison; heart rate = 200 beats/min. B—Atrial tachycardia; heart rate = 260 beats/min. Note increased amplitude and width of QRS complexes. c—Second degree atrioventricular block with ventricular escape beats; P waves are noted by arrows. D—Atrial fibrillation. E—Bigeminal rhythm; every alternate beat is a ventricular premature beat. F—Ventricular tachycardia based on subsequent studies. C—Electrocardiogram recorded from a 5-year-old Persian cat with acute dyspnea. The mean electrical axis has a severe left axis deviation. The electrocardiogram is consistent for the diagnosis of left anterior hemiblock³⁶ or an anterolateral myocardial infarction. A diagnosis of hypertrophic cardiomyopathy was made at necropsy. d—Electrocardiogram recorded from a 3-year-old domestic shorthaired cat with a 2-week history of anorexia and dyspnea. Note the deep Q waves in Leads I and aVL, the increased width and amplitude of QRS complexes in Leads II, III, and aVF. A diagnosis of asymmetric septal hypertrophy with severe obstruction of the left ventricular outflow tract was found at necropsy (Figure 9B).



TEXT-FIGURE 3—Left ventricular pressure tracings (Paper speed = 100 mm/sec; tracings have been retouched). A—A normal tracing from a normal 2-year-old domestic shorthaired cat. The end diastolic pressure (EDP) is less than 5 mm Hg. (Reprinted from Lord *et al.*²⁸ by permission of the publisher)

Thoracic Radiography

Gross cardiomegaly was present in all cats. The dorsoventral projection was found to be the best for detecting left atrial enlargement, where the right ventricle and left atrium projected slightly beyond the normal heart silhouette, giving the appearance of a "valentine-shaped" heart (Figure 1B); the normal is illustrated in Figure 1A.

This valentine shape of the heart was found to be associated with hypertrophic cardiomyopathy (the condition found in cats of Group A), while overall enlargement of all chambers was found to be associated with congestive cardiomyopathy (condition found in cats of Group B) (Figure 1C). Pulmonary edema was identified by a generalized or partly alveolar type fluffy density in 18 of 27 cats in Group A and was considered to be a sign of left-sided heart failure. Pulmonary edema was not found in any

cats in Group B. In contrast, 4 of 7 cats in Group B and 5 of 27 cats in Group A had pleural effusion which was considered a sign of right-sided heart failure.

Hemodynamic Studies

Left ventricular systolic and end diastolic pressures were compared with normal values (Table 3). In Group A, the mean systolic pressures remained within normal limits (85 to 135 mm Hg), although the range was greater than normal (90 to 160 mm Hg). In Group B, the mean systolic pressure (94 mm Hg) was in the lower end of normal range. The end diastolic pressure was consistently high in all cats (the mean pressure was 28.7 mm Hg in Group A and 30 mm Hg in Group B), being more than six times the normal pressure of 4.5 mm Hg. The left ventricular pressure tracing was characteristic for each group.⁸⁷ Group A pressure tracings often revealed a prominent transmitted *a* wave and an elevated end diastolic pressure (Text-figure 3B); compare to the normal (Text-figure 3A).

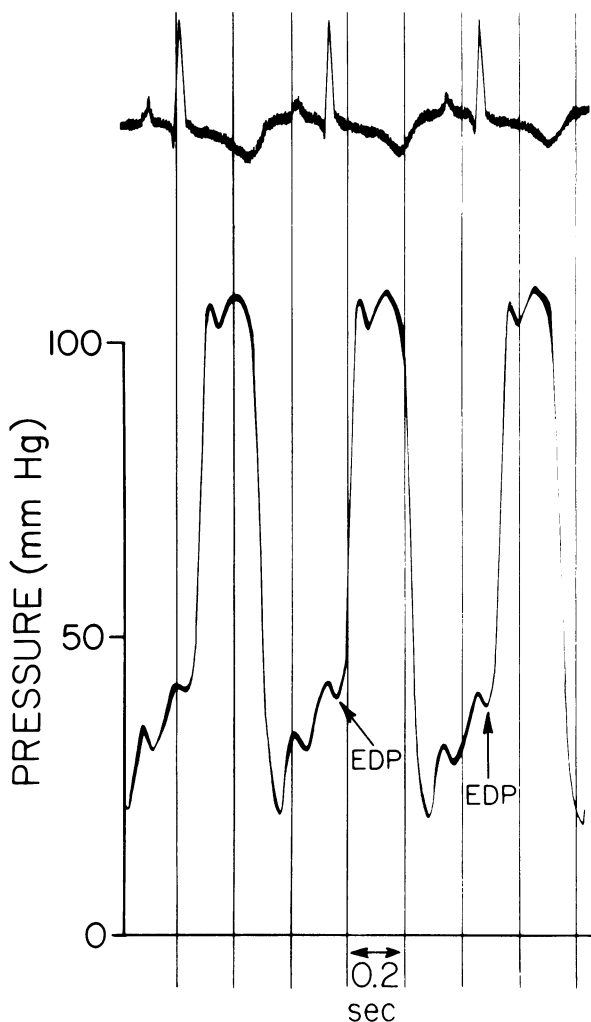
The left ventricular pressure tracings from cats in Group B revealed an elevation of end diastolic pressure with elevation of both the peak systolic

Table 3—Intracardiac Pressure Measurements and Angiocardiographic Data From 19 Cats With Cardiomyopathy

	Left ventricular systolic pressure (mm Hg)	Left ventricular diastolic pressure (mm Hg)	Mitral insuffi- ciency	Aortic thrombo- embolism
Normal range*	95-135	3-12		
Group A				
1	90	23	+	+
2	160	20	-	+
3	105	40	+	-
4	155	30	+	+
5	110	32	+	+
6	110	22	+	-
7	160-100†	40	+	-
8	140	25	+	-
9	140	10	+	+
10	145	35	+	+
11	110	25	+	-
12	115	25	+	+
13	100	40	+	-
14	120	35	+	+
Mean	125	28.7		
Group B				
1	100	15	+	-
2	75	35	+	-
3	80	20	+	-
4	115	40	+	-
5	100	40	+	+
Mean	94	30		

* Derived from 6 normal cats studied in this laboratory.

† Midventricular gradient.



TEXT-FIGURE 3B—Tracing from an 8-year-old domestic shorthaired cat with acute dyspnea. Systolic pressure is normal, but the EDP is increased to 40 mm Hg with a prominent a wave. Hypertrophic cardiomyopathy was found at necropsy (same cat as in Figure 4). (Reprinted from Lord *et al.*²⁶ by permission of the publisher)

and diastolic pressure tracing (Text-figure 3C). Two cats in Group B had left ventricular pressure tracings that represented pulsus alternans (Text-figure 3C).

In 1 cat of Group A, a midventricular systolic gradient of 160 to 100 mm Hg was recorded (Text-figure 3D). When the catheter was withdrawn to a portion above the aortic valve, no further pressure gradients were recorded. Isoproterenol in this cat and in 3 other cats with hypertrophic cardiomyopathy caused a marked rise in the end diastolic pressure (Text-figure 3A), as well as intensification of the systolic gradient.

Angiocardiographic Studies

In all 14 cats of Group A subjected to angiocardiography, a smaller than normal left ventricular end systolic volume was seen (Figures 3–5). Mus-

cular hypertrophy around the body of the ventricle appeared to be greater than that at the apex. Encroachment by a greatly hypertrophied ventricular septum upon the midportion of the ventricular cavity was found in some cats (Figures 3-5). In 1 cat, muscular hypertrophy and myocardial fibrosis caused irregular protrusions into the ventricular cavity (Figure 4). Many angiocardiograms showed evidence of radiolucent filling defects in the left ventricle caused by hypertrophied papillary muscle (Figure 3). Five of the 7 cats in Group B had end diastolic volumes that were greater than normal but with left ventricular wall thickness that was normal (Figure 6). Mitral insufficiency was present in all cats of both groups in those studied by angiocardiography. Thromboembolism was found in the aorta of 8 cats in Group A and 1 cat in Group B (Figure 7). One cat had a thromboembolus in the brachial artery.

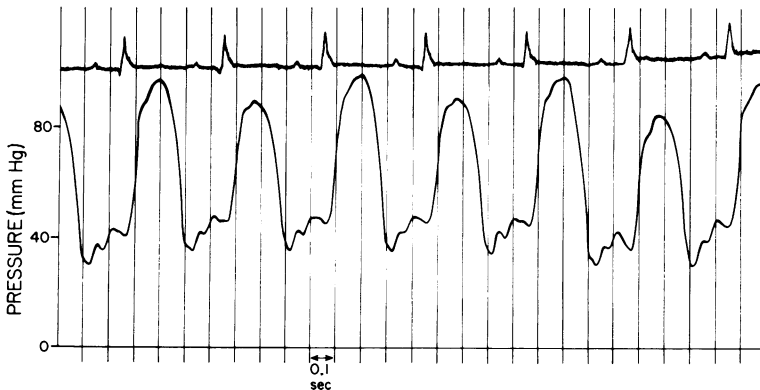
Duration of Disease Prior to Necropsy

The average follow-up time for cats in Group A was 3.4 months, with the longest follow-up being 30 months. Five cats died suddenly. The average follow-up in Group B was 2.7 months, with the longest follow-up being 10 months. Sudden death did not occur in any cat belonging to Group B. Euthanasia was performed on many of the cats, but only during the terminal stages of the disease.

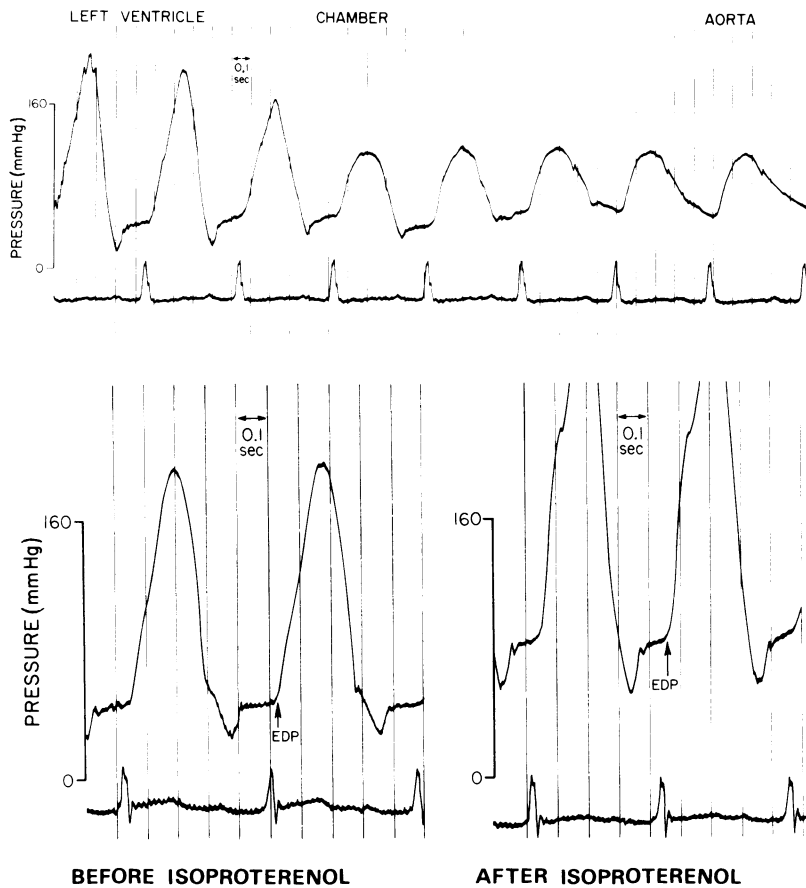
Pathology

Macroscopic Examination

The results of macroscopic examination are shown in Tables 4 and 5. *Group A.* Enlargement and hypertrophy of the left atrium was seen



TEXT-FIGURE 3C—Tracing from an 8-year-old domestic shorthaired cat with a 1-week history of listlessness and anorexia. There is elevation of the end diastolic pressure together with elevation of both of the peak systolic and diastolic pressure tracing. Pulsus alternans is also illustrated. Congestive cardiomyopathy was found at necropsy.



TEXT-FIGURE 3D—Tracings from a 3-year-old Persian cat with acute dyspnea. In the *top* tracing, a catheter was moved through the narrow midventricular chamber from the apex of the left ventricle to the aortic valve; it recorded a change in systolic pressure from 160 to 100 mm Hg. No further pressure gradients were recorded when the catheter was withdrawn to a portion above the aortic valve. The *bottom left* ventricular pressure tracings are before and after the infusion of isoproterenol in this cat. Note the marked increase in EDP, a drug response almost specific for hypertrophic cardiomyopathy. The systolic gradient was also increased. Hypertrophic obstructive cardiomyopathy was found at necropsy (same cat as in Figure 3).

consistently in the heart of 27 affected cats in Group A. There was hypertrophy of the left ventricular wall, papillary muscles, and septum which encroached upon the left ventricular cavity (Figure 8). A normal heart is shown in Figure 9A. Table 4 shows that 18 cats in Group A had ventricular septal hypertrophy, with 8 of these cats having disproportionate thickening of the ventricular septum. The 8 cats had bulging of the interventricular septum with impingement upon the lumen of the left ventricular outflow tract and thickening of the anterior mitral

Table 4—Major Pathologic Changes in 34 Cats With Cardiomyopathy at Necropsy

Pathologic changes	Group A (27 cats)	Group B (7 cats)
Cardiomegaly	21	7
Left atrial dilatation	27	7
Right atrial dilatation	5	7
Left ventricular dilatation	—	7
Right ventricular dilatation	2	7
Left ventricular hypertrophy	27	—
Right ventricular hypertrophy	3	2
Ventricular septal hypertrophy	18	—
Asymmetric septal hypertrophy	8	—
Ventricular septal atrophy	—	2
Mitral valvular fibrosis	13	2
Papillary muscle hypertrophy	13	—
Papillary muscle atrophy	—	4
Focal endomyocardial fibrosis	27	7
Disarrangement of muscle fibers	25	2
Thin wavy muscle fibers	—	7
Aortic thromboembolism	14	3
Pulmonary edema	19	6
Hepatic congestion	11	6

leaflet (Figure 9B and C). Aortic thromboembolism was found in 14 cats (Figure 10). As demonstrated in Table 5, using previously established normal values,²⁸ heart weight and muscle ratios clearly show increases in absolute heart weight and muscle thickness for Group A cats. Left ventricular thickness is increased by approximately 50%, while septal thickness increased by approximately 100%.

Group B. In the 7 cats of Group B, the heart was enlarged and globular, due to extreme dilatation of the ventricles (Figure 11) and the atria. The papillary muscles and trabeculae in the ventricles were flat-

Table 5—Heart Weight and Cardiac Muscle Thickness Ratios in Normal Cats and Cats With Hypertrophic Cardiomyopathy or Congestive Cardiomyopathy

	No. of cases	Heart* weight	Right ventricle†	Left ventricle†	Septum
Group A					
Normal	11	.0042 ± .0006	.0040 ± .0008	.0128 ± .0014	.0088 ± .0014
Hypertrophic cardiomyopathy	15/27	.0070 ± .0044	.0063 ± .0011	.0188 ± .0033	.0174 ± .0038
Group B					
Normal	11	.0042 ± .0006	.0040 ± .0008	.0128 ± .0014	.0088 ± .0014
Congestive cardiomyopathy	7/7	.0059 ± .0010	.0057 ± .0002	.0115 ± .0021	.0087 ± .0006

* Ratio of heart weight (g)/body weight (g).

† Ratios of muscle thickness (cm)/body length (cm).

tened and atrophied. Irregular whitish patches were occasionally seen in the endocardium and myocardium. Aortic thromboembolus was found in 2 cats. Table 5 shows that in Group B cats, the left ventricular wall thickness was close to normal, while the right ventricular wall thickness was greater than normal. Absolute heart weight was increased in 7 cats of Group B.

Microscopic Examination

The results of microscopic examination are shown in Table 4.

Group A. In the hypertrophic cardiomyopathy, the muscle cells were enlarged (Figure 12A) and had large, rectangular hyperchromatic nuclei. Muscle bundles showed bizarre disarrangement (Figure 12A and B) and were separated by increased interstitial connective tissue. Foci of endocardium were replaced by active fibroplasia. The atrioventricular Purkinje cells were frequently interrupted by or mixed with many dense collagen fibers.

Group B. In the congestive cardiomyopathy, the muscle cells appeared thinner than normal and were separated by edematous extracellular ground substance or connective tissue. Areas of wavy muscle fibers (Figure 13) were seen in the myocardium as a major pathologic change, while only a few fibers appeared hypertrophied (Table 4). The endocardium was thickened by the presence of dense collagen.

Discussion

Table 6 illustrates some important similarities between cardiomyopathy in man and cat. The most common features of feline cardiomyopathy are that it occurs in a mature male cat with: acute onset of dyspnea and/or aortic thromboembolism, a systolic murmur with a gallop rhythm, cardiomegaly with (hypertrophic cardiomyopathy) or without (congestive cardiomyopathy) pulmonary edema, an abnormal electrocardiogram, an elevated left ventricular end diastolic pressure, and angiocardiographic evidence of mitral regurgitation with left ventricular concentric hypertrophy (hypertrophic cardiomyopathy) or left ventricular dilatation (congestive cardiomyopathy). The pathologic findings are primarily those of generalized cardiomegaly with either severe dilatation or hypertrophy of the left ventricle.

A preponderance of males was found in the group of cats with hypertrophic cardiomyopathy, a factor that is not seen in humans with hypertrophic cardiomyopathy. The most common presenting clinical sign in human hypertrophic cardiomyopathy is dyspnea. Dyspnea was the most common presenting clinical sign in our series of cats with hypertrophic

cardiomyopathy. This is thought to be a reflection of a labile left ventricular end diastolic pressure.^{15,38} Thromboembolism is another common finding in the cat and may be observed in human cardiomyopathy.^{12,39-41} Systolic murmurs representing mitral regurgitation or left ventricular outflow obstruction is a common finding in human cardiomyopathy.^{13,14}

Table 6—A Comparison of the Common Findings of Feline and Human Cardiomyopathy

	Feline	Human
Hypertrophic cardiomyopathy		
Clinical findings		
Symptoms	Dyspnea Sudden death	Dyspnea Sudden death
Physical examination	Systolic murmurs Fourth heart sounds	Systolic murmurs Fourth heart sounds
Radiology	Cardiomegaly	Cardiomegaly
Electrocardiogram	Abnormal Left axis deviation Intraventricular conduction defects	Abnormal Left axis deviation Intraventricular conduction defects
Hemodynamics	LVEDP ↑	LVEDP ↑
Angiocardiography	LVESV ↓ Abnormal shape of ventricular cavity Mitral insufficiency	LVESV ↓ Abnormal shape of ventricular cavity Mitral insufficiency
Pathology		
Gross	Asymmetric septal hypertrophy (with & without obstruction) Left and right atrial dilatation Thromboembolism	Asymmetric septal hypertrophy (with & without obstruction) Left & right atrial dilatation Thromboembolism
Histology	Bundle of bizarre hypertrophied muscle cells	Bundle of bizarre hypertrophied muscle cells
Congestive cardiomyopathy		
Clinical findings		
Symptoms	Dyspnea	Dyspnea
Physical examination	Systolic murmur Third heart sounds	Systolic murmur Third heart sounds
Radiology	Gross cardiomegaly	Gross cardiomegaly
Electrocardiogram	Abnormal	Abnormal
Hemodynamics	Pulsus alternans LVEDP ↑	Pulsus alternans LVEDP ↑
Angiocardiography	LVEDV ↑ Mitral insufficiency	LVEDV ↑ Mitral insufficiency
Pathology		
Gross	Globular heart (with biventricular and biatrial dilatation) Thromboemboli	Globular heart (with biventricular and biatrial dilatation) Thromboemboli
Histology	Thin muscle cells Interstitial fibrosis	Thin muscle cells Interstitial fibrosis

LVEDP = left ventricular end diastolic pressure, LVESV = left ventricular end systolic volume, LVEDV = left ventricular end diastolic volume.

This is similar to that seen in the cat with cardiomyopathy. Hypertrophy of the papillary muscles and left ventricular wall, causing distortion and malposition of the valve leaflet during systole, causes mitral insufficiency. The leaflets themselves may be normal or fibrotic.^{12,42,43} In man it is well documented that the systolic murmur representing left ventricular outflow obstruction occurs because of an abnormal systolic anterior motion of the tip of the anterior mitral leaflet.^{13,17,44} A gallop rhythm is heard in the majority of humans with cardiomyopathy.^{13,45} This is also seen in cats with cardiomyopathy. Atrial gallop sounds correlate with left ventricular hypertrophy, while a ventricular gallop correlates with ventricular dilatation.⁴⁶

The thoracic radiographs of the cats in this series are much more variable in appearance in hypertrophic cardiomyopathy than in congestive cardiomyopathy. This is analagous to the situation in man.³⁰ The left ventricular hypertrophy causes malformation of the cardiac silhouette. Dilatation of the atrium is dependent on many factors: severity of impedance to ventricular filling, age, and duration of disease. In general, the heart is usually less enlarged in hypertrophic cardiomyopathy as compared to congestive cardiomyopathy.¹⁰ The left atrial enlargement in hypertrophic cardiomyopathy was much greater than the left ventricular enlargement in this series of cats (Figure 1B), while with congestive cardiomyopathy the reverse was true (Figure 1C). Pulmonary edema is the most prominent feature in the group of cats with hypertrophic cardiomyopathy, while a lack of pulmonary edema occurs in the group of cats with congestive cardiomyopathy. This minimal or absence of hilar congestion or edema in the cats with congestive cardiomyopathy is dramatic in view of the gross cardiomegaly. Again, this pulmonary feature is similar to that seen in man.¹⁰

The electrocardiogram is helpful in the diagnosis of cardiomyopathy in both the cat and human since it is abnormal in almost every case.⁴⁷ The electrocardiographic abnormalities in this group of cats were left axis deviation, intraventricular conduction disturbances (left anterior hemiblock), left bundle branch block, Wolff-Parkinson-White pattern, and some arrhythmias (ventricular premature contractions, atrial fibrillation). Intraventricular conduction defects are frequently encountered in human cardiomyopathies.^{41,46} The 2 cats with atrial fibrillation in our series were older than the average age of cases in Group A, 1 of the cats being 13 years. Cardiomyopathy in this cat caused a chronic and increasing resistance to ventricular filling, eventually resulting in atrial fibrillation.^{7,10}

The consistently elevated end diastolic pressures recorded in all cats together with the thick hypertrophied ventricular walls indicated a loss of

ventricular compliance during diastole. A marked concentric hypertrophy of the left ventricle and decreased end systolic volume has also been found in valvular aortic stenosis and hypertrophic cardiomyopathy in man.^{6,30} In both cat and man, greater pressure is needed to fill the left ventricle, as it is less compliant than normal, causing resistance to left ventricular filling. Tachycardia produced by stress or exercise shortens diastolic filling time and further limits diastolic filling. Cardiac output falls because the tachycardia is not sufficient to compensate for the drop in stroke volume caused by poor filling. Pulmonary congestion and edema with dyspnea result from mitral regurgitation. Hypertrophic cardiomyopathy may or may not progress to congestive cardiomyopathy. In cats, most cases with hypertrophic cardiomyopathy appear to die before congestive cardiomyopathy is reached. It has been suggested that each human patient with this syndrome is subject to individual variation, and this may also be true for the cat.^{6,13}

Hypertrophic cardiomyopathy with and without obstruction has been studied in detail; however, it is still not certain whether cardiomyopathy with and without obstruction are the same or separate diseases.^{5,17} One view is that both syndromes represent the same disease and that obstruction is only an incidental secondary feature.⁴⁸

The angiographic appearance of the left ventricular cavity of cats with hypertrophic cardiomyopathy was different from that seen most often in humans with hypertrophic cardiomyopathy. In man, the left ventricular cavity is often slitlike, with an S-shaped configuration and contact during systole of the anterior mitral leaflet and the mural endocardium of the left ventricular outflow tract.^{7,12,14,17,30} In most of our cats, the angiographic appearance was characterized by gross left ventricular hypertrophy with distortion of the left ventricular cavity. The angiograms of many cats with hypertrophic cardiomyopathy appear to be more similar to the nonobstructive variety of hypertrophic cardiomyopathy in man. One cat in this study had a type of midventricular systolic pressure gradient that resembled that seen in hypertrophic obstructive cardiomyopathy in man. This cat and others in this study had angiographic evidence of midventricular stenosis at the end of systole. Isoproterenol in this 1 cat caused a marked rise in left ventricular end diastolic pressure, with intensification of the systolic gradient. This drug response is an almost unique feature of hypertrophic cardiomyopathy. Isoproterenol improves the myocardial inotropic state and, hence, the systolic force of the abnormally contracting muscle, with little effect on the velocity of contraction.⁴⁴ Experiments involving the provocation of pressure gradients with isoproterenol in other cats are presently being conducted to further substantiate

hypertrophic cardiomyopathy with obstruction.³⁴ The absence of a pressure gradient in some of the cats may have been due to the fact that catheterizations were performed under anesthesia. It has been reported that the disappearance of the pressure gradient during anesthesia is related to a number of parameters, including magnitude of gradient, type, and concentration of anesthetic and the myocardial depressing effect of the anesthetic used.⁴⁹

In man, hypertrophic cardiomyopathy with obstruction is characterized by marked hypertrophy of the left ventricle, involving in particular the intraventricular septum and the left ventricular outflow tract. Angiocardigraphic and ultrasonic studies have supported the concept that obstruction in most cases results from narrowing of the left ventricular outflow tract produced by the apposition of the anterior leaflet of the mitral valve on the grossly hypertrophic septum during systole. The characteristic abnormality of the systolic motion of the mitral valve can be detected by ultrasound, with the degree of this abnormal systolic movement correlated well with the degree of obstruction.^{13,17} Ultrasonic studies (pending their development in veterinary medicine) will be necessary to document this concept of obstruction in the cat.

The principal pathologic findings in the 27 cats with hypertrophic cardiomyopathy were focal endocardial fibrosis, left ventricular and septal hypertrophy, and left atrial dilatation and hypertrophy. Endocardial fibrosis was always seen in the left ventricular outflow tract and papillary muscles. Left ventricular and septal hypertrophy were often symmetric. Asymmetric septal hypertrophy was observed in 8 affected cats. A microscopic examination revealed bizarre arrangements of cardiac muscle fibers separated by connective tissue. Endocardial fibrosis was observed in the left ventricle and septum.

The gross and histologic findings in the 27 cats in our series were quite similar to those in human patients with hypertrophic cardiomyopathy (with and without obstruction).^{11,12,14} The main cardiac lesions in the seven cats with congestive cardiomyopathy included dilatation of the four cardiac chambers and elongated muscle cells with interstitial fibrosis, similar to those found in human patients with congestive cardiomyopathy.^{11,12} Foci of wavy muscle fibers, characteristic of the feline lesions, were rarely reported in cases of human congestive cardiomyopathy.⁶⁰ Aortic thromboembolism was commonly observed in the cats in our series, while intracardiac fibrin-platelet thrombi were most common in human patients.^{11,12} On the basis of comparative pathology, feline cardiomyopathy provides the experimental pathologists with a biologic model for extensive investigation.

The etiology of hypertrophic cardiomyopathy in the cat is unknown, and cardiomyopathy can result from many different etiologic agents or a combination of factors.¹³ As in man, a familial incidence is present with a greater predominance of hypertrophic cardiomyopathy.^{13,17} The severe disorganization of cardiac muscle cells in the ventricular septum in our series of cats with hypertrophic cardiomyopathy is a histologic finding that is characteristic of genetically transmitted ASH in man.¹⁷ One Persian cat from Group A (hypertrophic cardiomyopathy) came from a household of 32 inbred Persian cats. Further evaluation in 16 of the 32 cats showed 5 cats met some of the clinical criteria suggestive of hypertrophic cardiomyopathy. In contrast to hypertrophic cardiomyopathy, the etiologic factor in congestive cardiomyopathy is regarded to be either viral infection or toxic factors.¹³ Because of the high incidence of spontaneous viral diseases in the cat, viruses may be an important factor in the pathogenesis of this disease. There are numerous reports concerning the possible viral etiology of congestive cardiomyopathy in man.¹⁸

Spontaneous feline hypertrophic and congestive cardiomyopathy presents a new and important model to the cardiovascular investigator. Our laboratory is continuing to explore the detailed natural history of this disease.

References

1. Mattingly TW: Clinical features and diagnosis of primary myocardial disease. *Mod Concepts Cardiovasc Dis* 30:677-682, 1961
2. Fowler NO, Gueron M, Rowlands DT: Primary myocardial disease. *Circulation* 23:498-508, 1961
3. Dye CL, Rosenbaum D, Lowe JC, Behnke RH, Genovese PD: Primary myocardial disease. I. Clinical features. *Ann Intern Med* 58:426-441, 1963
4. Fowler NO: Classification and differential diagnosis of the myocardopathies. *Prog Cardiovasc Dis* 7:1-16, 1964
5. Massumi RA, Rios JC, Gooch AS, Nutter D, DeVita VT, Datlow DW: Primary myocardial disease: Report of 50 cases and review of the subject. *Circulation* 31:19-41, 1965
6. Goodwin JF, Oakley CM: The cardiomyopathies. *Br Heart J* 34:545-552, 1972
7. Goodwin JF: Congestive and hypertrophic cardiomyopathies: A decade of study. *Lancet* 1:731-739, 1970
8. Goodwin JR, Gordon H, Hollman A, Bishop MB: Clinical aspects of cardiomyopathy. *Br Med J* 1:69-79, 1961
9. Braunwald E, Aygen MM: Idiopathic myocardial hypertrophy without congestive heart failure or obstruction to blood flow. *Am J Med* 35:7-19, 1963
10. Oakley CM: Clinical recognition of the cardiomyopathies. *Circ Res* 35 (Suppl II):152-167, 1974
11. Roberts WC, Ferrans VJ: Pathological aspects of certain cardiomyopathies. *Circ Res* 35 (Suppl II):128-144, 1974
12. Roberts WC, Ferrans VJ: Pathologic anatomy of the cardiomyopathies: Idiopathic dilated and hypertrophic types, infiltrative types, and endomyocardial disease with and without eosinophilia. *Hum Pathol* 6:287-342, 1975

13. Hurst JW: Diseases of the myocardium. The Heart, Third edition. New York, McGraw-Hill Book Company, 1974, pp 1311-1386
14. Braunwald W, Lambrew CT, Rockoff SD, Ross J Jr, Morrow AG: Idiopathic hypertrophic subaortic stenosis. I. Description of the disease based upon an analysis of 64 patients. *Circulation* 30 (Suppl IV):3-119, 1964
15. Cohen J Effat H, Goodwin JF, Oakley CM, Steiner RE: Hypertrophic obstructive cardiomyopathy. *Br Heart J* 26:16-32, 1964
16. Teare D: Asymmetrical hypertrophy of the heart in young adults. *Br Heart J* 20:1-8, 1958
17. Epstein SE, Henry WL, Clark CE, Roberts WC, Maron BJ, Ferrans VJ, Redwood DR, Morrow AG: Asymmetric septal hypertrophy: NIH Conference. *Ann Intern Med* 81:650-680, 1974
18. Hamlin RL, Tashjian RJ, Smith CR: Diseases of the cardiovascular system. Feline Medicine and Surgery, First edition. Santa Barbara, Calif., American Veterinary Publications, Inc., 1964, p 218
19. Buchanan JW, Baker CJ, Hill JD: Aortic embolism in cats: Prevalence, surgical treatment and electrocardiography. *Vet Rec* 79:496-505, 1966
20. Freak MJ: Symposium on thrombosis. I. Arterial thrombosis (embolism) in the cat. *J Small Anim Pract* 7:711-717, 1966
21. Liu S-K: Pathology of feline heart disease. Current Veterinary Therapy. Vol V. Edited by RW Kirk. Philadelphia, W. B. Saunders Company, 1974, p 341
22. Liu S-K, Tashjian RJ, Patnaik AK: Congestive heart failure in the cat. *J Am Vet Med Assoc* 156:1319-1330, 1970
23. Liu S-K: Acquired cardiac lesions leading to congestive heart failure in the cat. *Am J Vet Res* 31:2071-2088, 1970
24. Tilley LP, Liu S-K: Cardiomyopathy and thromboembolism in the cat. *Feline Pract* 5:29-41, 1975
25. Harpster NK: Acquired heart disease in the cat. Proceedings, 40th Annual Meeting, American Animal Hospital Association, 1973, p 118
26. Lord PF, Wood A, Tilley LP, Liu S-K: Radiographic and hemodynamic evaluation of cardiomyopathy and thromboembolism in the cat. *J Am Vet Med Assn* 164:154-165, 1974
27. Lord PF, Tilley LP, Wood A: Radiography and angiocardiology of feline cardiomyopathy: An abstract. *J Am Vet Radiol Soc* 15:56-59, 1974
28. Tilley LP, Lord PF, Wood A: Acquired heart disease and aortic thromboembolism in the cat.²¹ p 305
29. Tilley LP: Cardiomyopathy and thromboembolism in the cat. *Vet Med Small Anim Clin* 70:313-316, 1975
30. Fowler NO: Diagnosis of the myocardial disease. *Cardiovasc Clin* 4:77-94, 1972
31. Blok J, Boeles JThF: The electrocardiogram of the normal cat. *Acta Physiol Pharmacol (Neerlandica)* 6:95-102, 1957
32. Hamlin RL, Smetzer DL, Smith CR: The electrocardiogram, phonocardiogram, and derived ventricular activation process of domestic cats. *Am J Vet Res* 24:792-802, 1963
33. Rogers WA, Bishop SP: Electrocardiographic parameters of the normal domestic cat: A comparison of standard limb leads and an orthogonal system. *J Electrocardiol* 4:315-321, 1971
34. Tilley LP, Liu S-K, Gilbertson SR, Wagner BM, Lord PF: Unpublished data
35. Hamlin RL, Smetzer DL, Smith CR: Radiographic anatomy of the normal cat heart. *J Am Vet Med Assoc* 143:957-961, 1963
36. New York Heart Association: Nomenclature and Criteria for Diagnosis of Diseases of the Heart and Great Vessels, Seventh edition. Boston, Little, Brown and Company 1973, p 236

37. Hamby RI, Catangay P, Apiado O, Khan AH: Primary myocardial disease. Clinical, hemodynamic, and angiocardiographic correlates in 50 patients. *Am J Cardiol* 25:625-634, 1970
38. Goodwin JF, Oakely CM: The cardiomyopathies: Editorial. *Br Heart J* 34:545-552, 1972
39. Elster SK, Horn H, Tuchman LR: Cardiac hypertrophy and insufficiency of unknown etiology: A clinical and pathologic study of 10 cases. *Am J Med* 118:900-922, 1955
40. Spodick DH, Littman D: Idiopathic myocardial hypertrophy. *Am J Cardiol* 1:610-623, 1958
41. Stapleton JR, Segal JP, Harvey WP: Clinical pathways of cardiomyopathy. *Circ Res* 34 & 35 (Suppl II):168-178, 1974
42. Marcus FI, Gomez L, Glancy DL, Ewy GA, Roberts WC: Papillary muscle fibrosis in primary myocardial disease. *Am Heart J* 77:681-685, 1969
43. Roberts WC, Perloff JK: Mitral valvular disease: A clinicopathologic survey of the conditions causing the mitral valve to function abnormally. *Ann Intern Med* 77:939-975, 1972
44. Spodick DH: Hypertrophic obstructive cardiomyopathy of the left ventricle (idiopathic hypertrophic subaortic stenosis). *Cardiovasc Clin* 4:133-165, 1972
45. Harvey WP, Segal JP, Gurel T: The clinical spectrum of primary myocardial disease. *Prog Cardiovasc Dis* 7:17-42, 1964
46. Shah PM, Gramiak R, Kramer DH, Yu PN: Determinants of atrial (S_4) and ventricular (S_3) gallop sounds in primary myocardial disease. *N Engl J Med* 278:753-758, 1968
47. Bahl OMP, Massie E: Electrocardiographic and vectorcardiographic patterns in cardiomyopathy. *Cardiovasc Clin* 4:95-112, 1972
48. Nasser WK, Williams JF, Mishkin ME, Childress RH, Helman C, Merrit AD, Genovese PD: Familial myocardial disease with and without obstruction to left ventricular outflow: Clinical, hemodynamic, and angiocardiographic findings. *Circulation* 35:638-652, 1967
49. Braunwald E, Morrow AG, Cornell WP, Aygen MM, Hilbish TF: Idiopathic hypertrophic subaortic stenosis: Clinical, hemodynamic and angiograph manifestations. *Am J Med* 29:924-945, 1960
50. Okada R: A morphological classification of the idiopathic myocardial disease and allied cardiac diseases. *Jap Circ J* 35:755-763, 1971

Acknowledgments

The authors gratefully acknowledge the editorial assistance of Cynthia Fazzini of The Animal Medical Center and M. Zarufu of Beekman Downtown Hospital. The authors also express their appreciation to Dr. J. Ornato of New York Hospital-Cornell Medical Center for his review of the manuscript. Special recognition is also given to Dr. A. I. Hurvitz, Director of Research of the Department of Pathology of The Animal Medical Center for his continued support.

[Illustrations follow]

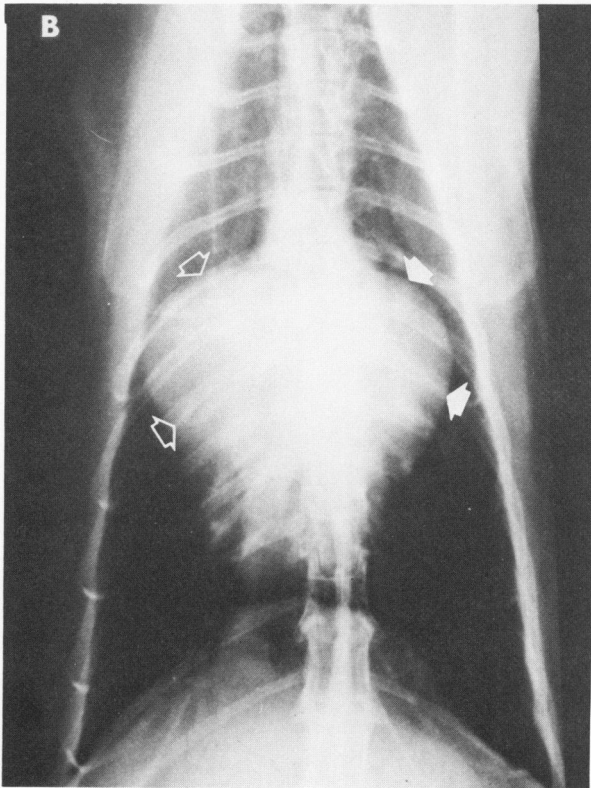
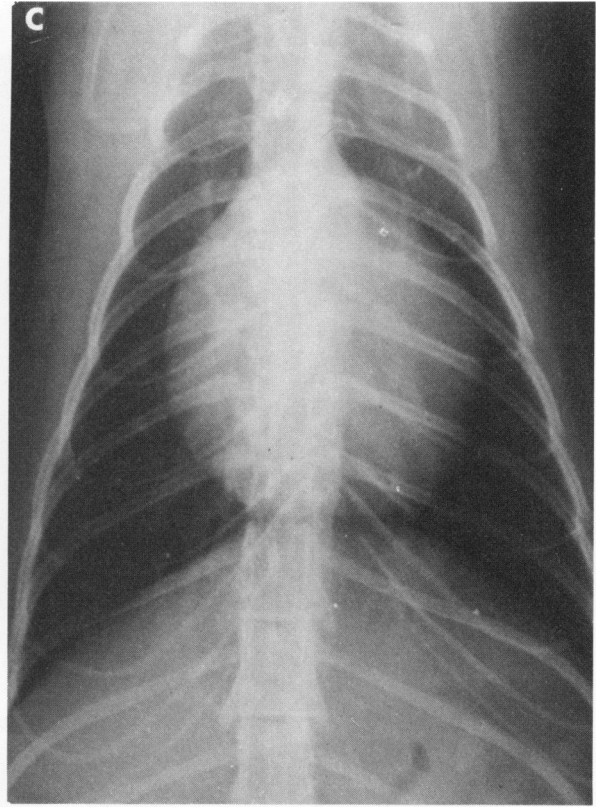
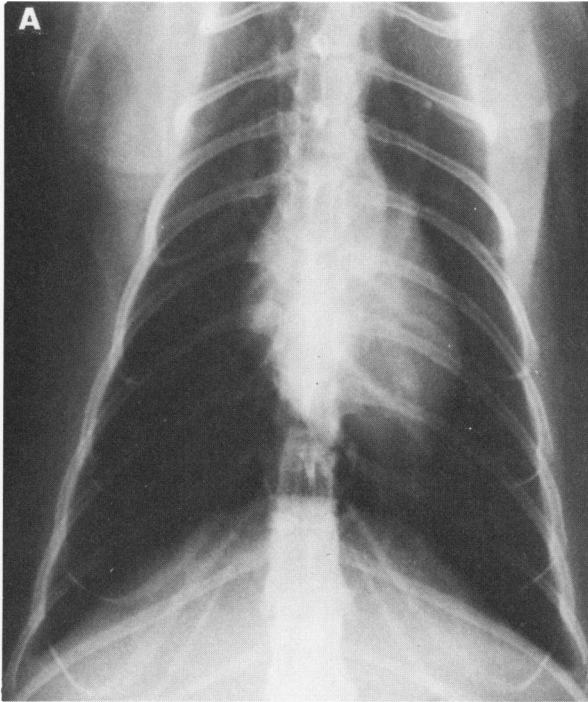

Figure 1—Plain film chest radiographs. **A**—Normal cardiac silhouette of a cat for comparison. **B**—Dorsoventral radiograph from a 2-year-old Persian cat with hypertrophic cardiomyopathy at necropsy. Enlargement of the right atrium and ventricle (*open arrows*) and left atrium (*solid arrows*) gives the appearance of a "valentine-shaped" heart. (Reprinted from Tilley²⁹ by permission of the publisher). **C**—Dorsoventral radiograph of a 10-year-old domestic shorthaired cat with congestive cardiomyopathy at necropsy. Enlargement of all chambers is present.

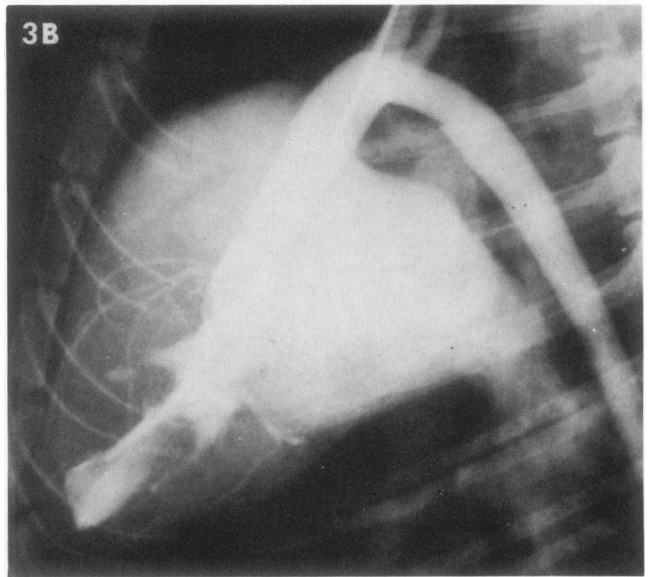
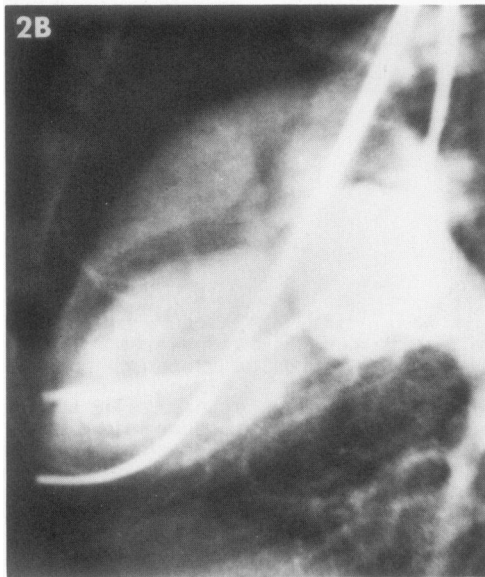
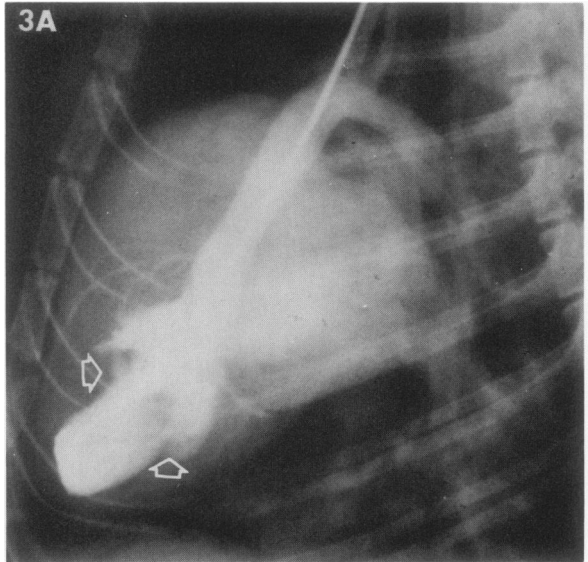
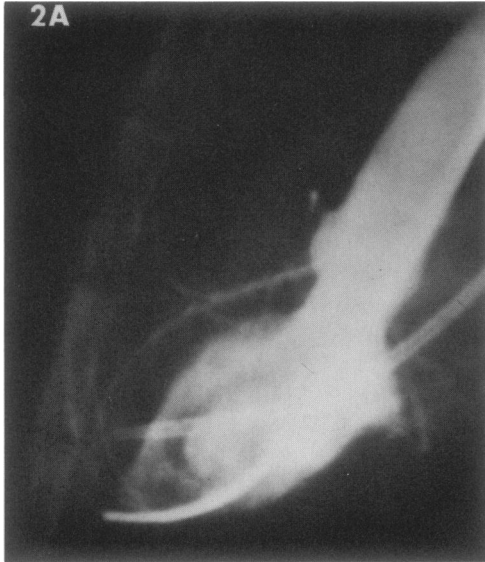

Figure 2—Normal left ventriculogram of same cat in early systole (A) and end diastole (B), showing the normal size of the chambers. The left atrium is outlined in B, as a right ventricular injection was used to opacify the heart. (Reprinted from Lord *et al.*²⁶ by permission of the publisher) **Figure 3**—Left ventriculogram of the same cat in Text-figure 3C (Cat 7, Table 3). **A**—Early systole, one second after injection of contrast medium. The chamber is very irregular with prominent filling defects (*arrows*) caused by the hypertrophied and fibrosed papillary muscles. **B**—End of systole, 4 seconds after injection of contrast medium. The hypertrophied ventricular wall caused marked midventricular stenosis, which produced a gradient of 60 mm Hg. The apex remains as a small cavity. The large left atrium is now opacified because of mitral regurgitation. (Reprinted from Lord *et al.*²⁶ by permission of the publisher)

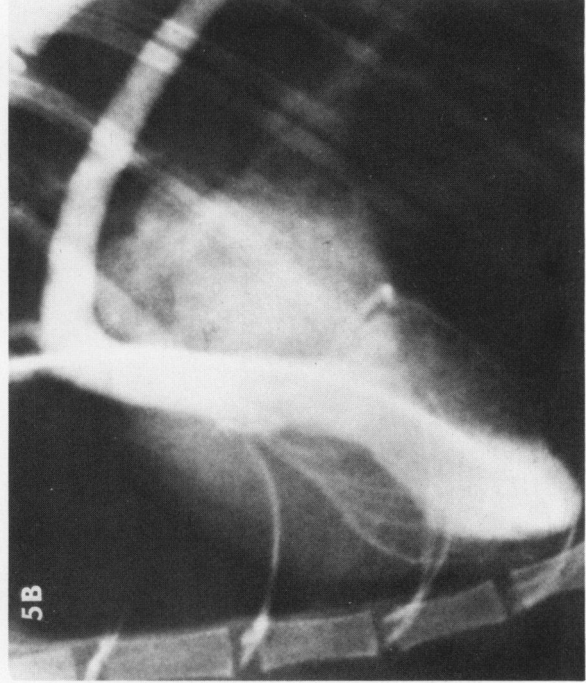
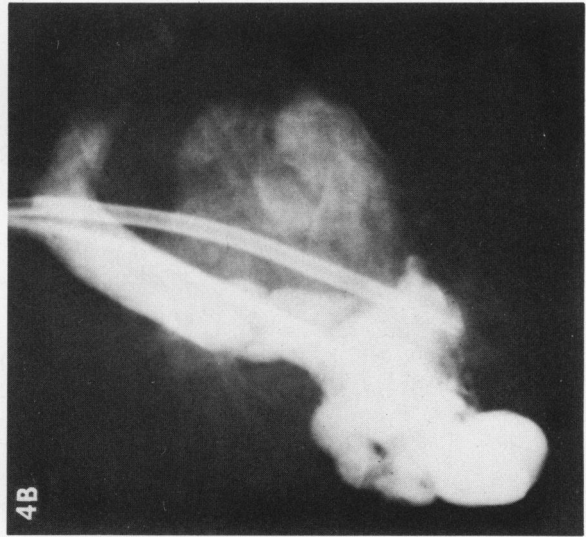
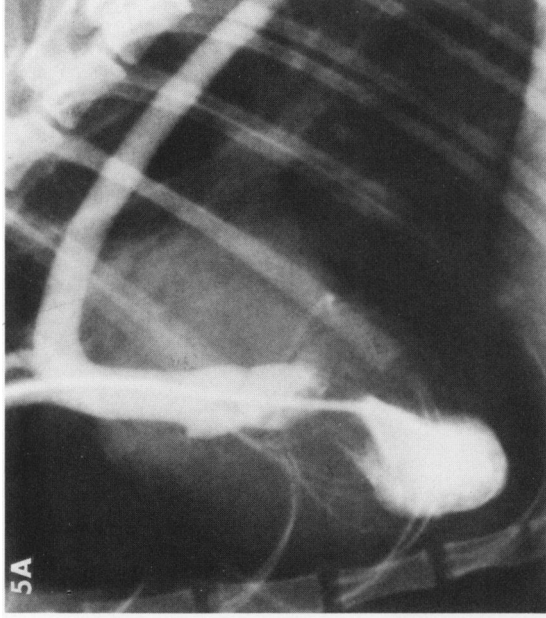
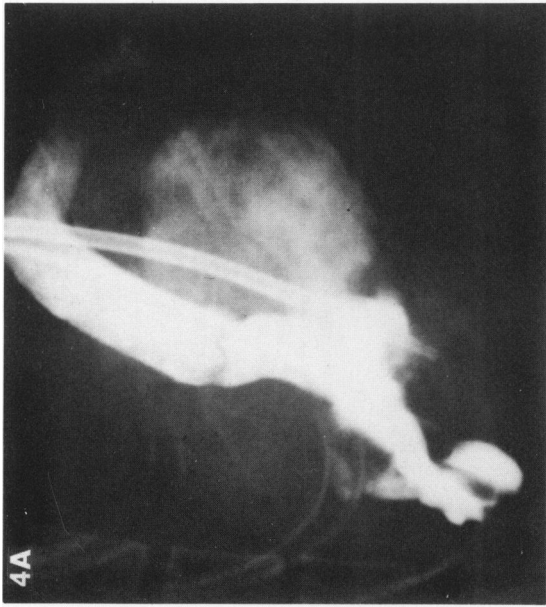

Figure 4—Left ventriculogram in early diastole (A) and at end of diastole (B) of the same cat in Text-figure 3B. Left ventricular hypertrophy and marked endomyocardial fibrosis have produced an irregular left ventricular cavity. Mitral insufficiency is indicated by a large opacified left atrium. The larger catheter extends from the jugular vein to the right atrium. (Reprinted from Lord *et al.*²⁸ by permission of the publisher)

Figure 5—Left ventriculograms in early diastole (A) and end of diastole (B) of a 2-year-old domestic shorthaired cat with posterior paralysis of sudden onset. Note midventricular obstruction due to the thickened left ventricular wall and encroachment upon the mid-portion of the ventricular cavity.

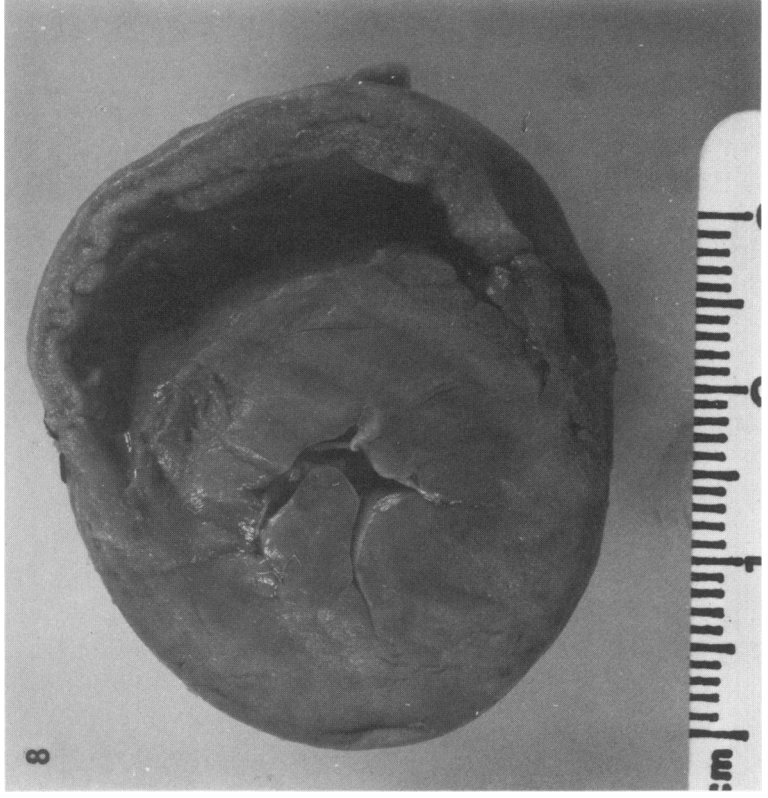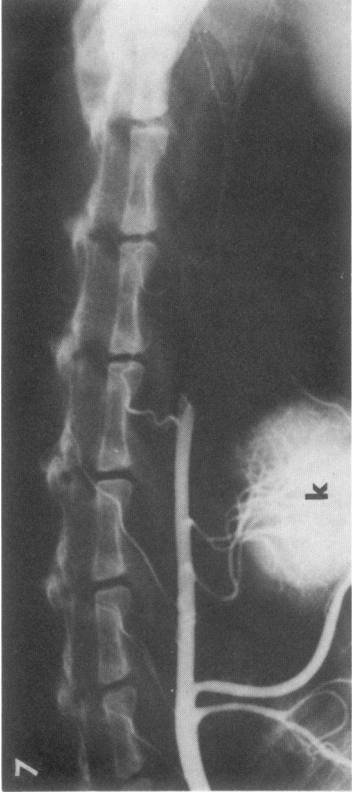
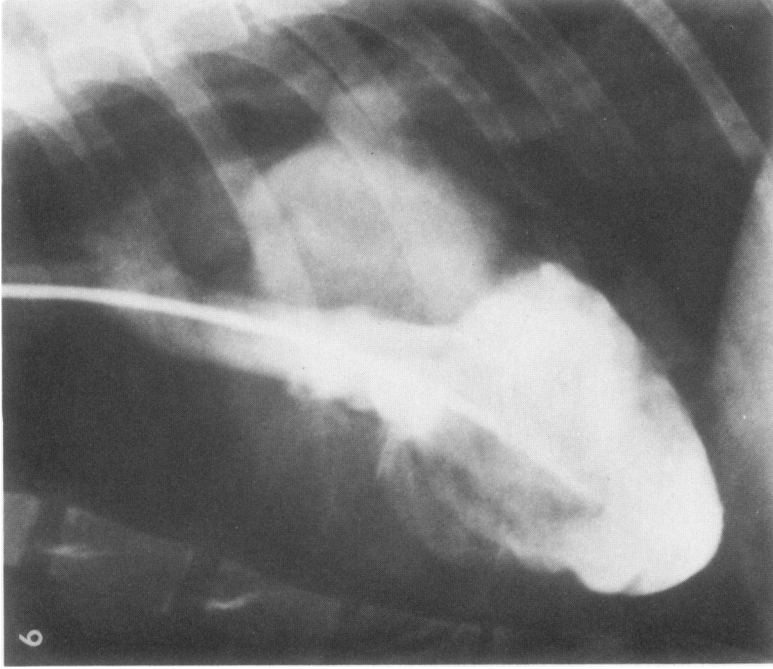


Figure 6—Left ventriculogram of a 5-year old domestic shorthaired cat with dyspnea. Enlargement of all cardiac chambers and pleural effusion was seen on plain film thoracic radiographs. Left atrial enlargement is seen because of mitral insufficiency. The left ventricle is severely dilated. This is an example of a cat with congestive cardiomyopathy. **Figure 7**—Aortogram of a 4-year-old domestic shorthaired cat with dyspnea and a sudden onset of lameness of the hind legs. A large thromboembolus is noted in the abdominal aorta cranial to the iliac bifurcation. The cat also had hypertrophic cardiomyopathy at necropsy. K = kidney. **Figure 8**—Transverse section of ventricles of the heart from a 13-year-old altered male domestic shorthaired cat. Hypertrophy of the left ventricular free wall, ventricular septum, and papillary muscles caused extreme narrowing of the left ventricular cavity.

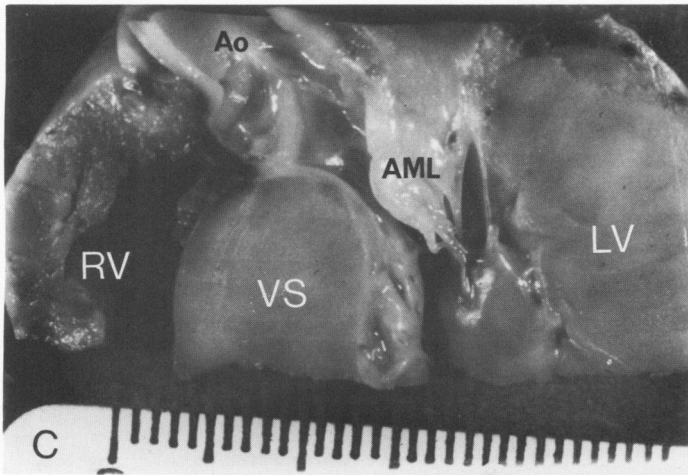
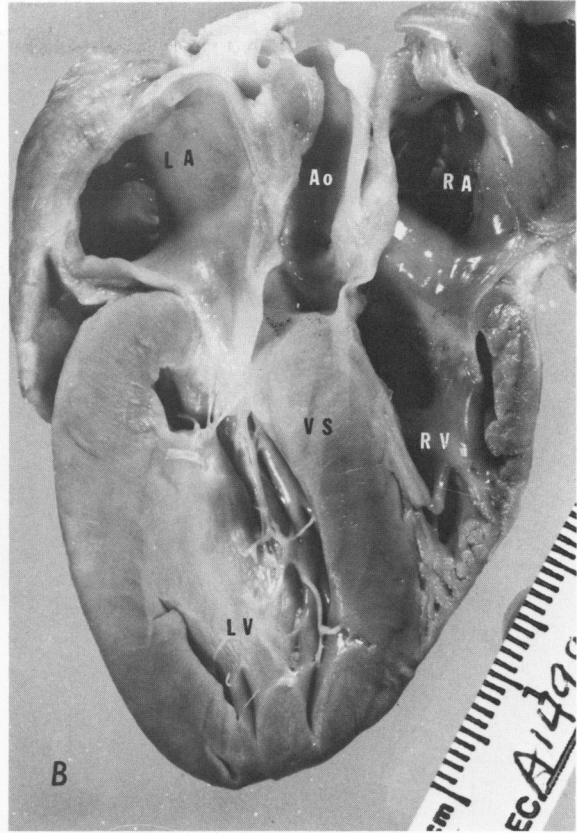
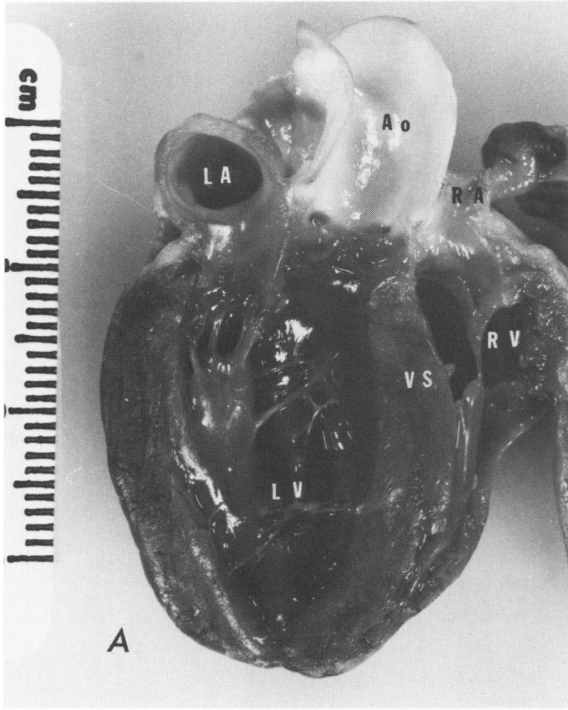


Figure 9A—A normal heart from a 2½-year-old male domestic shorthaired cat. The ventricular septum (VS), left atrium (LA), left ventricle (LV), right atrium (RA), right ventricle (RV), and aorta (Ao) are normal. **B**—Longitudinal section of heart with hypertrophic cardiomyopathy from a 3-year-old male Persian cat. The heart has been sectioned to that point where the posterior mitral valve leaflet is not shown. The ventricular septum was thicker than the left ventricular free wall. The anterior portion of the hypertrophied ventricular septum bulged into and obstructed the lumen of the left ventricular outflow tract. Hypertrophy of the left ventricular free wall, papillary muscles, and ventricular septum caused narrowing of the left ventricular cavity. **C**—Close-up view of left ventricular outflow tract from a 5-year-old male domestic shorthaired cat with hypertrophic cardiomyopathy. Endocardial fibrosis in the left ventricular outflow tract is present in close apposition to a thickened anterior mitral leaflet (AML). The left ventricular outflow tract is narrowed due to disproportionate thickening of the ventricular septum.

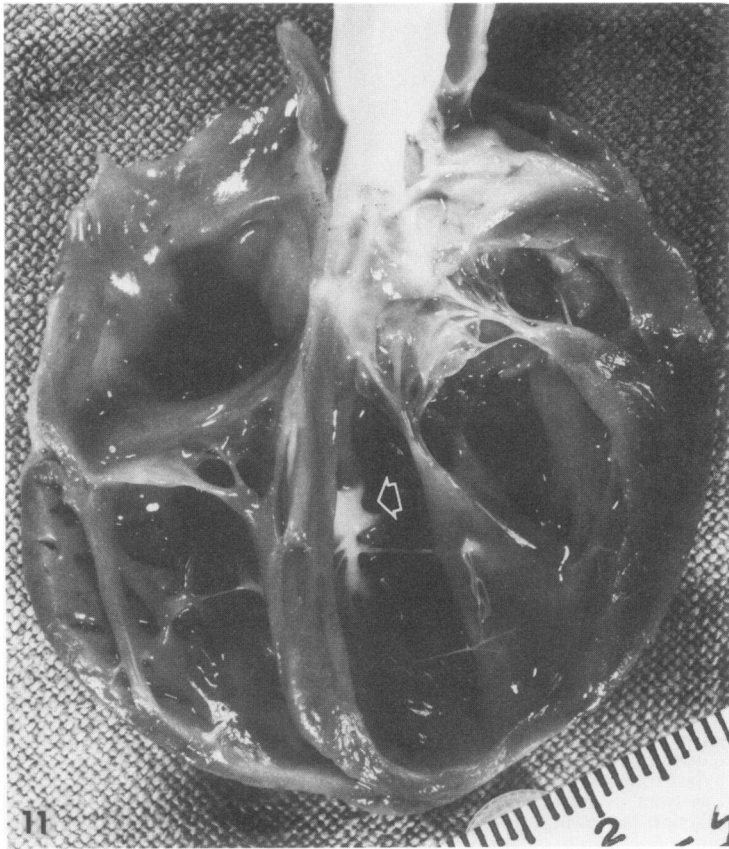



Figure 10—Presence of a fresh thromboembolus in the terminal aorta of a 4-year-old castrated male domestic shorthaired cat with hypertrophic cardiomyopathy. **Figure 11**—Heart from a 7-year-old male domestic shorthaired cat with congestive cardiomyopathy. All four chambers are dilated. Focal endocardial fibrosis (arrow) was found in left ventricular septum.

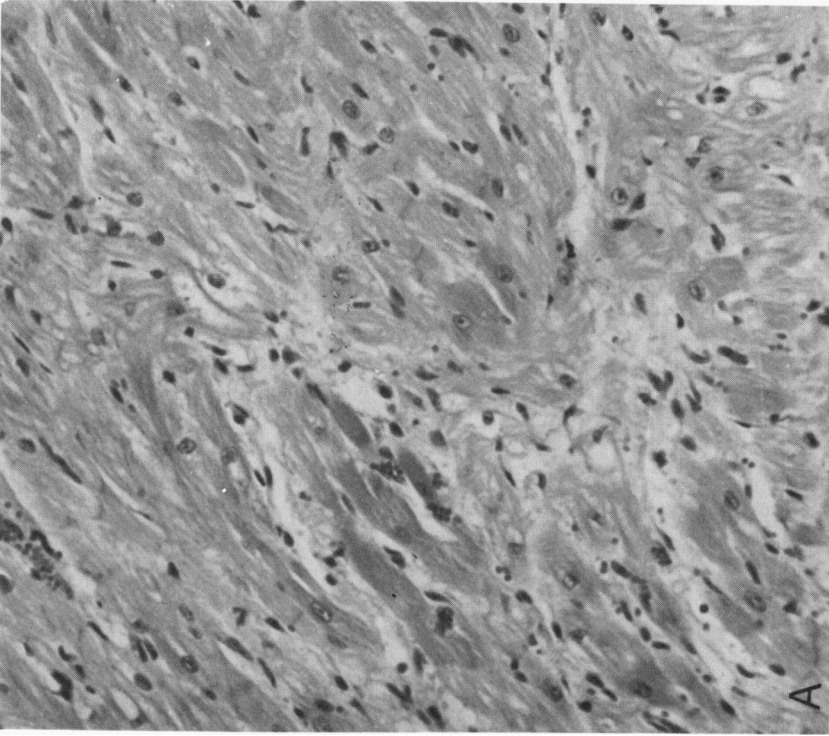
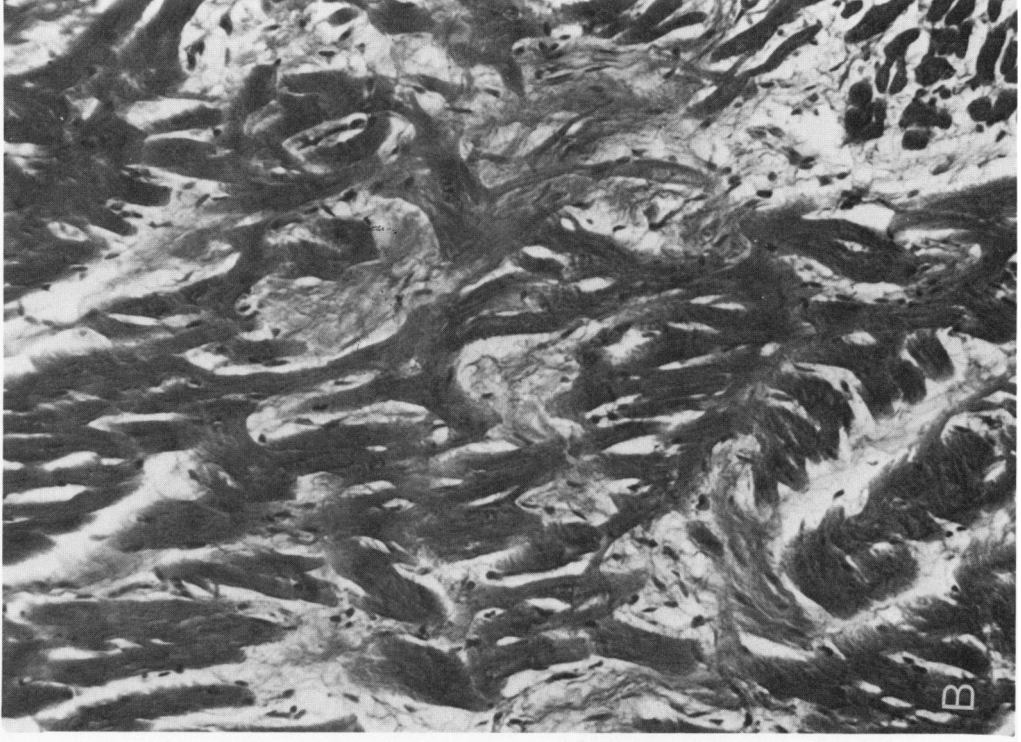


Figure 12A—Histologic section of the ventricular septum myocardium from Figure 9B showing hypertrophied muscle cells and abnormal arrangement of the bundles (H&E, original magnification $\times 100$). **B**—Histologic section of the ventricular septal myocardium from a 5-year-old male domestic shorthaired cat with hypertrophic cardiomyopathy showing irregular arrangement of the muscle cells (H&E, original magnification $\times 100$).



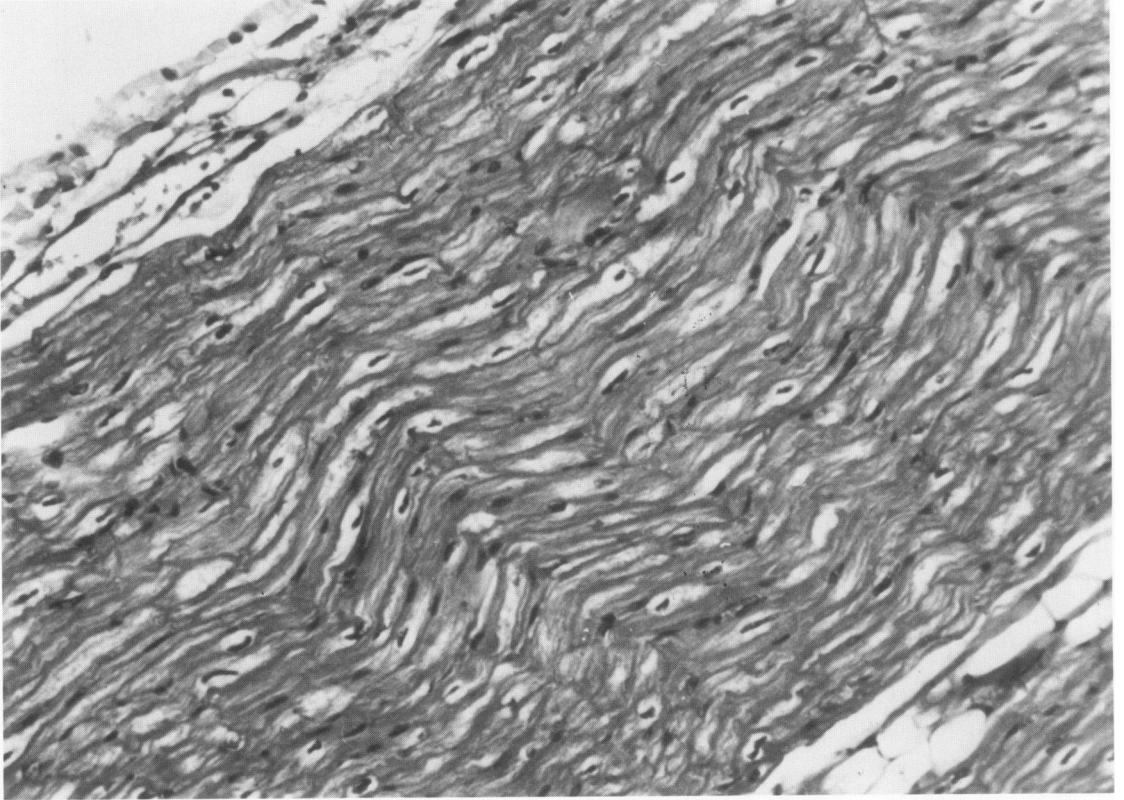


Figure 13—Histologic section of left ventricular free wall from Figure 11 exhibiting elongated and wavy myofibers (H&E, original magnification $\times 100$).