

# Myocardial Fibrosis and Smooth Muscle Cell Hyperplasia in Coronary Arteries of Allylamine-Fed Rats

J. J. Lalich, MD, J. R. Allen, PhD and W. C. W. Paik, MD

Immature female Long-Evans rats were fed 2 g of allylamine-HCl/kg of commercial diet for periods of 84–281 days. Coronary arteries and myocardium were examined in 16 control and 23 test rats. Cellular alterations in the arterial tributaries were found principally proximal to or within the areas of myocardial fibrosis. Whereas intimal smooth muscle cell (SMC) hyperplasia was prominent in vessels of smaller caliber, medial hyalinosis was seen frequently in arteries with diameters greater than 200  $\mu$ . Intimal hyperplasia developed in the peripheral coronary branches without any evidence of leukocytic infiltration or thrombus formation. It appeared that SMC hyperplasia in the intima contributed more often to a reduction of luminal patency than medial hyalinosis in allylamine-fed rats. On the basis of alterations in the coronary arteries and the localization of fibrosis, we believe that hypoxia is the cause of myocardial necrosis. (*Am J Pathol* 66:225–240, 1972).

ALLYLAMINE INJECTED PARENTERALLY has produced inflammation and necrosis in arteries of dogs and rats. The variable degrees of arterial injury recorded undoubtedly depend upon the concentration of drug utilized and the route of administration employed.<sup>1</sup> While it was relatively easy to produce myocardial necrosis and arteritis by inhalation of vapor in rats, intravenous or intraperitoneal injection of allylamine was ineffective.<sup>1</sup> Intravenous administration has predisposed dogs to edema, medial necrosis, intimal fibrosis or arteritis in the coronary arteries.<sup>2–5</sup> The same route of injection induced medial necrosis and leukocytic infiltration in aortas of rats.<sup>6</sup> Infusing of allylamine into the femoral artery of rats caused a loss of endothelial continuity.<sup>7</sup> Ingestion of this drug for periods of 3 or more months at concentrations compatible with moderate growth in immature rats elicited edema or hyalinosis of the media and hypertrophy of coronary arteries.<sup>8</sup> Three studies have drawn attention to the fact that allylamine-induced alterations in the coronary arteries are associated with myocardial necrosis.<sup>1,5,8</sup> However,

---

From the Department of Pathology and the Wisconsin Regional Primate Research Center, University of Wisconsin, Madison, Wisc.

Supported by grants HE-12162-08 and HE-10941-04 from the National Institutes of Health.

Accepted for publication August 3, 1971.

Address reprint requests to Dr. J. J. Lalich, Department of Pathology, University of Wisconsin Medical School, 470 North Charter St., Madison, Wisc 53706.

the magnitude and localization of necrosis with respect to the caliber of the coronary artery involved has not been resolved. In contrast to other studies, in the presence of multiple necrotic foci in the left ventricle, it was not possible to demonstrate thrombi, leukocytic infiltration or complete obliteration of the lumens in the coronary arteries.<sup>8</sup> Since myocardial necrosis was invariably accompanied by focal medial hyalinosis in large coronary arteries and what appeared to be medial hypertrophy in the intermediate tributaries, it was suggested that allylamine may be selectively cytotoxic to smooth muscle cells (SMC).<sup>8</sup> Observations in rats therefore suggest that extensive myocardial necrosis capable of producing cardiac decompensation may be induced without obliteration of the lumen of large coronary arterial branches. On the basis of this assumption it appeared worthwhile to undertake additional studies of allylamine feeding in rats so that the relationship of luminal patency in arteries of different size and myocardial fibrosis could be investigated more extensively with light and electron microscopy.

### Materials and Methods

Immature female Long-Evans rats were employed in this study. A ground commercial diet (Lab Blox) was fed to 16 control rats from 169 to 371 days. In 23 test rats, 2.0 g of granulated allylamine-HCl was uniformly mixed in the ground commercial diet and fed *ad libitum* for periods of 84–281 days. The rats were weighed at monthly intervals. When an animal lost 15% or more of its weight within 1–2 weeks, ether was administered and a necropsy was performed. Those rats were excluded from this study in which pneumonia was found to be responsible for the weight loss. The ventricles were opened, excess blood was blotted on paper and the hearts were weighed. Every heart was inspected for the presence of thrombosis in the left auricle and the location of ventricular fibrosis. After fixation in buffered formalin, two transverse segments of heart were taken for paraffin embedding. Sections of paraffin-embedded heart from 16 control and 16 test rats were cut and treated with H&E, trichrome and a platelet stain.<sup>9,10</sup> In 7 other test rats, multiple 1–2 mm cuts were made across the coronary arteries leading to an area of myocardial macrofibrosis. Thereafter, the heart was immersed into cold buffered glutaraldehyde for periods of ½–1 hour. After this, the myocardium with an attached arterial segment was trimmed into 1–2 mm blocks and subjected to additional fixation in cold glutaraldehyde.<sup>11</sup> These selected blocks were subsequently fixed in osmic acid and embedded in epoxy resin.<sup>12,13</sup> In this manner, 10 specimens proximal to or within the area of myocardial fibrosis were taken from each heart for evaluation with light and electron microscopy. Sections 1  $\mu$  thick were prepared from each epoxy-embedded block, stained with toluidine blue and examined for evidence of cellular hyperplasia in the intima of coronary arteries. Thin sections were later cut for ultrastructural inspection whenever examination by light microscopy indicated that cellular alterations had occurred in the peripheral arterial branches. The basilar portion from these 7 hearts was cut for paraffin embedding and inspection with light microscopy for the presence of hyalinosis, arteritis, or thrombosis in the larger arterial branches.

## Results

### Gross

The duration of feeding, weight gains, ratio of heart to body weight and microscopic alterations that were seen in paraffin-embedded hearts from 16 control and 16 test rats are tabulated in Table 1.

Control rats were heavier than the test animals at necropsy. Less weight in test rats was attributed to the toxicity of allylamine and a shorter experimental period. Nothing abnormal was found in the thoracic or peritoneal organs in control rats. One or more foci of fibrosis were evident in the apical portion of the heart in every test rat. Auricular hypertrophy alone was seen in 6 rats. In 3 animals, the auricular hypertrophy was complicated by thrombosis of the left auricle. Three of these rats developed cardiac decompensation and hydrothorax after 96, 240 and 280 days. Appreciable (in excess of 0.45) increases in the heart to body weight ratio occurred in 6 rats with auricular hypertrophy. In 11 rats in which the ratio varied from 0.32 to 0.44, we did not resolve the question of whether the increase was due to hypertrophy of the auricles or of the ventricles. In 6 of 16 rats, the ratio was equal to the upper normal limit (0.31). Ventricular fibrosis failed to induce a significant compensatory hypertrophy in 6 rats. The other organs were normal except for the lungs. In rats with impending or obvious cardiac decompensation, either focal alveolar hemorrhage or a rusty parenchymal discoloration was evident.

Table 1—Response of Heart to Feeding of Allylamine-HCl

	Control rats	Rats fed allylamine-HCl (2 g/kg)
No. of rats	16	16
Average duration of feeding (days)	337	239
Average weight: initial/final	102/364	111/270
Ratio of heart to body weight	0.28 ± 0.03	0.39 ± 0.08
Cellular alterations related to arterial size		
Intimal hyperplasia		
70 μ or less		11
70–200 μ		16
over 200 μ		4
Medial hyalinosis		
70 μ or less		0
70–200 μ		4
over 200 μ		6

### Light Microscopy

Nothing unusual was seen on microscopic inspection of 31 H&E sections of myocardium from 16 control rats. A focus of subepicardial microfibrosis was found in one section in 1 control rat. In 32 trichrome-stained sections, the coronary arteries were not affected by medial edema or hyalinosis. In paraffin-embedded tissue stained with H&E or trichrome, it was not always possible to discern whether the intima or media or both were contributing to hypertrophy in arteries of small and intermediate size. On such occasions, Gomori's silver stain was employed when necessary. In coronary arteries of 3 control rats, reductions of luminal width were attributed mainly to arterial contraction.

In 16 test hearts, the discrete foci of fibrosis were less common than the large bands of collagen. While the fibrosis was limited to the apical left ventricles in most instances, it also involved the right ventricle in some rats (Fig 1 and 2). When myocardial fibrosis was extensive, it formed a continuous circumferential subendocardial band. On many occasions, the cordae tendinae were replaced by cartilage. In about 1 of 4 hearts, foci of medial necrosis were associated with dystrophic calcification. The frequency of intimal hyperplasia in the coronary arteries of different size is shown in Table 1. Intimal hyperplasia was more extensive and frequent in arteries of intermediate size (Fig 3 and 5). Cellular proliferation in the arterioles appeared less frequently. Intimal hyperplasia of arterioles was seen principally within the band of myocardial fibrosis. Proliferations of intimal cells in intermediate arteries occurred within and exterior to foci of myocardial fibrosis. In large arteries, cellular proliferation tended to involve a portion of the intimal circumference and it occurred less frequently. As can be seen in Table 1, medial hyalinosis (as depicted in Fig 4) occurred in the intermediate and large arteries, but not in the arterioles. Usually medial hyalinosis and intimal cellular hyperplasia did not occur in the same segment of artery. Medial hyalinosis and adventitial fibrous proliferation were frequently present together. Invariably, necrosis of medial SMCs was associated with fibrous proliferation in the media as well. Both medial hyalinosis and intimal hyperplasia were definitely more prevalent in coronary arteries that were adjacent to or within a band of myocardial fibrosis. A special stain for platelets did not reveal thrombi in coronary arteries in 32 paraffin-embedded sections from 16 test rats. There was no evidence of medial hemorrhagic necrosis or leukocytic infiltration in the coronary arteries of these rats. In paraffin-embedded and H&E-stained sections from the basilar part of the ventricles of hearts employed for epoxy

embedding, inspection revealed focal medial hyalinosis in 3 hearts and medial edema in large arteries in 4 hearts.

Light microscopic inspection of epoxy-embedded tissue stained with toluidine blue clearly indicated that the cellular hyperplasia was occurring principally in the intima (Fig 6 and 7). Confirming observations made in paraffin-embedded sections, intimal cellular proliferation was more extensive and frequent in arteries of intermediate caliber. Regardless of the degree of intimal involvement, endothelial continuity remained intact (Fig 6-8 and 10). On most occasions the inner elastica remained intact although frequently repositioned by proliferated SMCs. Inspection of the arteries did not offer any morphologic clues that would suggest why intimal hyperplasia had occurred.

#### **Electron Microscopy**

Electron microscopic study was limited to those coronary vessels altered by variable degrees of SMC hyperplasia. The size, shape, and density of the hyperplastic subendothelial muscle cells varied considerably (Fig 9 and 10). The most obvious difference in the muscle cells in these vessels was the variation in electron density. Approximately one-third of the cells were electron dense while the others were more electron lucent (Fig 10). In addition to the difference in density, there were variations in their internal morphologic features. The more lucent cells contained fewer myofilaments and more widely distributed cytoplasmic organelles (Fig 11). The increased density of the dark cells was attributed to the numerous and closely associated myofilaments in the matrix. Both cell types contained variably sized dense granular aggregates (Fig 9, 10 and 12). On occasion, these aggregates attained a size equal to or larger than that of the nucleus (Fig 12). The basal laminae of contiguous muscle cells were separated by a narrow lucent and sinuous network of elastin (Fig 11). The repositioned internal elastic lamina underlying these muscle cells frequently was reduced in size, more irregular in outline and contained larger fenestrations (Fig 10). The media of the affected vessels consisted primarily of large cells that were predominantly of the lucent variety. In addition to the numerous filaments, organelles and dense aggregates, there were occasional cells that contained large clear vacuoles. Endothelial continuity remained intact; however, some of the cells contained cytoplasmic vacuoles.

#### **Discussion**

Necrotizing cardiomyopathy has been produced either by direct cardiotoxic injury or indirectly after a reduction of luminal size in coro-

nary arteries. Many drugs such as isoproterenol, methoxamine, plasmocid, adrenocorticoids or cobalt will exert a direct cardiotoxic effect after they are administered parenterally.<sup>14-17</sup> Up to the present time, only allylamine has induced coronary arteritis and gross myocardial necrosis after intravenous injection into dogs or inhalation by rats.<sup>1,5</sup> Injecting allylamine parenterally into rats has caused cellular alterations in the aorta without demonstrable involvement of the coronary arteries or myocardial infarction.<sup>6</sup> Feeding allylamine salt for periods of 3 or more months to rats has produced appreciable alterations in coronary arteries and myocardial necrosis.<sup>8</sup> In this respect the selectivity for coronary arteries of allylamine feeding is comparable to that produced by the ingestion of diets high in fat and cholesterol. Consumption of diets containing excess fat and cholesterol promotes severe atheromatous lesions, coronary occlusion and myocardial infarction.<sup>17-20</sup> Allylamine feeding, on the other hand, induces intimal hyperplasia, medial hyalinosis and adventitial fibrosis in the coronary arteries of rats. Whereas the possibility of thrombosis has not been excluded, examination of numerous heart sections failed to reveal thrombi in allylamine-fed rats. Despite the lack of demonstrable thrombi, we believe that allylamine-induced alterations in the coronary arteries are of sufficient magnitude to cause hypoxia and predispose the animal to a circumferential subendocardial necrosis of the ventricles.

Depending on the animal employed and the method of administering allylamine, alterations have been observed in the arterioles<sup>1,2</sup> and the intermediate<sup>1,2,5,8</sup> and large<sup>2,5,8</sup> branches of the coronary arteries. The cellular response in these vessels has varied from edema,<sup>4</sup> or hyalinosis of the media,<sup>8</sup> associated with adventitial fibrosis,<sup>2,8</sup> to hemorrhagic medial necrosis<sup>2,3,5</sup> and arteritis.<sup>1-3,5</sup> Ingestion of allylamine or one of its metabolites promotes either hyperplasia in the intima or necrosis of SMCs in the media. It is noteworthy that necrosis of SMCs in the media of coronary arteries has been produced by parenteral administration,<sup>2,3,5</sup> inhalation<sup>1</sup> and ingestion of allylamine. Information concerning the mechanism by which allylamine acts on SMCs, however, has not been clarified. For some unknown reason, medial hyalinosis is more prominent in arteries greater than 200  $\mu$ , whereas intimal hyperplasia is frequent and extensive in vessels of intermediate size and the arterioles. When medial hyalinosis was conspicuous, it was invariably accompanied by adventitial fibrous proliferation. It appears paradoxical indeed to observe active intimal proliferation of SMCs in the arterioles and intermediate tributaries, whereas necrosis of similar cells has occurred in the media, presumably in the same artery. A similar variation

in response of SMCs at different levels has been seen also in the aorta of rats fed allylamine.<sup>21</sup>

Examination of affected arteries by electron microscopy makes it possible to postulate the progressive modifications that eventually produce partial to extensive occlusion of small myocardial arteries. In normal arteries, only isolated SMCs were located between the basal portion of the endothelium and the internal elastic lamina. Intimal proliferation was first characterized by the appearance of four or five SMCs superficial to the internal elastic lamina. As these muscle cells increased in size and number, the internal elastic lamina was positioned further away from the lumen of the vessel. Alterations in the position and size of the elastic membrane suggested that SMC hyperplasia was exerting some effect on the elastica. Before it can be resolved whether cellular hyperplasia in the intima or migration of SMCs from the media occurred, additional studies will have to be done. While SMCs of the intima were undergoing hyperplasia, other modifications were developing in the media. Moderate hyperplasia and considerable hypertrophy of SMCs were seen in the media. When tissue for examination for electron microscopy was selected proximal to or within the areas of myocardial fibrosis, arteries with intimal hyperplasia without medial hyalinosis were obtained on most occasions. It appears that ingestion of allylamine over an extended period did not disrupt the endothelial continuity of coronary arteries. Our observations, therefore, differ substantially from those reporting loss of femoral endothelium after an intraarterial injection of allylamine.<sup>7</sup>

The anatomic location of myocardial fibrosis that develops in allylamine-fed rats is similar to the necrosis seen after the coronary artery is ligated in rats and rabbits.<sup>22,23</sup> After ligation of major arterial branches in rats or rabbits, viable myocardium has been shown to persist in the subepicardial and subendocardial zones. Persistence of viable subendocardial myocardium in allylamine-fed rats, therefore, does not exclude hypoxia as a cause for necrosis. Despite the numerous subdivisions that exist in the coronary arteries of normal rats,<sup>24,25</sup> widespread intimal hyperplasia in the intermediate and arteriolar branches could induce sufficient hypoxia to promote multifocal myocardial necrosis. Both the localization of myocardial necrosis principally in the apex of the left ventricle and the paucity of anastomoses that exists in coronary arteries of normal rats<sup>23</sup> support the concept that hypoxia can cause myocardial necrosis in allylamine-fed rats.

The absence of luminal obliteration in the proximal coronary arteries of allylamine-fed rats tends to favor the hypothesis that intimal hyper-

plasia in the smaller arteries is critical in the production of myocardial infarction. Allylamine is unusually selective in the localization of arterial injury in the coronary arteries, because vessels of similar caliber have been affected after intravenous injection,<sup>2,3,5</sup> inhalation,<sup>1</sup> and ingestion. Multifocal myocardial fibrosis in the apex of the heart is believed to result from a progressive reduction in luminal patency in numerous small arteries. With more extensive arterial involvement the foci of disseminated microfibrils would fuse into a circumferential subendocardial continuum. Obviously, variations in the response of SMCs along the length of a coronary artery or in segments of its circumference in any given area can not be attributed to the toxicity of the chemical alone. The observed variability in response of SMCs in the same coronary artery suggests that other factors in addition to chemical toxicity must be exerting a deleterious influence on these cells. An inability to substantially alter the systolic pressure following the infusion of allylamine into dogs would tend to exclude variations in arterial tension.<sup>1</sup> Other factors probably exist in coronary arteries that might exaggerate and enhance the toxicity of allylamine. In the pathogenesis of allylamine-induced cellular alterations in the coronary arteries, contributory factors such as torsion of the arterial wall,<sup>26</sup> focal variations in hemodynamic turbulence<sup>27</sup> and increased irritability of edematous SMCs have to be evaluated.

## References

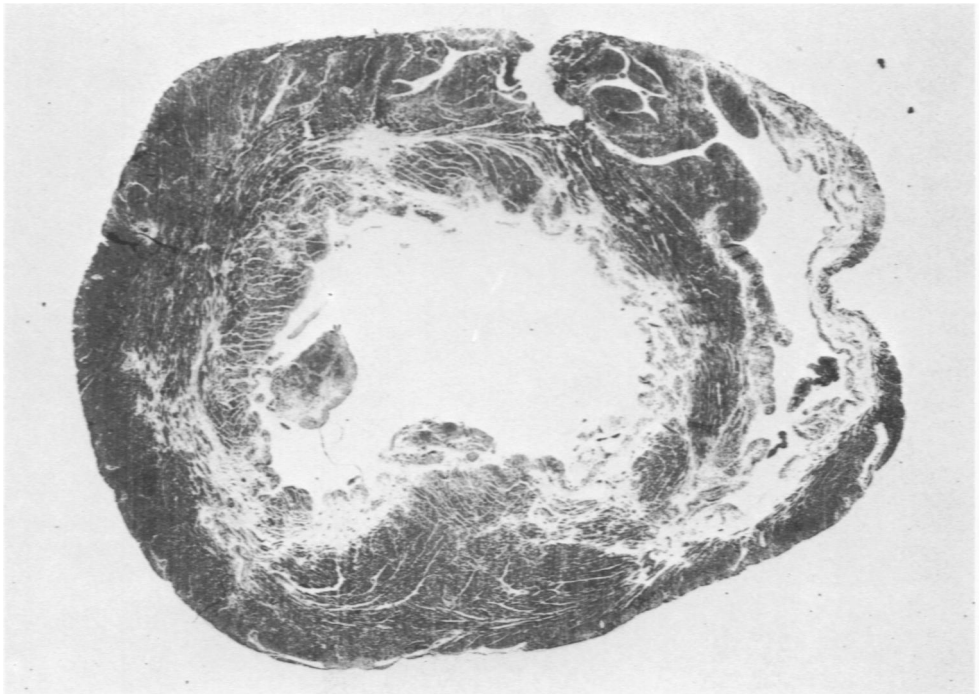
1. Guzman RJ, Loguvm GS, Kodama JK, Hine CH: Myocarditis produced by allylamines. *Arch Environ Health* 2:62-73, 1961
2. Waters LL: Changes in the coronary arteries of the dog following injections of allylamine. *Am Heart J* 35:212-220, 1948
3. Waters LL: Studies on the pathogenesis of vascular disease: the effect of intravenously injected human plasma and lipid rich human plasma globulins on inflammatory lesions in the coronary arteries of dogs. *Yale J Biol Med* 30: 57-71, 1957
4. Conrad LL, Gonzalez IE, Joel W, Furman RH: Histochemical evaluation of canine coronary artery and aortic lesions induced by intravenous allylamine. *Circ Res* 4:263-267, 1956
5. Bloor CM, Lowman RM: Experimental coronary arteriography: the distribution and extent of allylamine-induced vascular lesions in the dog. *Radiology* 81:770-777, 1963
6. Horst A, Rozyrkowa D, Zagorska I: Changes in the aorta of the rat after injection of allylamines and egg yolk. *Acta Med Pol* 1:1-9, 1960
7. Constantinides P, Robinson M: II. Effects of vasoactive amines. *Arch Pathol* 88:106-112, 1969
8. Lalach JJ: Coronary artery hyalinosis in rats fed allylamine. *Exp Mol Pathol* 5:14-26, 1969



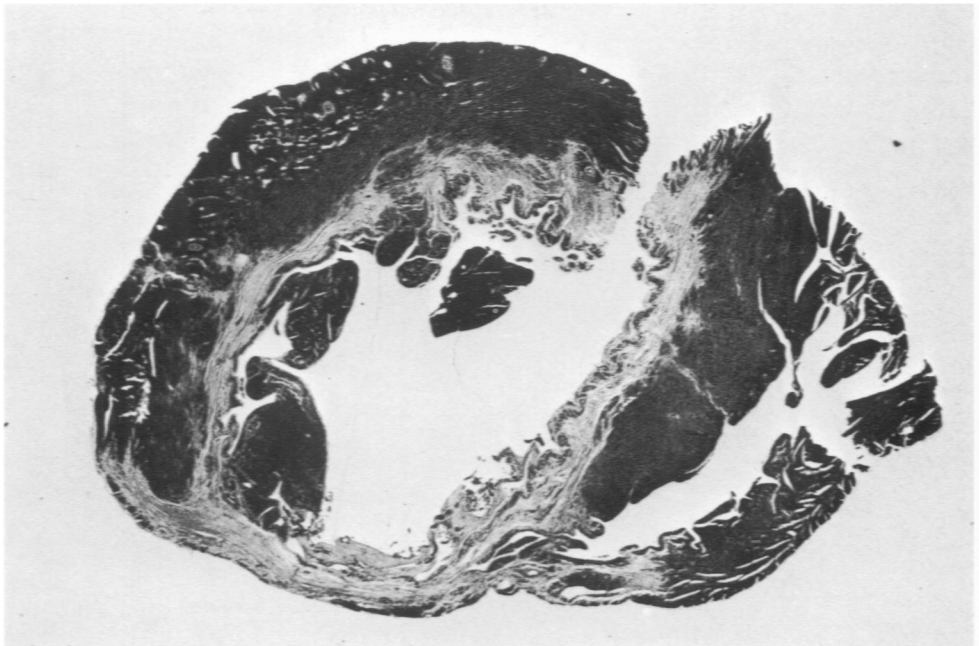
9. Gomori G: A rapid one-step trichrome stain. *Am J Clin Pathol* 20:661-664, 1950
10. Carstairs KC: The identification of platelets and platelet antigens in histological sections. *J Pathol Bacteriol* 90:225-231, 1965
11. Sabatini DD, Bensch K, Barnett RJ: Cytochemistry and electron microscopy: the preservation of cellular ultrastructure and enzymatic activity of aldehyde fixation. *J Cell Biol* 17:19-58, 1963
12. Caulfield JB: Effects of varying the vehicle for O<sub>2</sub>O<sub>2</sub> in tissue fixation. *J Biophys Biochem Cytol* 3:827-830, 1957
13. Mollenhauer HH: Plastic embedding mixture for use in electron microscopy. *J Stain Technol* 39:111-114, 1964
14. Selye H, Gabbini G: The role of electrolytes in the pathogenesis of experimental cardiopathies without vascular involvement, *Electrolytes and Cardiovascular Diseases*. Edited by E Bajusz. Basel, S Karger, 1965, pp 135-160
15. Bajusz E: The terminal electrolyte-shift mechanism in heart muscle, its significance in the pathogenesis and prevention of necrotizing cardiomyopathies.<sup>14</sup> pp 274-322
16. Heggveit HA, Grice HC, Wiberg GS: Cobalt cardiomyopathy: experimental basis for human lesion. *Pathol Microbiol* 35:110-113, 1970
17. Hartroft WS, Thomas WA: Pathological lesions related to disturbances of fat and cholesterol metabolism in man. *JAMA* 164:1899-1905, 1957
18. Wilgram GF: Experimental atherosclerosis and cardiac infarcts in rats. *J Exp Med* 6:293-309, 1959
19. Taylor CB, Cox GE, Manalo-Estrella P, Southworth J, Patton DE, Cathcart C: Atherosclerosis in rhesus monkeys: II. Arterial lesions associated with hypercholesteremia induced by dietary fat and cholesterol. *Arch Pathol* 74:16-34, 1962
20. Wissler RW, Eilert ML, Schroeder MA, Cohen L: Production of lipomatous and atheromatous arterial lesions in albino rat. *Arch Pathol* 57:333-351, 1954
21. Paik WCW, Lalich JJ: Factors which contribute to aortic fibrous repair in rats fed  $\beta$ -aminopropionitrile. *Lab Invest* 22:28-35, 1970
22. Hort W, Da Canalis S: Untersuchungen an Rattenherzen nach temporärer Unterbindung der linken Kranzarterie. *Virchows Arch [Pathol Anat]* 339:61-71, 1965
23. Ring PA: Myocardial regeneration in experimental ischaemic lesions of the heart. *J Pathol Bacteriol* 62:21-27, 1950
24. Halpern MH: The dual blood supply of the rat heart. *Am J Anat* 101:1-16, 1957
25. Dbalý J, Oštádal B, Rychter Z: Development of coronary arteries in rat embryos. *Acta Anat* 71:209-222, 1968
26. Boucek RJ: Regional coronary artery motion and vascular fibrosis, *Biological Aspects of Occlusive Vascular Disease*. Edited by DG Chalmers, GA Gresham. Cambridge, Cambridge University Press, 1964, pp 136-155
27. Texon M: The role of vascular dynamics in the development of atherosclerosis, *Atherosclerosis and Its Origin*. Edited by M Sandler, GH Bourne. New York, Academic Press Inc, 1963, pp 167-195

**Fig 1**—Rat 235, fed allylamine for 180 days and then Lab-Blox pellets for 100 days and sacrificed. At necropsy, infarcts were found in both ventricles along with marked hypertrophy of the left auricle. The heart to body weight ratio was 0.48. The photograph illustrates a transverse segment through the distal half of the heart, which was embedded in paraffin and stained with trichrome. White areas of circumferential sub-endocardial fibrosis are apparent in both ventricles. Along the lateral and posterior aspects of the left ventricle, the myocardial fibrosis is interrupted ( $\times 8.1$ ).

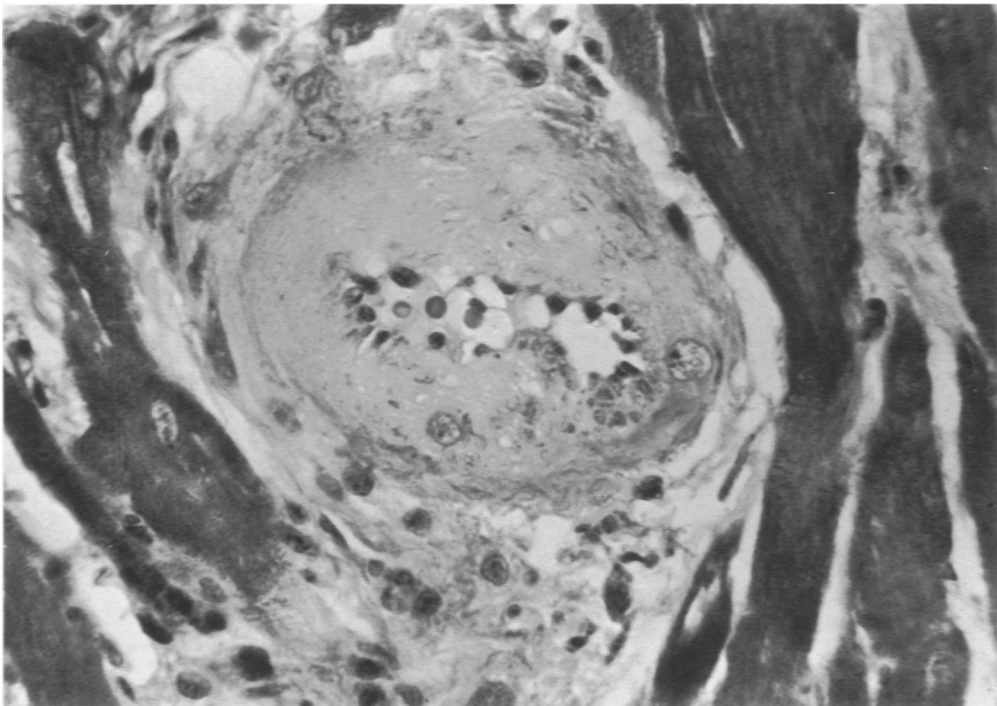
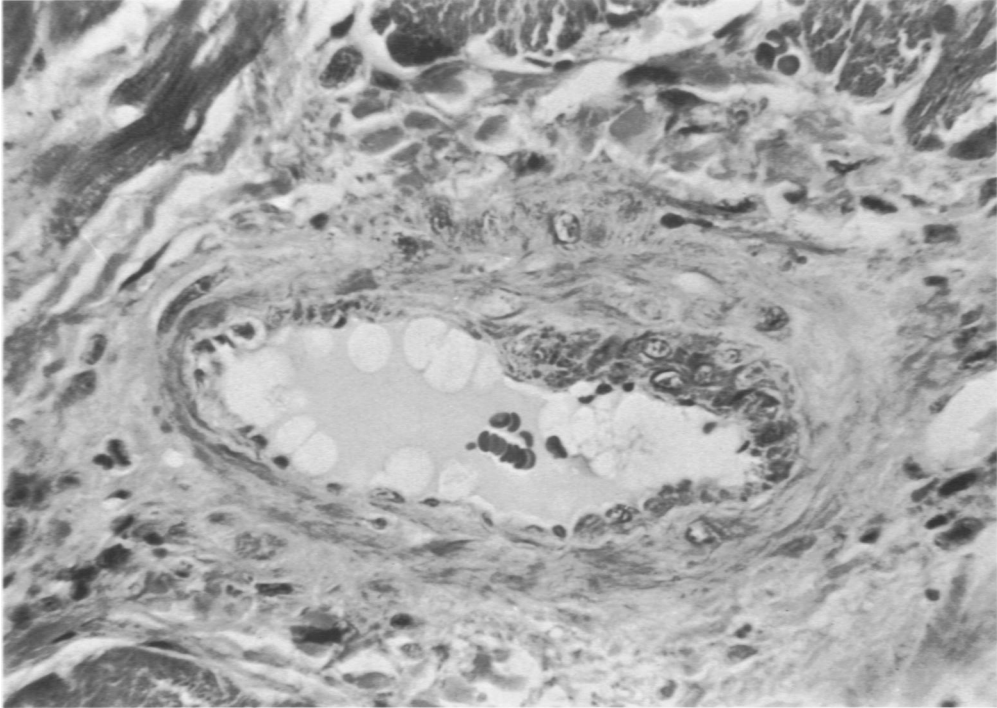
**Fig 2**—Rat 236, fed allylamine for 180 days and pellets for 100 days before sacrifice. An  $8 \times 10$  mm white infarct was observed at the posterior tip of the left ventricle. The heart to body weight ratio was 0.35 in this animal. The segment of heart was processed as in Fig. 1. There is a dense circumferential subendocardial band of fibrosis in the left ventricle. Only minimal fibrosis in the posterior right ventricle adjacent to the septum is evident ( $\times 8.1$ ).



1

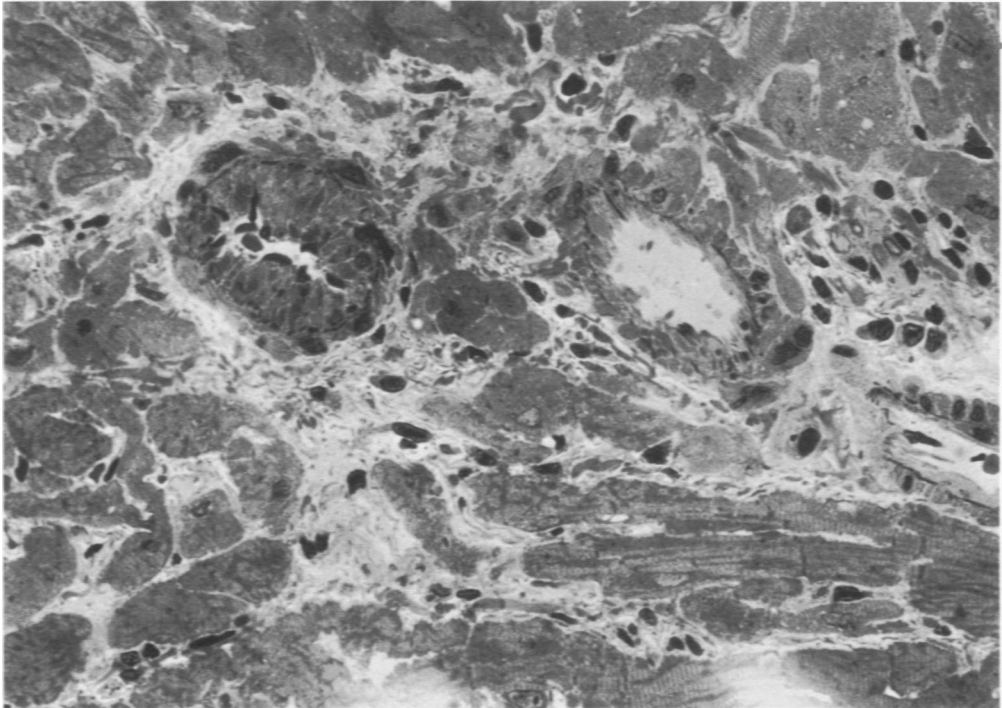


2

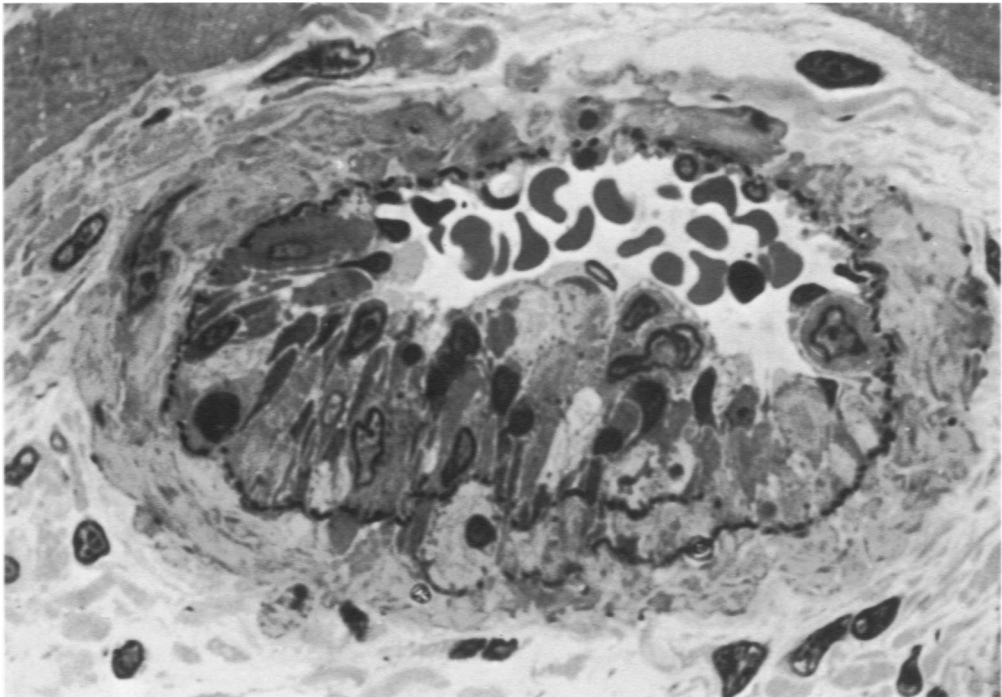


**Fig 3**—Rat 233, fed allylamine for 180 days and pellets for 101 days. The photograph illustrates an artery of intermediate size in which the intimal hyperplasia is limited to one side. The media in this artery is viable and adventitial fibrous proliferation is absent (Paraffin-embedded section stained with trichrome,  $\times 560$ ). **Fig 4**—Rat 234, fed allylamine for 180 days and pellets for 100 days. The photograph illustrates an absence of SMC nuclei in the media due to necrosis in an intermediate-sized artery. In arteries with medial hyalinosis of this magnitude, intimal hyperplasia was minimal or absent, whereas adventitial fibrous proliferation was abundant (Paraffin-embedded tissue stained with trichrome,  $\times 560$ ).

Epoxy-embedded tissues were cut at  $1\ \mu$  and stained with toluidine blue for light microscopy in Fig 5–8. Selected arteries were later processed for electron microscopy.

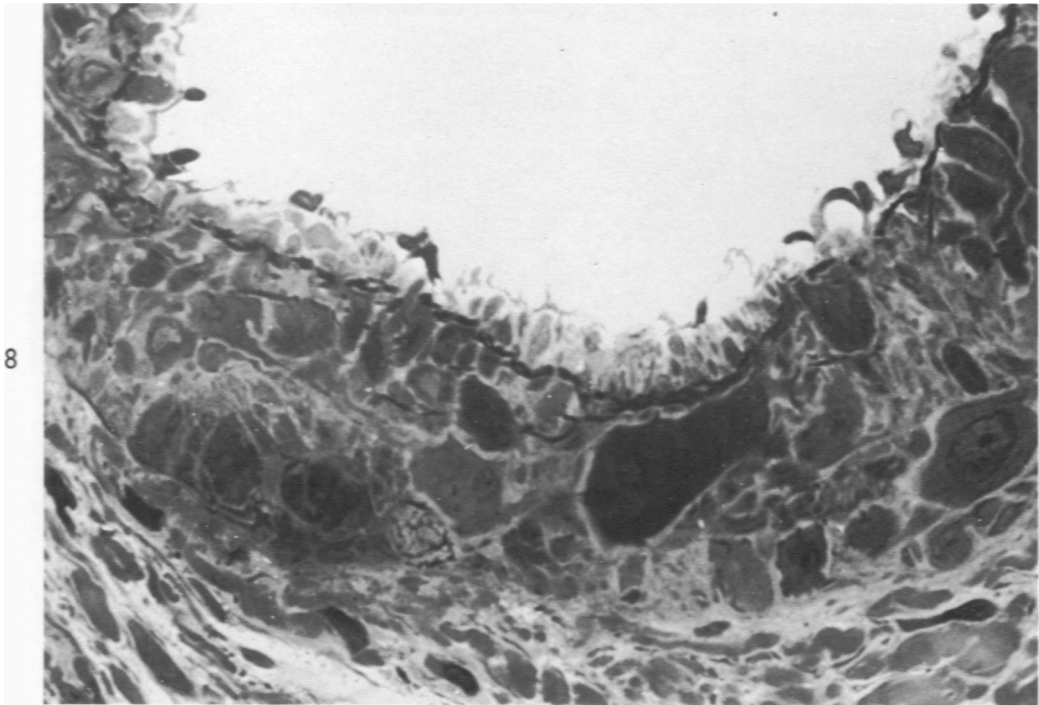
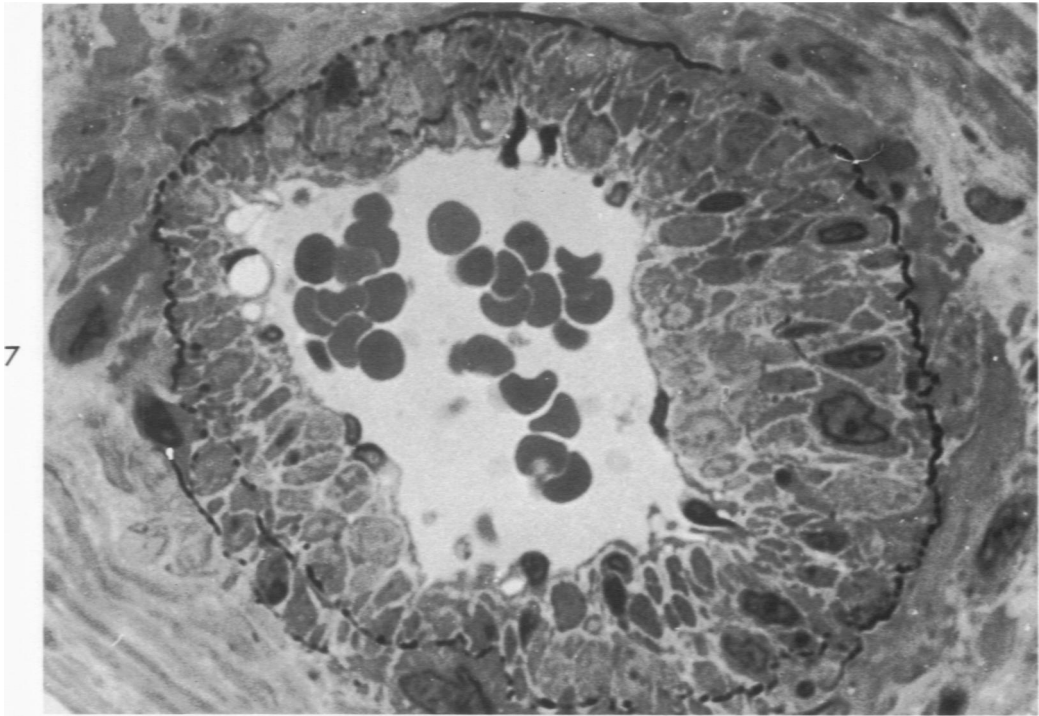


5

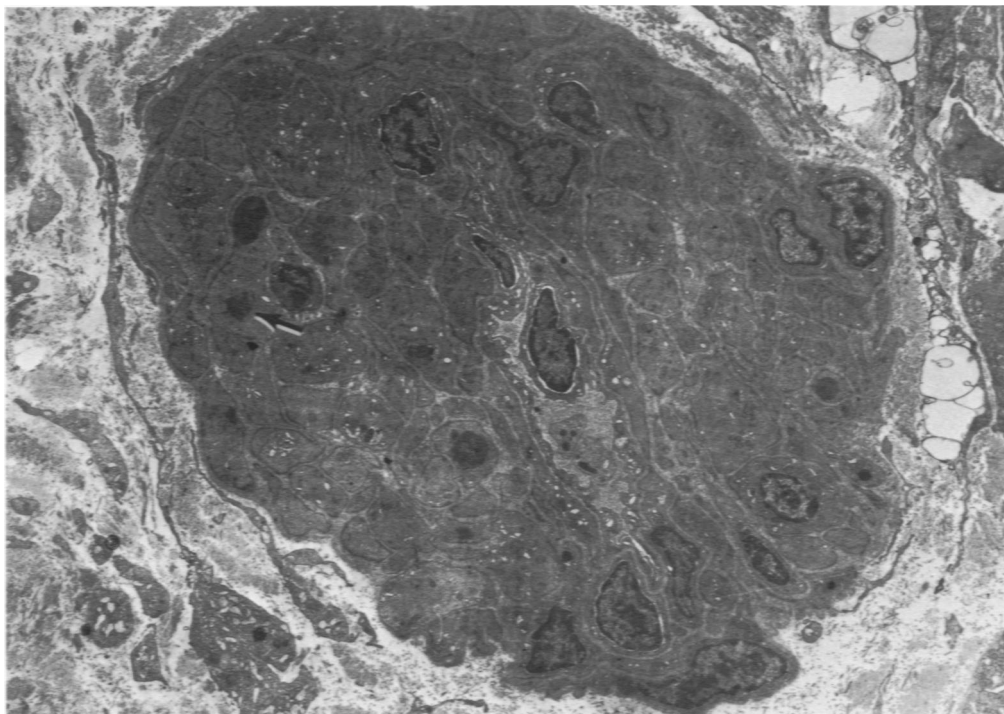


6

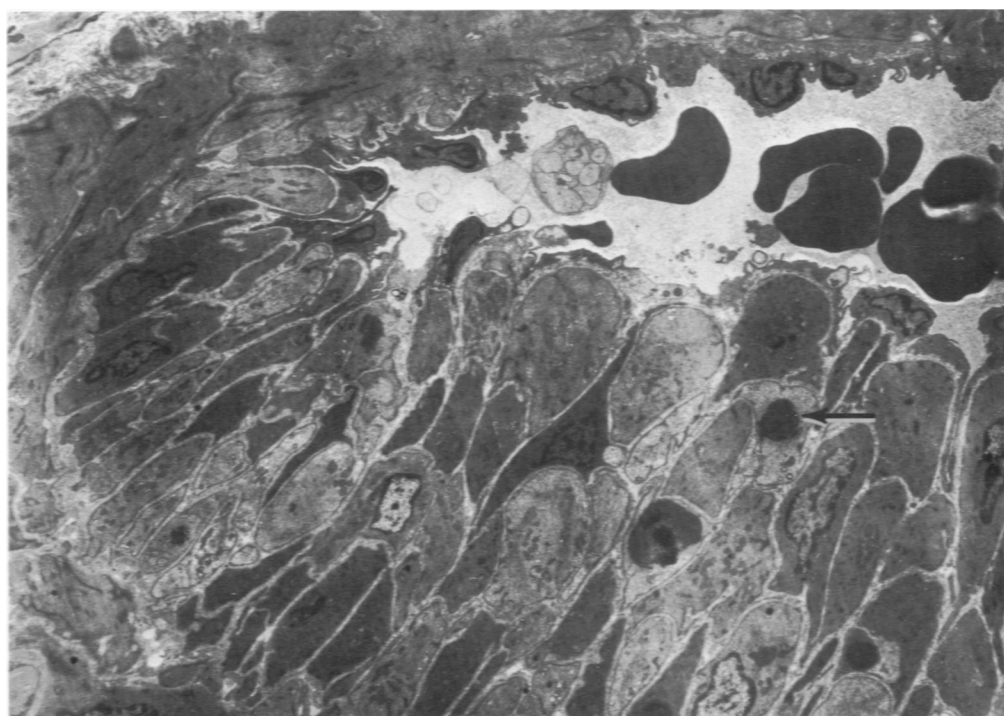
**Fig 5**—Rat 42, fed allylamine for 233 days. These two closely associated myocardial arterioles illustrate that allylamine may affect one vessel whereas the other appears to be unaffected. There is extensive muscular hyperplasia in the intima and a repositioning of the internal elastic lamina in the vessel on the left. The other vessel appears normal (toluidine blue stain,  $\times 450$ ). **Fig 6**—Rat 41, fed allylamine for 235 days. Extensive sub-endothelial muscular hyperplasia involves approximately one-half the circumference in this intermediate-sized artery. Variation in the size and staining affinity of the intimal muscle cells is believed to be caused by the ingestion of allylamine. No appreciable changes are present in the medial and adventitial portion of this vessel (toluidine blue stain,  $\times 1650$ ).



**Fig 7**—Section taken from same heart as that shown in Fig 5. Extensive subendothelial muscular hyperplasia involves the entire circumference of the vessel. These hyperplastic muscle cells show considerable variation in their size. The magnitude of intimal hyperplasia is particularly apparent when the distance between the endothelium and internal elastic lamina is evaluated. Several endothelial cells with cytoplasmic vacuoles can be seen (toluidine blue stain,  $\times 1650$ ). **Fig 8**—Rat 40, fed allylamine for 235 days. Within the media of this large-caliber artery, dark and lucent SMCs are apparent. The variability in size suggests that muscular hypertrophy and hyperplasia occur in the media as well as the subendothelial portion of the vessel wall. The intima is normal except for cytoplasmic vacuolization of some endothelial cells (toluidine blue stain,  $\times 1800$ ).

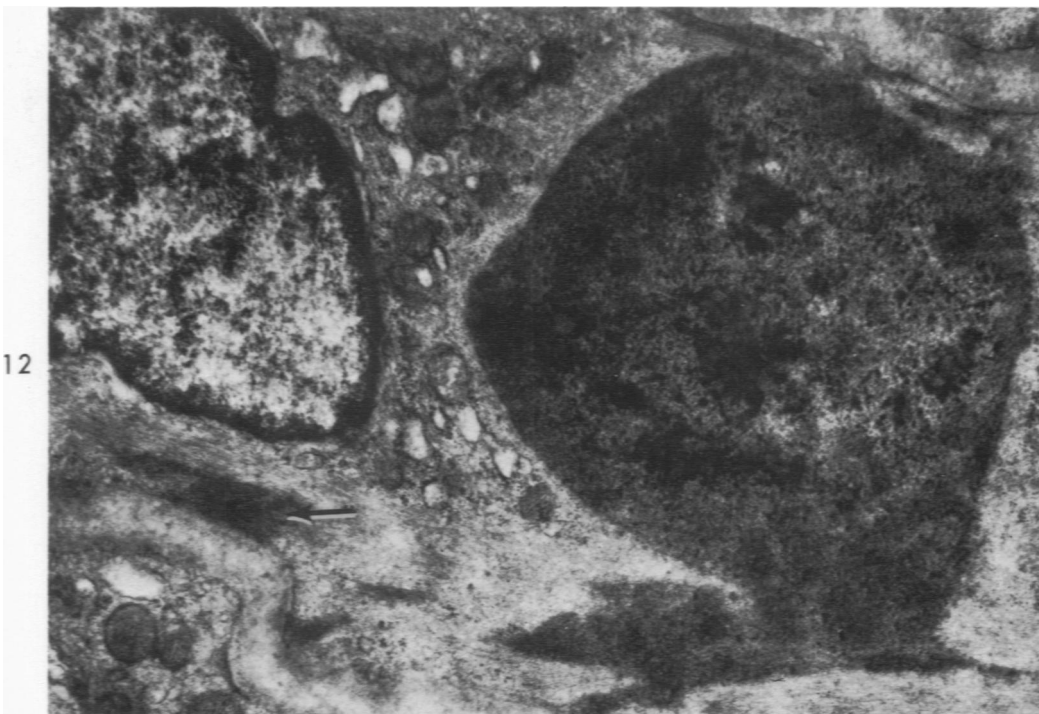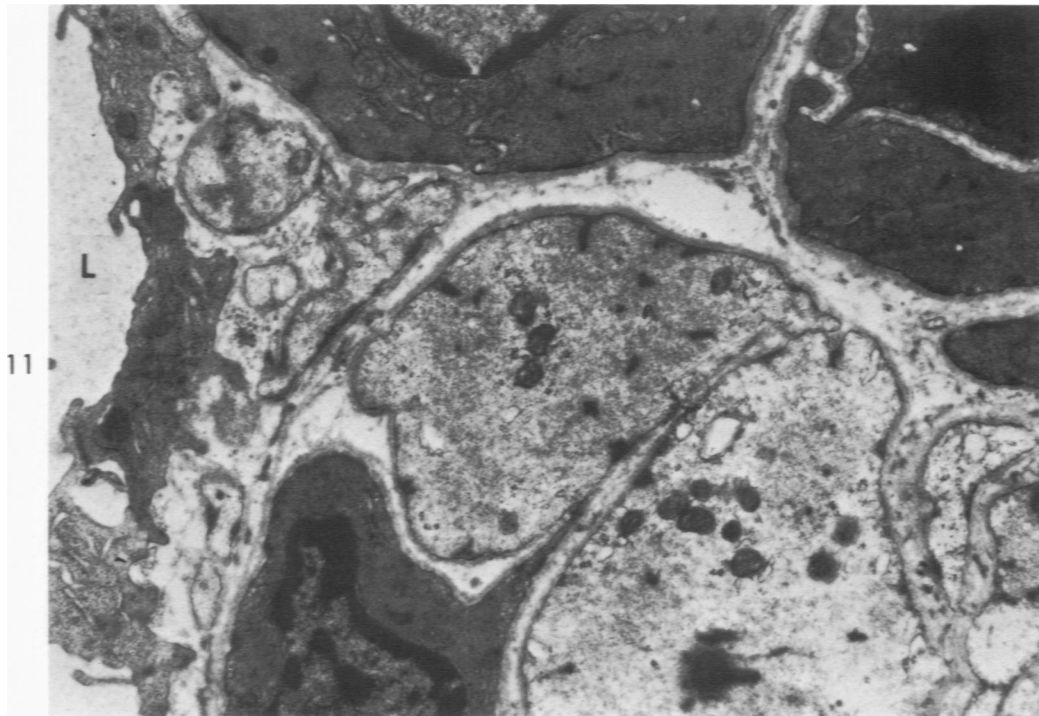


9



10

**Fig 9**—Artery of rat shown in Fig 6. Extensive cellular proliferation in the intima has occurred in this myocardial arteriole. Variation in the size and contour of the individual SMCs is evident. Widely distributed electron-dense cytosomes (*arrow*) and lucent vesicular segments of the endoplasmic reticulum are obvious in the muscle cells (uranyl acetate stain,  $\times 2095$ ). **Fig 10**—Artery of rat shown in Fig 5. Extensive subendothelial muscular hyperplasia has occurred in over half the circumference of this small artery. Appreciable variation in cell size and density is apparent. Large electron-dense cytosomes (*arrow*) are also apparent within the cytoplasm of many of the muscle cells. Positional modification of the internal elastic lamina is apparent in the areas of hyperplasia (uranyl acetate stain,  $\times 2420$ ).



**Fig 11**—Artery of rat illustrated in Fig 5. The variation in lucency of the hyperplastic muscular components is depicted. This difference in lucency is primarily associated with the variation in number of myofilaments that are present. Well-developed mitochondria and segments of endothelial cells are located on the luminal surface (L) (uranyl acetate stain,  $\times 18,640$ ). **Fig 12**—Artery of rat shown in Fig 6. This large electron-dense aggregate, similar to those depicted in Fig 9 and 10, is composed primarily of closely packed, variably sized granules that appear to be continuous with the more electron-dense areas of the myofilament (*arrow*). However, other morphologic features of this cell appear normal (uranyl acetate stain,  $\times 25,500$ ).