

BRITISH MEDICAL JOURNAL

LONDON SATURDAY SEPTEMBER 16 1950

CONGENITAL HEART DISEASE*

A REVIEW OF ITS CLINICAL ASPECTS IN THE LIGHT OF EXPERIENCE GAINED
BY MEANS OF MODERN TECHNIQUES

BY

PAUL WOOD, O.B.E., M.D., F.R.C.P.

Director of the Institute of Cardiology (National Heart Hospital); Physician in Charge of the Cardiac Department, Brompton Hospital

[WITH SPECIAL PLATE]

PART I

In the past the chief contributions to the better understanding of congenital heart disease have been based on necropsy studies, particularly those by Peacock (1866), Keith (1909), and Maud Abbott (1928). More recently, Brown (1939) and Helen Taussig (1947) have presented us with important monographs from a more practical angle, but even these have depended on the correlation of clinical and post-mortem findings. In some respects all these works have necessarily been influenced by the selected nature of the material, and have tended to create a number of false impressions. For example, of Abbott's 1,000 cases there were 37 with three-chambered hearts, 81 with partial or complete transposition of the great vessels, 40 with pulmonary atresia, 21 with persistent truncus, and 16 with tricuspid atresia (total 195); against 33 with atrial septal defect (A.S.D.), 55 with uncomplicated ventricular septal defects (V.S.D.), 105 with uncomplicated patent ductus, 9 with simple pulmonary stenosis, and about 71 with Fallot's tetralogy (total 273), giving a ratio of the rare to the common types of 2:3. Again, in 1947 Helen Taussig stated that she had never had an opportunity of studying a single case of pure pulmonary stenosis. The suggestion that V.S.D. accounts for 35-40% of all congenital hearts seen in school-children (Perry, 1931; Muir and Brown, 1934) is also unacceptable.

In recent years, modern techniques have made it possible to prove the precise nature and physiological effects of 90% of all congenital cardiac anomalies during life. In the light of this rapidly acquired knowledge of dynamic processes, many physical signs have acquired a new significance and their proper interpretation has so greatly improved bedside diagnosis that the special investigations responsible for their discovery have already become superfluous in many cases. The time is ripe, therefore, for a review of the whole subject of congenital heart disease from a more functional standpoint, to present a fresh account of these physical signs, to offer a more practical and physiological classification of the common or well-recognized anomalies, and incidentally to give a truer picture of their clinical incidence. By implication, stillborn infants and those dying shortly after birth have been excluded from the study.

Material.—Observations are based on 233 cases of supposed congenital heart disease examined personally by me during the last two and a half years at the National Heart Hospital, Hammersmith and Brompton Hospitals, in private practice, and at the Rheumatic Fever Centre, Taplow. Of these, 152 were catheterized, and in 42 angiocardiograms were taken. Further confirmation of the diagnosis was obtained at operation in 44 cases and at necropsy in 20.

Techniques

1. Cardiac Catheterization

American nylon catheters and saline manometers were used throughout, as described by McMichael and Sharpey-Schafer (1944). Mean pressures are expressed in millimetres of mercury above the sternal angle with the patient horizontal. Blood gas analysis was carried out by trained technicians using Haldane's or van Slyke's apparatus. The catheter was inserted into a median antecubital vein in all cases but one, in which the external jugular had to be used. Failure to enter the superior vena cava was always due to inexperience and could usually be overcome by asking the patient to breathe deeply or by causing an anaesthetized patient to cough or gasp; changing the position of the head, arm, or body was usually a waste of time. Occasionally it was necessary to change the catheter or to use the other arm. The services of an anaesthetist are required for children under 7 or 8 years old. Dr. B. G. Lucas, at the Heart Hospital, has usually given rectal thiopentone with intravenous supplements.

Venospasm is a reflection on the skill of the operator, and never occurs if the skin is properly anaesthetized, if all traces of disinfectant are washed off the catheter before use, and if the catheter is not too large for the vein. It has caused no embarrassment in the last 100 cases.

Air embolism is avoided by keeping the hilt of the catheter below right auricular level when sampling. It has not occurred in this series.

Thrombo-embolism, paradoxical or pulmonary, is avoided by giving 50 mg. of heparin to the patient, by adding a smaller quantity to the saline reservoir, and by taking care to keep blood out of the catheter, especially when entering a high-pressure chamber and after sampling. It has not been encountered in this series.

*St. Cyres Lecture delivered on June 13 at the Royal Society of Medicine under the auspices of the National Heart Hospital.

Rigors are due to pyrogens in a previously used catheter. They do not occur if catheters are thoroughly washed out and subsequently cleaned by running hydrogen peroxide through the lumen until bubbles cease.

Ventricular fibrillation developed in two patients, and proved fatal in one of them (a severe case of atrial septal defect with gross cardiac enlargement and congestive heart failure). Since then all cases have received quinidine (5–10 gr.—0.32–0.65 g.) half an hour beforehand.

Subsequent infection, such as thrombophlebitis, pulmonary or cerebral abscess, septicaemia, and bacterial endocarditis, should not occur with aseptic technique, but all our cases have been given penicillin for 48 hours after the procedure, as a precaution. No such infection has yet arisen.

X-ray overdosage has been avoided by limiting the screening time to 30 minutes at 1 mA, 20 minutes at 2 mA, and 15 minutes at 3 mA. The operator wears a lead apron and does not regularly perform more than two catheterizations a week.

Failures.—Of 152 cases of suspected congenital heart disease an attempt was made to catheterize the pulmonary artery in 129, and was successful in 110 (85%). This figure includes failures due to inability to enter the right ventricle. The latter was entered in 135 out of 146 attempts (92%). There was only one failure to catheterize the right auricle in the 152 cases. Many of the failures occurred in difficult cyanosed cases, including six with tricuspid atresia and at least one with pulmonary atresia. In acyanotic cases, including simple pulmonary stenosis, the right ventricle was catheterized in 98%, and the pulmonary artery in 91%. In Fallot's tetralogy the pulmonary artery was entered in 15 out of 21 cases. The high incidence of successful catheterization is attributed to the development of what we have called "the coil technique." Instead of attempting to pass the catheter direct into the right ventricle, its tip is first rotated outwards against the lateral wall of the right auricle; a half-loop is easily formed in this situation, and when this is rotated medially the upwardly directed tip passes straight towards the pulmonary artery after slipping through the tricuspid valve.

2. Angiocardiography

I am indebted to Dr. Maurice McGregor, of Johannesburg, for personally constructing the angiocardiograph now used at the Brompton Hospital, and for helping to develop the technique. Copies or slightly modified copies of his model are used at the Hammersmith and the Heart Hospitals. Angiocardiograms have been carried out mostly by the cardiological registrars at these hospitals, particularly by Dr. J. B. Lowe at Brompton and at the Heart Hospital, and by Dr. E. Petrie at Hammersmith. Technical details have been described elsewhere. There were no fatalities.

Incidence

The series was closed at the 233rd case, for by then the nature of the congenital anomaly was virtually certain in 200. Of the residue, 13 proved to have normal hearts, 4 had rheumatic aortic and/or mitral valve disease, 6 had idiopathic pulmonary hypertension, and 10 eluded analysis.

The incidence of the various forms of congenital heart disease encountered is given in Table I. It is believed that weighting in favour of those lesions amenable to surgical repair is slight, because the clinics at which most of the cases were seen did not have a surgical flavour or unduly close surgical link. It is concluded that the commonest forms of congenital heart disease are Fallot's tetralogy

(18%) and atrial septal defect (17%); followed closely by patent ductus (14.5%), ventricular septal defect (12%), and simple pulmonary stenosis (11.5%); whilst coarctation of the aorta comes next (8%). Together these six conditions accounted for 81% of the total.

TABLE I.—Incidence of Chief Anomalies

Total No. of cases investigated	233	
Rheumatic A.S.; M.I.; or A.I.+M.S.	4	
Proved normal	13	
Primary pulmonary hypertension	6	
Nature still obscure	10	
True congenital heart disease	200	
Acyanotic		No. %
Coarctation of the aorta	16	8
Aortic or subaortic stenosis	6	3
Simple pulmonary stenosis (4 with V.S.D.)	23	11.5
Atrial septal defect	35	17.5
Ventricular septal defect (excluding 4 with pulmonary stenosis)	24	12
Patent ductus arteriosus	29	14.5
Cyanotic		
Fallot's tetralogy (including 3 with pulmonary atresia)	36	18
Pulmonary stenosis with reversed interatrial shunt	5	2.5
Tricuspid atresia	6	3
Eisenmenger's complex	2	1
Transposition of the great vessels	2	1
Others	16	8
Total	200	100

Clinical Features

In attempting to make a bedside diagnosis of the precise nature of any case of suspected congenital heart disease, due consideration should be given to 10 major items, all of which have multiple facets.

1. Other Congenital Stigmata

Mongolism and arachnodactyly are well-recognized associations, but in their complete form are uncommon. Partial arachnodactyly, especially high arched palate and pigeon chest, however, is common. Brown also stresses accessory nipples. When the diagnosis rests between normality, congenital heart disease, or acquired heart disease, any such stigmata favour a congenital anomaly.

2. Effort Intolerance

Breathlessness may be divided into four grades: (1) slight—the patient attempts to compete with his fellows, but is always at a disadvantage; (ii) moderate—he is obviously breathless on effort, but can walk several miles; (iii) severe—he can walk only several hundred yards, certainly not more than a mile; and (iv) gross—incapacitated and cannot walk 100 yards.

Squatting (Taussig, 1947) should always be noted. It is especially common in Fallot's tetralogy, but not limited to it. It occurred in practically every cyanotic form of congenital heart disease in this series, but whereas it was recorded in two-thirds of those with Fallot's tetralogy, it was mentioned in only one-quarter of the others. It was noted only once in an acyanotic case (severe pulmonary stenosis).

Angina pectoris and syncope were rare, but occurred occasionally in severe pulmonary stenosis with or without reversed interatrial shunt. Angina occurred in three of the six cases with idiopathic pulmonary hypertension, and syncope in one of them.

Palpitations had a nuisance value in several severe cases of patent ductus, and in a few advanced cases of atrial or ventricular septal defect.

3. Cyanosis

It is usual to grade the intensity of cyanosis and clubbing so that some idea of their degree may be recorded. Central cyanosis is best seen on warm surfaces such as the conjunctivae, the inner side of the lips, the palate, and the tongue. Peripheral cyanosis may occur on exposed surfaces which may be cold, such as the nose, ears, face, outer side of the lips, and hands. The distinction is very important. Clubbing always means central cyanosis when other causes can be excluded.

Polycythaemia is also recorded under this heading, and usually implies central cyanosis; but it sometimes helps to compensate for an extremely low cardiac output.

Central cyanosis in congenital heart disease means a veno-arterial shunt. It may occur, however, in the late stages of primary pulmonary hypertension, and of course in anoxic cor pulmonale.

4. Pulse

A small pulse is characteristic of all the severe cyanotic and severe acyanotic forms of congenital heart disease except patent ductus, aorto-pulmonary septal defect, and perforated aortic sinus, when it is water-hammer in quality. It is normal in mild cases in both groups. In the absence of aortic incompetence Corrigan's sign provides valuable evidence in favour of patent ductus or its near relatives. Both water-hammer pulse and Corrigan's sign were present in 18 out of 22 such cases in which they were looked for.

Hypertension is limited to coarctation of the aorta, and then, of course, it can be detected only in the upper extremities. The blood pressure was normal in all other conditions except the ductus group, although the pulse pressure was small in the most severe cases. In the ductus group the diastolic pressure was significantly reduced in the majority.

5. Jugular Venous Pressure

The general level of the jugular venous pressure was usually normal, excluding cases of heart failure; but it tended to be within the upper limits of normal or even slightly raised in the group with arteriovenous shunt and in cases of simple pulmonary stenosis or idiopathic pulmonary hypertension. It was slightly raised in 4 out of 28 cases of Fallot's tetralogy.

Giant *a* waves were conspicuous in the neck in the most severe cases of simple pulmonary stenosis with or without reversed interatrial shunt. These were easily recognized and distinguished from the well-known venous pulse of tricuspid incompetence by their presystolic timing, by their abrupt and collapsing quality (venous Corrigan), and by the fact that they represented a pressure far above that of the *c* and *v* waves. In two cases they were transmitted to the liver. Giant *a* waves may also be seen in acquired tricuspid stenosis and severe primary or secondary pulmonary hypertension, but rarely in other conditions. They resemble in quality, but not in timing, the cannon waves of heart-block. They are not seen in uncomplicated A.S.D., V.S.D., patent ductus, aortic stenosis, or mitral incompetence.

6. Pulsation

The quality of the cardiac impulse is very important. It may be described as normal (gentle left ventricular thrust), heaving (from a hypertrophied left ventricle), hyperdynamic (a quick tumultuous thrust), or tapping. It is believed that the tapping cardiac impulse represents absence of pulsation at the apex beat associated with an easily palpable first heart sound. This may result from clockwise rotation or from enlargement of the right ventricle, usually both. It is characteristic of A.S.D., Fallot's tetralogy, and severe pulmonary stenosis. A hyperdynamic left ventricular thrust is characteristic of patent ductus and V.S.D. Occasionally a tumultuous cardiac impulse is due to a grossly hyperkinetic right ventricle in A.S.D. (Roessler, 1934).

When the left ventricle is enlarged the normal precordial systolic retraction tends to be exaggerated. When the right ventricle is enlarged there is a diffuse lift in the third and fourth spaces between the sternum and the nipple line. This lifting outflow tract or conus is very rarely recorded in hospital notes, yet it is highly important, and is probably the best clinical evidence available of an enlarged right ventricle.

Systolic pulsation in the second left space offers good evidence of a dilated pulmonary artery, and is a most helpful and reliable physical sign. It was recorded positively in 7 out of 25 cases of A.S.D. in this series, but negatively only twice, and was never seen in any form of pulmonary stenosis. Occasionally, however, it may be due to a large aorta, as in pulmonary atresia, or to a persistent truncus.

7. Murmurs and Thrills

The significance of the site, intensity, and conduction of most murmurs and thrills is well recognized and needs little comment. But more attention should be paid to functional murmurs; par-

ticularly to the Graham Steell murmur of pulmonary incompetence, which was heard in 13 out of 25 cases of A.S.D. in this series, and which always indicates a dilated pulmonary artery; and to the mitral diastolic murmur that denotes a torrential mitral blood flow—this was heard in 16 out of 18 cases with either a large patent ductus or a large V.S.D. There can be no doubt that it is functional, for it disappears immediately the ductus is ligated. Phonocardiograms show that it follows the third heart sound at the mitral area and is indistinguishable in timing, quality, intensity, and duration from the mitral diastolic murmur associated with mitral valvulitis.

8. Second Heart Sound

It is nearly always possible to distinguish two components of the second heart sound in normal children and in most healthy adults who are neither emphysematous nor over weight, particularly during inspiration. In other words, the second heart sound is normally split. The first component represents aortic valve closure, the second pulmonary valve closure. The second heart sound is usually single in the neck, at the aortic area, and at the cardiac apex—at these sites only the aortic element is normally heard. At the pulmonary area both elements are heard, and the loudest is usually the aortic. Phonocardiograms taken by Dr. Aubrey Leatham confirm the clinical view that the pulmonary valve normally closes after the aortic. The significance of this fact will not be overlooked, for it offers a bedside method of detecting pulmonary hypertension, pulmonary hypotension, and right bundle-branch block (or its functional equivalent).

Thus in primary or secondary pulmonary hypertension the second element of a normally split second heart sound is usually obviously accentuated; in Fallot's tetralogy the second sound at the pulmonary area is always single and usually loud—it is the aortic sound that is heard and the vessel is not covered by the pulmonary artery; in severe simple pulmonary stenosis the pulmonary element is also absent, but may be present in mild cases; in A.S.D. with functional right branch block or its electrocardiographic equivalent, and a grossly overfilled right ventricle, the second heart sound is widely split and the second or pulmonary element is but little accentuated. No sign will repay closer study than the second heart sound at the pulmonary area. It is believed that Helen Taussig (1947) was the first to point out the value of hearing a split second sound, stating that it offered clear evidence of the existence of both great vessels.

9. The Electrocardiogram

The important findings in congenital heart disease include the P pulmonale, evidence of left or right ventricular preponderance, and appearances resembling partial or complete right bundle-branch block. The P pulmonale is common, and therefore not very helpful, in all cyanosed cases, but in acyanotic cases it usually means pulmonary stenosis or severe pulmonary hypertension. It is never conspicuous in uncomplicated A.S.D., V.S.D., or patent ductus.

The electrocardiogram is the most reliable clinical means of deciding which ventricle is predominant, and the point is of the utmost importance in differential diagnosis. Details cannot be discussed here.

Partial or complete right bundle-branch block occurs in 95% of all cases of A.S.D., the clinical diagnosis of which is almost untenable in its absence.

10. X-ray Appearances

The most valuable recent addition to well-known radiological signs is perhaps the recognition of overfilled or underfilled peripheral pulmonary arteries. Pulmonary plethora (Plate, Fig. 1) occurs in A.S.D., V.S.D., patent ductus, and transposition of the great vessels; pulmonary ischaemia (Fig. 2) in all cyanotic cases with veno-arterial shunt, including Eisenmenger's syndrome. The difference is very obvious and does not necessarily bear any relation to the size of the pulmonary artery itself or to its main left and right branches; thus dilatation of the pulmonary artery itself without pulmonary plethora occurs in pulmonary valve stenosis, pulmonary hypertension, and

Eisenmenger's complex; on the other hand, diminutive main pulmonary arteries occur only when the pulmonary blood flow is reduced.

Another point of great importance is the quality of pulmonary artery pulsation: whether it is abrupt and collapsing as in A.S.D. and pulmonary incompetence, or whether it is relatively slow-rising and sustained as in pulmonary stenosis (Wells, 1950).

Coarctation of the Aorta

Of the 16 cases in the series 8 were male and 8 female. Their ages ranged from 5 to 47. The findings were characteristic, and there is very little to add to the well-known clinical picture.

Patent ductus was associated in one, V.S.D. in two, and aortic stenosis in one (possibly two). The coarctation was of the usual adult type in all of these.

A mitral diastolic murmur was heard in no fewer than 9 of the 16 cases. There was a ready explanation for it in five (ductus, 1; V.S.D., 2; calcific mitral stenosis, 1; and active rheumatic carditis, 1). But there was no explanation for it in the other four; there was no rheumatic history, and the murmur disappeared after surgical repair in one of them. The contrary evidence that an unexplained mitral diastolic murmur may persist after successful surgical repair is still lacking. According to Brown, cases of coarctation of the aorta, like cases of A.S.D., are peculiarly apt to develop rheumatic mitral valvulitis in childhood, and at present there is no better explanation to offer.

A radiological sign that too often escapes notice is the double aortic knuckle (Fig. 3) described by Bramwell (1947) and others. This at once distinguishes coarctation from obstruction lower down.

Retrograde aortography was carried out on three cases, but the results were little better than those obtained by the intravenous route, and the procedure is probably more dangerous. Good aortograms are essential, however, so that cases which are anatomically unsuitable for repair need not be subjected to thoracotomy.

The mortality rate for Crafoord's operation is now 10-16% (Gross, 1949; Shapiro, 1949).

Patent Ductus Arteriosus

There were 29 cases of patent ductus in the series—21 female and 8 male. Only one was seriously incapacitated, but five others had moderate breathlessness and complained of palpitations.

Of the physical signs, Corrigan pulsation in the neck, a water-hammer pulse, a normal venous pressure and pulse, a thrusting hyperdynamic left ventricular cardiac impulse, a high continuous murmur in the first and second left intercostal spaces, a normally split (when not obscured) second heart sound at the base, often with some accentuation of the pulmonary element, and a functional mitral diastolic murmur were the most important. The electrocardiogram showed normal P waves, a varying degree of left ventricular preponderance, and no bundle-branch block. S waves were always dominant in Lead V₁, and a small secondary R wave was seen only once; but the main R wave in this lead was sometimes notched, and S was occasionally slurred. The most severe cases showed T-wave inversion in left ventricular surface leads or their equivalents, and one patient had auricular fibrillation, which reverted to normal rhythm after ligation of the ductus. Skiagrams usually revealed left ventricular enlargement, pulmonary plethora, and a varying degree of dilatation of the pulmonary artery.

The mildest cases showed no abnormality apart from the Gibson murmur. Nine out of ten severe cases had a func-

tional mitral diastolic murmur which disappeared immediately the ductus was ligated. Two patients did not have a continuous murmur at any time, and in two others the murmur was atypical and was thought by some observers to be absent in one of them and discontinuous in the other. The two without the classical murmur were the most severe in the series. Both were proved by cardiac catheterization and subsequent ligation of the ductus. Four acyanotic patients with continuous murmurs did not have a patent ductus. Two had aorto-pulmonary septal defects, and two had a perforation of the aortic sinus—one into the pulmonary artery and one into the right ventricle. Several other continuous murmurs were heard in acyanotic patients during the two-and-a-half-year period under review, but have been excluded from the series. Some represented a venous hum and were louder in the neck. One was due to a needle causing an aorto-pulmonary fistula; another was caused by an arteriovenous aneurysm in the lung. No case of coronary arteriovenous aneurysm was encountered.

The venous hum is accentuated when the patient sits up and may be abolished by compressing the jugular vein at the root of the neck. Continuous murmurs due to aorto-pulmonary septal defects or to a perforated aortic sinus tend to be loudest a little lower than the classic ductus murmur; they are also extremely coarse and accompanied by a gross thrill. Both cases of perforated aortic sinus in this series developed during or after an attack of bacterial endocarditis.

Arteriovenous aneurysm of the lung usually causes cyanosis; if not, it may yet be recognized by means of pulmonary angiocardiology and by finding a lowered arterial oxygen saturation. Coronary arteriovenous aneurysm should show an unusually high oxygen content in samples obtained from the coronary sinus.

Cardiac catheterization was undertaken in 13 cases. Mean pressures in the pulmonary artery were normal in four and raised, often considerably, in nine (Table II).

TABLE II.—Patent Ductus

Case No.	Age	Mean Pressure (mm. Hg)		% O ₂ Saturation		Ratio of Pul. to Systemic Flow	Approx. Pul. Resistance (P.A. Pressure/Pul. Flow.)
		R.V.	P.A.	S.V.C., R.A., and R.V.	P.A.		
1 H	6	18	32	63	83	3:1	2.0
2 H	9	12	17	65	80	2:1	1.7
3 F	18	16	24	53	75	2.5:1	2.0
4 F	8	30	52	68	81	2:1	5.0*
5 F	7	7	7	69	81	2:1	0.7d
6 F	35	19	40	52	85	6.5:1	1.25d
7 F	9	33	48	69	87	3.7:1	2.5
8 F	32	9	13	72	80	1.7:1	1.4
9 F	8	24	37	62	73	1.5:1	5.0*
10 F	23	30	65	69	86	2:1	6.0*
11 F	5	27	47	65	87	3.5:1	2.8
12 F	4	10	13	69	86	2.7:1	1.0 d
13 F	13	8	12	67	83	2.2:1	1.0 d

* Increased resistance. d = Diminished resistance.

There was some relationship between the height of the pressure and the size of the shunt, but it was not close. The peripheral resistance in the lungs was variable: it was reduced in four, normal in six, and raised in three. When it was low a relatively large shunt was associated with a relatively low mean pressure in the pulmonary artery; when it was high a relatively small shunt was associated with a high pressure in the pulmonary artery. Only when the peripheral resistance was normal was the pressure proportional to the shunt (Fig. A). This, of course, is obvious and may be calculated by the formula $B.P. = T.P.R. \times C.O.$, which applied here becomes: pulmonary artery pressure = pulmonary peripheral resistance \times pulmonary blood flow.

PAUL WOOD: CONGENITAL HEART DISEASE. PART I

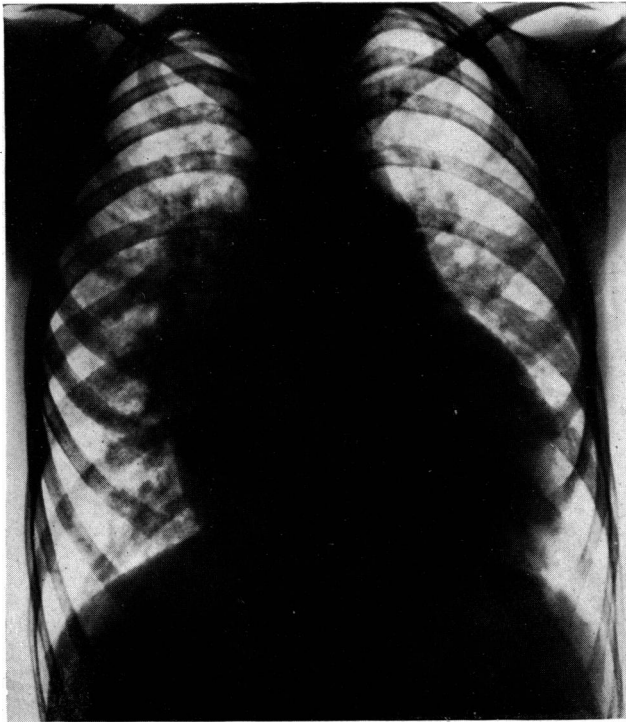


FIG. 1.—Pulmonary plethora in a case of V.S.D.

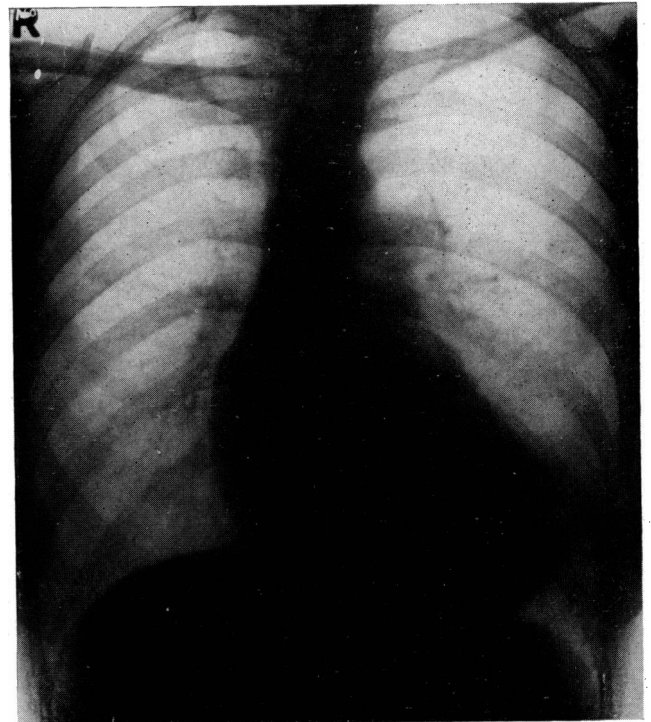


FIG. 2.—Pulmonary ischaemia in a case of Fallot's tetralogy.

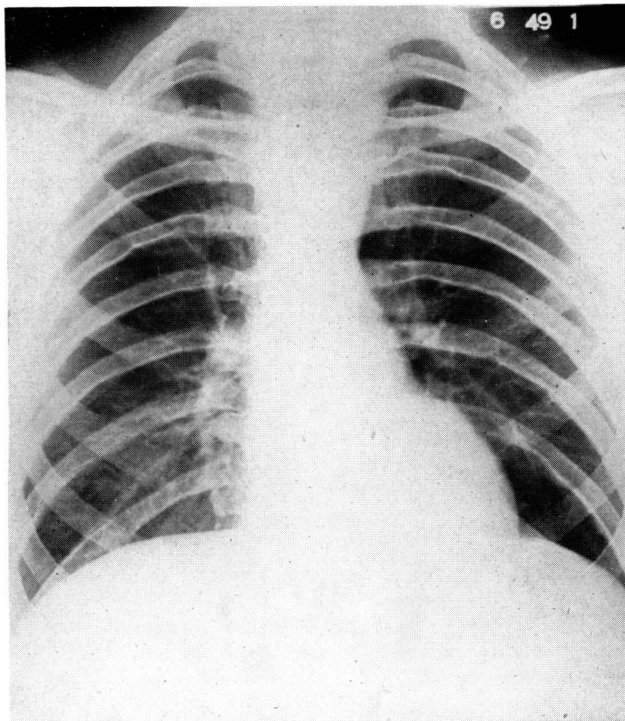


FIG. 3.—Coarctation of the aorta showing a double aortic knuckle.

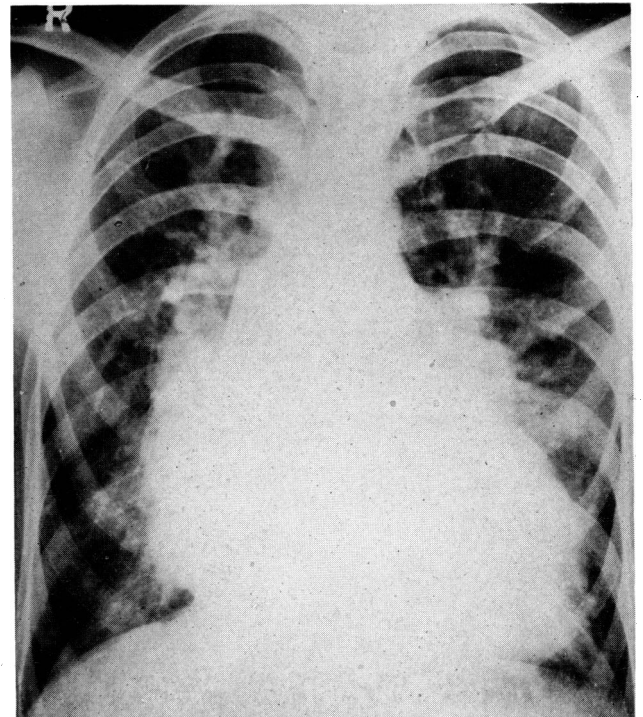


FIG. 4.—X-ray appearances in V.S.D., showing pulmonary plethora and left ventricular enlargement.

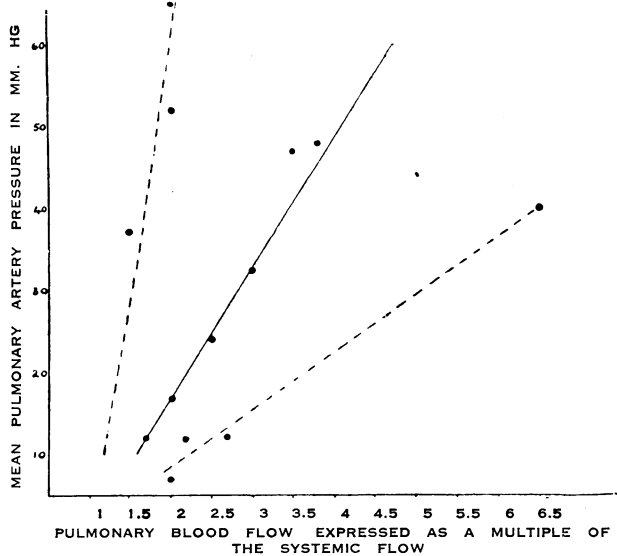


FIG. A.—Graph illustrating the relationship of the pulmonary blood flow to the pulmonary artery pressure in patent ductus.

To the three patients with true pulmonary hypertension mentioned (aged 8, 8, and 23) must be added a fourth (a girl of 12) who was catheterized only a year after successful ligation. Her mean pulmonary artery pressure was then 33 mm. Hg. above the sternal angle. The prognosis of these cases should be guarded, for the hypertension may be irreversible; on the other hand, before ligation a moderate increase of peripheral pulmonary resistance may be beneficial, for it reduces the size of the shunt and the work of the left ventricle. By far the worst case (a woman of 35) in this series had a low normal resistance. Another point that emerges is that three of those with true pulmonary hypertension were younger than the average of those without, which was 14.

It is clear that the duration of the shunt does not determine whether the peripheral resistance rises or not, but some other factor. Should the resistance rise precipitously, reversal of the shunt is theoretically possible, and this might occur in childhood. The point will be discussed again in relation to Eisenmenger's complex.

The pulmonary blood flow was usually two to four times the systemic flow—that is, about 10–20 litres a minute. The whole of the extra work entailed in pumping the shunted blood falls on the left ventricle. The systemic flow (and therefore the right ventricular output) was usually a high normal (5–6 litres a minute).

Differential Diagnosis

1. *Aorto-pulmonary Septal Defect or Perforation of an Aortic Sinus into the Pulmonary Artery.*—Apart from the fact that the thrill and murmur are especially coarse and loud, respectively, and tend to be maximal in the third rather than the second intercostal space, there is nothing to distinguish this condition from patent ductus. Cardiac catheterization revealed the same kind and degree of shunt in three cases studied, and angiocardiology has not helped. If the onset of the thrill and murmur can be dated to an attack of bacterial endocarditis, however, a perforated aortic sinus may be diagnosed with confidence.

2. *Perforated Aortic Sinus into the Right Ventricle.*—Only one case was encountered. The clinical findings were similar to those of patent ductus, but the continuous thrill and murmur were distinctly lower, being maximal in the fourth space. Cardiac catheterization proved that the shunt

was from the aorta to the right ventricle, pressures and samples being similar to those found in cases of V.S.D.

3. *Other Causes of a Continuous Murmur.*—These include a jugular venous hum, and arteriovenous aneurysm of the lung or of coronary, intercostal, or internal mammary vessels. These have already been discussed.

4. *Rheumatic Aortic Incompetence and Mitral Stenosis.*—The combination of a water-hammer pulse, systolic and diastolic murmurs at the base, left ventricular enlargement, and a mitral diastolic murmur with or without slight enlargement of the left auricle may occur in rheumatic heart disease or patent ductus, and the distinction between the two occasionally presents difficulty: this is when opinion differs about whether the basal murmur is to-and-fro or continuous, or when a continuous murmur is missing in a case of patent ductus with pulmonary incompetence. The presence or absence of a rheumatic history or of other rheumatic manifestations and of radiological evidence of pulmonary plethora should prevent error. If there is still doubt, cardiac catheterization should be performed.

5. Ventricular septal defect with aortic incompetence gives rise to a water-hammer pulse, a systolic and diastolic basal murmur, left ventricular enlargement, a functional mitral diastolic murmur, and pulmonary plethora. The differential diagnosis rests entirely on the site and timing of the thrill and murmur, and if these should be atypical serious error resulting in ill-advised thoracotomy may result. Moreover, cardiac catheterization in V.S.D. occasionally yields data compatible with patent ductus plus pulmonary incompetence.

Treatment

Surgical ligation is advised in all severe cases of patent ductus, and in all infected cases after preliminary penicillin treatment. As the operative mortality is still 2–3%, mild uncomplicated cases should be left alone. Whether moderate cases are ligated or not often depends on the attitude of the parents or patient; on the whole they are probably best ligated.

Ventricular Septal Defect

There were 24 cases with uncomplicated V.S.D.—11 male and 13 female. Their ages ranged between 3 and 55, 15 of them being children under 12 years old, 5 adolescent, and 4 adult. The majority were symptom-free, but five could not compete physically with their fellows, and one (aged 5) had congestive failure.

The important physical signs included a small or normal peripheral pulse, a normal jugular venous pressure without a conspicuous *a* wave, a thrusting hyperdynamic left ventricular type of cardiac impulse, a lifting right ventricular outflow tract and pulsating pulmonary artery, a Roger murmur and thrill, a normally split second heart sound at the pulmonary area (if not obscured by the murmur) with accentuation of the pulmonary element, and a functional mitral diastolic murmur.

Mild cases showed little but the Roger murmur and thrill. The least common sign in the more severe cases was detectable pulsation of the pulmonary artery.

A thrill accompanied the Roger murmur in every case. It was maximal in the fourth or third and fourth intercostal spaces in all but three, when it was maximal in the second (two) or second and third (one) spaces. In two patients it was unusually far to the left towards the apex beat and could have been mitral in origin. A mitral diastolic murmur was distinct in 10 out of 12 relatively severe cases, and was heard by some observers (but not by

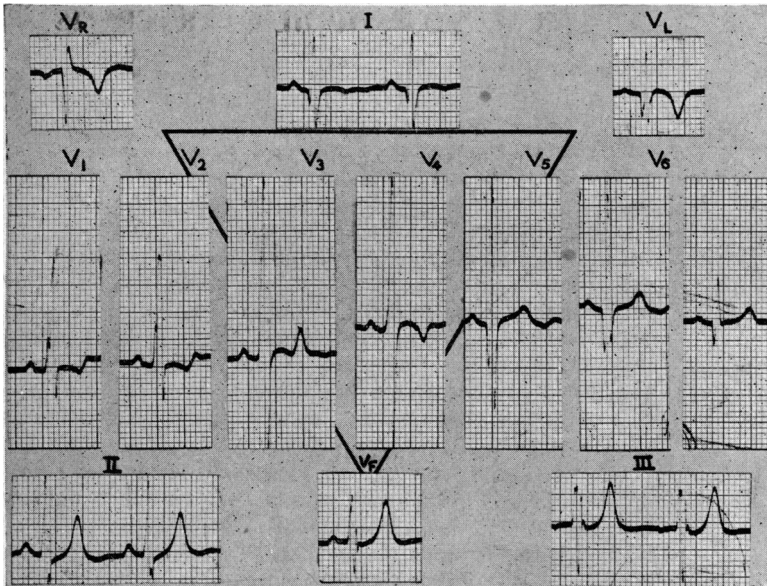


FIG. B.—Electrocardiogram in a case of V.S.D. showing large Q waves, tall R waves, and inverted U waves in left ventricular surface leads; and tall secondary R waves and inverted T waves in right ventricular surface leads.

me) in one of the other two. It was also heard in two relatively mild cases. A Graham Steell murmur from functional pulmonary incompetence was heard in four patients, and what was believed to be an aortic diastolic murmur in a fifth.

The electrocardiogram showed normal P waves, and QRS complexes that sometimes resembled the appearances in A.S.D. and sometimes those of patent ductus, but which as a rule lay somewhere between the two. Thus there might be prominent Q waves, tall R waves, and inverted U waves in left ventricular surface leads (Fig. B), and yet V₁ might show a well-formed secondary R wave. Partial right bundle-branch block, indistinguishable from that in A.S.D., was seen in three cases. In mild "maladie de Roger" the electrocardiogram was normal.

X-ray appearances were indistinguishable from those of patent ductus. Pulmonary plethora and left ventricular enlargement were very conspicuous in the more severe cases (Fig. 4).

By all standards at least 13 of the 24 cases were severe. Only four showed nothing but the characteristic Roger thrill and murmur.

Cardiac catheterization was undertaken in 16 cases. The mean pulmonary artery pressure was raised considerably

TABLE III.—Ventricular Septal Defect

Case No.	Age	Mean Pressure (mm. Hg)		% O ₂ Saturation			Ratio of Pul. to Systemic Flow	Pul. Resistance (P.A. Pressure / Pul. Flow)	
		R.V.	P.A.	R.A.	Low R.V.	High R.V.			P.A.
1	36	19	11	13	56	70	75	2:1	1.3
2	51	55	18	18	58	75	71	1.7:1	1.8
3	56	6	54	95	49	63	63	3.5:1	5.4*
4	27	29	29	29	59	81	83	2:1	(?)
5	85	15	13	18	70	83	86	2:1	7*
6	94	11	43	73	72	86	82	1.9:1	1.8
7	102	24	24	42	56	82	81	4.3:1	7*
8	139	7	9	10	72	78	84	2:1	2
9	145	8	9	11	76	75	83	1.4:1	1.5
10	160	6	12	18	73	85	82	1.7:1	2
11	166	6	6	7	73	82	84	2:1	7d
12	167	28	12	14	64	81	81	2.5:1	1d
13	161	11	8	12	74	73	72	1.3:1	1.5
14	7B	15	34	71	69	81	81	2:1	7*
15	163	3	9	11	66	77	77	1.6:1	1d
16	169	6	37	61	68	86	86	2.5:1	5*

* Increased pulmonary resistance. d = Diminished pulmonary resistance.

in six, slightly in four, and was normal in six (Table III). As with patent ductus, the height of the pressure did not parallel the size of the shunt at all closely but depended on the pulmonary peripheral resistance: this was increased in four cases, decreased in four, and normal in eight. The patient with the largest shunt had a low resistance, and three of the four patients with high pressures had only average shunts (Fig. C). The pulmonary blood flow was usually at least double the systemic flow, being of the order of 10–15 litres a minute, but in four mild cases it was only about one and a half times the systemic flow. The contention that very mild cases of "maladie de Roger" may not be detectable by the method of cardiac catheterization is difficult to dispute in the absence of necropsies, but seems improbable.

Angiocardiography was carried out in the patient with the highest pulmonary artery pressure to see if transient reversal of the shunt could be demonstrated. The mean pulmonary artery pressure was 95 mm. Hg, and the systemic blood pressure 160/100 mm. Hg, there being associated coarctation of the aorta. No reversal of shunt could be seen in the angiocardiogram. Nevertheless reversal of the shunt is likely to occur in rare cases that develop an extremely high pulmonary resistance (see under Eisenmenger's syndrome).

Differential Diagnosis

The clinical diagnosis of V.S.D. by specialist physicians was often incorrect, and many cases of V.S.D. had been diagnosed otherwise. Thus, of 33 cases proved by means of cardiac catheterization, 17 had been diagnosed as uncomplicated V.S.D.

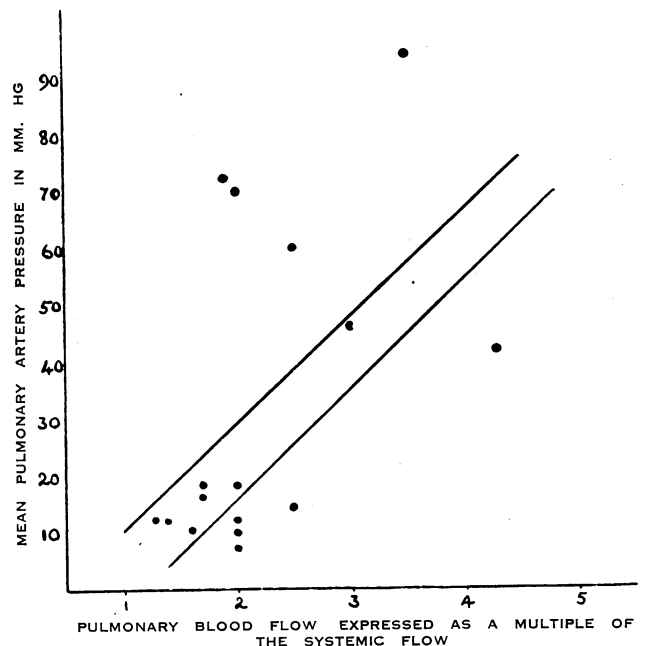


FIG. C.—Graph showing the relationship of the pulmonary blood flow to the pulmonary artery pressure in V.S.D.

in error, 7 with V.S.D. had been diagnosed otherwise, and 9 were correctly diagnosed as having V.S.D. The chief sources of confusion in suggested mild cases were innocent left parasternal murmur, simple pulmonary stenosis, subaortic stenosis, and organic mitral incompetence; and in cases with pulmonary plethora, patent ductus, and A.S.D.

If there is no thrill, a left parasternal murmur unaccompanied by any of the clinical features of V.S.D. mentioned above should be regarded as innocent.

Simple pulmonary valvular stenosis can usually be distinguished by the higher position of the thrill and murmur, by the softness of the pulmonary element of the second heart sound (if it can be heard at all), by the tapping cardiac impulse, and by dilatation of the pulmonary artery in the absence of pulmonary plethora. Subvalvular stenosis is more difficult, because turbulence may then be lower and the pulmonary artery may not be dilated; but the second heart sound and the quality of the cardiac impulse should prevent mistakes. Severe pulmonary stenosis is easily distinguished by the electrocardiogram. Mild subaortic stenosis may be clinically indistinguishable from the "maladie de Roger" if the murmur and thrill are low; if the left ventricle is enlarged, however, absence of other evidence of V.S.D. strongly favours subaortic stenosis.

Organic mitral incompetence with left ventricular enlargement, a mitral diastolic murmur, and a systolic thrill and murmur rather centrally placed may deceive the most experienced; but skiagrams should reveal the tell-tale systolic expansion of the left auricle if there is mitral incompetence, and pulmonary plethora if there is V.S.D.

Patent ductus without a Gibson murmur should be recognized by the peripheral pulse. Confusion is scarcely possible unless V.S.D. is complicated by aortic incompetence; and if systolic turbulence then happens to be high, real difficulty may be encountered. Clinical or electrocardiographic evidence of right ventricular dilatation (as well as left) favours V.S.D.

Atrial septal defect with a relatively low systolic thrill and murmur, and with a hyperdynamic right ventricle forming the apex beat, may closely simulate V.S.D. But the second heart sound is much more widely split in A.S.D., and the pulmonary element is not accentuated. Moreover, the Roesler type of thrusting cardiac impulse is much less common in A.S.D. than was at one time thought: in clinical diagnosis few mistakes will be made if a left ventricular type of cardiac impulse is accepted at its face value.

Terminology

It is suggested that the term "maladie de Roger," if retained at all, should be applied only to mild cases showing nothing more than the Roger murmur and thrill. The majority of cases of V.S.D. present a very different picture from that described by Roger himself and from all textbook descriptions of the "maladie de Roger." Nor is Taussig's classification of high and low defects acceptable. She regards cases with pulmonary plethora and dilated pulmonary arteries as examples of high V.S.D., the left ventricle pumping much blood almost direct into the pulmonary artery. She thinks that trivial shunts mean low V.S.D. This is incorrect. Selzer (1949) has already reviewed the literature from the pathological point of view and shown that only 10% of all cases of uncomplicated V.S.D. have low defects in the muscular septum and that these present no distinctive clinical features. In the present series cardiac catheterization has shown that high and low right ventricular samples are similar to one another and to samples from the pulmonary artery in nearly all instances (Table III); only in the mildest case was there any significant difference, and then the lowest sample was the least saturated.

(The conclusion of the paper will appear next week, with a full list of references.)

A circular from the Ministry of Health to local health authorities points out that many soldiers discharged from the Army on psychiatric grounds need social rather than medical aftercare. A special procedure has therefore been devised for these people as an experiment for one year. Army Form D.487, with which medical officers of health are familiar, will be marked "psychiatric aftercare" and sent to the M.O.H. of the area where the soldier will live. The local health authority should arrange for an initial visit to be paid to the ex-soldier by a social worker soon after the form is received. The authority may then arrange for aftercare services to be provided.

DIFFUSE EOSINOPHILIC ARTERITIS

BY

GEORGE LUMB, M.D.

*Honorary Consultant Pathologist, Westminster Hospital;
Senior Lecturer in Pathology, Westminster Medical
School*

[WITH SPECIAL PLATE]

During the past years considerable interest has centred on the problems of tissue changes in conditions of allergic origin, and an increasing quantity of evidence has been collected demonstrating that certain abnormalities, such as vascular proliferative lesions, focal necrosis, and tissue oedema, are to be found in a variety of apparently different diseases linked only by the probability of their having an allergic background.

Essentially similar changes have been found in cases of rheumatic polyarthritis and polyarteritis nodosa (Bergstrand, 1946), whilst evidence of associated allergic skin phenomena have been demonstrated in these conditions; and the association of polyarthritis with clear-cut cases of polyarteritis nodosa is not unknown (Herlitz, 1930-1; Friedberg and Gross, 1934). Further, Rich and Gregory (1943) have shown that the lung lesions in rheumatic pneumonia are essentially similar to those found in cases in which hypersensitivity to sulphonamide drugs exists. There is also certain evidence (Salvesen, 1938; Ehrström, 1941) that glomerulo-nephritis—also considered to be of allergic origin—may, more often than was first supposed, be an associated factor in cases of rheumatism.

More recently, examples of vascular and tissue changes of a similar type, occurring particularly in the lungs, have been described in cases of asthma, and Wilson and Alexander (1945) have shown that 18% of their cases of polyarteritis nodosa had an associated bronchial asthma.

A group of cases has therefore emerged which, although presenting widely differing clinical pictures, has in common the possibility of a similar type of aetiology—namely, an allergic manifestation. Experimental proof of such a theory is so far lacking, and the threads of evidence which do exist are disappointingly inconclusive. Evidence of similar or related morbid anatomical and histological changes in the tissues of patients suffering from this group of diseases provides another method of approach to this problem which has been followed principally by Bergstrand. Opportunities for post-mortem examination have been scanty, for diseases of the asthma group are of relatively benign type, and it is considered justifiable to place on record a further case in which necropsy was performed and full clinical details are available, in order to add to the few examples of this type already in the literature.

Case Report

A married woman aged 33, with one healthy child aged 3, first consulted her doctor in the autumn of 1948 complaining of a cough which had been present for nine months. Previously she had been healthy, with no personal or family history of any complaint of an allergic nature. She gave a history of frequent streaking of blood in the sputum, and for two months she had suffered from dysphagia and hoarseness associated with a swelling of the thyroid gland, together with some increase of nervousness and irritability. She was admitted to hospital on October 10, 1948.

A blood count showed: Hb, 82%; red cells, 4,570,300; white cells, 7,400 (23% eosinophils). Sputum examined for tubercle bacilli was negative on three occasions, but 9% of the total number of nucleated cells were eosinophils. A radiograph of