

Deposition of IgA in Renal Glomeruli of Mink Affected With Aleutian Disease

J. L. Portis, MD, and J. E. Coe, MD

The glomerular deposition of immunoglobulin (Ig) was studied in sapphire mink affected with terminal Aleutian disease (AD). Fluorescein conjugated Ig-class specific antisera were used to evaluate and identify the glomerular Ig. Kidneys of all 28 mink with documented AD had deposits of IgA and β_1C in a capillary and mesangial distribution. Only 7 of 28 mink had demonstrable glomerular IgG and/or IgM. In addition, interstitial plasma cell infiltrates in 17 of 19 kidneys stained exclusively with anti-IgA. All antisera used in this study were evaluated for Ig-class specificity by both gel diffusion and agarose-bead techniques. The striking Ig class restriction demonstrated for glomerular Ig deposition in AD is discussed in light of current knowledge of the pathogenesis of AD glomerulopathy. (*Am J Pathol* 96:227-236, 1979)

OF THE PERSISTENT VIRAL DISEASES, Aleutian disease of mink is of particular interest because of the importance of circulating immune complexes in its pathogenesis¹ and, thus, its use as an infectious model for immune complex diseases of man. The predominant pathologic lesions consist of systemic plasmacytosis, proliferative glomerulonephritis, and vasculitis associated with local deposits of Ig and β_1C .^{2,3} Porter et al first demonstrated circulating infectious immune complexes in the serum and viral antigen in the glomeruli of affected mink.⁴ However, the nature of the pathogenic complexes has not been firmly established. We are particularly interested in defining the antigen(s) and Ig class(es) associated with the pathogenic complexes. In the current study using Ig class specific fluorescein labeled antisera, we examined the renal glomeruli of 28 mink with terminal AD. After determining the specificity of the reagents at the level of sensitivity implicit in fluorescence microscopy, we found that 21 of 28 kidneys contained demonstrable glomerular deposits consisting exclusively of IgA and β_1C . The predominance of IgA in diseased glomeruli suggests that this Ig class is an important constituent of the pathogenic immune complexes of AD.

From the US Department of Health, Education, and Welfare, Public Health Service, National Institutes of Health, National Institute of Allergy and Infectious Diseases, Rocky Mountain Laboratory, Hamilton, Montana.

Accepted for publication March 5, 1979.

Address reprint requests to John L. Portis, MD, National Institute of Allergy and Infectious Diseases, Rocky Mountain Laboratory, Hamilton, MT 59840.

0002-9440/79/0709-0227\$01.00

© 1979 American Association of Pathologists

Materials and Methods

Animals

Mink of the sapphire color phase were obtained from a closed herd free of Aleutian disease and were maintained at the Rocky Mountain Laboratory. New Zealand white rabbits were obtained from a local source.

AD Virus

Mink were inoculated with the Pullman strain of AD virus (10th to 12th passage) by the intraperitoneal route as described previously.⁵ Diagnosis of AD was based on elevated serum gamma globulin concentration by cellulose acetate electrophoresis⁶ and autopsy findings.⁵ Serums of some mink were also subjected to the counterimmunoelectrophoresis (CIE) test for anti-AD viral antibody.⁶

Preparation of Antiserums

All antiserums were prepared in rabbits as described previously.⁷ Briefly, specific antimink IgG was prepared by injection of rabbits with isolated mink IgG H chains in complete Freund's adjuvant (CFA) and absorbed by passage through a Sepharose column conjugated with mink F(ab')₂ fragments by cyanogen bromide.⁸ Antimink IgA was made by injection of rabbits with a nonspecific antimink IgG immunoprecipitate of mink succus entericus in CFA. Anti-IgM was prepared by injection with Pevikon and Sephadex G-200 isolated mink IgM in CFA. Both anti-IgA and IgM were rendered specific by absorption on a Sepharose column conjugated with mink IgG.⁸ Antimink β_1 C was prepared by the method of Mardiney.⁹ This antiserum was specific for β_1 C by immunoelectrophoresis and gel diffusion without further absorption. However, because of the sensitivity of the immunofluorescence technique, purified mink IgG was added to the antiserum to avoid potential cross reactions with Ig. All antiserums were fluoresceinated as previously described.¹⁰

Preparation of Tissue Sections

Kidneys were obtained at autopsy from mink affected with terminal disease. The kidneys were sliced transversely in approximately 2-mm sections, and small fragments containing both cortex and medulla were placed on the inside wall of glass tubes, plunged into a bath of dry ice-95% ethanol, and stored at -70°C until used. Several kidneys were prepared by freezing in hexane.¹¹

Sections ($4\ \mu$) were made on a cryostat maintained at -30°C . The sections were placed on glass slides and then washed in PBS for 15 minutes at room temperature.^{4,12} The unfixed sections were stained for 30 minutes with appropriate dilutions of the respective antiserums and washed on a rocking platform for 45 minutes at 4°C with three changes of PBS. They were examined under glycerol with a Reichert fluorescent microscope with KP490 and BG38 interference filters and a K530 barrier filter. In some studies frozen sections or imprints were fixed with acetone at -20°C overnight and stained as described above.

Studies on the Specificity of the Antiserums

The specificity of the fluorescein conjugates was determined by gel diffusion as previously described⁷ and by a Sepharose bead fluorescent technique.¹³ Briefly, Sepharose 6B was conjugated with either DEAE purified mink IgG,⁷ or whole mink serum.¹⁴ The latter serum, from a mink affected with avian tuberculosis, had high levels of IgG (16.6 mg/ml), IgA (16.4 mg/ml), and IgM (9.5 mg/ml) as determined by Mancini radial immunodiffusion.¹⁵ Residual reactive sites on the bead conjugates were blocked with 1 M glycine at

room temperature for 4 hours, and the beads were washed with M/15 PBS by centrifugation. To 50 μ l of beads in M/15 PBS (25% suspension) was added 2 μ l neat fluorescein conjugate. The mixture was incubated 30 minutes at room temperature with occasional swirling and then washed 5 times with PBS by centrifugation. The beads were mounted under coverslips, sealed with petroleum jelly, and examined under the fluorescent microscope.

Results

Specificity Studies

After absorption all anti-Ig conjugates were specific for the respective Ig classes by gel diffusion.⁷ That is, the precipitin lines resulting from reaction of anti-IgG, IgA, and IgM against whole mink serum spurred past one another in gel diffusion analysis. In addition, as previously shown⁷ the anti-IgA reagent reacted with a 12 to 13S β serum protein which had antigen binding capacity and was found predominantly in external secretions. All anti-Ig preparations stained plasma cells in acetone fixed imprints of mink mesenteric lymph node (Figure 1C) and along with anti- β_1 C stained Sepharose beads coated with whole mink serum (Figure 1B). Thus, the reagents were reactive at the dilutions used. However, only anti-IgG bound to IgG-coated beads (Figure 1A) indicating that the anti-IgA and anti-IgM did not cross react with IgG. Because of the difficulty of separating serum IgA and IgM, delineation of the specificity of the respective antisera was carried no further.

Fluorescence Studies of AD Kidneys

Kidneys from 29 mink inoculated with AD virus were examined for the presence of Ig and β_1 C in the glomeruli. These animals had been inoculated from 8 weeks to 20 months before they were killed, and all but one had morphologic and laboratory evidence of AD at the time of autopsy. Fluorescent staining of the kidney sections revealed Ig and β_1 C deposition in glomeruli of all kidneys from clinically positive animals (28/29). Immunoglobulin and β_1 C were deposited in a granular pattern with a predominantly capillary distribution. Occasional mesangial deposits were also seen. Of the three Ig classes studied, IgA was the predominant Ig present in affected kidneys and the exclusive Ig demonstrated in 21 of 28 diseased kidneys (Table 1 and Figure 2). Staining with anti-IgG was seen in only 5 of the 28 kidneys (Table 1). The distribution of β_1 C corresponded well with that of Ig being primarily capillary with minimal to moderate mesangial deposits. Of interest was the staining of variable numbers of plasma cells in the interstitium of cortex and medulla. Of 19 kidneys in which plasma cells were seen by fluorescence microscopy, 17 were stained exclusively by anti-IgA (Table 1 and Figure 3).

Table 1—Summary of Laboratory Data of Mink Examined for Glomerular Immunofluorescence

| Mink† | No. | Serum γ globulin % of total protein ± SEM | | Serum BUN* at autopsy | CIE† titer at autopsy | Ig class demonstrated in glomeruli | | | | | | | |
|--------------------------|-----|--|---------------|-----------------------------|-----------------------------|------------------------------------|-------|-----|-----|-----|-----|-----|-----|
| | | Before inoculation | At autopsy | | | No. | Range | IgA | | IgG | | IgM | |
| | | | | | | | | IgA | IgG | IgA | IgG | IgA | IgG |
| Inoculated AD+§ | 28 | 11.7 ± 0.5 | 39.8 ± 1.7 | 263 ± 23.6 | 13 | 1:256- >1:1024 | 21 | 2 | 2 | 3 | 17 | 2 | |
| Inoculated AD-§ | 1 | 8.3 | 12.7 | 39 | 1 | 0 | 0 | 0 | 0 | 0 | 0 | 0 | |
| Uninoculated Controls | 6 | 10.8 ± 1.7 | 22.8 ± 4.8 | ND | ND | 0 | 0 | 0 | 0 | 0 | 0 | 0 | |

* Blood urea nitrogen determined by diacetyl-monoxime using a Technicon autoanalyzer.

† Counterimmunoelectrophoresis.

‡ Mink were inoculated IP with 10th to 12th passage of AD virus (Pullman strain).

§ AD+ = Aleutian disease by clinical, laboratory, and pathologic criteria; AD-- = no evidence of Aleutian disease.

As further evidence of the specificity of the anti-IgA, prior absorption of the antiserum with non-AD mink serum completely abrogated glomerular staining whereas absorption with purified mink IgG or heterologous (rabbit) serum had no effect (Figure 4).

Discussion

This report presents evidence of the preferential deposition of IgA and β_1C in the glomeruli of sapphire mink affected with terminal AD. IgA was detected in all 28 AD positive kidneys examined; in 21 the deposits were exclusively of the IgA class. In contrast, glomeruli of only 5 of the 28 kidneys stained with anti-IgG. Glomeruli from all diseased kidneys contained β_1C deposited in a distribution corresponding to that of Ig (ie, predominantly capillary with occasional mesangial deposits). In addition, of 19 kidneys in which plasma cells were seen by fluorescence microscopy, 17 showed cytoplasmic staining only with anti-IgA. Studies of the specificity of the antisera revealed that all reagents were reactive at the dilutions used and that anti-IgA did not cross react with IgG; thus, fluorescein-conjugated anti-IgA did not bind to Sepharose beads coated with purified mink IgG (Figure 1) and the glomerular staining by anti-IgA was not diminished by prior absorption of the antiserum with purified IgG (Figure 4).

Glomerular deposition of IgA generally associated with IgG has been reported in a number of systemic diseases including systemic lupus erythematosus¹⁶ and Schönlein-Henoch purpura.¹⁷ In the latter disease the IgA deposits can be a striking feature.¹⁸ Berger and Hinglais¹⁹ first described a relatively benign, usually nonprogressive human glomerulopathy manifested by IgA deposition in the glomerular mesangium but with no systemic manifestations (reviewed by Lowance²⁰).

It is noteworthy that other studies have demonstrated the deposition of IgG and β_1C ^{12,21,22} and in one report IgM²³ in the glomeruli of mink with AD. However, the specificity of the antisera used was not documented, and, therefore, the possibility of cross reacting light chain interactions was not excluded. Pan et al³ demonstrated, in the acid eluate from isolated AD glomeruli, a β protein in addition to gamma globulin. Although this could have represented a complement component, these authors were reluctant to suggest that IgG deposition was of pathogenic significance.

One of the cardinal signs of AD is a markedly elevated serum gamma globulin concentration,²¹ a large proportion of which consists of IgG.²⁴ However, in sapphire mink inoculated with the Pullman (or Utah-1) strain of AD virus, the increased IgG concentration is accompanied by a striking elevation of the serum IgA concentration²⁴ (Coe, unpublished observa-

tions). The predominant glomerular deposition of IgA, as shown in this study, suggests that this Ig class may be important in the pathogenesis of AD glomerulitis.

The nature of the antigen(s) within the pathogenic complexes has been a subject of much dispute. Porter et al first demonstrated the presence of circulating infectious immune complexes in the serum of mink with AD,⁴ although circulating DNA and anti-DNA antibody have also been detected.²⁵ Acid eluates from isolated glomeruli of AD kidneys appear to contain anti-AD viral antibody¹² and AD viral antigens have been demonstrated in the glomeruli by immunofluorescence techniques.¹ Thus, the evidence suggests that viral antigen-antibody complex may be of pathogenic significance. With the purification of the structural proteins of AD virus at hand,²⁶ definition of the immune complexes within the glomeruli and comparison with circulating complexes should allow a better understanding of the nature of the glomerulopathy of AD.

References

1. Porter DD, Larsen AE: Aleutian disease of mink. *Prog Med Virol* 18:32-47, 1974
2. Henson JB, Gorham JR, McGuire TC, Crawford TB: Pathology and pathogenesis of Aleutian disease, *Frontiers of Biology*, Vol 44. Edited by RH Kimerlin. Amsterdam, North Holland Publishing Co, 1976, pp 175-205
3. Pan IC, Tsai KS, Karstad L: Glomerulonephritis in Aleutian disease of mink: Histological and immunofluorescence studies. *J Pathol* 101:119-127, 1970
4. Porter DD, Larsen AE: Aleutian disease of mink: Infectious virus-antibody complexes in the serum. *Proc Soc Exp Biol Med* 126:680-682, 1967
5. Eklund CM, Hadlow WJ, Kennedy RC, Boyle CC, Jackson TA: Aleutian disease of mink: Properties of the etiologic agent and the host responses. *J Infect Dis* 118:510-526, 1968
6. Bloom ME, Race RE, Hadlow WJ, Chesebro B: Aleutian disease of mink: The antibody response of sapphire and pastel mink to Aleutian disease virus. *J Immunol* 115:1034-1037, 1975
7. Coe JE, Hadlow WJ: Studies on immunoglobulins of mink: Definition of IgG, IgA, and IgM. *J Immunol* 108:530-537, 1972
8. Cuatrecasas P: Protein purification by affinity chromatography. *J Biol Chem* 245:3059-3065, 1970
9. Mardiney MR, Muller-Eberhard JR, Muller-Eberhard HJ: Mouse β_2 C-globulin: Production of antiserum and characterization in the complement reaction. *J Immunol* 94:877-882, 1976
10. Coe JE: Immunoglobulin synthesis by an SV-40 induced hamster lymphoma. *Immunology* 31:495-502, 1976
11. Kawamura A: Fluorescent antibody techniques and their application. Second Edition. Tokyo, University of Tokyo Press, 1977, pp 68-76
12. Cho HJ, Ingram DG: Pathogenesis of Aleutian disease of mink: Nature of the antiglobulin reaction and elution of antibody from erythrocytes and glomeruli of infected mink. *Infect Immun* 8:264-271, 1973
13. Scales RW, Jacobs Jr NF, Skaggs R: Use of immunoglobulin coupled to agarose beads for examining the specificity of conjugates. *J Clin Microbiol* 2:292-295, 1975
14. March SC, Parikh I, Cuatrecasas P: A simplified method for cyanogen bromide

- activation of agarose for affinity chromatography. *Anal Biochem* 60:149-152, 1974
15. Mancini G, Carbonara AO, Heremans JF: Immunochemical quantitation of antigens by single radial immunodiffusion. *Immunochemistry* 2:235-254, 1965
 16. Heptinstall RH: Pathology of the kidney. Vol 2. Little, Brown, and Co, 1974, pp 656-661
 17. Urizar RE, Michael A, Sisson S, Vernier RL: Anaphylactoid purpura. II. Immunofluorescent and electron microscopic studies of the glomerular lesions. *Lab Invest* 19:437-450, 1968
 18. Berger J, Yaneva H, Hinglais N: Immunohistochemistry of glomerulonephritis. *Advances in Nephrology*, Vol 1. Edited by J Hamburger, J Crosnier, MH Maxwell. Chicago, Yearbook, 1971, p 11
 19. Berger J, Hinglais N: Les depots intercapillaires d'IgA-IgG. *J Urol Nephrol (Paris)* 74:694, 1968
 20. Lowance DC, Mullins JD, McPhaul JJ: IgA-associated glomerulonephritis. *International Review of Experimental Pathology*, Vol 17. Edited by GW Richter, MA Epstein. New York, Academic Press, 1977, pp 143-172
 21. Porter DD, Larsen AE, Porter HG: The pathogenesis of Aleutian disease of mink. I. In vivo viral replication and the host antibody response to viral antigen. *J Exp Med* 130:575-589, 1969
 22. Trautwein G, Seidler D: Studies on the pathogenesis of Aleutian disease of mink. V. Immunofluorescence microscopical findings in the kidneys. *Zbl Vet Med* 19:144-157, 1972
 23. Johnson MI, Henson JB, Gorham JR: The influence of genotype on the development of glomerular lesions in mink with Aleutian disease virus. *Am J Pathol* 81:321-332, 1975
 24. Porter DD, Porter HG, Larsen AE: Immunoglobulin class of Aleutian disease viral antibody. *Fed Proc (Abstr)* 36:1268, 1977
 25. Barnett EV, Williams RC, Kenyon AJ, Henson JE: Nuclear antigens and anti-nuclear antibodies in mink serums. *Immunology* 16:241-253, 1969
 26. Shahrabadi MS, Cho HJ, Marusyk RG: Characterization of the protein and nucleic acid of Aleutian disease virus. *J Virol* 23:353-362, 1977

[Illustrations follow]

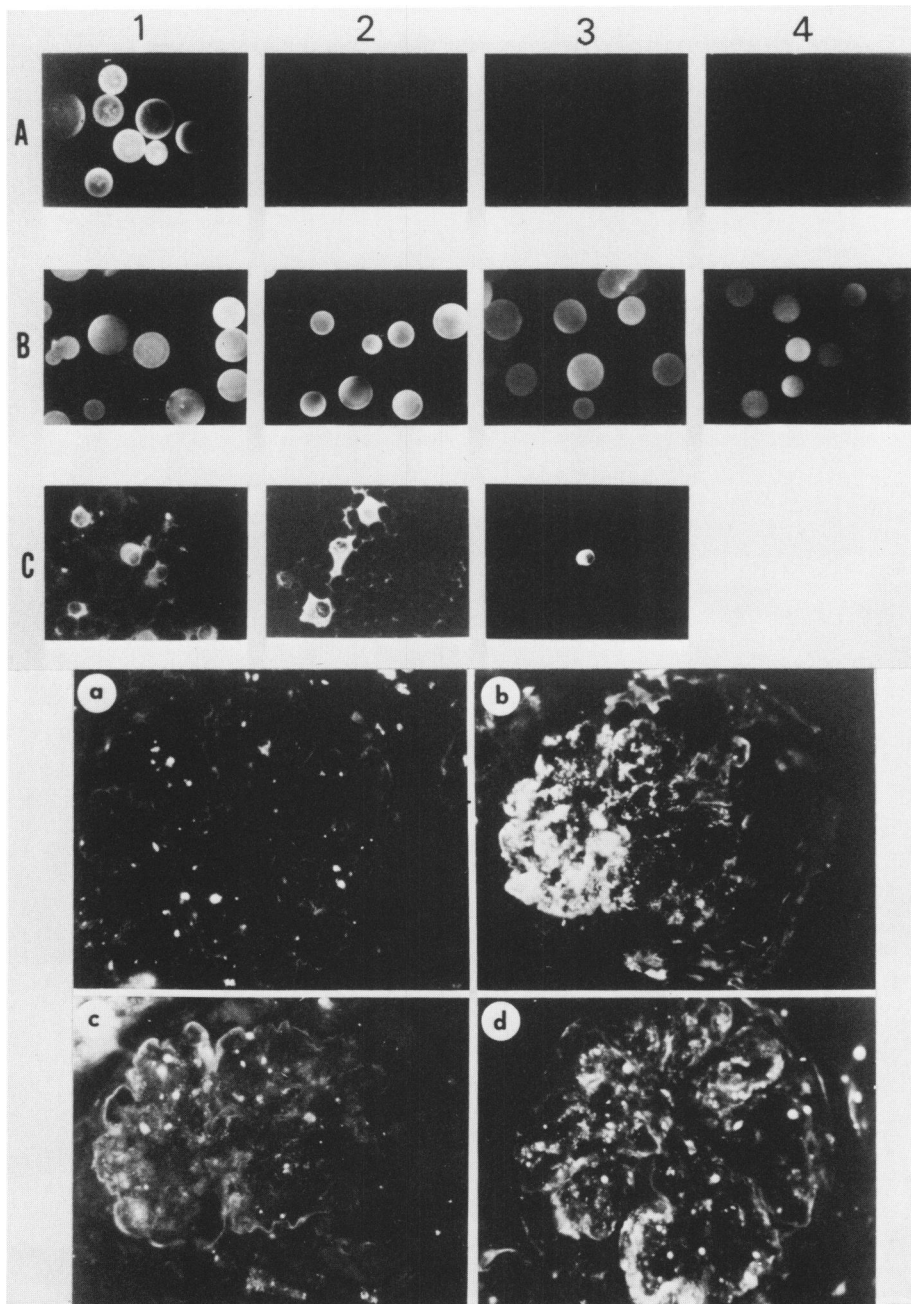


Figure 1—Specificity studies on fluorescein-conjugated antisera. Sepharose beads coated with mink IgG (A) were incubated with fluoresceinated anti-mink IgG (1), IgA (2), IgM (3), and β_2C (4) (57 \times). Fluorescence of the beads was seen only with anti-IgG. Yet all reagents reacted with beads coated with whole mink serum (B) (57 \times), and all anti-Ig reagents stained plasma cells in acetone-fixed imprints of normal mink mesenteric lymph node (C). (368 \times)

Figure 2—Immunofluorescence of glomeruli from an unfixed AD positive sapphire mink kidney stained with fluoresceinated anti-mink IgG (a), IgA (b), IgM (c), and β_2C (d). Predominantly capillary deposits were seen with anti-IgA and anti- β_2C but not with anti-IgG or IgM (260 \times).

(Both with a photographic reduction of 24%)

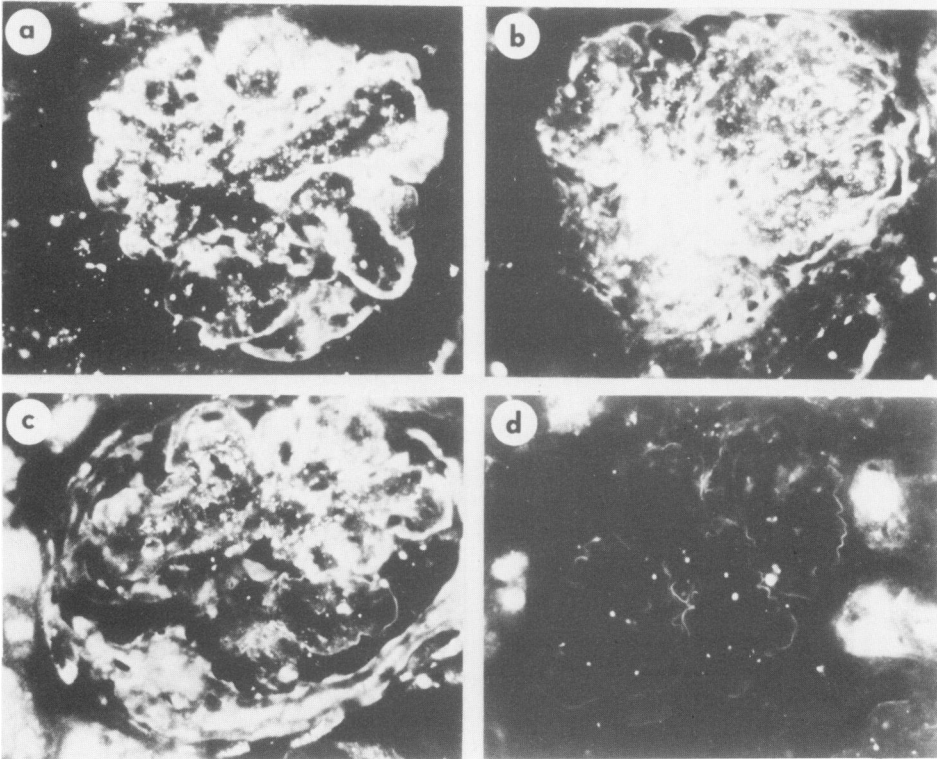
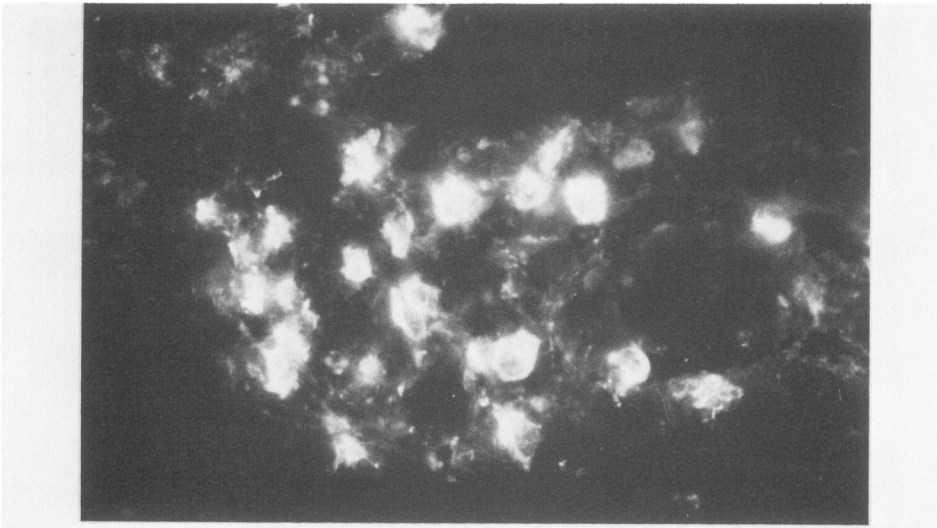


Figure 3—Interstitial plasma cells in the cortex of an acetone fixed AD positive sapphire kidney stained with fluoresceinated anti-mink IgA (836 \times).

Figure 4—Inhibition of glomerular fluorescence by preabsorption of fluoresceinated anti-mink IgA with PBS (a), mink IgG (b), normal rabbit serum (c) and non-AD sapphire mink serum (d) (260 \times).

(Both with a photographic reduction of 9%)