

# BRITISH MEDICAL JOURNAL

LONDON SATURDAY JUNE 18 1949

## THE SPLEEN AND SPLENECTOMY\*

BY

RONALD BODLEY SCOTT, M.A., D.M., F.R.C.P.

*Assistant Physician, St. Bartholomew's Hospital; Physician, Woolwich Memorial and Surbiton General Hospitals*

It is a melancholy reflection that Galen's only aphorism to remain in common currency after 1,800 years is his observation that the spleen was an organ full of mystery. Even to-day its functions in the healthy body remain in part mysterious and its structure matter for argument; but, if physiologists and anatomists still wrangle, the last ten years have enlarged the clinicians' understanding of the spleen in disease and have enabled them to define more exactly the indications for its removal. It is of these clinical aspects of disturbed splenic function and of the value of splenectomy in its correction that this paper treats. Our knowledge of these matters is built on the foundations laid by Frank (1916, 1917), Eppinger (1920), and Naegeli (1940), but its practical application is derived largely from the observations of American haematologists, and in particular of Doan and Dameshek.

### Anatomy and Physiology

The spleen may be regarded as a vast lymph node in which, among other specialized circulatory arrangements, the lymph sinuses are replaced by venous sinuses. It consists of a medulla in which are set the Malpighian corpuscles, globular aggregations of lymphocytes disposed around a central arteriole; it is enclosed within a fibrous capsule and scaffolded by fibrous trabeculae with a feltwork of reticulin fibrils. The organ is contractile, and along the verges of the venous sinuses are arranged elements of the reticulo-endothelial system, histiocytes, and undifferentiated mesenchymal cells. The intimate vascular anatomy of the spleen is still uncertain: some believe that the circulation is entirely enclosed within vessels (Knisely, 1934-5, 1936); some that there is no continuity from artery to vein, but that arterial capillaries open into the spongework of the splenic pulp, which in turn drains into the venous sinuses (MacKenzie, Whipple, and Wintersteiner, 1941); and some that there is a double circulation, a closed system in whose walls are pores which allow escape into and return from the surrounding pulp (McNee, 1931).

Whatever the exact nature of the spleen's circulatory arrangements, the organ is well designed to play the part of a reservoir for blood cells, a function postulated 240 years ago by Leeuwenhoek (1708) and established by the well-known researches of Barcroft (1925). In foetal life the spleen is engaged in the genesis of blood cells, but, although some lymphocytes and monocytes are normally of splenic origin, in adult life it resumes haemopoietic

activity only in certain pathological states. Its large complement of reticulo-endothelial cells ensures the spleen's co-operation in the many complex, and often obscure, activities of this system.

These reservoir, haemopoietic, and reticulo-endothelial functions, although clearly of great importance in the body's economy, have not the clear-cut clinical significance of those of the next category. These are concerned with the regulation of the cellular composition of the circulating blood. Although there is no evidence that the spleen takes an active part in the destruction of red blood cells, its removal is followed by a decrease in urobilinogen excretion, which suggests that it removes effete erythrocytes from the circulation. After splenectomy the red blood cells become thinner and more resistant to hypotonic salt solutions, "target cells" appear, and Howell-Jolly bodies and Cabot's rings may be found (Singer, Miller, and Dameshek, 1941).

It may be concluded that the spleen normally increases the thickness of erythrocytes passing through it, that it forms a cemetery for defunct red blood cells, and that it exerts some control over the maturation of erythroblasts, particularly of that phase at which the nucleus is shed. Splenectomy is followed by an increase in the peripheral leucocyte and platelet counts. The former rises to between 15,000 and 20,000 per c.mm., and although the neutrophils commonly share in this increase it is mainly due to a lymphocytosis. The platelet count may reach 1,000,000 per c.mm. The explanation of neither phenomenon is certain: there is no evidence that leucocytes or platelets are normally destroyed by the spleen; the organ must either control delivery of these elements from the bone marrow or exert an inhibitory influence on their formation.

### Indications for Splenectomy

This brief review of the spleen's functions must serve as an introduction to the subject of splenectomy. First, two general indications, unrelated to functional disturbance, may be dismissed. The necessity for operation in spontaneous or traumatic rupture is obvious: this gross surgical accident is seldom the concern of the physician, but it is well to recall the special liability to spontaneous rupture of the enlarged spleen in glandular fever (Attlee, 1932; King, 1941; Darley, Black, Smith, and Good, 1944; Davis, Macfee, Wright, and Allyn, 1945; Smith and Custer, 1946). Splenic tumours are almost invariably part of a neoplastic process systematized throughout the lympho-reticular tissue and thus do not constitute an indication for splenectomy; occasionally cysts may require excision.

\*A lecture delivered to the Ulster Medical Society on March 3.

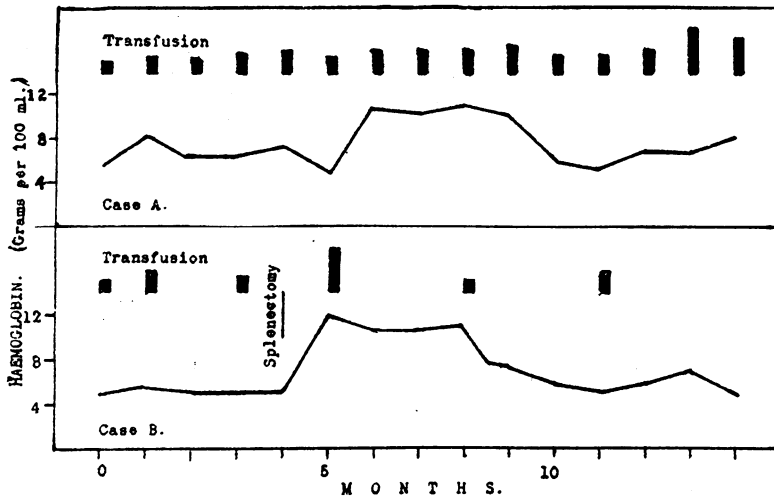


FIG. 1.—Transfusion requirements in identical twins with Mediterranean anaemia. The effect of splenectomy is shown in one. (After Govan, 1946.)

Of particular interest to the physician are the various disturbances which may be attributed to exalted splenic function. A resumption of haemopoietic activity occurs in several diffuse obliterative diseases of the bone marrow: it is seen in metastatic carcinoma, in osteosclerosis (Albers-Schönberg), and, particularly and most often, in myelosclerosis in which there is a replacement of normal blood-forming marrow by fibrous tissue and fine trabeculae of new bone. The spleen in this disorder undergoes myeloid transformation and may reach massive proportions; it is virtually the only haemopoietic tissue remaining, and for this reason its excision is strongly contraindicated. The diagnosis of this disease thus assumes some importance: in addition to splenomegaly, the features are anaemia of the leuco-erythroblastic type and a marrow of reduced cellularity on puncture; a trephine biopsy of the sternum may be required before the diagnosis is assured.

of great importance. This may result in anaemia, in thrombocytopenia, or in leucopenia, or in any combination of these changes.

**Splenectomy in Anaemia**

The value of splenectomy in some forms of haemolytic anaemia has long been appreciated, but the relation between splenic activity and the various haemolytic states is a matter of complexity. There is first a group of haemolytic anaemias in which the fundamental abnormality is a congenital and often inherited deformity of the red blood cell. The most common of these is familial acholuric jaundice, in which the erythrocytes have a shape approximating to the spherical. These spherocytes are retained selectively by the spleen and there destroyed in numbers often sufficient to lead to anaemia and haemolytic jaundice.

The spleen's activity in this disease must be regarded as normal but one which has a vicious effect on the organism because large numbers of the red blood cells, although functionally adequate, are mal-

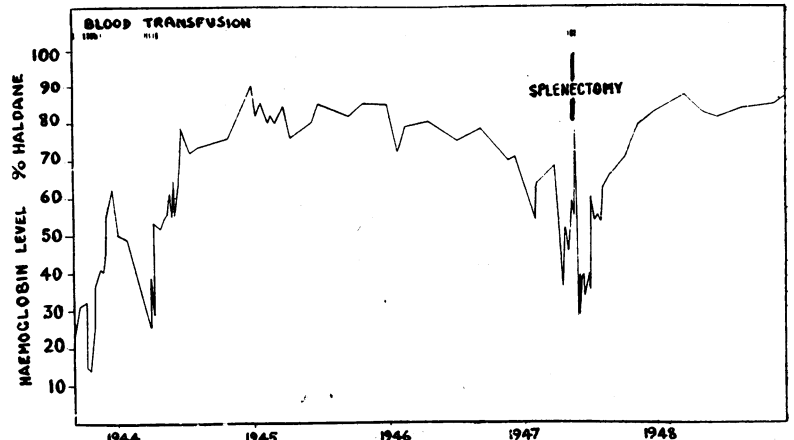


FIG. 3.—Haemolytic anaemia of unknown cause in a man aged 43.

Exaltation of the reticulo-endothelial functions of the spleen provides no definite clinical syndrome; it is in its effect on the circulating blood that hypersplenism becomes

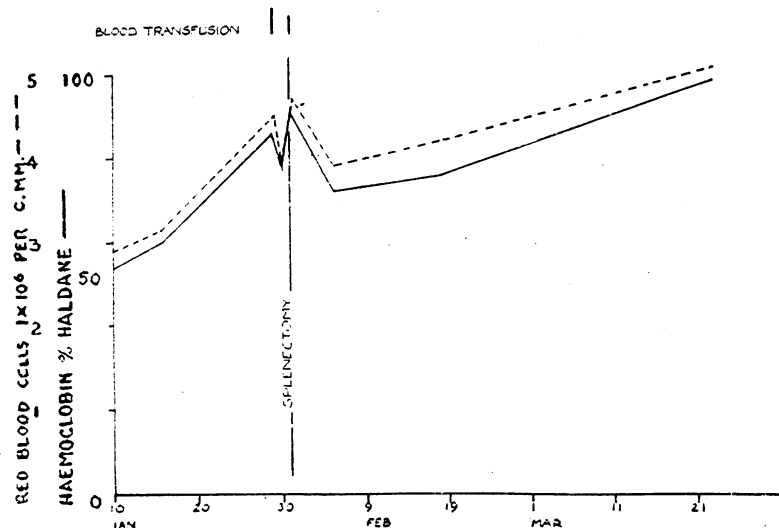


FIG. 2.—Acquired haemolytic anaemia of unknown causation in girl aged 18. Erythrocyte fragility 0.7-0.45% NaCl. Splenectomy: recovery.

formed and consequently are removed from the circulation. Splenectomy abolishes excessive haemolysis and usually reduces spherocytosis, for cells passing through the spleen are normally increased in thickness. In sickle-cell anaemia, which presents analogies with acholuric jaundice, splenectomy is curiously and notoriously ineffective. The third anaemia of this type—Mediterranean anaemia—occupies an intermediate position in this respect, and an interesting controlled experiment in which the spleen was removed from one of a pair of identical twins with this disease shows how beneficial the operation may be (Fig. 1) (Govan, 1946).

The second category of haemolytic anaemias is that in which some external factor is responsible for the destruction of red blood cells. This may be a recognizable toxic agent such as lead or one of the sulphonamide drugs, but the present discussion is concerned with those acute and chronic forms of acquired haemolytic anaemia in which no cause is evident. There is reason to believe that many are due to an antigen-antibody type of reaction: in some a haemolysin can be demonstrated in the patient's serum (Dameshek and Schwartz, 1938, 1940);

in others the Coombs test provides indirect proof of its presence (Coombs, Mourant, and Race, 1945). Damage to the circulating erythrocytes, falling short of lysis, may be shown by spherocytosis and decrease in hypotonic resistance; in others inclusion bodies within the red blood cells are evidence that they have suffered injury (McFadzean and Davis, 1947). These cells may be adequate for the transport of oxygen, but they are removed and destroyed by the voracious and indiscriminating spleen.

In acquired haemolytic anaemia of this type, where the cause is unknown and therefore unsusceptible of control, splenectomy must be recommended if the haemolytic process shows no sign of abating during a period of observation and blood transfusion. Removal of the organ responsible for destroying damaged red blood cells, and it has been suggested that the haemolysis may be elaborated in the spleen itself. The effect of operation cannot be foretold: it may be dramatically efficacious; it may not influence the process at all; but the patient whose condition is deteriorating should always be given the chance. Figs. 2-5 show instances of this disease in which the result of splenectomy varied from complete and immediate remission to utter ineffectiveness.

The third group of haemolytic anaemias are those secondary to a splenomegaly which may be of almost any nature: there are records of this combination in lymphatic leukaemia (Marchal, Dany, and Grupper, 1934; Singer and Dameshek, 1941; Feldman and Yarvis, 1944), Hodgkin's disease (Holler and Paschkis, 1927; Kwaszewska, 1931; Bensis and Gouttas, 1934; von Braitenberg, 1937-8; Slot, 1938; Stats, Rosenthal, and Wasserman, 1947), sarcoidosis (Crane and Zetlin, 1945), Gaucher's disease (Mandelbaum, Berger, and Lederer, 1942), kala-azar (Burchenal, Bowers, and Haedicke, 1947), and tuberculous splenomegaly (Engelbreth-Holm, 1938). In many instances the haemolytic anaemia has been cured by splenectomy. The cause of this form of haemolysis is uncertain: in some instances it seems likely that red blood cells have become sequestered in the labyrinthine pulp of a vast spleen, there undergoing lysis; it has been suggested that the enlarged spleen elaborates a lysin or produces in

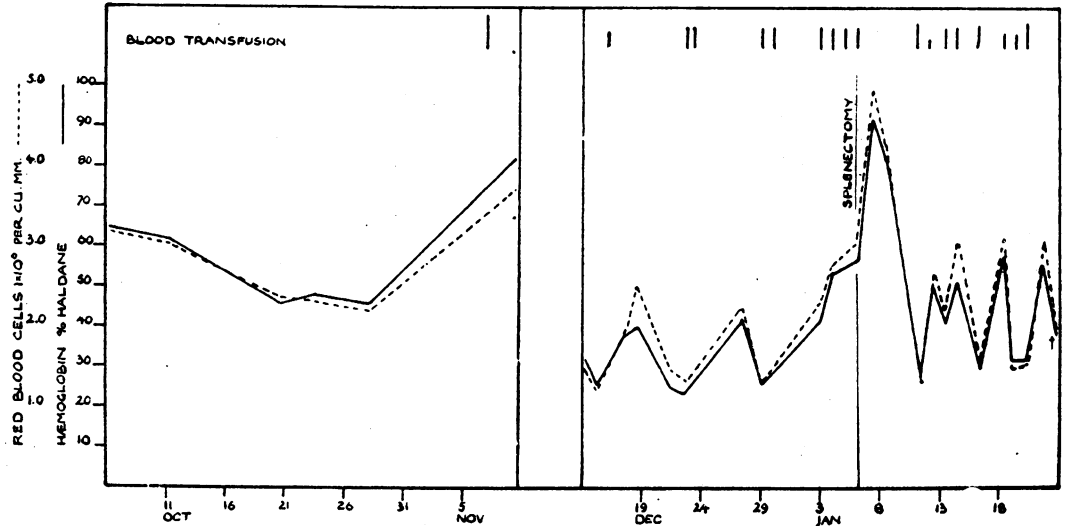


FIG. 4.—Acquired haemolytic anaemia of unknown cause in a woman aged 31. Erythrocyte fragility 0.5-0.45% NaCl. Failure of splenectomy.

greater measure its normal lysolecithin (Dameshek and Miller, 1943). Circumstances dictate the desirability of splenectomy: in a slowly progressive disorder in which the major disability is due to haemolytic anaemia it may well be justifiable; in a rapidly advancing leukaemia it would clearly be injudicious.

Figs. 6-8 illustrate instances of haemolytic anaemia associated with the splenomegaly of Hodgkin's disease, reticulosarcoma, and lymphatic leukaemia. In the first the patient presented with haemolytic anaemia and splenomegaly; splenectomy relieved all symptoms, but the excised organ showed the changes of Hodgkin's disease (Fig. 6). He remained in good health for 4½ years, when haemolytic anaemia recurred and he died from renal failure due to amyloidosis three months later. In this patient splenectomy resulted in nearly five years of normal existence. The anaemia in the second patient was of subacute evolution and the haemolytic process was controlled by splenectomy, although she died three months later from the underlying disease (Fig. 7). The patient with lymphatic leukaemia had four haemolytic episodes over a period of five years, the last proving fatal (Fig. 8); haemolysis was controlled in the first three by irradiation of the spleen and repeated blood transfusion. In the light of subsequent events splenectomy during the first episode might have been justifiable.

**Splenectomy in Thrombocytopenia**

Idiopathic thrombocytopenic purpura has long been recognized as a condition in which splenectomy is often

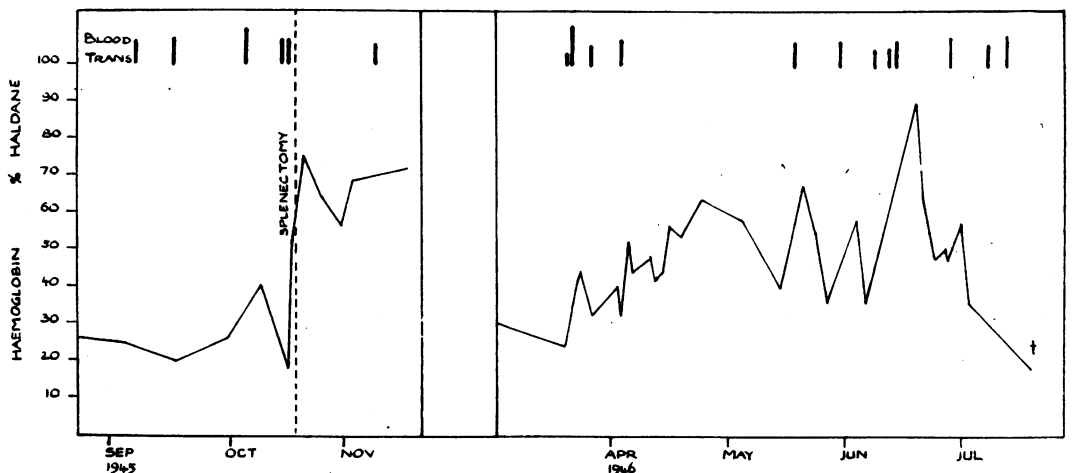


FIG. 5.—Acquired haemolytic anaemia of unknown cause in a woman aged 57. Erythrocyte fragility 0.55-0.45% NaCl. Splenectomy was followed by remission, but fatal relapse occurred.

followed by a rise in the platelet count and by relief of the haemorrhagic symptoms. The relation of thrombocytopenia to the haemorrhagic tendency is as yet an unsolved problem, but it is true to say that a reduction in platelets below 100,000 per c.mm. is usually attended by spontaneous haemorrhages, which as a rule cease when the platelet count rises to normal levels.

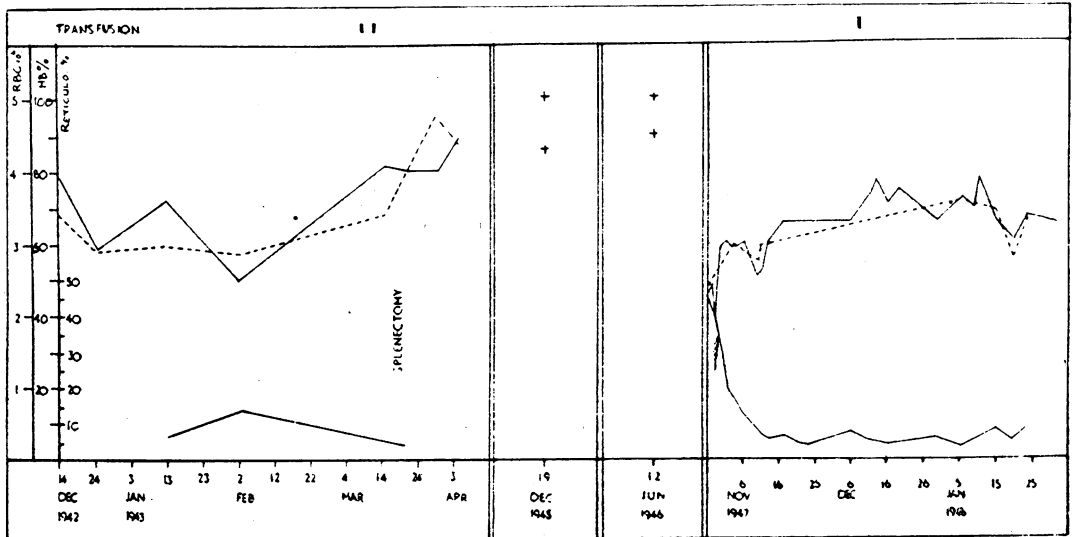


FIG. 6.—Hodgkin's disease with haemolytic anaemia in a boy aged 14.

The part played by the spleen in idiopathic thrombocytopenic purpura has been the subject of much debate and there are still two opposed doctrines—the one holding that this organ is engaged in excessive destruction of platelets, the other that it exerts an inhibitory effect on platelet formation in the bone marrow.

Injections into animals of extracts of spleens excised in this disease have an inconstant effect in inducing thrombocytopenia; the observations are inconclusive (Troland and Lee, 1938; Tocantins, 1939; Major and Weber, 1939; Pohle and Meyer, 1939; Hobson and Witts, 1940; Rose and Boyer, 1941). Histological evidence of excessive platelet destruction in the excised spleens is usually lacking, although there are claims to the contrary (Nickerson and Sunderland, 1937).

Thrombocytopenia may occur independently of the spleen's action: in acute leukaemia, aplastic anaemia, and carcinomatosis of bone it is secondary to changes in the bone marrow; it may be allergic in origin (Squier and Madison, 1937); it may be the result of idiosyncrasy to such drugs as "sedormid," gold, or arsphenamine. Precise diagnosis is clearly an essential preliminary to splenectomy. Examination of the bone marrow will exclude leukaemia and similar conditions. Schwartz (1945) has claimed that an increase in marrow eosinophils is associated with a particular tendency to spontaneous remission and has suggested that these cases have an allergic origin. His claims lack confirmation (Diggs and Hewlett, 1948), and the diagnosis of allergic thrombocytopenia must remain a matter of diffi-

culty; it is undoubtedly rare. A careful history will allow separation of the cases due to drug idiosyncrasy.

Bone marrow examination has a more positive value in the diagnosis of splenic thrombocytopenia: in this condition the megakaryocytes, the parent cells of the platelets, are plentiful, although it is uncertain whether they are more abundant than normal (Dameshek and Miller, 1946; Diggs and Hewlett, 1948). Although numerous, they are less mature than normal and show little or no evidence of active platelet formation. Within twenty-four hours of splenectomy, coincident with the thrombocytosis in the blood, the megakaryocytes show a great increase in platelet formation and in maturity. These observations seem to indicate an inhibitory effect of the spleen on thrombocytopoiesis and to dispose of the hypothesis of excessive splenic destruction of platelets.

Granted the clinical picture of idiopathic thrombocytopenic purpura and the absence of other possible cause, splenectomy is indicated when there is no sign of spontaneous remission and when the bone-marrow examination shows plentiful megakaryocytes but depressed platelet formation.

Two recent cases (Fig. 9) illustrate the satisfactory increase in platelet count that may be expected if these criteria are observed, but they stress another difficulty in the treatment of this disorder. Case 1 was relieved of all tendency to bleed and has remained well for over a year; in Case 2 there has been no change in the haemorrhagic state.

In addition to the familiar primary splenic thrombocytopenia, a similar condition may occur secondary to splenomegaly of many kinds: it has been noted, for example, in Hodgkin's disease, Gaucher's disease, congestive splenomegaly, and reticulosarcoma. The changes in the bone marrow are identical with those of the "primary" variety. In some instances the haemorrhagic state is of such intensity that it constitutes the main disability. In such circumstances it may be justifiable to recommend splenectomy, for it will often ensure additional months or years of comfortable existence, although it cannot of course influence the final outcome of the underlying disorder.

Fig. 10 shows the effect of splenectomy on the platelet count in two examples of this secondary type of hypersplenic thrombocytopenia. The cause of splenic enlargement was lymphoid follicular reticulosis and lymphoblastic reticulosarcoma respectively; a similar result has been obtained in a patient with Hodgkin's disease. In all three a disabling haemorrhagic state was satisfactorily controlled.

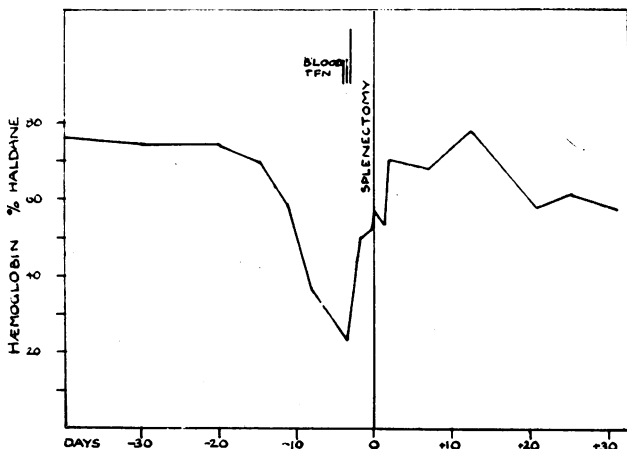


FIG. 7.—Haemolytic anaemia secondary to reticulosarcoma of the spleen in a woman aged 58. Splenectomy: remission.

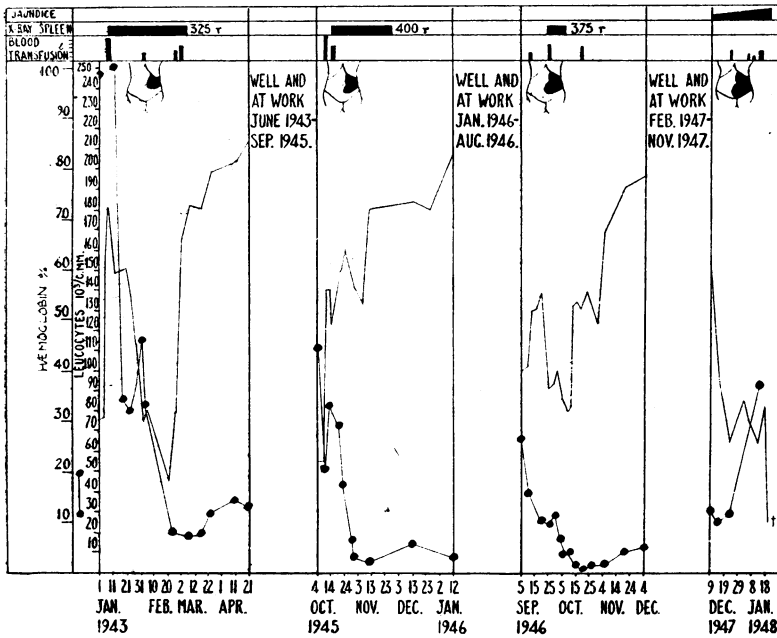


FIG. 8.—Haemolytic anaemia associated with chronic lymphoid leukaemia in a man aged 57.

In the past there has been tacit assumption that thrombocytopenia following medication with such drugs as gold, nearsphenamine, and the sulphonamides was due to a direct toxic effect on the bone marrow. The bleeding tendency usually disappears after the drug is withdrawn, but in two recently reported instances, one following gold (Mettier, McBride, and Li, 1948) and one sulphathiazole (Farfel, 1944-5), it persisted and endangered life. In both, the bone marrow was found to contain megakaryocytes in normal or increased numbers, although they were inactive and less mature than normal; in both, splenectomy was followed by a rise in the platelet count to normal and by cessation of bleeding. It may be that removal of the physiological splenic inhibition of thrombopoiesis was enough to restore platelet formation to normal.

**Splenectomy in Neutropenia**

The effects of the spleen on the leucocytes are less well appreciated than those on the red blood cells and platelets. Frank (1916, 1917) noted a leucopenia in many patients with splenomegaly and the increase in white blood cells

which followed splenectomy. He suggested that the spleen exerted a toxic effect on the bone marrow, which might result in aplasia when it became intense, and proposed the term "aleukia splenica" for the condition.

As in splenic thrombocytopenia, two forms of splenic neutropenia can be recognized. Although the first case was reported by Reissman (1938), Wiseman and Doan (1939, 1942) must be credited with recognition of the primary syndrome. This occurs most commonly in women between the ages of 30 and 60 years, and is manifest by chronic ill-health with recurrent skin and oral infections. The spleen is usually moderately, sometimes greatly, enlarged. Blood counts show persistent leucopenia, commonly varying between 1,000 and 2,000 per c.cm., with less than 20% of neutrophils; in many there is a moderate thrombocytopenia. The bone marrow is of increased cellularity, and formation of granular cells is unduly active, although mature forms may be scanty.

In many instances splenectomy has been followed by restoration of a normal leucocyte count and disappearance of all symptoms (Muether, Moore, Stewart, and Broun, 1941; Auger, Jobin, and Larochelle, 1945; Langston, White, and Ashley, 1945; Rogers and Hall, 1945; Salzer, Ransohoff, and Blatt, 1945; Hepp and Mallarmé, 1946; Kinsey and Bingham, 1946; Lotz, 1947). In this disorder again there is controversy over the means by which the spleen exerts its effect. Some hold that there is excessive lysis of neutrophils in the organ (Wiseman and Doan, 1939; von Haam and Awany, 1948), describing phagocytosis of granular cells in sections and smears of the

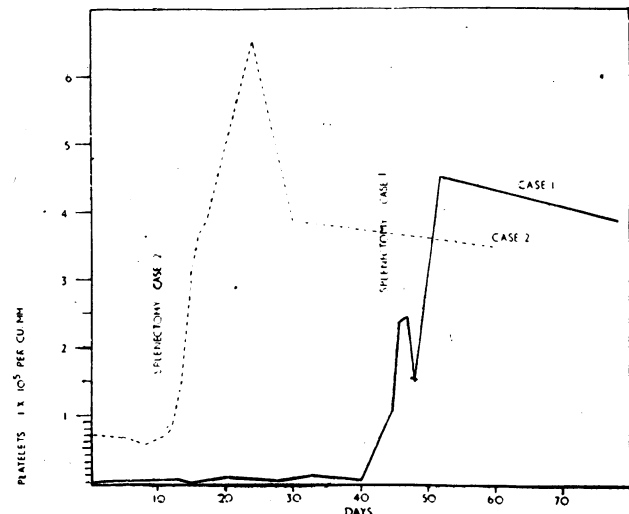
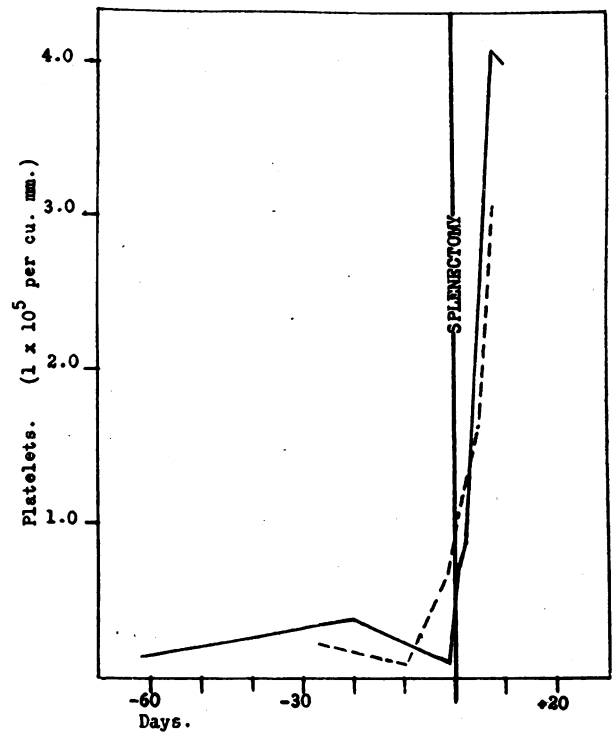


FIG. 9.—Effect of splenectomy in idiopathic thrombocytopenic purpura.



Male, 33 yrs., Lymphoid Follicular Reticulosis: - - - - -  
Female, 52 yrs., Lymphoblastic Reticulosarcoma: ———

FIG. 10.—Effect of splenectomy on platelet count in two cases of thrombocytopenic purpura due to secondary hypersplenism.

excised spleen. Many have reported non-specific hyperplasia of the organ without evidence of phagocytosis; perhaps the body of opinion favours the view that the spleen controls in some fashion the emission of granulocytes from the bone marrow (Engelbreth-Holm, 1938).

A recently reported instance, which can be matched by a personal experience, illustrates the need for caution (Hattersley, 1947). Both fulfilled all the diagnostic criteria of Wiseman and Doan, but in neither did splenectomy relieve the neutropenia or the tendency to infection.

Secondary splenic neutropenia as an isolated phenomenon is rarer than the analogous thrombocytopenia. It has been most often recorded in Felty's syndrome, wherein rheumatoid arthritis is associated with generalized lymphadenopathy and splenomegaly. Splenectomy has been advocated for this combination (Hanrahan and Miller, 1932; Craven, 1934), but, although the neutropenia is thereby relieved and general health may be improved, the arthritis is seldom affected (Steinberg, 1942). It is justifiable only when disabling symptoms can be attributed to the leucopenia. The operation has even been recommended for rheumatoid arthritis without splenomegaly or leucopenia; it has the support neither of logic nor of experience.

#### Splenectomy in Pancytopenia

It is not surprising to find that in some instances the action of the spleen is exerted not on one variety of blood cell but on all; in these patients there is anaemia, neutropenia, and thrombocytopenia. The syndrome has been given the title of "splenic pancytopenia" (Doan and Wright, 1946, 1947). Two distinct forms of anaemia are encountered in this disorder: in some it is frankly haemolytic, with jaundice, reticulocytosis, and urobilinuria; more often there is little unequivocal evidence of blood destruction, although the daily excretion of urobilinogen is usually above normal. The bone marrow in splenic pancytopenia is of increased cellularity: granulopoiesis is active and megakaryocytes are present in normal numbers, although thrombocytopoiesis is defective; erythropoiesis is normoblastic and unduly active in the haemolytic form of the disease, and in the non-haemolytic variety there is often a predominance of the less mature grades of normoblast, suggesting arrest of the normal process of maturation.

As with other hypersplenic syndromes, primary and secondary pancytopenia has been recognized. In most of the reported primary cases splenectomy has restored the blood to normal and the patient to health. The excised spleen is agreed by most observers to show no more than a non-specific hyperplasia. It is a rare disorder, but the following example is characteristic in all respects but the unhappy outcome.

A night watchman aged 55 was admitted with symptoms of anaemia and with splenomegaly. There was a normocytic anaemia with a haemoglobin level of 50% (Haldane); leucocytes numbered 2,000 per c.mm., of which 32% were neutrophils; platelets totalled 77,000 per c.mm. There was no evidence of excessive haemolysis. Sternal puncture showed an active bone marrow. Splenectomy resulted in a rapid rise of leucocytes to 14,500 and of platelets to 368,000 per c.mm. The spleen showed a non-specific hyperplasia; the liver was normal at operation and on biopsy. Unfortunately he died on the tenth day after operation from a secondary haemorrhage from the wound.

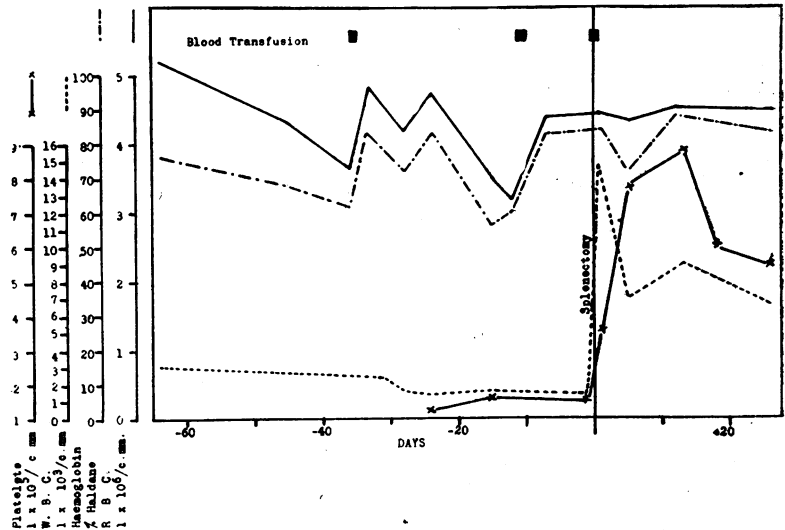


FIG. 11.—Splenectomy in secondary splenic pancytopenia in a woman aged 34. Reticulum-cell medullary reticulosis.

Secondary splenic pancytopenia is not uncommon in its minor grades: it is the rule in congestive splenomegaly and occurs with many other forms of splenic enlargement. It does not often justify splenectomy, although satisfactory results have been reported in Gaucher's disease (Mandelbaum, Berger, and Lederer, 1942). The blood changes in kala-azar can best be explained by secondary hypersplenism of this type (Cartwright, Chung, and Chang, 1948), and, although chemotherapy will usually effect a cure, cases resistant to treatment and sometimes associated with a haemolytic anaemia occur. Several recent reports have stressed the value of splenectomy in such patients (Burchenal, Bowers, and Haedicke, 1947; Morton and Cooke, 1948).

In some of the less common proliferative diseases of lympho-reticular tissue secondary splenic pancytopenia is a prominent feature. This is so in histiocytic medullary reticulosis (Bodley Scott and Robb-Smith, 1939), and in one instance a satisfactory remission of some months was secured by splenectomy (Asher, 1946). A recent example of a related condition has responded in like manner.

A married woman aged 34 was admitted with massive splenomegaly and moderate generalized lymphadenopathy. There was thrombocytopenia, neutropenia, and normocytic anaemia without evidence of undue haemolysis. The bone marrow was active. Remittent fever was present. An excised lymph node showed the changes of reticulum-cell medullary reticulosis. The radiotherapist was unwilling to treat her in view of the leucopenia. Splenectomy restored the blood picture to normal and relieved all symptoms. She remains well three months after the operation (Fig. 11).

This mechanism has recently been suggested as the explanation of the puzzling crises of acholuric jaundice (Dameshek and Bloom, 1948). It has long been known that in these "crises de déglobulisation" there is profound anaemia without reticulocytosis but accompanied by thrombocytopenia and leucopenia. The bone marrow may show changes suggesting an arrest of erythroblastic development while granular cells are prominent and megakaryocytes numerous but inactive. Splenectomy at this point is followed not only by rapid repair of the anaemia but by release of granular cells and platelets. The hypothesis that the enlarged spleen, as well as destroying the spherical red blood cells, is exerting a secondary inhibitory effect on bone-marrow function satisfactorily explains this puzzling phenomenon.

The indications for splenectomy in aplastic, or refractory, anaemia are relevant to the topic of splenic pancytopenia if it is allowed that the spleen normally exerts an inhibitory influence on haemopoiesis. The operation has been recommended from time to time for this disease and occasional successes have been recorded. It is the general experience that results are disappointing and the benefit only transient (van Beurden, 1935). The Italian haematologists have recognized an indolent form of aplastic anaemia which they term "progressive myeloid atrophy" (Ferrata, 1939a, 1939b; Cattaneo, 1942, 1946). Its distinction from other forms seems to depend on the speed of its evolution, but good results have been reported from splenectomy in some patients. Occasional examples are seen in which a haemolytic element is clearly present, and this constitutes an indication for operation; some would extend it to those whose bone marrow contains megakaryocytes, especially if they are inactive, and shows some evidence of erythroblastic regeneration (Estren and Dameshek, 1947).

### Splenectomy in Congestive Splenomegaly

The problem of splenectomy in congestive splenomegaly (Banti's syndrome) is of a different order. Observations at the Presbyterian Hospital in New York have shown that the splenomegaly is here due to obstruction to the venous outflow from the organ (Whipple, 1937, 1945; Rousselot, 1940; Thompson, 1940). It is in fact synonymous with obstruction to, and hypertension in, the portal venous system, apart from occasional examples due to thrombosis of the splenic vein. In 70% the cause is cirrhosis of the liver; in the remainder various extrahepatic obstructive lesions are present. The main danger lies in the tendency to rupture of the dilated venous collaterals at the lower end of the oesophagus.

It has already been pointed out that secondary hypersplenism is common in congestive splenomegaly, but it is seldom of a degree to demand operation. Splenectomy is curative in thrombosis of the splenic vein, but where the obstruction is of the portal trunk or its branches within the liver this operation has little effect on portal hypertension. The improvement occasionally noted must be attributed to the relief of secondary hypersplenism, and perhaps to the removal of the splenic contribution to the portal blood flow, which is said to amount to 40% of the total. Splenectomy cannot be regarded as a rational or effective treatment for congestive splenomegaly, unless due to thrombosis of the splenic vein. The operations devised to by-pass the obstruction by shunting the venous flow via the splenic vein into the left renal vein, or by anastomosing the portal vein and the inferior vena cava, are more logical and more promising (Blakemore and Lord, 1945; Learmonth and Macpherson, 1948).

### Conclusion

This review has attempted to show that, with the exception of two mechanical disturbances—rupture and thrombosis of the splenic vein—the indication for splenectomy is an imbalance of the delicately poised equilibrium between the haemopoietic functions of the bone marrow and the inhibitory and haemolytic activities of the spleen. This may arise from a primary splenic disorder or be secondary to many forms of splenomegaly; it may be due to hypoplasia of the bone marrow or to the production of malformed red blood cells; it may affect the erythrocytes, the granular cells, or the platelets, severally or concurrently. In every variety splenectomy may restore the blood to normal and the patient to health.

I am grateful to my colleagues at St. Bartholomew's Hospital for permission to refer to patients who have been under their care.

### REFERENCES

- Asher, R. (1946). *Lancet*, **1**, 650.  
 Atlee, W. (1932). *Ibid.*, **1**, 291.  
 Auger, C., Jobin, J. B., and Larochelle, L. N. (1945). *Canad. med. Ass. J.*, **53**, 335.  
 Barcroft, J. (1925). *Lancet*, **1**, 319.  
 Bensus, V., and Gouttas, A. (1934). *Sang.*, **8**, 288.  
 Blakemore, A. H., and Lord, J. W. (1945). *Ann. Surg.*, **122**, 476.  
 Burchenal, J. H., Bowers, R. F., and Haedicke, T. A. (1947). *Amer. J. trop. Med.*, **27**, 699.  
 Cartwright, G. E., Chung, H. L., and Chang, A. (1948). *Blood*, **3**, 249.  
 Cattaneo, A. (1942). *Haematologica*, **24**, 995.  
 — (1946). *Gazz. Osp. Clin.*, **67**, 139.  
 Coombs, R. R. A., Mourant, A. E., and Race, R. R. (1945). *Brit. J. exp. Path.*, **26**, 255.  
 Crane, A. R., and Zetlin, A. M. (1945). *Ann. intern. Med.*, **23**, 882.  
 Craven, E. B. (1934). *J. Amer. med. Ass.*, **102**, 823.  
 Dameshek, W., and Bloom, M. L. (1948). *Blood*, **3**, 1381.  
 — and Miller, E. B. (1943). *Arch. intern. Med.*, **72**, 1.  
 — (1946). *Blood*, **1**, 27.  
 — and Schwartz, S. O. (1938). *New. Engl. J. Med.*, **218**, 75.  
 — (1940). *Medicine*, **19**, 231.  
 Darley, W., Black, W. C., Smith, C., and Good, F. A. (1944). *Amer. J. med. Sci.*, **208**, 381.  
 Davis, J. S., Macfee, W., Wright, M., and Allyn, R. (1945). *Lancet*, **2**, 72.  
 Diggs, L. W., and Hewlett, J. S. (1948). *Blood*, **3**, 1090.  
 Doan, C. A., and Wright, C. S. (1946). *Ibid.*, **1**, 10.  
 — (1947). *J. Lab. clin. Med.*, **32**, 1399.  
 Engelbreth-Holm, J. (1938). *Amer. J. med. Sci.*, **195**, 32.  
 Eppinger, H. (1920). *Die Hepato-Lienalen Erkrankungen*. Berlin.  
 Estren, S., and Dameshek, W. (1947). *Amer. J. Dis. Child.*, **73**, 671.  
 Farfel, B. (1944-5). *Texas St. J. Med.*, **40**, 603.  
 Feldman, F., and Yarvis, J. J. (1944). *N.Y. St. J. Med.*, **44**, 1693.  
 Ferrata, A. (1939a). *Gazz. Osp. Clin.*, **60**, 219.  
 — (1939b). *Ibid.*, **60**, 415.  
 Frank, E. (1916). *Berl. klin. Wschr.*, **53**, 555.  
 — (1917). *Ibid.*, **54**, 573.  
 Govan, C. D. (1946). *J. Pediat.*, **29**, 504.  
 Hanrahan, E. M., and Miller, S. R. (1932). *J. Amer. med. Ass.*, **99**, 1247.  
 Hattersley, P. G. (1947). *Blood*, **2**, 227.  
 Hepp, J., and Mallarmé, J. (1946). *Mém. Acad. Chir., Paris*, **72**, 359.  
 Hobson, F. C. G., and Witts, L. J. (1940). *British Medical Journal*, **1**, 50.  
 Holler, G., and Paschke, K. (1927). *Wien. Arch. inn. Med.*, **14**, 149.  
 King, R. B. (1941). *New. Engl. J. Med.*, **224**, 1058.  
 Kinsey, H. I., and Bingham, J. R. (1946). *Canad. med. Ass. J.*, **55**, 291.  
 Knisely, M. H. (1934-5). *Proc. Soc. exp. Biol., N.Y.*, **32**, 212.  
 — (1936). *Anat. Rec.*, **65**, 23.  
 Kwaszewska, G. (1931). *Wien. klin. Wschr.*, **44**, 684.  
 Langston, W., White, O. A., and Ashley, J. D., jun. (1945). *Ann. intern. Med.*, **23**, 667.  
 Learmonth, J. R., and Macpherson, A. I. S. (1948). *Lancet*, **2**, 882.  
 Leeuwenhoek, A. van (1708). *Philos. Trans.*, **25**, 2305.  
 Lotz, K. (1947). *Med. Klin.*, **42**, 274.  
 McFadzean, A. J. S., and Davis, L. J. (1947). *Glasg. med. J.*, **28**, 237.  
 MacKenzie, D. W., jun., Whipple, A. O., and Wintersteiner, M. P. (1941). *Amer. J. Anat.*, **68**, 397.  
 McNee, J. W. (1931). *Trans. med. Soc. Lond.*, **54**, 185.  
 Major, R. H., and Weber, C. J. (1939). *J. Lab. clin. Med.*, **25**, 10.  
 Mandelbaum, H., Berger, L., and Lederer, M. (1942). *Ann. intern. Med.*, **16**, 438.  
 Marchal, G., Dany, H., and Grupper (1934). *Sang.*, **8**, 847.  
 Mettier, S. R., McBride, A., and Li, J. (1948). *Blood*, **3**, 1105.  
 Morton, T. C., and Cooke, J. N. C. (1948). *Lancet*, **2**, 920.  
 Muether, R. O., Moore, L. T., Stewart, J. W., and Broun, G. O. (1941). *J. Amer. med. Ass.*, **116**, 2255.  
 Naegeli, O. (1940). *Differential Diagnosis of Internal Diseases*. Chicago.  
 Nickerson, D. A., and Sunderland, D. A. (1937). *Amer. J. Path.*, **13**, 463.  
 Pohle, F. J., and Meyer, O. O. (1939). *J. clin. Invest.*, **18**, 537.  
 Reissmann, K. (1938). *Med. Welt.*, **12**, 16.  
 Rogers, H. M., and Hall, B. E. (1945). *Arch. intern. Med.*, **75**, 192.  
 Rose, H., jun., and Boyer, L. B. (1941). *J. clin. Invest.*, **20**, 81.  
 Rousselot, L. M. (1940). *Surgery*, **8**, 34.  
 Salzer, M., Ransohoff, J. L., and Blatt, H. (1945). *Ann. intern. Med.*, **22**, 271.  
 Schwartz, S. O. (1945). *Amer. J. med. Sci.*, **209**, 579.  
 Scott, R. B., and Robb-Smith, A. H. T. (1939). *Lancet*, **2**, 194.  
 Singer, K., and Dameshek, W. (1941). *Ann. intern. Med.*, **15**, 544.  
 — Miller, E. B., and Dameshek, W. (1941). *Amer. J. med. Sci.*, **202**, 171.  
 Slot, W. J. Bruins (1938). *Ned. Tijdschr. Geneesk.*, **82**, 38.  
 Smith, E. B., and Custer, R. P. (1946). *Blood*, **1**, 317.  
 Squier, T. L., and Madison, F. W. (1937). *J. Allergy*, **8**, 143.  
 Stats, D., Rosenthal, N., and Wasserman, L. R. (1947). *Amer. J. clin. Path.*, **17**, 585.  
 Steinberg, C. L. (1942). *Ann. intern. Med.*, **17**, 26.  
 Thompson, W. P. (1940). *Ibid.*, **14**, 255.  
 Tocantins, L. M. (1939). *Proc. Soc. exp. Biol., N.Y.*, **42**, 485.  
 Troland, C. E., and Lee, F. C. (1938). *J. Amer. med. Ass.*, **111**, 221.  
 Van Beurden, A. J. R. E. Scoonhoven (1935). *Folia haemat., Lpz.*, **53**, 135.



- Von Braitenberg, H. (1937-8). *Frankfurt. Z. Path.*, **51**, 515.  
 Von Haam, E., and Awmy, A. J. (1948). *Amer. J. clin. Path.*,  
**18**, 313.  
 Whipple, A. O. (1937). *Surg. Gynec. Obstet.*, **64**, 296.  
 — (1945). *Ann. Surg.*, **122**, 449.  
 Wiseman, B. K., and Doan, C. A. (1939). *J. clin. Invest.*, **18**, 473.  
 — (1942). *Ann. intern. Med.*, **16**, 1097.

## AN OPERATION FOR THE TREATMENT OF STRESS INCONTINENCE

BY

WILFRED SHAW, M.D., F.R.C.S., F.R.C.O.G.

Surgeon in Charge, Obstetrical and Gynaecological  
 Department, St. Bartholomew's Hospital; Gynaecologist,  
 St. Andrew's Hospital, Dollis Hill

Although most cases of stress incontinence are seen in patients who have sustained injury during childbirth, the condition is by no means uncommon in nulliparae and even in young women. Clinically, in the average case the external meatus is patulous and the urethra is prolapsed downwards and forwards, with the result that the external meatus lies below and behind its normal situation.

### Anatomical Considerations

Much work has been done by Curtis *et al.* (1939, 1942), and by Von Lüdinghausen (1932), Kalischer (1900), Andina and Hintzche (1946), in particular. The plain muscle sphincter round the internal meatus consists of two series of loops. In one of these, muscle fibres pass behind the internal meatus with the arms of the loops extending upwards and forwards. The other loop passes in front of the meatus with its arms extending posteriorly and with each arm being pierced by the ureter. There is a tendency to describe this sphincter muscle as the "lisso sphincter."

The striated muscle sphincter of the urethra, which is also known as the sphincter urethrae, the urogenital sphincter, and, more recently, as the "rhabdo sphincter," is much more complicated. Some of its fibres pass circularly round the urethra. Other fibres pass from an attachment to the back of the symphysis pubis area backwards to form a loop posteriorly round the urethra. A third group of fibres are looped in front of the urethra and then pass backwards laterally, to be attached to the lateral wall of the vagina. In another group the fibres are looped in front of the urethra to interlace between the urethra and vagina and subsequently merge into the vaginal wall.

There is some evidence that those cases of stress incontinence which develop after anterior colporrhaphy are caused by the division of the nerves which supply the urethral sphincter. My own view of the aetiology of stress incontinence is that most cases are due primarily to damage or to loss of tone of the condensation of endopelvic fascia which lies between the urethra and the anterior vaginal wall, which I have called the post-urethral ligament. This condensation consists of plain muscle tissue and is attached to the pubic rami on each side and to the neck of the bladder above. It forms a firm supporting shelf of tissue. The ligament cannot be displayed at operation except in cases of cystocele of slight degree, for if any form of prolapse of the anterior vaginal wall is well marked the tissues of the ligament are inconspicuous. It is because of this weakness of the ligament that the prolapse develops. In my view the main cause of stress incontinence is weakness of this ligament, although damage to the urethral sphincter or to its nerve supply is a contributory factor. The radiographic findings of downward displacement of the urethra and the neck of the bladder in cases of stress incontinence can be explained in this way.

### Surgical Methods

Surgical treatment by the vaginal route has the object of forming a shelf of the para-urethral tissues beneath the urethra, and numerous modifications of this technique are employed. Kelly's method of introducing mattress sutures into the neck of the bladder gives moderately good results. It is well known that stress incontinence is usually cured if prolapse is treated by vaginal hysterectomy or by the modern modifications of the Fothergill operation.

It is also well known that the vaginal methods are not always successful, and various sling methods have been employed. Stoeckel's modification of Goebel's method, in which longitudinal strips of rectus fascia were brought down behind the symphysis and sutured together below the urethra, did not give satisfactory results. I learnt the method in Vienna some years ago, but the clinical results were unsatisfactory. In 1942 Aldridge employed a method of bringing down transverse strips of fascia taken from the aponeurosis of the oblique abdominal muscles. Millin (1947) introduced a method whereby the operation is performed retropubically, and modifications have been described by Millin and Read (1948), Marshall (1948), and others. Studdiford (1944, 1945) has described modifications of Aldridge's technique. These sling operations are being performed extensively at the present day, and good results are being reported.

In the latter part of 1947 it occurred to me that the problem could be approached in another way, and the idea behind the method which is described below is to replace the weakened post-urethral ligament by a strip of fascia lata taken from the thigh. A preliminary report has already been published (Shaw, 1949).

*Selection of Clinical Material.*—A very large number of patients suffering from stress incontinence attend the out-patient department of St. Bartholomew's Hospital. It is important to select cases with care, for urgency and frequency of micturition must be distinguished from stress incontinence. The patient should be made to cough when her bladder contains urine, and if the urine can be seen to be discharged from the meatus when the patient coughs stress incontinence is diagnosed. It is also important to exclude neurological causes, and in doubtful cases the patient is referred to a neurologist. Many of the patients have been operated upon on several previous occasions by the vaginal route, and these failures are considered to be particularly suitable for the operation.

### Technique

#### Method of Obtaining the Fascial Strip

The patient lies on her left side with the right knee flexed. An incision 7 in. (17.5 cm.) long is made from the lateral epicondyle of the femur, and the fascia lata is exposed by dissecting the fatty tissues from the fascia. A strip of fascia lata is then taken, not less than 6 in. (15 cm.) and not more than 7 in. long. It is shaped so that it is  $1\frac{1}{2}$  in. (3.75 cm.) in diameter in the middle and decreases at each end to a diameter of  $\frac{1}{2}$  in. (0.8 cm.) (Fig. 1). The fascial strip is placed upon a gauze pad soaked in warm saline, and the cut edges of the fascia lata are brought together by means of three mattress sutures followed by a long continuous suture. The skin incision is closed with clips. As a general rule

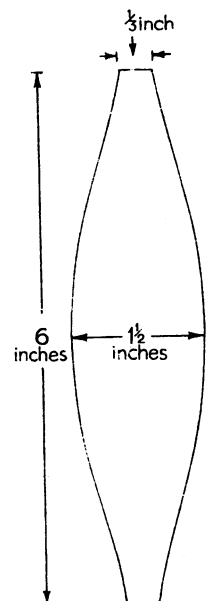


FIG. 1.—The strip of fascia taken from the fascia lata is  $1\frac{1}{2}$  in. broad in the middle, tapering to each end, and is 6 in. long.