

## PITUITARY DESTRUCTION BY INJECTION OF RADIOACTIVE SUBSTANCE AND SECTION OF THE PITUITARY STALK FOR ADVANCED CANCER

F. L. DAVIES AND P. H. BUXTON

*From the Neurosurgical Unit and the Bland-Sutton Institute of Pathology, Middlesex Hospital, London, W.1.*

Received for publication January 30, 1957

TRANSFRONTAL hypophysectomy is an established surgical procedure in the treatment of advanced cancer. Results of this operation have been reported by Perrault, Le Beau, Klotz, Sicard and Clavel (1952), Shimkin, Boldrey, Kelly, Beirman, Ortega and Naffziger (1952), Luft and Olivecrona (1953) and by Pearson Ray, Harrold, West, Li, Maclean and Lipsett (1956).

Luft and Olivecrona (1953) performed hypophysectomy in 15 cases of malignant disease. Twelve cases suffered from carcinoma of the breast, one from chorion carcinoma, one from carcinoma of the kidney, and one from carcinoma of the prostate. They showed that when hypophysectomy is complete a remarkable regression of the carcinoma may occur in cases of metastatic breast cancer. There were no operative deaths in this series.

Pearson *et al.* (1956) have reported a series of 79 patients with advanced malignant disease on whom hypophysectomy had been performed from 1953–55. There were 11 operative deaths in the whole series. Forty-one patients with metastatic breast cancer could be evaluated and 21 of these obtained objective remission.

All the available evidence indicates that only those cases of breast cancer which are hormone dependent benefit from removal of the pituitary. The present difficulty in selecting patients with breast cancer for operation is to determine those whose growths are in fact hormone dependent.

Two possible tests are available. In one (Pearson *et al.*, 1956) oestrogens are given and the effect on the mammary cancer noted, an increase in activity indicates that the growth is influenced by oestrogens and that hypophysectomy might be of value. The second test is the estimation of the mammatrophins in the urine (Hadfield, 1956). Further work on these methods is awaited with interest. It should be noted however that while patients who have had a favourable response to oophorectomy or to androgen therapy are likely to have a favourable response to hypophysectomy, failure to respond to androgen or oestrogen therapy does not necessarily mean that the patient will fail to respond to hypophysectomy.

In view of the reported results of hypophysectomy in advanced cancer, it was decided to attempt to destroy the pituitary gland by local irradiation in cases of malignant disease where the tumour was likely to be hormone dependent. Chromic phosphate was injected into the gland, the phosphorus being in the form of the radioactive isotope  $P^{32}$ . This method was described by Rothenberg, Jaffe, Putnam and Simkin (1955). It appeared a less severe procedure than hypophysectomy in a seriously ill patient.

Radioactive colloidal chromic phosphate seemed theoretically an ideal substance for pituitary ablation by radiation. It is precipitated upon injection and

remains at the injection site ;  $P^{32}$  emits beta radiation only with a maximum effective penetration of 0.8 mm. in body tissue ; it has a half-life of 14 days which is very convenient when planning the operation. Radioactive gold does not remain at the injection site and it has a half-life of  $3\frac{1}{2}$  days, thus like radioactive yttrium (half-life 61 hours), it has to be obtained immediately before operation to get a sufficiently high dose of radioactive substance in a small volume of the injection material.

*Pituitary Destruction by Injection of Radioactive Chromic Phosphate*

Between October 1955 and June 1956, 5 cases of advanced carcinoma of the breast with widespread metastases and 1 case of malignant melanoma with metastases were treated by injection of radioactive chromic phosphate into the pituitary gland. These 6 cases form Group I (Table I). The effectiveness of the procedure was assessed by endocrine and electrolyte changes.

TABLE I.—*Summary of Cases Treated for Advanced Carcinoma*

Group I

Cases treated by injection of radioactive chromic phosphate

Case	Age	Sex	Site of primary tumour	Post-operative survival
1	42	F.	Breast	Died at 7 weeks
2	28	"	Skin (malignant melanoma)	" " 26 "
3	36	"	Breast	" " 10 "
*4	47	"	"	" " 30 "
5	54	"	"	" " 29 "
6	40	"	"	" " 22 "

\* Stalk section carried out 23 weeks after injection.

Group II

Cases treated by injection of radioactive material, and section of pituitary stalk

Case	Age	Sex	Site of primary tumour	Post-operative survival
4	47	F.	Breast	Died at 30 weeks
7	50	"	"	" " 4 "
8	52	"	"	" " 9 days.

In Groups I and II operation produced no appreciable effect on the tumour.

Group III

Cases treated by section of the pituitary stalk

Case	Age	Sex	Site of primary tumour	Effect on tumour	Post-operative survival
9	57	F.	Breast	Relief of bone pain	Alive at 21 weeks.
10	58	"	"	" "	Died at 14 "
11	42	"	"	Regression of cutaneous and pleural deposits	Alive at 13 "
12	63	M.	Prostate	Marked fall in acid phosphatase	Alive at 12 "
13	46	F.	Breast	No change	Died at 10 "
14	42	"	"	" "	Alive at 5 "

### *Investigations*

The following tests of pituitary function were carried out before and after operation: estimation of the basal metabolic rate, the radioactive iodine uptake and excretion, the urinary 17 ketosteroids (17 KS) and glucocorticoids (17 OH). The change in excretion of the glucocorticoids was found to be of more significance than the change in the ketosteroids in assessment of adrenocortical function, as ketosteroid output is always low in seriously ill patients. A complete radiological survey was undertaken and estimations of the 24-hourly urinary calcium excretion were made. A full blood count was done and the blood urea, serum cholesterol, blood sugar, plasma proteins and electrophoretic pattern and serum electrolytes were estimated. The most helpful of all these tests were found to be the radioactive iodine uptake and excretion and the glucocorticoid estimation.

### *Operative procedure*

This has been previously described (Davies, 1956). In summary, a coronal scalp incision is made, the flap being turned down over the forehead and eyes. A trephine opening  $1\frac{1}{2}$ -in. diameter is made above the superior orbital ridge, the frontal lobe is elevated, the olfactory tract is cut and the pituitary stalk is seen below the optic chiasm. After injection of the radioactive material the bone disc is replaced and the scalp sutured in the usual way. The amount of radioactive material injected varied from 3–8 millicuries in 0.2–0.4 ml. of solution.

### *Post-operative complications*

All patients complained of headache and a feeling of fullness behind the eyes for a few days, aspirin or codeine tablets were sufficient for the relief of these symptoms. Somnolence was noted in all patients but in only 1, Case 6, was cortisone necessary for relief. One patient developed a temporary right temporal field defect which cleared up in 10 days. Another patient complained of mistiness of vision which disappeared in 14 days.

### *Results*

In the first 5 cases there was no clinical nor endocrine evidence of effective pituitary destruction. In Case 6 however there was profound disturbance soon after operation (Fig. 1). In this case there had been some haemorrhage in the pituitary region at operation and it was thought that the pituitary stalk might have been damaged whilst controlling this bleeding.

Autopsy was possible only in Case 2 of this group. Widespread tumour deposits were found in this case. The pituitary gland showed partial destruction of the epithelial elements (Fig. 2) but viable glandular tissue remained. The hypothalamus showed nodules of tumour cells but no gross parenchymal damage (Fig. 3, 4). The thyroid and suprarenals though extensively infiltrated by carcinoma showed no gross damage to secretory tissue.

In view of these findings and the absence of endocrine changes in life in the cases other than Case 6, it was decided to combine injection of radioactive chromic phosphate with deliberate destruction of the pituitary stalk. Three cases were treated in this manner and form Group II (Table I). Pre- and post-operative

investigations were done as before. The technique of the combined operation was as described above but after the gland had been injected the pituitary stalk was divided close to the gland and the ends cauterised. (Fig 5).

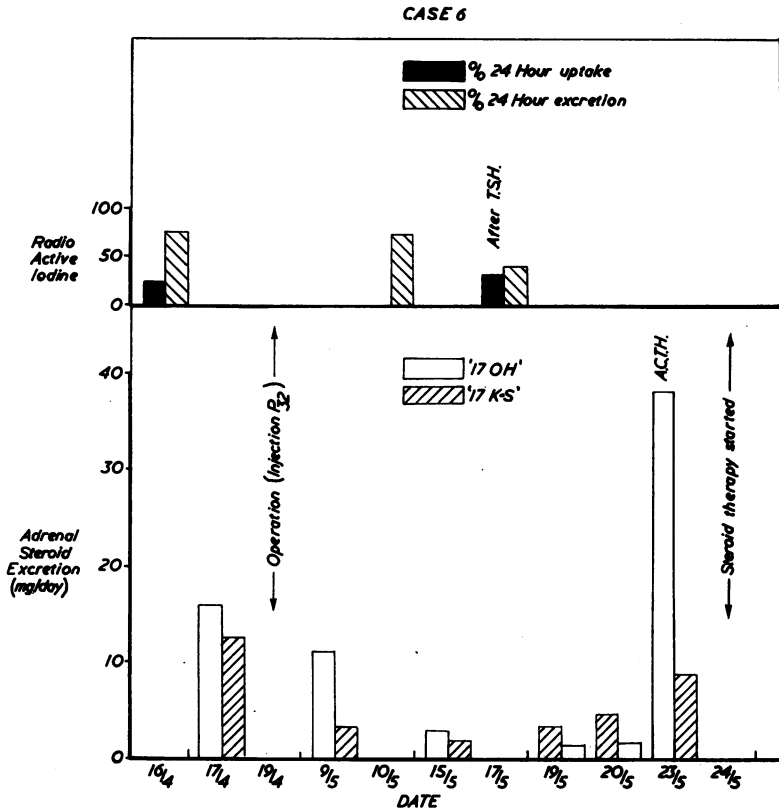


FIG. 1.—Case 6. Post-operative fall in radioactive iodine uptake and fall in “17 OH” excretion. Reversal of these changes after thyrotrophic and adrenotrophic hormone is also shown.

*Pituitary Destruction by Injection Combined with Stalk Section*

The first two cases treated by this combined method showed marked endocrine changes (Fig. 6). As Case 4, treated earlier by injection only, still showed no endocrine disturbance, nor was there any alleviation of symptoms from malignant disease, she was operated upon again and stalk section was performed. Immediately there were profound endocrine changes (Fig. 7). There was however no appreciable change in the patient’s extensive malignant disease, the local skin deposits practically surrounded the chest.

Autopsy was possible in Cases 7 and 8 treated by the combined method. In Case 7 gross pituitary destruction was found though a small island of viable epithelial cells remained (Fig. 8). The hypothalamus in this case showed very

marked parenchymal damage which was thought to be due to ascending thrombosis from the cauterised, divided pituitary stalk (Fig. 9). Small groups of tumour cells were also seen in the hypothalamus (Fig. 10). The thyroid showed no gross histological abnormality; the suprarenal glands had been removed previously. In Case 8, despite the marked endocrine changes found in life, autopsy showed only partial destruction of the pituitary epithelial tissue, no gross hypothalamic damage, but complete necrosis of the distal part of the pituitary stalk (Fig. 11). The thyroid and suprarenal cortex showed degenerative changes and extensive infiltration by carcinoma cells.

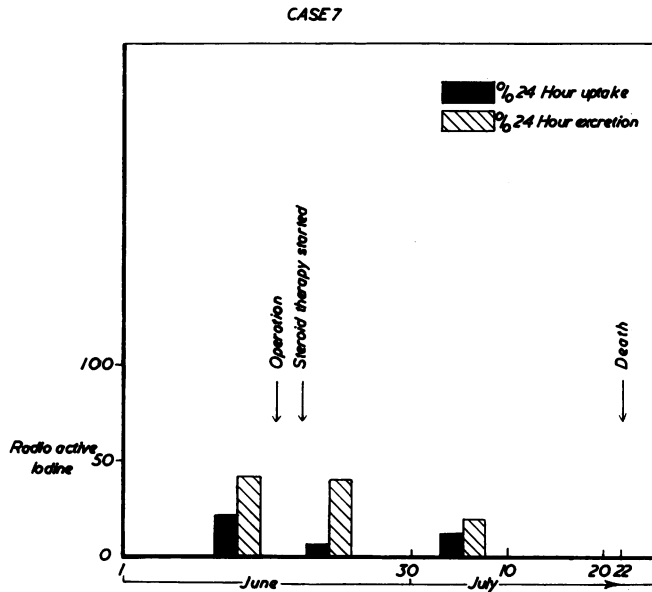


Fig. 6.—Case 7. To show post-operative fall in radioactive iodine uptake.

These results suggested that destruction of the pituitary stalk produced profound endocrine disturbance despite incomplete destruction of the pituitary glandular tissue, whereas incomplete destruction of the glandular tissue alone produced no such effect. It was therefore decided to treat the next group of cases by destruction of the pituitary stalk alone without injection of radioactive material. Support for this method of treatment was obtained by reference to the publication of Professor D. S. Russell in which the effects of dividing the pituitary stalk in man were discussed (Russell, 1956).

#### *Pituitary destruction by stalk section alone*

Six patients have been treated by section of the pituitary stalk alone, and form Group III (Table I). Five of these were cases of carcinoma of the breast, the other was a case of carcinoma of the prostate.

The pre- and post-operative investigations were similar to those employed in Groups I and II and the same operative technique was used.

*Post-operative progress*

In all cases of Group III there was immediate hypothermia which was followed in 12 hours by pyrexia of 100° to 102° F. which persisted for 48 hours. Somnolence, tachycardia, and hypotension developed within 12 hours, but were abolished by intravenous hydrocortisone. A maintenance oral dose of hydrocortisone was attained in 2 weeks. Case 14 was given pre-operative intramuscular cortisone and did not develop these symptoms.

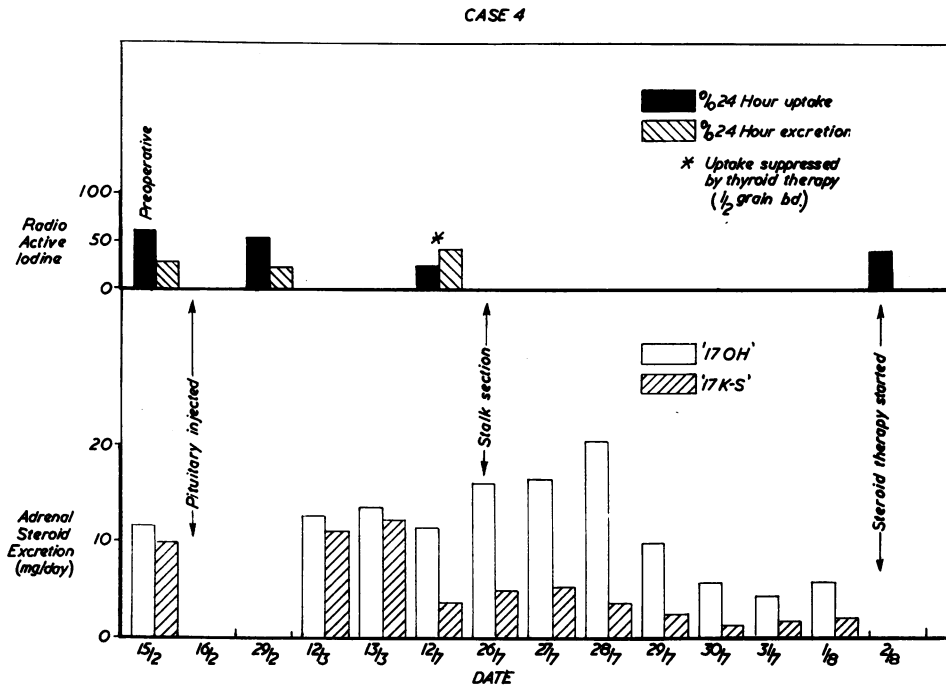


FIG. 7.—Case 4. To show post-operative fall in “17 OH” excretion and complete suppression of radioactive iodine uptake and excretion till start of steroid therapy.

Two patients had a generalised convulsion 7 days post-operatively, the fits were controlled by intramuscular phenobarbitone.

In 4 patients there was an immediate polyuria after operation which persisted until injections of pitressin tannate were given at weekly intervals.

Headache was present in all cases but usually disappeared completely in 4–5 days.

The radioactive iodine uptake was considerably reduced in all cases post-operatively. In 1 case this occurred as early as the third post-operative day. In Case 11 the  $I_{131}$  uptake fell from a pre-operative value of 43 per cent to 7 per cent while in Case 12 the values were 31 and 3 per cent respectively. The urinary 17 OH and 17 KS rapidly decreased in all cases post-operatively. Repre-

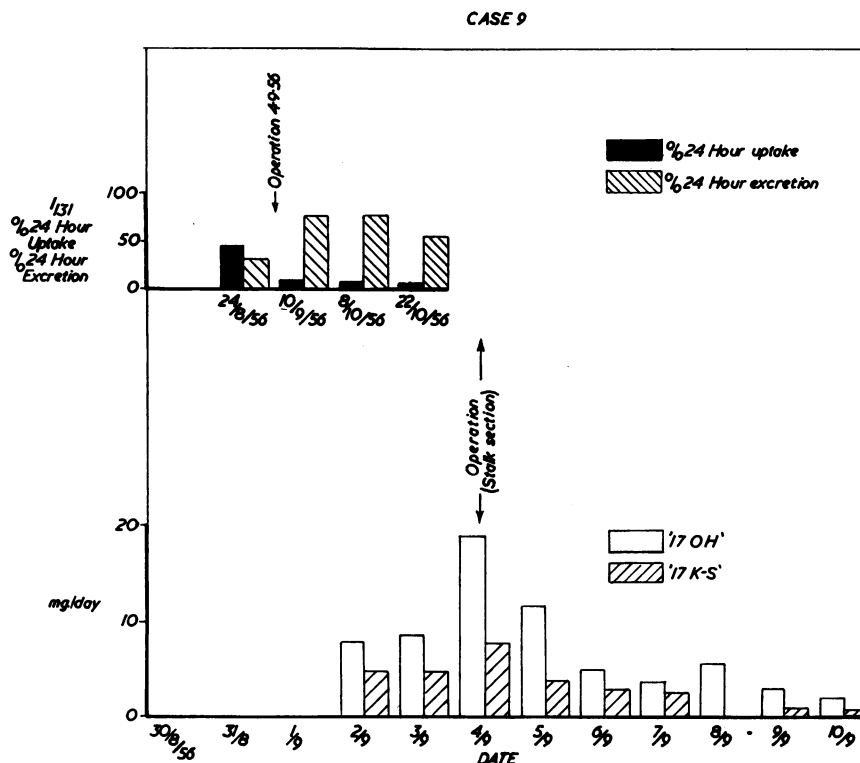


FIG. 12 (Case 9), FIG. 13 (Case 10).—To show post-operative fall in radioactive iodine uptake and steroid excretion.

sentative results of radioactive iodine and steroid excretion are shown in Fig. 12 and 13.

In Case 12, a man with skeletal metastases from prostatic carcinoma, the 24-hour urinary calcium excretions pre-operative values were 42, 52, 36, 42 mg. per 100 ml. The post-operative values were 14, 19 and 24 mg. per 100 ml. These figures suggested marked reduction in activity of the bony metastases. In this patient also there was a dramatic fall in the acid phosphatase after operation (Fig. 14).

Cases 9 and 10 had been bedridden with pathological fractures of the femora before operation. They were improved to the extent of being able to walk out of hospital after operation. In both these cases and in Case 12 there was marked relief of bone pain and subjective improvement, but despite this there were no changes in the radiological appearances of the skeleton.

Case 11 had multiple secondary deposits in the lung with a pleural effusion. She showed remarkable improvement after operation. Her pleural effusion which had required aspiration before operation did not recur; the lung deposits and the cutaneous metastases (Fig. 15) showed regression. There was no improvement in the cutaneous deposits in Case 14, 5 weeks after operation; Case 13 died 10 weeks after operation without change in her malignant disease.

All the cases in this group claimed marked improvement subjectively.

CASE 10

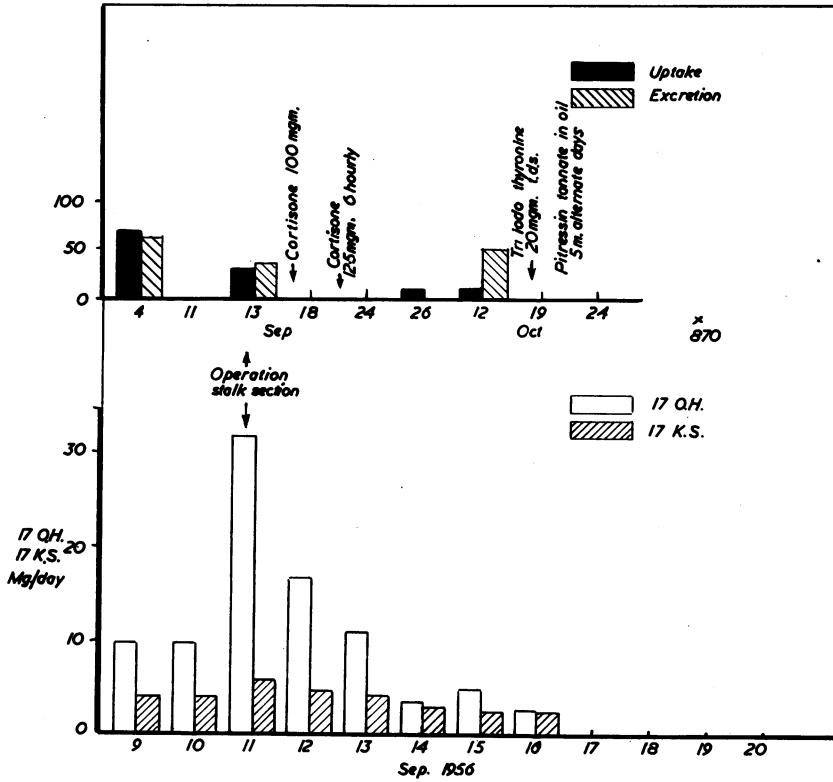


FIG. 13.

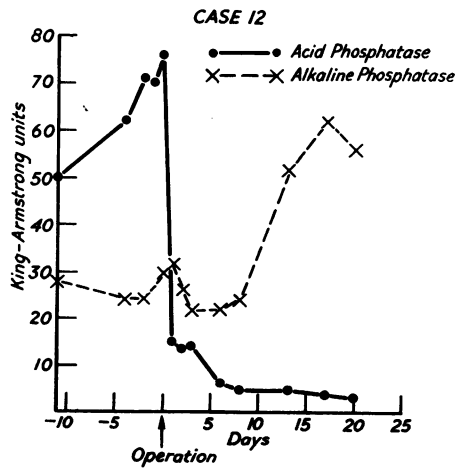


FIG. 14.—Case 12. To show changes in acid and alkaline phosphatase after stalk section in a case of carcinoma of prostate.



## CONCLUSIONS AND SUMMARY

Fourteen cases of advanced malignant disease were treated by methods designed to destroy pituitary glandular tissue. In Group I, 6 cases, the pituitary gland was injected with radioactive chromic phosphate. Complete destruction of the gland was not attained in any case, nor was any improvement seen in the malignant disease for which the patients had been treated. The only case which showed any endocrine disturbance was Case 6 and at operation the pituitary stalk of this patient had been damaged.

In Group II (3 cases, 1 of which had already been treated unsuccessfully in Group I) and Group III (6 cases), the pituitary stalk was divided. Immediate and profound endocrine disturbance was evident, though the two autopsies performed on cases in Group II showed viable pituitary epithelial tissue still present. There was no apparent difference between cases treated by stalk section alone and those treated by stalk section and injection of radioactive material. Subjective improvement and relief from pain was claimed by all patients treated by stalk section and in 4 cases there was objective evidence of improvement.

It is felt that the technique of operation described for section of the pituitary stalk through a trephine hole without a major craniotomy is a relatively simple procedure; it has proved safe in our hands even when used for seriously ill patients. It is for this reason that we decided to publish this small series at this time. It is appreciated that, though this procedure has been shown to produce severe endocrine changes suggesting suppression of pituitary glandular function, our longest follow-up is only 21 weeks after stalk section, so we do not yet know how permanent the endocrine changes may be. If pituitary function should recover at a later date due to re-growth of pituitary glandular tissue, this might be prevented by injection of radioactive material into the gland at the time of stalk section using the same operative approach.

The outstanding problem is the selection of cases of malignant disease in which regression of the tumour may be expected as a result of the severe endocrine changes produced by suppression of pituitary function.

## EXPLANATION OF PLATES

FIG. 2.—Pituitary gland—Case 2. Showing partial destruction surviving tissue in left upper quadrant. H. & E.  $\times 2.5$ .

FIG. 3.—Hypothalamus—Case 2. Showing nodule of tumour cells. H. & E.  $\times 10$ .

FIG. 4.—As Fig. 3. H. & E.  $\times 50$ .

FIG. 5.—To show operative approach.

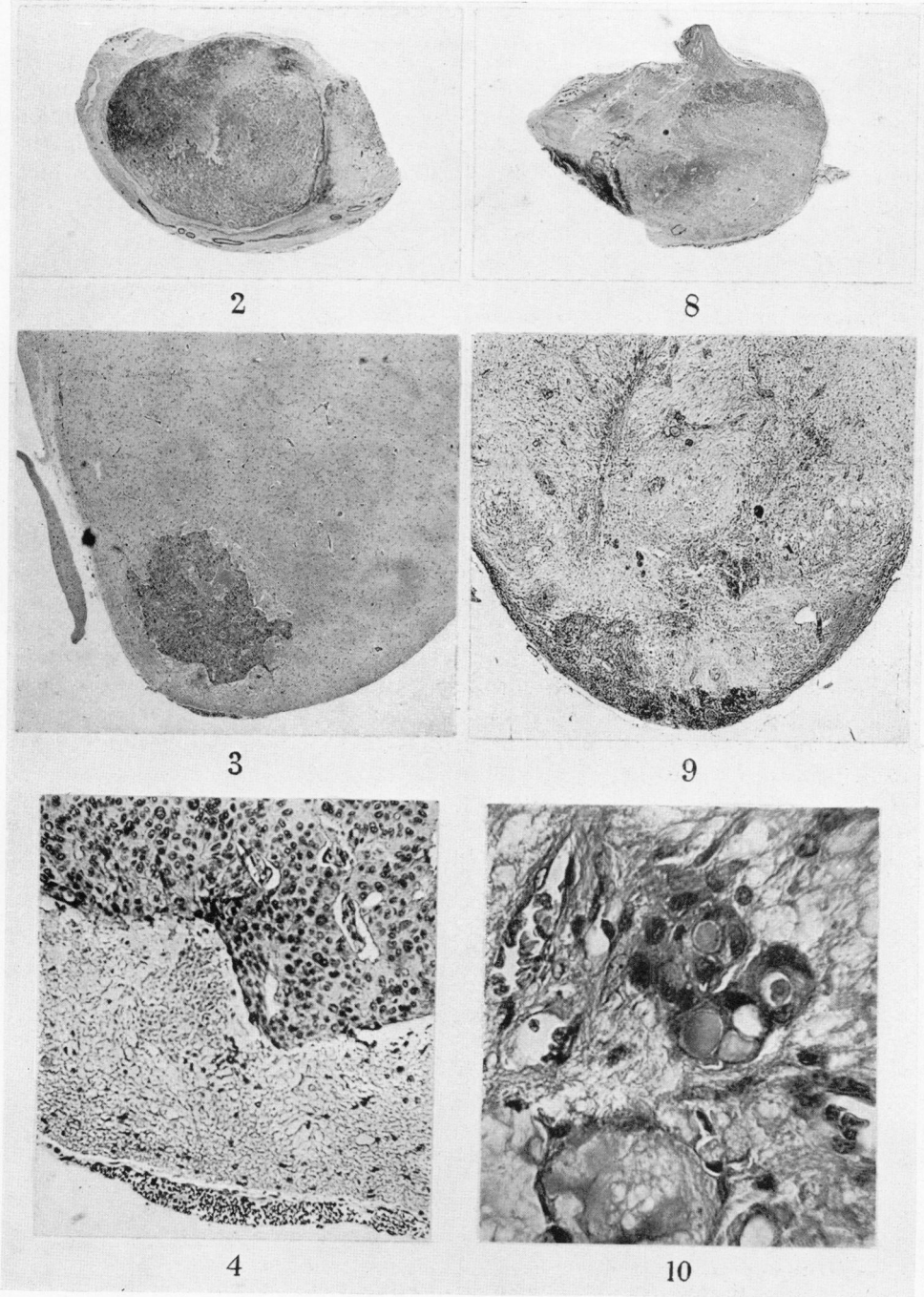
FIG. 8.—Pituitary gland—Case 7. Showing almost complete destruction. There is a small island of viable cells at the left lower border. H. & E.  $\times 3$ .

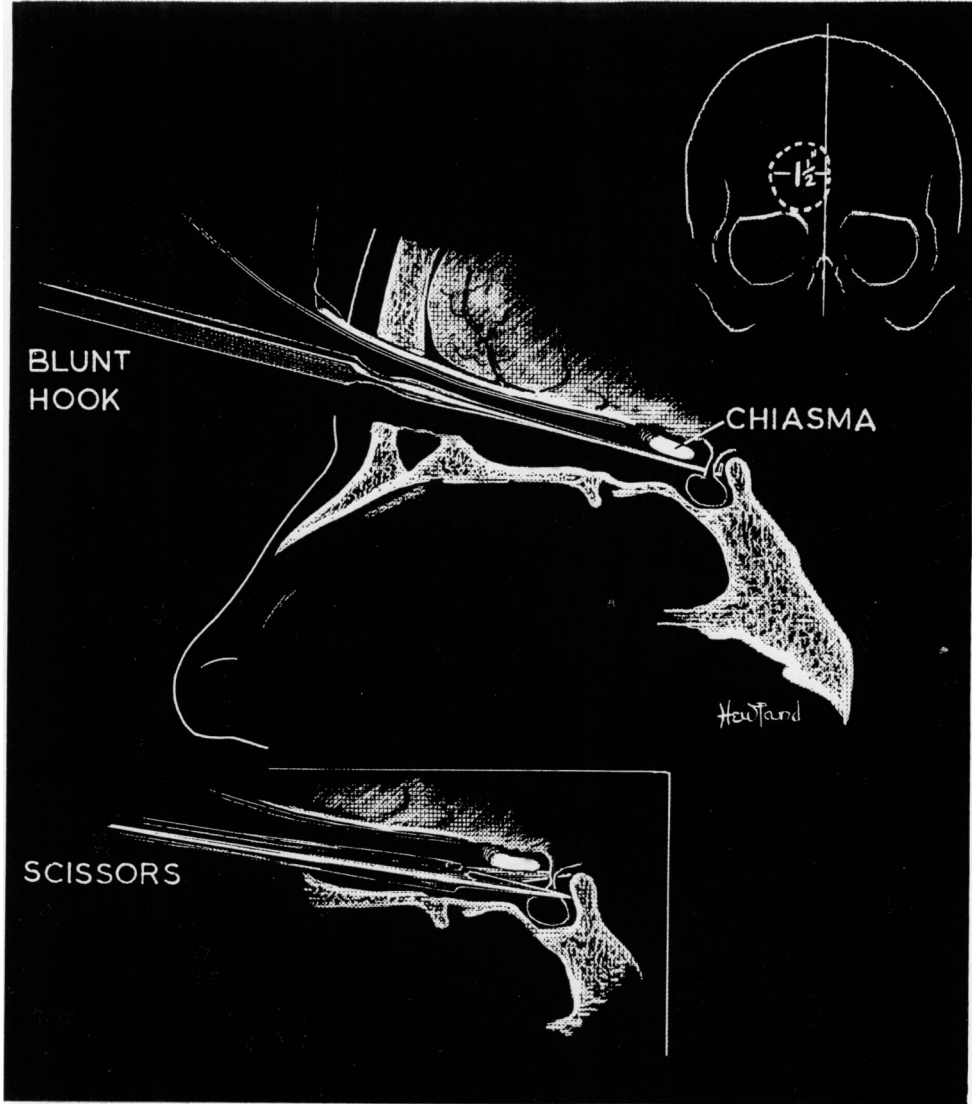
FIG. 9.—Hypothalamus—Case 7. Showing marked destruction. H. & E.  $\times 10$ .

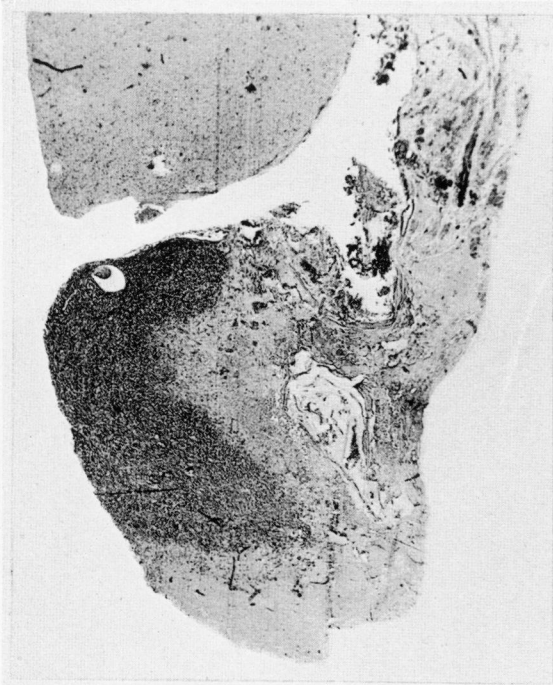
FIG. 10.—High power view of group of tumour cells just above centre of Fig. 9. H. & E.

FIG. 11.—Pituitary gland and hypothalamus—Case 8. Showing (a) destruction of distal part of stalk, with thrombosis of portal vessels; partial destruction of gland—surviving tissue left lower quadrant. H. & E.  $\times 5$ . (b) Higher power view of surviving glandular tissue. (c) Higher power view of pituitary stalk.

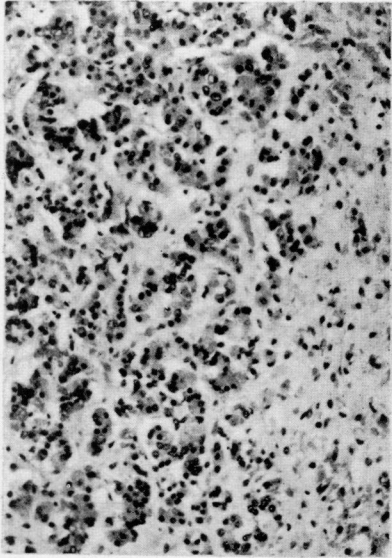
FIG. 15.—Case 11. To show regression of cutaneous metastases 2 months after stalk section.



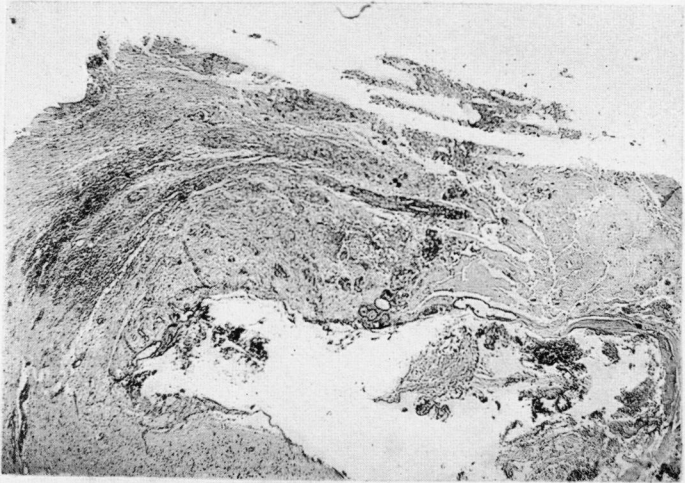




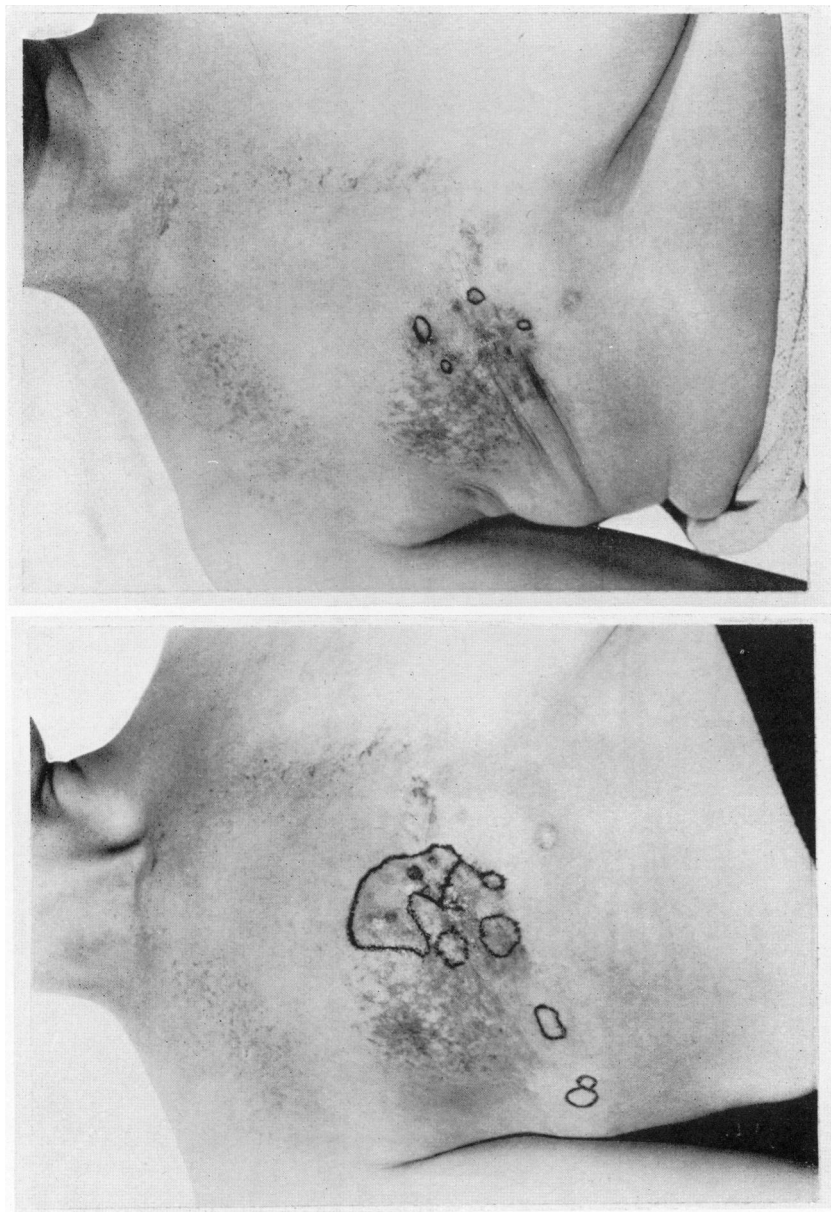
11a



11b



11c



We wish to thank Dr. J. D. N. Nabarro and Dr. G. Walker who have collaborated in this work and undertaken the metabolic and endocrinological investigations which will be the subject of a later report.

Dr. A. M. Jelliffe and Mr. R. E. Ellis collaborated in the work in which radioactive chromic phosphate was used.

Our thanks are also due to Professor B. W. Windeyer, Miss M. D. Snelling, Mr. D. H. Patey and Mr. R. S. Handley for their co-operation and permission to operate on their cases.

We are grateful to Mr. T. E. Cowan for drawing the charts and to Miss E. Hewland and Mr. M. Turney for the drawings and photographs.

Part of the expenses of this investigation were met by a grant from the British Empire Cancer Campaign.

A paper based on the earlier cases in this report was read before the Society of British Neurological Surgeons in November 1956.

#### REFERENCES

- DAVIES, F. L.—(1956) *Lancet*, i, 466.  
 HADFIELD, G.—(1956) *Brit. med. J.*, i, 94.  
 LUFT, R. AND OLIVECRONA, H.—(1953) *J. Neurosurg.*, **10**, 301.  
 PEARSON, O. H., RAY, B. S., HARROLD, C. C., WEST, C. D., LI, M. C., MACLEAN, J. P. AND LIPSETT, M. P.—(1956) *J. Amer. med. Ass.*, **161**, 17.  
 PERRAULT, M., LE BEAU, J., KLOTZ, B., SICARD, J. AND CLAVEL, B.—(1952) *Therapie*, **7**, 290.  
 ROTHENBERG, S. F., JAFFE, H. L., PUTNAM, T. T. AND SIMKIN, B.—(1955) *Arch. Neurol. Psychiat., Chicago*, **73**, 193.  
 RUSSELL, D. S.—(1956) *Lancet*, i, 466.  
 SHIMKIN, M. B., BOLDREY, E. B., KELLY, K. H., BIERMAN, H. R., ORTEGA, P. AND NAFFZIGER, H. C.—(1952) *J. clin. Endocrin.*, **12**, 439.

#### ADDENDUM

Since this paper was submitted for publication Cases 9 and 12 in Group III have died, 6 and 5 months, respectively, after operation. Section of the pituitary glands in both these cases at autopsy has shown surviving pituitary glandular tissue amounting to approximately 20 per cent of normal, mainly around the periphery of the gland. There is no evidence in these cases of functional reconnection of the pituitary gland to the hypothalamus nor of re-growth of glandular tissue around the divided stalk.