

CARDIAC LESIONS PRODUCED IN THE RABBIT BY INTRAMYOCARDIAL INJECTION OF VARIOUS MICRO-ORGANISMS*

I. GINSBURG, A. LAUFER AND S. Z. ROSENBERG

From the Department of Experimental Medicine and Cancer Research, The Department of Pathology, and the Cardio-Vascular Research Laboratory, The Hebrew University-Hadassah Medical School and the Rothschild Hadassah University Hospital, Jerusalem, Israel.

Received for publication June 9, 1959

SEVERAL studies were undertaken in order to reproduce in laboratory animals cardiac lesions which would resemble those appearing in human beings suffering from the sequelae of streptococcal infections (Schultz, 1936 ; Smith, Morgan and Mudd, 1940 ; Gross, Cooper and Philips, 1941 ; Robinson, 1947 ; Schultz, 1947 ; Murphy and Swift, 1949 ; Murphy, 1949 ; Clawson, 1950 ; Robinson, 1951 ; Murphy, 1952 ; Glaser, Thomas, Morse and Darnell, 1956). These studies describe the histopathological changes obtained in laboratory animals following inoculation by various routes of haemolytic streptococci, of their products and of a number of other micro-organisms.

As to the mechanism involved in the production of cardiac lesions, two main theories have been proposed : (a) allergic phenomena, or production of auto-antibodies to the heart muscle (Rich and Gregory, 1944 ; Rich, 1946 ; Cavelty, 1947*a* and 1947*b*), (b) direct action of haemolytic streptococci and their toxins on the heart muscle (McLeod, 1953 ; Kellner and Robertson, 1954*a* and 1954*b*). Although both theories have been supported by some experimental evidence, the exact mechanism has not yet been clarified.

This study describes the histo-pathological changes obtained in rabbits as a result of single intramyocardial injections of haemolytic streptococci and their cell-free extract, as well as of other bacterial species, both related and not related to haemolytic streptococci. The possible mechanism involved, and especially the role of trauma to the myocardium, in inducing cardiac lesions, is described.

MATERIALS AND METHODS

Micro-organisms : The following bacterial species were employed : (a) *Streptococcus pyogenes*, group A, strain S84, type 3 (obtained from the State Serum Institute, Copenhagen). (b) A nonhaemolytic variant of strain S84 accidentally obtained by repeated passages of strain S84 on a synthetic medium (Ginsburg and Grossowicz, 1957). (c) *Streptococcus faecalis*, group D, isolated from human faeces. (d) *Lactobacillus casei* 7469. (e) *Bacterium coli*, strain B.

Micro-organisms (c), (d) and (e) were obtained from stock cultures of the Department of Bacteriology at the Hebrew University-Hadassah Medical School to whom we are indebted. Micro-organisms (a)-(d) were cultivated in brain-heart infusion broth (Difco), while (e) was cultivated in an ordinary bacteriological broth. Usually a 16-hr. culture grown at 37° was employed. The bacterial growth was washed 3 times with 20 ml. of 0.066 M phosphate saline buffer (pH 7.4). The washed bacteria were then resuspended in buffer and diluted

* This study was supported by the Barnett Louis Memorial Scholarship Fund..

to contain approximately 5×10^8 cells/ml. In some experiments streptococci were heated at 100° for 30 min., or irradiated for 15 min. with ultraviolet light using a Mineralight model V 41 ultraviolet lamp, from a distance of 20 cm. No viable micro-organisms were left as determined by plating method.

Preparation of cell-free extract: Washed streptococci were subjected to sonic disintegration using a Raytheon 9 Kc sonic oscillator for 30 min. The cell debris and the remaining intact cells were removed by high-speed centrifugation and the supernatant fluid was filtered through a fine sintered glass filter.

Animals: Sixty-two male and female rabbits, weighing 2-3 kg., raised at the animal house of the Hebrew University, were used. They were kept on a vegetable diet and water, both given *ad libitum*.

Material injected: Amounts of 0.2 ml. of the above mentioned micro-organisms, or of cell-free extract obtained from strain S84, were injected into the myocardium of the unanaesthetized animals.

Histological preparations: The animals were killed at 7 and 14 days after the intramyocardial injection. Heart slices were fixed in Zenker's acetic acid solution. Paraffin sections were stained with haematoxylin-eosin, Van Gieson, azan stains, and Gram stain.

RESULTS

Group I (Control animals).—This group comprised 8 animals. The hearts of 4 rabbits were traumatized twice with a sterile needle (22 gauge), but no material was injected. In the other rabbits, sterile phosphate saline buffer was injected into the myocardium. The histological examination of heart sections in some cases revealed a proliferation of collagen fibres in the myocardium; in others no pathological changes were seen.

Group II.—This group consisted of 27 animals. In 13 rabbits living streptococci (S84), in 5 rabbits heat-killed streptococci, and in 5 animals ultraviolet irradiated streptococci were injected into the myocardium. The remaining 4 animals received intramyocardial injection of cell-free extract obtained from strain S84.

The histological examination revealed pronounced endomyocardial changes in all the animals injected with any type of material. The intensity of the histological picture however varied (*a*) in different animals, (*b*) according to the number of days which elapsed from the injection to the time of sacrifice. The endocardium of animals killed 7 days following injection showed a marked fibroblastic and histiocytic proliferation which in some areas showed a palisade arrangement (Fig. 1 and 2). Mingled with these cells were some leucocytes. The endothelial lining of the endocardium was usually preserved and in some areas proliferation of these cells was marked (Fig. 3). The myocardial changes consisted of muscle degeneration and necrosis with a proliferative, granulomatous reaction. The latter consisted of foci of mononuclear cells, histiocytes, fibroblasts and giant cells with a basophilic or mildly eosinophilic cytoplasm. In the multi-nuclear giant cells, the nuclei were irregularly scattered in the cytoplasm and had a prominent, large nucleolus. The cytoplasm of some giant cells contained eosinophilic material. In some areas the granulomata surrounded empty spaces or some eosinophilic finely granulated fragments, which resembled sarcoplasmatic remnants (Fig. 4). The granulomata were often surrounded by lymphoid cells, and in some areas by a proliferation of collagen fibres. Similar histopathological changes were obtained by intramyocardial injection of a cell-free extract obtained from strain S84 (Fig. 5). In other areas no relationship between the location of the granuloma and the degenerated muscle fibres was found. No micro-

organisms were detected in the histological section or by culture. In animals killed 14 days following injection the histological picture was essentially similar to that described above, but the granulomatous lesions were more pronounced. In animals killed as early as 3 days following injection muscle necrosis and mononuclear cell infiltration could already be seen. It is of interest that only few granulocytes were present at that time.

Group III.—This group consisted of 9 animals: 3 animals received an intramyocardial injection of a mutant of strain S84. Enterococci, lactobacilli and *Bact. coli* respectively were injected into the myocardium of each 2 of the remaining 6 rabbits.

The histological changes in this group closely resembled those obtained in Group II. The most striking similarity was observed following the injection of *Bact. coli* and *L. casei* (Fig. 6) and a mutant of strain S84. In the case of the enterococci the lesions were of a milder degree. The lesions were abacterial.

Group IV.—This group consisted of 18 rabbits. Ten animals received a single intravenous injection of 1 ml. of living strain S84, but no previous trauma to the heart was performed. In another 8 animals the myocardium was traumatized twice with a sterile needle so as not to penetrate into the cavity of the heart, and 5 min. later 1 ml. of living strain S84 was injected intravenously into 6 of them, while the remaining 2 animals received 1 ml. of heat killed streptococci.

The histological examination of the heart of the animals receiving only an intravenous injection of living strain S84 showed no pathological changes. However, in 4 out of 6 animals the heart of which had been damaged by a sterile needle prior to the intravenous injection of living streptococci and in 2 animals receiving heat killed streptococci following needle trauma, well developed granulomatous lesions accompanied by muscle degeneration and necrosis were observed (Figs. 7 and 8). These alterations closely resembled those obtained in groups II and III. Of the remaining 2 animals, one exhibited interstitial myocarditis while the other revealed no pathological changes.

DISCUSSION

The results obtained in this study show that pronounced endomyocardial changes were found in rabbits at the site of a single intramyocardial injection of living or killed haemolytic streptococci, of their cell-free extract, and following injections of other micro-organisms. It is noteworthy that the histological changes obtained in the various groups examined were much alike. That the endomyocardial lesions produced by haemolytic streptococci could not be differentiated from those obtained by other micro-organisms indicates that the alterations are not specific for haemolytic streptococci. Myocardial changes similar to those described by us have been reported by Gross, Cooper and Philips (1941) following intracardiac injection of α -haemolytic streptococci. These authors claimed that the histological changes were identical irrespective of whether single or repeated injections were given. Glaser, Thomas, Morse and Darnell (1956) reported the appearance of myocardial granulomata 48–72 hr. following a single intrapharyngeal injection of haemolytic streptococci. These observations make it unlikely that sensitization or allergy play a significant role in their production. Since well developed granulomata have been found in our study 7 days after one single injection, the role of sensitization in the production of these lesions is

further questioned. As the injections of the various organisms caused trauma to cardiac muscles, the question arose as to whether or not trauma to the heart conditions the production of granulomata by the micro-organisms. This assumption was based on the fact that neither intravenous injection of streptococci nor the intramyocardial injection of buffered saline nor the puncture of the heart muscle itself by a sterile needle produced significant histological changes. However, fully developed muscle alterations and granulomatous reaction were observed in the myocardium following intravenous injection of living or dead streptococci when the rabbits' hearts were previously traumatized by a sterile needle.

These findings suggest that trauma to the heart is of importance in the production of myocardial changes, necrotic and granulomatous in nature, provided that streptococci are present in the blood. The possibility exists that products of various micro-organisms—toxins and enzymes—may cause "trauma" to the heart muscle, and thereby predisposing it to the effect of the micro-organisms. Kellner and Robertson (1954*a* and 1954*b*) showed that various proteolytic enzymes of streptococcal and other origin produced cardiac lesions in rabbits when injected intravenously. These lesions are similar to those obtained by other authors using whole streptococcal suspension (Murphy, 1949; Robinson, 1951; Glaser *et al.*, 1956). More recently it has been shown that various streptococcal haemolysins may injure and kill various mammalian cells *in vitro* and that these injured cells may be completely disintegrated when small amounts of various proteolytic enzymes are added to them (Ginsburg and Grossowicz, 1957).

It will be of interest to establish whether or not a combination of haemolysins and proteolytic enzymes may predispose the heart to develop such lesions.

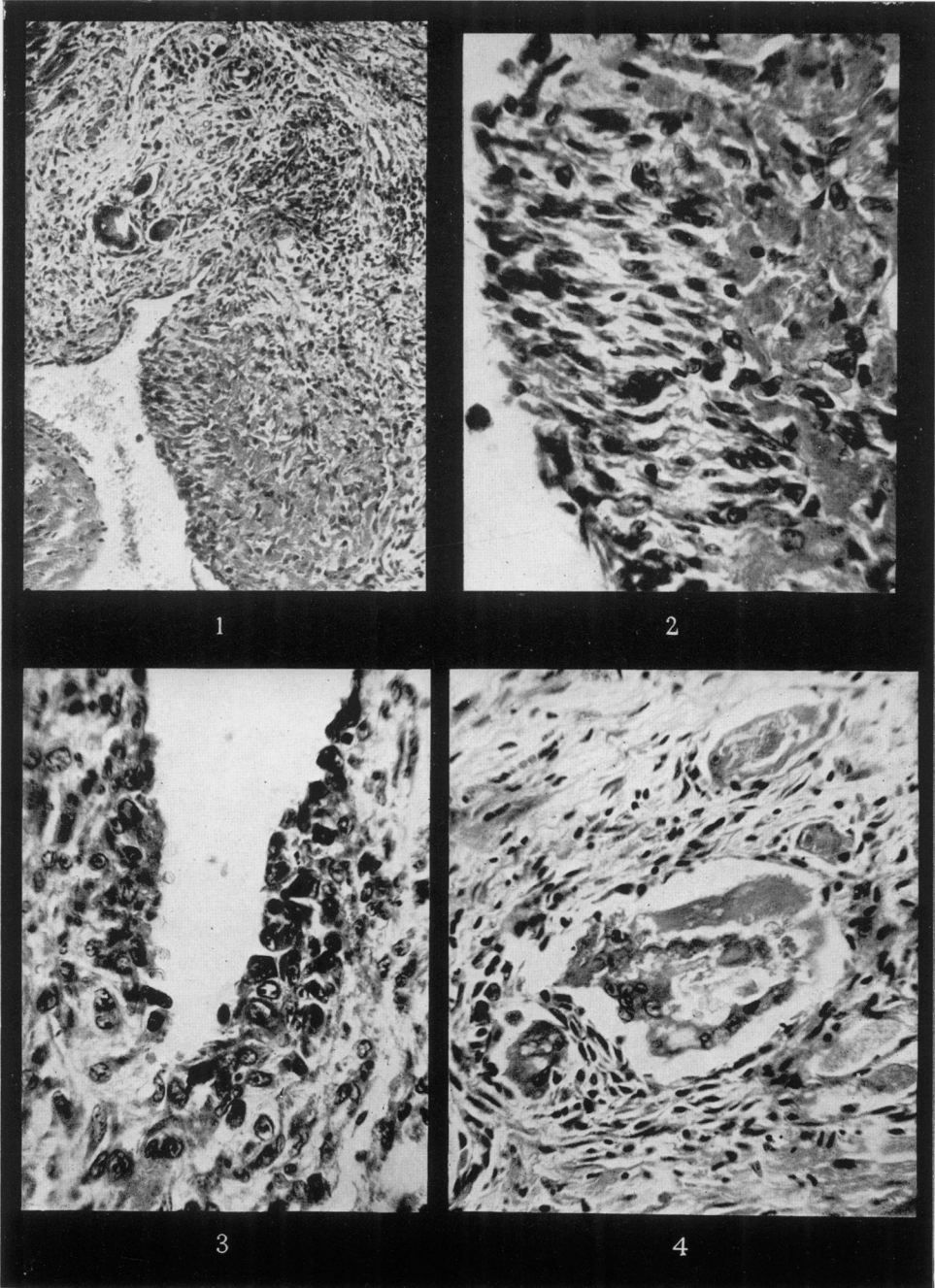
SUMMARY

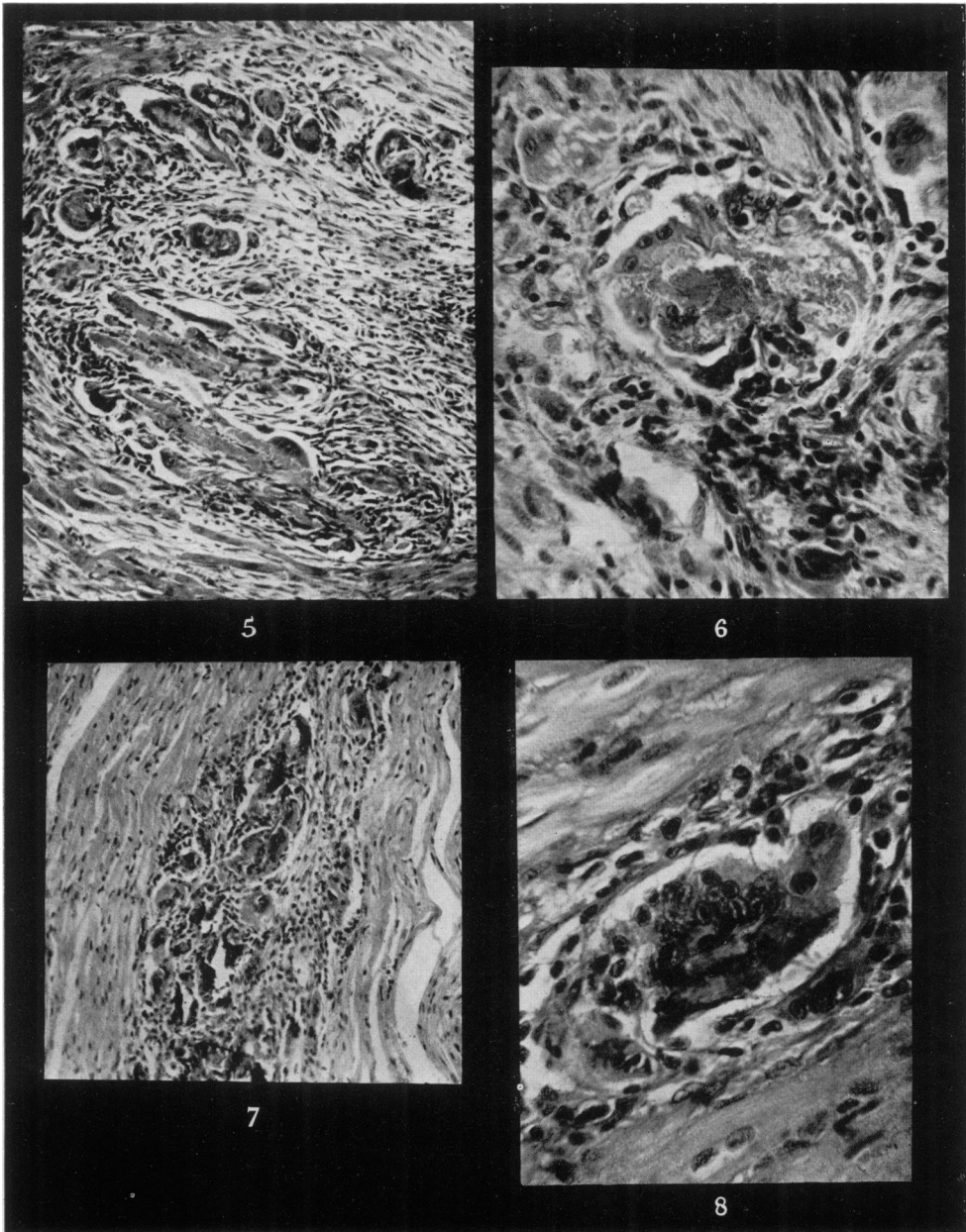
Histopathological changes obtained in the rabbit's heart by a single intramyocardial injection of haemolytic streptococci were studied.

EXPLANATION OF PLATES

The histological preparations were obtained from animals sacrificed 7 days following intramyocardial injection of the various micro-organisms.

- FIG. 1.—Endomyocardial lesions following injection of haemolytic streptococci (strain S84). Note the fibroblastic and histiocytic cell proliferation in the endocardium mingled with round cell infiltration. A small granulomata with giant cells is seen adjacent to the endocardium. $\times 117$. Haematoxylin and eosin.
- FIG. 2.—Palisade arrangement of the proliferation in the endocardium following injection of haemolytic streptococci. $\times 406$. Haematoxylin and eosin.
- FIG. 3.—Proliferation of endothelial lining cells of the endocardium mingled with histocytes and round cells following injection of haemolytic streptococci. $\times 406$. Haematoxylin and eosin.
- FIG. 4.—Granulomatous lesion in the myocardium surrounding necrotic muscle fibres following injection of haemolytic streptococci. $\times 406$. Haematoxylin and eosin.
- FIG. 5.—Granulomatous lesion in the myocardium surrounding necrotic muscle fibres following injection of a cell-free extract of haemolytic streptococci. $\times 114$. Haematoxylin and eosin.
- FIG. 6.—Granulomatous lesion in the myocardium following injection of *Lactobacillus casei*. $\times 285$. Haematoxylin and eosin.
- FIG. 7.—Granulomatous lesion in the myocardium obtained after cardiac damage with a sterile needle followed 5 min. later by an intravenous injection of haemolytic streptococci. $\times 107$. Haematoxylin and eosin.
- FIG. 8.—Same as in Fig. 7. Note the presence of mono- and multinuclear giant cells with large nucleoli. $\times 371$. Haematoxylin and eosin.





Nonbacterial endomyocarditis accompanied by muscle necrosis and marked granulomatous reaction was observed.

Such lesions were not specific for haemolytic streptococci since similar lesions were obtained following intramyocardial injection of enterococci, lactobacilli, *Bact. coli* and a nonhaemolytic mutant of haemolytic streptococcus.

Neither trauma to the heart muscle alone, nor the intravenous injection of living or heat-killed haemolytic streptococci caused any pathological changes in the heart. On the other hand, well developed granulomatous lesions appeared in the heart when the intravenous injection of these organisms was preceded by puncturing the myocardium with a sterile needle.

The specificity of haemolytic streptococci and the role of trauma in the production of cardiac lesions is discussed.

REFERENCES

- CAVELTY, P. A.—(1947a) *Arch. Path.*, **44**, 1.—(1947b) *Ibid.*, **44**, 13.
CLAWSON, B. J.—(1950) *Ibid.*, **50**, 68.
GINSBURG, I. AND GROSSOWICZ, N.—(1957) *Proc. Soc. exp. Biol. N.Y.*, **96**, 108.
GLASER, R. J., THOMAS, W. A., MORSE, S. I. AND DARNELL, J. E.—(1956) *J. exp. Med.*, **103**, 173.
GROSS, P., COOPER, F. B. AND PHILLIPS, J. D.—(1941) *Amer. J. Path.*, **17**, 377.
KELLNER, A. AND ROBERTSON, T.—(1954a) *J. exp. Med.*, **99**, 387.—(1954b) *Ibid.*, **99**, 495.
MCLEOD, C. M.—(1953) *Maryland Med. J.*, **2**, 236.
MURPHY, G. E.—(1949) *J. exp. Med.*, **91**, 371.—(1952) *Ibid.*, **95**, 316.
Idem AND SWIFF, H. F.—(1949) *Ibid.*, **89**, 687.
RICH, A. R.—(1946) *Harvey Lect.*, **42**, 106.
Idem AND GREGORY, J. E.—(1944) *Johns Hopk. Hosp. Bull.*, **75**, 115.
ROBINSON, J. J.—(1947) *Arch. Pediat.*, **44**, 1.—(1951) *Arch. Path.*, **51**, 602.
SCHULTZ, M. P.—(1936) *Ibid.*, **21**, 472.—(1947) *Publ. Hlth Rep. Wash.*, **62**, 1509.
SMITH, L. W., MORGAN, I. M. AND MUDD, S.—(1940) *Amer. J. Path.*, **16**, 87.
-