

THE BRITISH JOURNAL OF EXPERIMENTAL PATHOLOGY

VOL. XLVII

OCTOBER, 1966

NO. 5

ACID PHOSPHATASE AND LYSOSOME ACTIVITY IN DIPHThERITIC NEUROPATHY AND WALLERIAN DEGENERATION

R. O. WELLER AND R. S. MELLICK

*From the Department of Pathology, Guy's Hospital Medical School and the
M.R.C. Research Group in Applied Neurobiology, Institute of Neurology*

Received for publication January 4, 1966

The main histological differences between Wallerian degeneration and diphtheritic neuropathy lie in the character of the myelin damage and the fate of the axons. During the early stages of Wallerian degeneration the axon distal to the point of injury degenerates and there is consequent breakdown of the myelin sheath throughout this portion of the severed nerve (Cajal, 1928; Weddell and Glees 1941; Young, 1942; Guth, 1956; Nathaniel and Pease, 1963; Thomas, 1964).

Diphtheritic neuropathy, by contrast, is characterised by segmental degeneration of the myelin with preservation of most of the axons (Meyer, 1881). The myelin tends to break down throughout the whole internode in the smaller fibres, whereas the damage to the larger fibres is often restricted to the paranodal regions (Cavanagh and Jacobs, 1964).

Diphtheritic neuropathy has been produced by the injection of the toxin in a variety of experimental animals including rabbits (Waksman, Adams and Mansmann, 1957) guinea pigs (Webster, Spiro, Waksman and Adams, 1961) and cats (McDonald, 1963). Cavanagh and Jacobs (1964) observed a fairly uniform response in young chickens following the intramuscular injection of diphtheria toxin. The birds developed a flaccid paresis some 6-7 days after the injection of 0.33 L⁺ of toxin per 100 g.; it was at this time that myelin breakdown became evident in the peripheral nerves. Electron microscopic study of the nerves during these first 6 days after injection has shown a marked increase in lysosomes in the affected Schwann cells, and their close association with the breakdown of the myelin sheath (Weller, 1965).

The present study is a comparison of the lysosome activity during the early stages of myelin breakdown in diphtheritic neuropathy and Wallerian

degeneration. The quantitative biochemical estimations of acid phosphatase activity have been correlated with the cytological localization of the enzyme with the electron microscope.

MATERIALS AND METHODS

Animals.—Young chickens (White Leghorn \times Silver Link) aged about 10 weeks and weighing between 700–1200 gm. were used. They were housed singly or in pairs in cages and fed on poultry bran.

Biochemical investigation

Diphtheritic neuropathy.—A localised area of demyelination was produced in the chicken sciatic nerve on one side only by the intraneural injection of diphtheria toxin (batch R \times 7151 obtained through the courtesy of Dr. Mollie Barr of the Wellcome Research Laboratories, Beckenham). The injection was performed under ether anaesthesia following the technique described by Brierley and Field (1949). The toxin was given in a dose of 1.25×10^{-5} L⁺. (The L⁺ dose is defined as the least amount of toxin which, when mixed with 1 unit of anti-toxin, will kill a 250 g. guinea pig in 5 days after s.c. injection) in a volume of 0.01 ml., delivered from a tuberculin syringe with a micrometer attachment to depress the plunger. The toxin was administered in this way to a total of 23 birds; in 11 birds it was mixed with 2 μ g. of trypan blue to facilitate subsequent identification of the injected segment. In the 12 birds where the toxin alone was administered, the injected segment was marked by means of a black silk suture in the overlying muscle.

The diphtheritic lesion produced by intraneural injection of such a small dose of toxin is similar in all essentials to that produced by severe intoxication with parenteral toxin-antitoxin mixture (Jacobs, Cavanagh and Mellick, 1966).

Wallerian degeneration.—The sciatic nerve on one side only was completely transected in the thigh close to the sciatic notch under aseptic conditions in 8 birds and allowed to undergo Wallerian degeneration. Specimens of degenerating nerve for enzyme estimation were taken more than 2 cm. distal to the site of section after 1, 6 and 11 days.

Control experiments.—Acid phosphatase activity was estimated in pieces of sciatic nerve from 19 normal animals. The increase in the enzyme activity after introducing a needle alone into the nerve was studied in 2 birds; the results of injecting normal saline alone were studied in 3 birds, and the effect of trypan blue mixed with normal saline was studied in 10 birds.

Estimation of enzyme activity.—The acid phosphatase activity was determined using a modification, described by King and Wootton (1956), of the method of King and Armstrong (1934). This modification gives results comparable with those of the earlier workers (Jenner and Kay, 1932).

Acid phosphatase activity was estimated using Folin and Ciocalteu's phenol reagent, 0.01M disodium phenyl phosphate substrate, and a sodium citrate-citric acid buffer at a pH of 4.9. A constant length of 24 mm. of injected or degenerating nerve, and a similar length from the control side were removed, and weighed fresh. The nerves were homogenised in 1 ml. distilled water at room temperature for not less than 20 min. After adding the substrate the reaction was allowed to proceed at 37° for 60 min. Results were related to the weight of 24 mm. of the nerve from the control side and expressed as mg. phosphate released per g. wet weight of nerve per hr. The results were thus corrected for change in water content due to the lesion.

Electron microscopy

Diphtheritic neuropathy.—Young chickens were injected i.m. with a partly neutralised diphtheria toxin-antitoxin mixture containing a dose of 0.33L⁺ of toxin per 100 g.

Approximately 0.5 cm. of sciatic nerve was removed under ether anaesthesia from 2 groups of birds at 5 and 6 days after the injection of the toxin. The former group showed very little weakness, but in the latter group there was marked hypotonia and flaccid paresis. The nerve was fixed in each case for 4 hr. in cold 3 per cent glutaraldehyde in 0.067M cacodylate buffer at pH 7.4. This was followed by 18 hr. washing in the cacodylate buffer containing 7.5 per cent sucrose. Frozen sections, 50 μ thick, were cut and incubated for 20–30 min. at 37° in an acetate buffer, pH 5.6, containing lead nitrate and β -glyceryl phosphate (Gömöri,

1952). The localisation of acid phosphatase activity by this method depends upon the precipitation of lead phosphate which is visualised as an electron dense deposit in the electron microscope (Sheldon, Zetterqvist and Brandes, 1955; Holt and Hicks, 1961). The enzyme activity was inhibited in control sections by treatment with 0.01M NaF for 30 min. before incubation with substrate. Following 2 hr. of postosmication the specimens in each case were dehydrated in alcohol, some were stained with alcoholic 1 per cent phosphotungstic acid, and all were embedded in araldite. Thin sections of the nerve were cut on a Huxley Cambridge microtome and viewed in an RCA EMU3e electron microscope.

Specimens of the lateral cutaneous nerve of the calf were also taken and fixed immediately in buffered osmium tetroxide (Palade, 1952) dehydrated in alcohol and embedded in araldite.

Wallerian degeneration.—The right sciatic nerve was severed in the upper thigh region and the distal portion allowed to degenerate. The operation was performed under ether anaesthesia with aseptic precautions. Chickens were killed 4, 6 or 10 days later and 0.5 cm. lengths of the degenerating nerve were taken at least 1 cm. distal to the point of transection. The specimens were fixed in 3 per cent Glutaraldehyde and 50 μ frozen sections were stained for acid phosphatase activity and embedded by the same methods as the sciatic nerves from the diphtheritic and normal chickens.

Control specimens of normal sciatic nerve were also processed in the same way.

RESULTS

Biochemical investigation

Diphtheritic neuropathy and Wallerian degeneration.—Twelve birds were killed within the first 5 days following the injection of diphtheria toxin; ten showed no functional disability and two showed hypotonia only. All the birds, however, killed after the 5th day showed varying degrees of paresis. Histological examination of the injected nerves with the light microscope has revealed a close correlation between the onset of myelin breakdown and the development of functional disability with this dose of diphtheria toxin (Jacobs *et al.*, 1966) so that no definite disturbance of the myelin sheaths can be found before the sixth day. The demyelination begins towards the end of the first week and reaches its maximum during the second week. The proportion of fibres involved in any one section during this time is approximately 50 per cent with this dose of toxin.

The activity of 19 normal sciatic nerves was found to be 1.1 mg. P. released/g./hr. (± 0.11 SD.). Two birds in which the needle only had been inserted into the nerve, and three birds in which an equivalent volume of normal saline had been injected were examined 5 days later. The mean enzyme activities of these 2 groups were between 1.3 and 1.5 mg.P./g./hr. Ten birds were injected with saline containing 2 μ g. of trypan blue. They were killed at 1, 3, 5, 11 and 19 days. Acid phosphatase activity in these inoculated nerves began to rise at 1 day and reached a peak at 5 days declining thereafter. Since the activity at 5 days was considerably greater than with saline alone it must be concluded that trypan blue itself has a tendency to stimulate acid phosphatase activity. Nonetheless, when the results of examining nerves inoculated with diphtheria toxin alone and with diphtheria toxin combined with 2 μ g. trypan blue were compared at each period after inoculation, the results were virtually identical; for that reason these results have been taken together.

Nerves inoculated with diphtheria toxin were examined at 1, 3, 5, 9 and 12 days after inoculation (Table I). Acid phosphatase activity was significantly increased above normal even one day after inoculation and continued to rise steadily beyond the 8th day (Fig. 1). By the 5th day when none of the birds showed functional disability and when no significant myelin degradation was

TABLE I.—*Acid Phosphatase Activity of Chicken Sciatic Nerve in Local Diphtheritic Neuropathy*

Time after intraneural injection (days)	Number of birds	Acid phosphatase activity (mg.P./hr./g.)
1	2	1.7
3	4	2.5 (± 0.21)
5	6	3.1 (± 0.25)
9	4	4.3 (± 0.32)
12	7	4.7 (± 0.31)

discernible under the microscope, the enzyme activity was more than 3 times the normal activity.

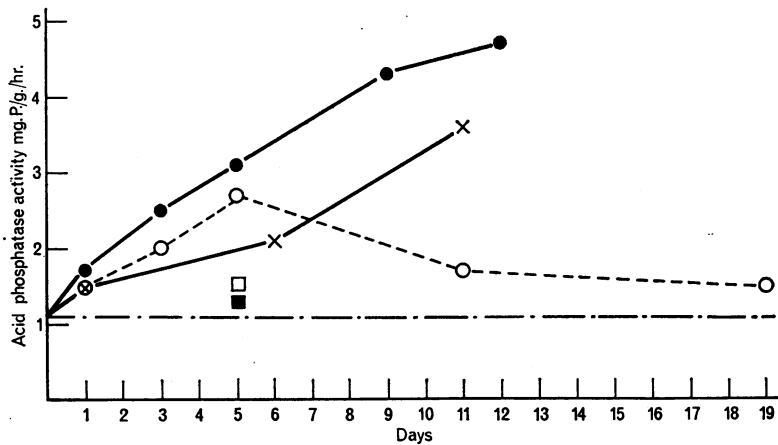


FIG. 1.—Acid phosphatase activity in diphtheritic neuropathy and Wallerian degeneration in peripheral nerves.

●	—	Diphtheritic neuropathy.
×	—	Wallerian degeneration.
<i>Controls</i>		
— · — · —	—	Normal nerve.
○	—	Intraneural injection of saline and trypan blue.
□	—	Intraneural injection of saline alone.
■	—	Needle inserted but nothing injected.

Transected nerves undergoing Wallerian degeneration were examined at 1, 6 and 11 days (Table II). The increase in enzyme activity was less during this period than with diphtheritic neuropathy (Fig. 1). At 6 days the increase was

TABLE II.—*Acid Phosphatase Activity of Chicken Sciatic Nerve During Wallerian Degeneration*

Time after nerve section (days)	Number of birds	Acid phosphatase activity (mg.P./hr./g.)
1	1	1.5
6	4	2.1 (± 0.31)
11	3	3.6 (± 0.34)

only half the increase found with diphtheria toxin, despite the fact that at this time wholesale myelin breakdown was occurring.

Electron microscope observations

Normal chicken nerve.—The ultrastructure of the chicken myelinated peripheral nerve is similar in all its major features to that of the guinea pig (Webster and Spiro, 1960). The axon is surrounded by a myelin sheath in the internodal regions. The Schwann cytoplasm in the smaller fibres is distributed in a layer outside the myelin, and in small pockets within the circumference of the sheath in the juxta-axonal region (Fig. 2). The larger fibres have very little cytoplasm associated with the sheath in the internodal regions except adjacent to the node of Ranvier and around the nucleus. It is in the latter region that most of the granular and agranular endoplasmic reticulum is situated.

The other cells within the endoneurium sheath are mainly endoneurial fibroblasts; these can be distinguished from Schwann cells because they do not usually possess a basement membrane. No macrophages and only an occasional mast cell are seen in the normal nerve, and no acid phosphatase activity can be detected in the preparations stained for the enzyme. There is slight shrinkage of Schwann cytoplasm and some disruption of myelin in both the normal and pathological specimens which have been subjected to freezing, thawing, and incubation in a medium at a low pH for enzyme studies, but there is no gross disruption of cells except at the edges of the 50μ sections.

Diphtheritic Neuropathy.—Functional assessment of the birds injected with diphtheria toxin revealed little or no weakness before the 5th day, and no significant breakdown of myelin in teased preparations of the nerve. By the 6th day, however, there was a flaccid paresis, and myelin breakdown in the peripheral nerves began to appear.

Acid phosphatase activity was found in the Schwann cells both before and after the onset of myelin breakdown. When the enzyme activity was associated with an intact myelin sheath, it was confined to structures with a regular circular outline (Figs. 3 and 4). An investing membrane around these structures could not usually be resolved in the electron-histochemical preparations, although similar profiles were seen in parallel osmium-fixed material to be surrounded by a single membrane (Weller, 1965). The enzyme activity is therefore likely to be present in primary lysosomes. De Duve (1964) defined primary lysosomes as the conveyors of acid hydrolases which have not yet been involved in a digestive event, and secondary lysosomes as intracellular digestive vacuoles in which acid hydrolases are present.

The primary lysosomes have been found in 2 types in this material. One consists of lysosomes, $0.15-0.2\mu$ in diameter, situated in clusters in the juxta-axonal Schwann cytoplasm (Fig. 3). The other type is slightly larger in diameter (0.75μ) and tends to occur singly in the cytoplasm outside the myelin sheath (Fig. 4). Both forms are found in close association with undamaged myelin sheaths.

The onset of myelin breakdown is accompanied by a marked decrease in the number of fibres containing primary lysosomes and it has been shown that there is a close connection between the sites of primary lysosome accumulation and initial myelin breakdown (Weller, 1965).

The destruction of the sheath is characterised by the early separation of the damaged myelin from the undamaged axon (Fig. 5). A varying number of

vacuoles containing myelin debris are seen in the Schwann cells and in many of them the myelin is still compact. Acid phosphatase activity is observed in the vacuoles both around the periphery and associated with compact myelin well within the vacuole (Fig. 6). These may be regarded as secondary lysosomes.

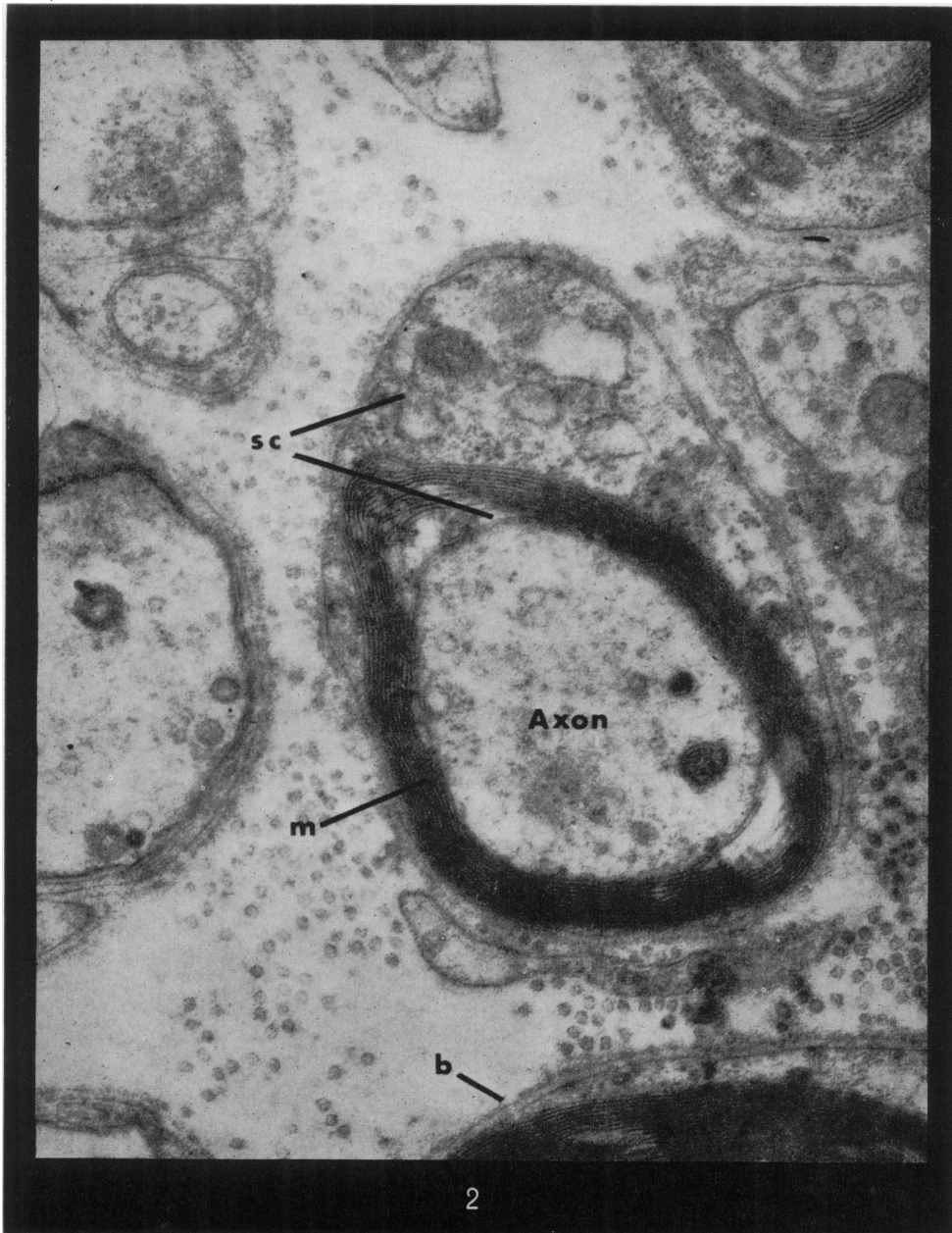
Wallerian degeneration.—The earliest specimen examined histochemically by the acid phosphatase method was 4 days after division of the nerve. At this time the axons show gross degenerative changes and in many cases nothing remains except a conglomeration of electron dense granular material. The myelin sheaths are distorted and collapsed, though there is very little myelin fragmentation, and no acid phosphatase activity can be detected in the Schwann cells.

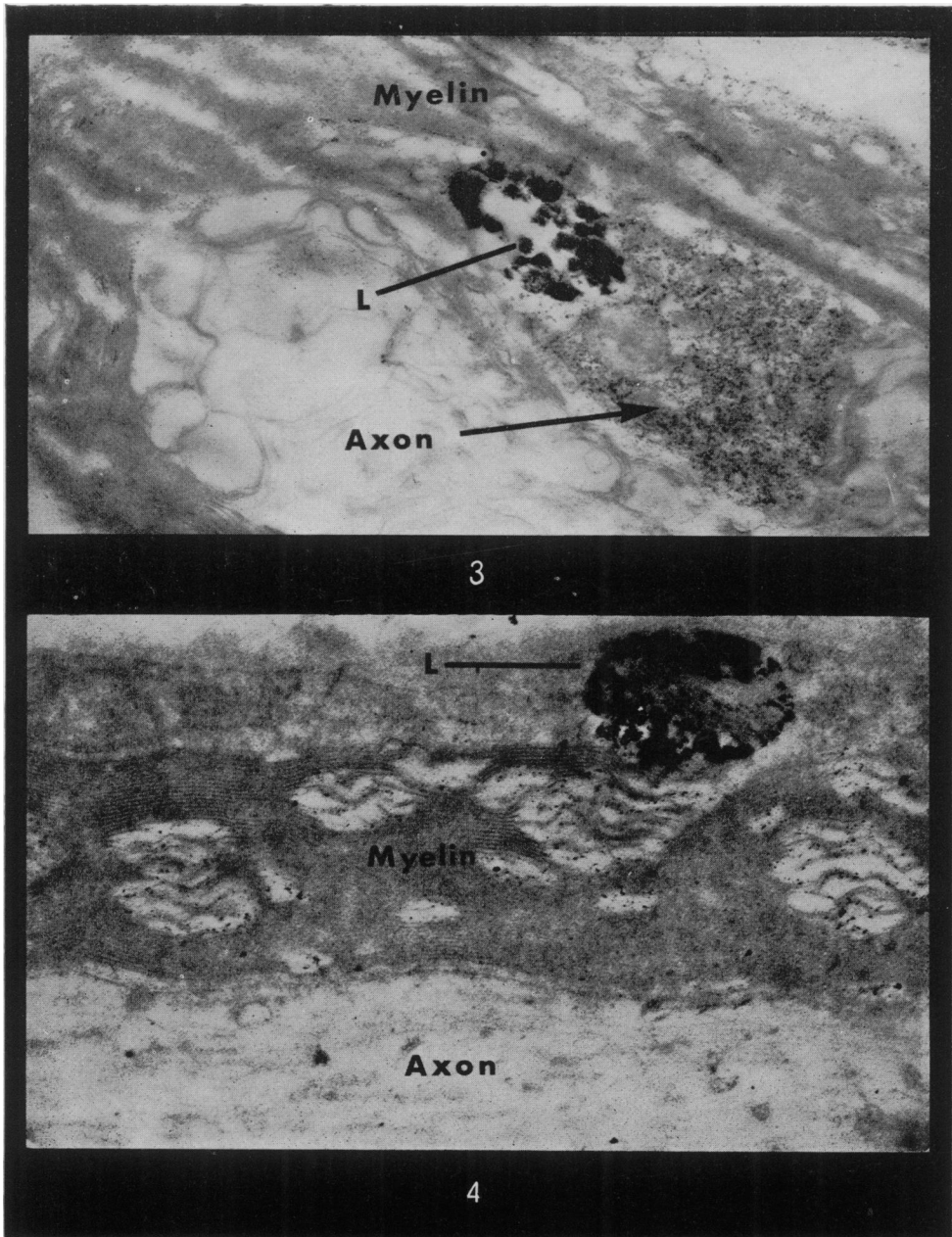
The degeneration of the axons is almost complete at 6 days and in many Schwann cells it can no longer be identified. The distortion of the sheath is more marked than at 4 days though much of the myelin still retains its compact lamellar pattern. However, in a number of Schwann cells the myelin debris is distributed throughout the cytoplasm in vacuoles, but no acid phosphatase activity can be detected within them, nor are there any primary lysosomes to be found. The only sites of enzyme activity are in the endoneurial macrophages at this stage.

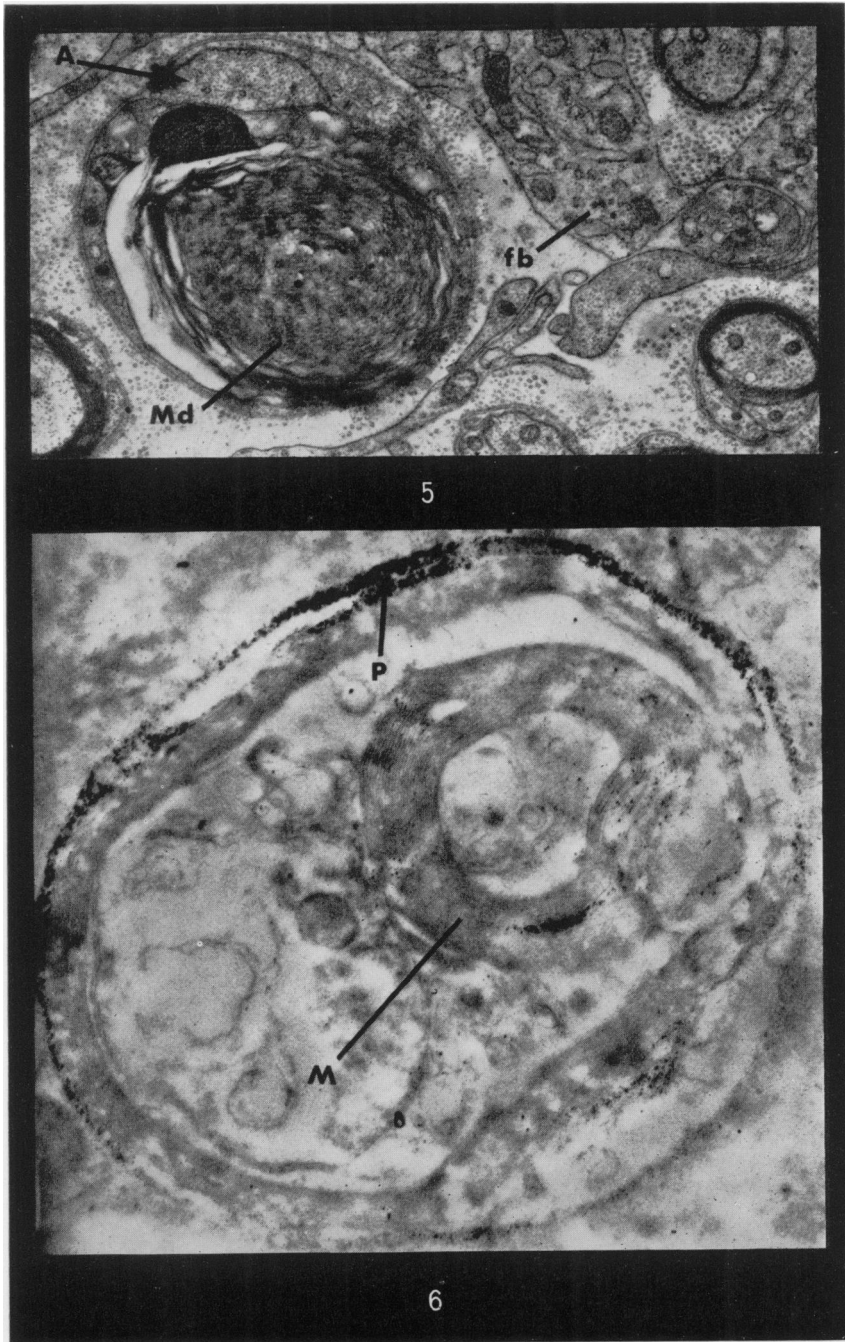
Ten days after section of the nerve the Schwann cells are hypertrophied and swollen with vacuoles containing myelin debris. Many of the vacuoles seem empty; others contain membrane fragments, and in a few cells, considerable amounts of compact myelin still remain. There are many macrophages in the endoneurial spaces distinguishable from Schwann cells by their typical ruffle border of cytoplasmic projections and by the absence of a basement membrane. Sometimes, however, macrophages are present inside basement membrane

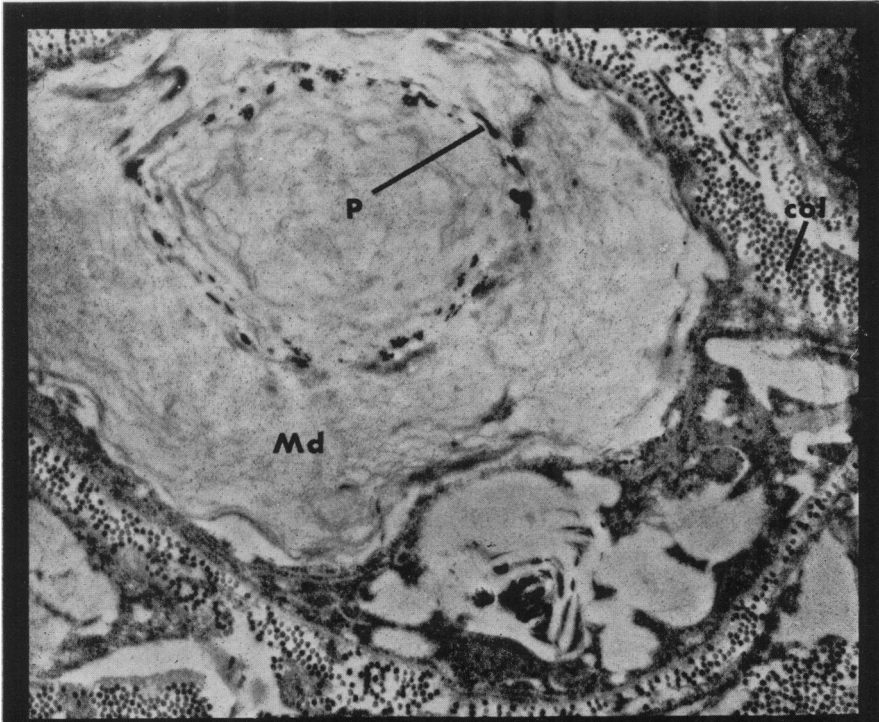
EXPLANATION OF PLATES

- FIG. 2.—T.S. Normal chicken nerve. The axon is surrounded by the myelin sheath (m). Schwann cytoplasm (sc.) is present both outside the sheath and in pockets within the circumference of the sheath. Basement membrane (b). Osmium fixed, PTA stained. $\times 11,100$.
- FIG. 3.—T.S. Chicken nerve 5th day diphtheritic neuropathy. The axon is surrounded by myelin, and acid phosphatase reaction product is present in a cluster of lysosomes (L) each measuring $0.15-0.2\mu$ in diameter. Glutaraldehyde fixed. Incubated in Gömöri medium post-osmicated but unstained. $\times 18,700$.
- FIG. 4.—L.S. Chicken nerve 6th day diphtheritic neuropathy. The myelin is intact and acid phosphatase is present in a lysosome (L) 0.75μ in diameter situated in the Schwann cytoplasm outside the sheath. Glutaraldehyde fixed. Incubated in Gömöri medium, post-osmicated but unstained. $\times 28,000$.
- FIG. 5.—T.S. Chicken nerve 6th day diphtheritic neuropathy. The myelin debris (Md) and the axon (A) are in separate parts of the Schwann cell. Fibroblast (fb.). Osmium fixed, stained with PTA. $\times 10,500$.
- FIG. 6.—Sixth Day diphtheritic neuropathy. A vacuole containing myelin, similar to that in Fig. 5 stained for acid phosphatase. The enzyme reaction product (P) is mainly around the edge of the autophagic vacuole. However, some is associated with the compact myelin (M) within the vacuole. Glutaraldehyde fixed, incubated in Gömöri medium post-fixed in osmium but unstained. $\times 23,000$.
- FIG. 7.—Tenth Day Wallerian degeneration. The Schwann cell is hypertrophied and dilated with vacuoles containing myelin debris (Md). Acid phosphatase reaction product (P) is associated mainly with the membranous myelin debris. Collagen (col). Glutaraldehyde fixed, incubated in Gömöri medium post-fixed in osmium stained with PTA. $\times 11,400$.
- FIG. 8.—Tenth Day Wallerian degeneration. Many vacuoles (vac) are present in the Schwann cell; some contain membranous myelin debris with enzyme reaction product associated with it (P). Elongated vesicles containing acid phosphatase may represent the Golgi apparatus (G). Collagen (col). Glutaraldehyde fixed, incubated in Gömöri medium post-fixed in osmium, stained with PTA. $\times 8,800$.

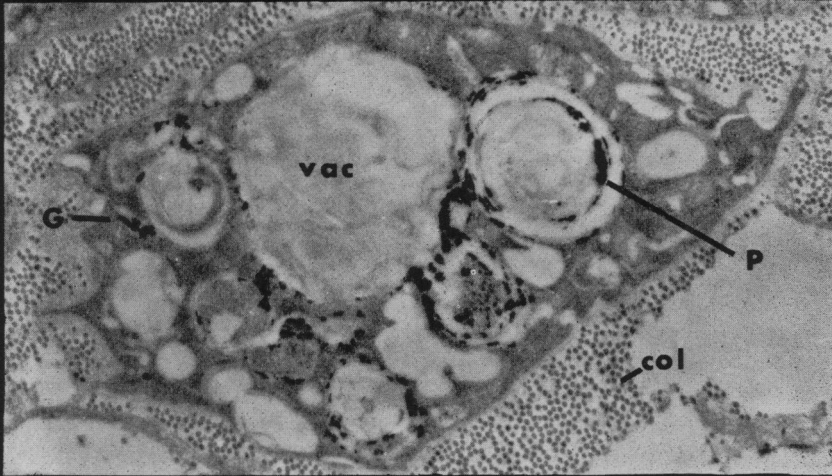








7



8

tubes as Thomas (1964) has shown in the Wallerian degeneration in the rabbit and Speidel (1935) has demonstrated in the frog tadpole. The macrophages in this position can only be identified by their cytoplasmic or nuclear characteristics. Enzyme activity was observed in some macrophages either within lysosomes or in the smooth surface endoplasmic reticulum.

The amount of acid phosphatase activity in the Schwann cells varies widely and appears to be closely related to the stage of structural breakdown of the myelin debris. Very little activity is found associated with compact, well preserved, myelin, whereas a marked reaction is observed in Schwann cell vacuoles containing only a few membranous strands (Figs 7 and 8).

The source of the enzyme was not clearly defined but in some cells small pockets of enzyme activity, 0.75μ in diameter, were seen in association with the larger myelin containing vacuoles. Other cells, containing myelin in a more advanced stage of degradation, exhibit enzyme activity in flattened elongated vesicles which may possibly be derived from the Golgi agranular endoplasmic reticulum (Fig. 8).

Control specimens placed in $0.01M$ NaF for 30 min. at 37° before 2 hr. incubation in the Gömöri medium show no gross lead deposits in the 10 day Wallerian degeneration or the 6th day diphtheritic nerves. There are, however, minute granules deposited on the myelin lamellae especially where there is splitting of intact myelin and also within many fibroblast and macrophage nuclei. We have regarded this staining as non-specific in the interpretation of the other material.

DISCUSSION

The results of the biochemical estimation of acid phosphatase activity have shown a rapid rise in the enzyme content of the sciatic nerve during the first 5 days after intraneural inoculation of diphtheria toxin. This is the period during which there is little or no breakdown of myelin detectable by either light or electron microscopy. These observations are in close agreement with the electron histochemical studies which demonstrate the accumulation of acid phosphatase within primary lysosomes prior to the onset of myelin breakdown.

The pattern of enzyme increase during the first week of Wallerian degeneration differs from that in diphtheritic neuropathy. There is only a slight rise in enzyme activity in the nerve preceding the stage of chemical breakdown of myelin which begins at the end of the first week (Johnson, McNabb and Rossiter, 1950; Adams and Tuqan, 1961). Thereafter there is a more rapid rise in acid phosphatase content of the degenerating nerve. The difference between the enzyme activity in the two lesions is even more striking if the amount of acid phosphatase activity is related to the proportion of myelin sheaths breaking down, for there is total myelin breakdown during Wallerian degeneration whereas only some 50 per cent of the myelin degenerates in the local diphtheritic lesion.

The increased acid phosphatase activity during Wallerian degeneration has been observed in previous biochemical estimations (Heinzen, 1947; Hollinger, Rossiter and Upmalis, 1952). Their estimations, however, were performed at a later stage than in the present study. Hollinger *et al.*, 1952, working with cat sciatic nerve, found an increase in enzyme activity from the normal range of $0.27-64\mu g.$ P/hr./mg. to between $0.97-2.4\mu g.$ P/hr. mg. at 16 days after nerve section. They suggested that the rise in acid phosphatase activity was due to the

rapid increase in cell population during the second week as observed in the rabbit by Abercrombie and Johnson (1946). The same conclusion would also hold for Wallerian degeneration in the chicken where the increase in cell population is also much greater during the second week than during the first (Cavanagh and Webster, 1955).

Electron microscopy of the nerves during the first week of Wallerian degeneration in the chicken has only demonstrated acid phosphatase in macrophages, whereas during the second week most of the enzyme activity seems to be within the Schwann cell vacuoles containing myelin debris.

Acid phosphatase has been used in the present study as an index of lysosomal activity, for it is an acid hydrolase which can be reliably demonstrated by electron microscopy. The origin of lysosomes in various tissues has been studied by cytochemical methods. Liver cells and neurones have been widely investigated and the production of acid hydrolases by the ribosomes, the transport of the enzymes through granular endoplasmic reticulum to the Golgi apparatus has been proposed by Goldfischer, Essner and Novikoff (1964) and by Novikoff, Essner and Quintana (1964). These authors suggest that lysosomes arise from the "pinching off" of vesicles from the Golgi saccules. Brandes (1965), however, has produced evidence for the production of lysosomes in the cytoplasm between the saccules of granular endoplasmic reticulum in rat prostate epithelium.

There appear to be two main sites of lysosome accumulation within the Schwann cell during the early stages of diphtheritic neuropathy. One is within the Schwann cytoplasm external to the intact myelin sheath and it is possible that these lysosomes may be derived from the Golgi apparatus. The other site is within the small pockets of cytoplasm in the juxta-axonal region, separated from the nucleus and the Golgi apparatus by the intact myelin sheath. The only organelles that have been found in the normal nerve in this situation are free ribosomes and, occasionally, mitochondria. It seems probable that the lysosomal enzymes in this isolated region may be produced in association with the ribosomes within the cytoplasmic pockets and that the investing membrane could be derived either from the plasma membrane or may be produced *in situ*.

Gould and Holt (1961) have studied lysosomal activity during Wallerian degeneration in the rat and have shown an increase in lysosomes in the Schwann cytoplasm during the second week after section. The lysosomes possibly originate from the Golgi apparatus in the perinuclear region, and from the present electron microscopic studies it also seems possible that the acid phosphatase may accumulate within the flattened Golgi saccules.

The conclusion drawn from these observations is that there are at least two different mechanisms whereby the breakdown of the myelin sheath is initiated. In Wallerian degeneration it is generally conceded that the initial fragmentation of the myelin into coarse droplets is the result of disintegration of the axon and the retraction of the Schwann cell cytoplasm from the nodes of Ranvier. This early change is accompanied by little chemical degradation, and enzymatic changes including increased acid phosphatase activity are not marked until the end of the first week. By this time physical disorganisation of the myelin sheath is advanced. By contrast, in the segmental demyelination seen in diphtheria intoxication striking increases in acid phosphatase activity have been shown to occur before there are any discernible changes in either the function of the nerve or in the structure of the myelin sheath. These enzyme changes continue after

myelin breakdown commences, but unlike Wallerian degeneration, acid phosphatase and possibly other lysosomal enzymes here may well play a role in initiating the disintegration of the myelin sheath.

It is not known precisely how diphtheria toxin produces these selective lesions in Schwann cells. While it is possible that it directly induces lysosome formation, it is more probable that this is a non-specific end result of a general disturbance to the metabolism of the cell. Moreover, partial internodal breakdown, similarly affecting paranodal regions, occurs in experimental chronic lead poisoning (Gombault, 1880) and in one type of diabetic neuropathy (Thomas and Lascelles, 1965). It is likely that a comparable mechanism may well be operating in these conditions.

SUMMARY

Acid phosphatase activity has been studied biochemically and electron histochemically during the early stages of diphtheritic neuropathy and Wallerian degeneration in the young chicken.

Biochemical estimations showed a steep rise in the enzyme activity during the first week of the diphtheritic lesion preceding the onset of myelin breakdown; by contrast the increase of enzyme in Wallerian degeneration followed myelin fragmentation and was most marked during the second week when chemical breakdown of myelin occurs.

Electron histochemical studies showed an accumulation of primary lysosomes containing acid phosphatase in Schwann cells in association with the intact myelin sheath during the first week in diphtheritic neuropathy. The close association of acid phosphatase with the breakdown of myelin subsequent to this was also demonstrated. In Wallerian degeneration, acid phosphatase activity was visualised in endoneurial macrophages at 6 days, and in Schwann cells at 10 days. The amount of enzyme activity present was greater as the myelin became more degraded. It is concluded that myelin breakdown in segmental demyelination differs from that in Wallerian degeneration and that it may be initiated by lysosomal activity.

We are most grateful to Dr. J. B. Cavanagh for his advice and criticism of the work, the National Spastics Society for the use of the electron microscope, and the Multiple Sclerosis Society and the National Fund for Research into Poliomyelitis and Other Crippling Diseases, who supported one of us in the latter part of the study.

REFERENCES

- ABERCROMBIE, M., JOHNSON, M. L. (1946) *J. Anat. (Lond.)*, **80**, 37.
ADAMS, C. W. M. AND TUQAN, N. A. (1961) *J. Neurochem.*, **6**, 334.
BRANDES, D. (1965)—*J. Ultrastructure Res.*, **12**, 63.
BRIERLEY, J. B. AND FIELD, E. J.—(1949) *J. Neurol. Neurosurg. Psychiat.*, **12**, 86.
CAJAL, S. RAMON Y.—(1928) 'Degeneration and regeneration of the nervous system'. Oxford University Press.
CAVANAGH, J. B. AND JACOBS, JEAN M.—(1964) *Br. J. exp. Path.* **45**, 309.
CAVANAGH, J. B. AND WEBSTER, G. R.—(1955) *Quart. J. exp. Physiol.*, **40**, 12.
DE DUVE, C.—(1964) *Fed. Proc.*, **23**, 1045.
GOLDFISCHER, S., ESSNER, E. AND NOVIKOFF, A. B.—(1964) *J. Histochem., Cytochem.*, **12**, 72.

- GOMBAULT.—(1880) 'Empoisonnement lent par le plomb chez le cochon d'Inde'. *Progrès medical* 1880, No. 10.
- GÖMÖRI, G.—(1952) 'Microscopic histochemistry'. Chicago (University of Chicago Press), p. 189.
- GOULD, R. P. AND HOLT, S. J.—(1961) In: 'Cytology of Nervous Tissue'. Supplement, Symposium of Anatomical Society of Great Britain and Ireland. London, p. 45.
- GUTH, L.—(1956) *Physiol. Rev.*, **36**, 441.
- HEINZEN, B.—(1947) *Anat. Rec.*, **98**, 193.
- HOLLINGER, D. M., ROSSITER, R. J. AND UPMALIS, H.—(1952) *Biochem. J.*, **52**, 652.
- HOLT, S. J. AND HICKS, R. MARIAN—(1961) *J. biophys. biochem. Cytol.*, **11**, 31.
- JACOBS, J., CAVANAGH, J. B. AND MELLICK, R. S.—(1966) *Br. J. exp. Path.*, **47**, 507.
- JENNER, H. D. AND KAY, H. D.—(1932) *Br. J. exp. Path.*, **13**, 22.
- JOHNSON, A. C., McNABB, A. R. AND ROSSITER, R. J.—(1950) *Arch. Neurol and Psychiat.*, **64**, 105–121.
- KING, E. J. AND ARMSTRONG, A. R. —(1934) *Can. med. Ass. J.*, **31**, 376.
- KING, E. J. AND WOOTTON, I. D. P.—(1956) 'Micro Analysis in Medical Biochemistry'. 3rd Ed. London (Churchill), p. 87.
- MCDONALD, W. I.—(1963) *Brain*, **86**, 481.
- MEYER, P.—(1881) *Virchows Arch. f. path. Anat.*, **85**, 181.
- NATHANIEL, E. J. H. AND PEASE, D. C.—(1963). *J. Ultrastructure Res.*, **9**, 511.
- NOVIKOFF, A. B., ESSNER, E. AND QUINTANA, N.—(1964) *Fed. Proc.*, **23**, 1010.
- PALADE, G. E.—(1952) *J. exp. Med.*, **95**, 285.
- SHELDON, H. ZETTERQVIST, H., AND BRANDES, D.—(1955) *Exp. Cell. Res.*, **9**, 592.
- SPEIDEL, C. C.—(1935) *J. Comp. Neurol.*, **61**, 1.
- THOMAS, P. K.—(1964) *J. Anat. (Lond.)*, **98**, 175.
- THOMAS, P. K. AND LASCELLES, R. G.—(1965) *Lancet* *i*, 1355.
- WAKSMAN, B. H., ADAMS, R. D. AND MANSMANN, H. C. Jr.—(1957) *J. exp. Med.*, **105**, 591.
- WEBSTER, H. DE F. AND SPIRO, D.—(1960) *J. Neuropath. Exp. Neurol.*, **19**, 42.
- WEBSTER, H. DE F., SPIRO, D., WAKSMAN, B. H. AND ADAMS, R. D.—(1961) *J. Neuropath. Exp. Neurol.*, **20**, 5.
- WEDDELL, G. AND GLEES, P.—(1941) *J. Anat. (Lond.)*, **76**, 65.
- WELLER, R. O.—(1965) *J. Path. Bact.*, **89**, 591.
- YOUNG, J. Z.—(1942) *Physiol. Rev.*, **22**, 318.
-