

VENEREAL SPIROCHETOSIS IN AMERICAN RABBITS.

By HIDEYO NOGUCHI, M.D.

(From the Laboratories of The Rockefeller Institute for Medical Research.)

PLATES 17 TO 20.

(Received for publication, November 10, 1921.)

Ross,¹ in 1912, in a discussion of an intracellular phase of *Treponema pallidum*, mentioned a disease of rabbits characterized by chancres, buboes, ulcers on the genitals, mouth, anus, etc., in which he reported finding cell inclusions in the mononuclear leucocytes similar to those which he had found in human syphilis. He suspected that there might be a spiral phase of the parasite of the rabbit disease, and Bayon² undertook the examination of the genital lesions, in which he found a spiral organism indistinguishable from *Treponema pallidum*. Similar lesions appeared in other rabbits 25 days after inoculation of the material containing the spiral organism. Bayon described the rabbit spirochete as being about one and a half times the diameter of a blood corpuscle in length, having 5 to 8 closely set, deep, rather elastic curves, and showing rotating but not lashing movements. He remarked that students of experimental syphilis in the rabbit should take note of the presence of this new species of *Treponema*.

Arzt and Kerl,³ in 1914, reported finding in a peculiar scaly, papular, or erosive lesion, with crust, around the anogenital region of apparently normal rabbits, spiral organisms morphologically indistinguishable from *Treponema pallidum*. Of 850 rabbits examined by them, 26.9 per cent showed the same organism, and in one series of 189 adult rabbits the spirochetes occurred in 34.4 per cent. Arzt and Kerl transmitted the spirochetal affection by applying to the scarified vulva or prepuce of normal rabbits the exudate from the lesion of a rabbit showing the spontaneous disease. After several weeks incubation, the inguinal lymph nodes became somewhat enlarged, and the spirochetes appeared. Similar lesions of lips and clitoris showed the spirochete in large numbers. Intratesticular inoculations were unsuccessful, possibly because of the contaminated nature of the material, and inoculations into the scarified eyebrows of two monkeys were negative.

¹ Ross, E. H., An intracellular parasite developing into spirochaetes, *Brit. Med. J.*, 1912, ii, 1653.

² Bayon, H., A new species of *Treponema* found in the genital sores of rabbits, *Brit. Med. J.*, 1913, ii, 1159.

³ Arzt, L., and Kerl, W., Weitere Mitteilungen über Spirochätenbefunde bei Kaninchen, *Wien. klin. Woch.*, 1914, xxvii, 1053.

With a view to differentiating between this organism and *Treponema pallidum*, Arzt and Kerl^{3,4} inoculated the testicle of a rabbit suffering from the disease in question with a strain of *Treponema pallidum*. The inoculation was successful, but since a syphilitic rabbit can be superinfected or doubly infected, as shown by Truffi,⁵ and by Uhlenhuth and Mulzer,⁶ no conclusion was drawn. No importance was attached to the Wassermann reaction, and an attempt to employ as antigen in a complement deviation test tissue from syphilitic orchitis of the rabbit failed. Examination of certain stocks in Innsbruck,⁷ where no experimental work on syphilis in the rabbit had ever been done, showed the same disease to prevail.

Similar observations were made on Hamburg rabbits by Jacobsthal in 1920.⁸ The lesions present were situated on the vulva and were of a squamous, erosive kind. The dark-field microscope revealed, in the lesions and in the vaginal secretion, numerous spirochetes resembling *pallidum*. Jacobsthal thought the spiral organism to be a trace thicker than *pallidum* and not to exhibit the undulatory movements so characteristic of the latter. Transmission experiments with mice and guinea pigs were negative, but lesions were reproduced in female rabbits in three instances by scarification of the vulva, after an incubation period of 3 to 6 weeks. A chancre-like lesion was noted in one animal. He proposed calling the disease *paralues cuniculi* and the organism *Spirochæta paraluis cuniculi*.⁹

Later in 1920, Schereschewsky¹⁰ stated that the peculiar lesion of the rabbit disease is of papular and ulcerative form and is transmitted by coitus, the incubation period varying from 14 to 30 days.

In 1921 Klarenbeek¹¹ observed spirochetal lesions in five Dutch rabbits. Inoculations of the spirochete-containing material by scarification into the perineal

⁴ Arzt, L., Spirochätenbefunde in Genitalveränderungen ungeimpfter Kaninchen, *Dermat. Z.*, 1920, xxix, 65.

⁵ Truffi, M., Ueber die Empfänglichkeit des Kaninchens gegenüber syphilitischen Reinfektionen, *Centr. Bakt., 1te Abt., Orig.*, 1910, liv, 337.

⁶ Uhlenhuth, P., and Mulzer, P., Beiträge zur experimentellen Pathologie und Therapie der Syphilis mit besonderer Berücksichtigung der Impf-Syphilis der Kaninchen, *Arch. k. Gesundheitsamte*, 1913, xlv, 307.

⁷ Arzt, L., and Kerl, W., Zur Frage der "Kaninchensyphilis," *Dermat. Woch.*, 1920, lxxi, 1047.

⁸ Jacobsthal, E., Untersuchungen über eine syphilisähnliche Spontanerkrankung des Kaninchens (*Paralues cuniculi*), *Dermat. Woch.*, 1920, lxxi, 569.

⁹ Arzt and Kerl⁷ remind Jacobsthal that neither incubation time nor histological changes of the lesion warrant the differentiation of this disease from experimental syphilis in rabbits.

¹⁰ Schereschewsky, J., Geschlechtlich übertragbare originäre Kaninchensyphilis und Chinin-Spirochätotropie, *Berl. klin. Woch.*, 1920, lvii, 1142.

¹¹ Klarenbeek, A., Recherches expérimentales avec un spirochète, se trouvant spontanément chez le lapin et ressemblant au *Treponema pallidum*, *Ann. Inst. Pasteur*, 1921, xxxv, 326.

region of normal rabbits gave rise, 11 days later, to a slightly excoriated hyperemic reaction without induration, while on the scarified dorsal skin superficial lesions with white crust appeared after 1 to 2 months incubation. The lesions showed spirochetes. Intraocular inoculations in rabbits resulted in some instances in an ulcer on the upper lid and a keratitis after 41 to 43 days; intratesticular inoculations failed to give any spirochetal orchitis.

Spontaneous Instances in America.

The facts reviewed in the foregoing paragraphs suggested the examination of American rabbits. The same condition has been found among the stock rabbits at The Rockefeller Institute. Of 50 rabbits examined in June, 1921, three females and two males were found to have lesions on the vulva, prepuce, and perineum. One (No. 3) of the female rabbits was born at The Rockefeller Institute 6 years ago, has been kept as normal breeding stock ever since, and has never been used for any experimental work.

Recently (November, 1921) six females with similar lesions have been found among twenty rabbits just purchased in Pennsylvania.

Rabbit 1.—Adult female; used for breeding purposes for several months. June 29, 1921. Scaly ulcerative lesions covered with grayish white crusts present on both sides of vulva (Fig. 38). Upon removal of the crusts with forceps, a granular, easily bleeding surface was exposed. The crust and scrapings from the exposed ulcer both revealed the presence in fairly large numbers of a spiral organism resembling *Treponema pallidum* (Figs. 1, 13, and 17). The lesions persisted without much change in extent and character up to the last examination (Sept. 26, 1921). Spirochetes were still numerous. Tissue was removed on June 29, 1921, for inoculation and histological studies. The animal was sacrificed on Sept. 27, and the lymphatic glands were examined for the spirochetes.

Rabbit 2.—Adult nursing female. June 30, 1921. Found to have small, scaly, rather dry lesions on both sides of the vulva; no ulceration. Scrapings examined by dark-field microscope showed in small numbers spirochetes resembling *pallidum*. The lesions remained unchanged up to the last examination (Oct. 13, 1921), but spirochetes were more numerous at that time. The three young rabbits remain entirely free from any lesion, although kept with the mother during a period of 3 months.

Rabbit 3.—Adult female; born at The Rockefeller Institute in 1915 and kept as breeding stock since. June 30, 1921. Scaly, papular elevation or thickening of the vulval region on both sides (Fig. 39), covered by thin grayish crusts over the center of the hyperemic lesions. Examination for spirochetes revealed one fine

type in enormous numbers (Figs. 2 to 4, 14, 15, and 18 to 20) and another decidedly coarser type in smaller numbers (Figs. 5, 6, and 27 to 29). Tissue was excised on June 30, and July 15, 1921, for section and for inoculation. On July 20, 1921, there was no perceptible change in the lesion, and numerous spirochetes were still present (Figs. 9 to 11). This animal was later treated with salvarsan (see below).

Rabbit 4.—Normal adult male; recently purchased. July 6, 1921. Presented small congested and quite swollen but not indurated lesions of the prepuce (Fig. 40), covered with thin crusts; the lesions bled easily when the crusts were removed. The dark-field microscope showed numerous spirochetes similar to those found in the other animals (Figs. 7, 8, 16, and 21 to 24). On July 20, 1921, there were still spirochete-containing lesions. Toward the end of September scaly papular lesions were noticed on nose and lips (Fig. 42), eyelid (Fig. 43), and paws (Fig. 44), and the spirochetes were found to be present there also.

Rabbit 5.—Normal adult male; recently purchased. Sept. 10, 1921. Prepuce swollen and covered with grayish thin scales, under which the tissue was granular, soft, somewhat edematous, and congested (Fig. 41). Numerous spirochetes present. Lesion excised for histological examination.

Spirochetes.

The type of spirochete existing in the lesions of the five rabbits just described closely resembles *Treponema pallidum*. The measurements are: length 10 to 16 μ ; width 0.25 μ . The spiral amplitude, in regular portions, is about 1 to 1.2 μ , and the spiral depth 0.6 to 1 μ ; hence the number of spirals in an individual measuring 10 μ may be about 9 or 10. The last spirals near the extremities are often shallower than those of the middle portion or *vice versa*, and the ends are sharply drawn. A delicate terminal filament has been seen at one, and sometimes at both ends. The shortest specimens measured 7 μ , with 6 spirals, and the longest about 30 μ , with 25 to 28 spirals (Fig. 4). The average is about 12 to 14 μ (Figs. 3, 5, and 6), the organism being slightly longer than the *pallidum* in human lesions. In experimentally inoculated rabbits specimens of *pallidum* as long as 24 μ may be encountered, but the single length is usually 10 to 12 μ (Figs. 12 and 32 to 34). As in the case of *pallidum* (Figs. 35 to 37), specimens with stretched spirals appear in stained preparations (Figs. 25 and 26).

In the lesion of Rabbit 3 there were present two types of spirochete, one the usual fine type and the other decidedly coarser than the average. The morphology of the coarser variety suggests that of

Treponema calligyrum found by the writer in the human condyloma,¹² but it is somewhat longer than *calligyrum* (14 to 18 μ , width 0.35 μ). The spiral amplitude is 1.2 to 1.75 μ and the spiral depth 0.6 to 1.5 μ (Figs. 6 and 27 to 29). This form is perhaps a trace thinner and longer than the *calligyrum*, or medium type smegma treponema of the normal human genitalia. The organism rotates actively, with occasional bending at the middle, but no vibratory or lashing movements have been observed.

The rabbit treponema forms entangled masses of long threads, 30 μ at least (Figs. 4 and 11), a phenomenon I do not recall having seen in the case of *Treponema pallidum*. The agglomeration of organisms in a striking stellate mass of several to a dozen individuals is frequently observed (Fig. 10). A similar behavior has been observed in young, actively motile, pure cultures of *Treponema pallidum*. Both *pallidum* and the rabbit treponema sometimes form a ring by touching one end with the other while actively rotating, and occasionally they make a knot of themselves. In a film preparation from the lesions of Rabbit 3, stained by Fontana's method, occasional wavy, but not spiral forms were seen; perhaps they were degenerated or involution forms (Figs. 30 and 31).

The staining properties of these rabbit spirochetes are the same as those of *Treponema pallidum*. Both can be readily stained by ordinary basic aniline dyes when fixed in a buffered formaldehyde solution, as shown by Miss Tilden.¹³ Jacobsthal proposed for the organism the name *Spirochæta paraluis cuniculi*, but in view of its close resemblance to *Treponema pallidum* and *Treponema pertenuis* it may perhaps be more appropriate to use the simpler name *Treponema cuniculi*.

Examinations of smegma and mucous secretions on the genitalia of many normal male and female rabbits failed to reveal any spirochetal organisms, which circumstance does not of course exclude the possibility that spirochetes are occasionally present in such materials.

¹² Noguchi, H., Cultivation of *Treponema calligyrum* (new species) from condylomata of man, *J. Exp. Med.*, 1913, xvii, 89.

¹³ Noguchi, H., A note on the venereal spirochetosis of rabbits. A new technic for staining *Treponema pallidum*, *J. Am. Med. Assn.*, 1921, lxxvii, 2052.

Histology of the Lesions.

Excised tissue from the undisturbed spontaneous lesion on the prepuce of Rabbit 5 (Fig. 41) was fixed in Zenker's fluid and sections were stained with hematoxylin-eosin and eosin-methylene blue. The epidermis was thickened and the papillæ were large and prominent; the infiltration was spotty and mainly confined to the interpapillary layers. The new cells were mainly mononuclear, partly eosinophils, and few or no polymorphonuclears were present. In general features the lesion suggests a condyloma. Although certain blood vessels were surrounded by mononuclear cells, no definite endothelial proliferation was apparent (Fig. 48). The lesion as described may be taken as the pure type before secondary bacterial infection has come in to induce acute inflammation and mar the picture. Once ulceration has taken place, as in the vulval lesions of Rabbits 1 and 3 (Figs. 38 and 39), the interpapillary infiltration of mononuclear cells is accompanied by numerous polymorphonuclear leucocytes, which invade also the stratified layers of the thickened epidermis. Minute hemorrhages and necrotic foci are then occasionally met with.

For comparison with these lesions, a scrotal chancre was induced with the Nichols strain of *Treponema pallidum* long adapted to the rabbit (since 1912). The chancre on the 28th day was indurated and stood out as an oval mass from the surrounding loose connective tissue (Fig. 47); in histology it differed widely from the genital lesions induced by the rabbit spirochete. The corium was highly infiltrated with mononuclear cells, some showing eccentric nuclei and checker-board chromatin. Polymorphonuclear leucocytes were absent. But the striking difference was in the blood vessels, which were surrounded by the new cells (Fig. 49).

Repeated attempts to stain the spiral organism in the tissue by means of silver impregnation have been only partially successful. The organisms near the surface of the lesion took the stain. By careful teasing of the deeper layers and dark-field examination, spirochetes have been found to be present in all parts of the lesions.

Transmission Experiments.

First Passages.—Sixteen rabbits and four monkeys¹⁴ (*Macacus rhesus*) were inoculated with the material containing the spirochetes, usually on the scarified prepuce or vulva. In rabbits some intratesticular, intracorneal, and intraocular inoculations were made; in monkeys the scarified eyebrows, as well as prepuce or vulva, were smeared with the scraping of the rabbit lesion. Each of the original rabbits was paired in a separate cage with a normal rabbit of opposite sex for the purpose of sexual transmission.

Reproduction of the disease on the vulva or prepuce respectively was obtained in all five of the female and in eight of the eleven male rabbits inoculated (Table I). One strain (Rabbit 3) produced in two male rabbits a superficial scaly, papular lesion on the scrotal skin at the site of testicular inoculation (Fig. 45), and in one of them a lesion developed also on the prepuce. The results of intratesticular inoculation were in general unsatisfactory. In most cases, owing to the impure nature of the material, a more or less acute suppurative orchitis ensued, and no spirochetes were present in these lesions. Negative results also followed intraocular and intracorneal inoculations and the application of the material to the scarified surface of the cornea. The lymph glands were not noticeably enlarged either in the original rabbits or in those inoculated. The inoculation of emulsions of popliteal and inguinal lymph glands from ten rabbits infected with *Treponema cuniculi* into both testicles of four normal male rabbits did not produce any orchitis within 3 months. On the other hand, similar emulsions from rabbits infected with *Treponema pallidum* gave rise to typical orchitis within 1 month.

¹⁴ Four additional monkeys were later inoculated with different strains of *Treponema cuniculi*, but none showed any lesion during a period of observation of 3 months. In order to determine whether the adaptation to rabbits of the human strain of *Treponema pallidum* had rendered it avirulent for monkeys, two monkeys were inoculated with the Nichols strain (1912). Both presented typical lesions within 1 month. Two monkeys inoculated from a case of human chancre showed typical lesions within 2 months. The pathogenicity of *Treponema cuniculi* appears, therefore, to be different from that of *Treponema pallidum* of human syphilis.

TABLE I.
Transmission Experiments.

Animal No.	Sex.	Source of inoculated material.	Site of inoculation.	Date and mode of inoculation.	Results.	Period of incubation.	Remarks.
Rabbits. 6	Female.	Rabbit 1	Vulval mucosa.	June 30, 1921. Scarification and smearing.	Scaly lesion at site of inoculation first noticed Sept. 26, 1921.	88 days	
7	"	" 1	"	"	Definite lesion Sept. 13, 1921.	75	
8	Male.	" 1	Prepuce.	"	Ulcer with thin crust on prepuce Aug. 10, 1921.	41	
9	"	" 1	"	"	No lesion after 90 days.		
10	"	" 1	"	"	Definite scaly lesion around anus Sept. 26, 1921.	88	
			Right cornea.	"	No lesion after 90 days.		
			" testicle.	June 30, 1921. 1 drop intratesticularly.	No orchitis after 90 days.		
11	"	" 1	Prepuce.	June 30, 1921. Scarification.	Definite lesion Sept. 26, 1921.	88	
			Right cornea.	"	No lesion after 90 days.		

11	Male.	Rabbit 1	Right testicle.	June 30, 1921. 1 drop intratesticularly.	Abscess formation and induration lasting for 1 mo. No spirochetes found in testicular puncture.	
<i>Macacus rhesus.</i> 1	"	" 1	Prepuce. Left eyebrow.	June 30, 1921. Scarification. "	No lesion after 80 days. "	Reinoculated with material from Rabbit 4, Sept. 19, 1921.
2	"	" 1	Prepuce. Left eyebrow.	" "	" "	"
Rabbits. 12	Female.	" 2	Vulva.	July 1, 1921. Scarification.	Scaly lesion Sept. 13, 1921, since spread.	75
13	"	" 2	"	"	Small lesion July 20, 1921, now slightly increased.	20
14	Male.	" 2	Prepuce. Cornea. Right testicle.	" " July 1, 1921. Intratesticular.	Definite lesion Aug. 17, 1921. None. Abscess formation in 7 days, extended to left testicle.	47

TABLE I—Concluded.

Animal No.	Sex.	Source of inoculated material.	Site of inoculation.	Date and mode of inoculation.	Results.	Period of incubation. days	Remarks.
Rabbits. 15	Male.	Rabbit 2	Prepuce. Cornea. Right testicle.	July 1, 1921. Scari- fication. " July 1, 1921. Intra- testicular.	Definite lesion Sept. 26, 1921. None. Suppurative lesions after 1 wk., re- mained firm for 40 days.	88	
<i>Macacus rhesus</i> . 3	"	" 2	Prepuce. Right eye- brow.	July 1, 1921. Scari- fication. " "	None. " "		
4	Female.	" 2	Vulva. Eyebrow.	" "	" "		
Rabbits. 16	"	" 3	Vulva.	July 2, 1921. Scari- fication. "	Definite lesion Aug. 16, 1921.	45	
17	Male.	" 3	Prepuce.	" "	Definite lesion Aug. 17, 1921.	46	
			Both testicles.	July 2, 1921. Intra- testicular.	Scab at lower part of left scrotum Aug. 17, 1921. Lesion slightly indurated and many spiro- chetes found.	46	
18	"	" 3	Prepuce.	July 2, 1921. Scari- fication.	No lesion developed.		

18	Male.	Rabbit 3	Right testicle.	July 2, 1921. Intra-testicular.	Abscess formation. Scaly lesions on left scrotum Aug. 20, 1921. Spirochetes+.	49	Photographed (Fig. 45) Sept. 13, 1921 (73 days).
19	"	" 3	Prepuce.	July 5, 1921. Scarification.	Definite lesion Sept. 13, 1921.	70	
<i>Macacus rhesus.</i> 3	"	" 3	Left testicle.	July 5, 1921. Intra-testicular.	No lesion developed.		
	"	" 3	" eyebrow.	July 2, 1921. Scarification.	" " "		Right eyebrow had been inoculated from Rabbit 3 on July 1, 1921.
Rabbits. 20	"	" 4	Prepuce.	July 5, 1921. Scarification.	Definite lesion Aug. 10, 1921.	36	
	"	" 4	Cornea.	July 2, 1921. Intra-corneally with syringe.	Opacity still persists after 85 days.		
21	"	" 4	Both testicles.	July 2, 1921. Intra-testicular.	Two small nodules on left testicle (no spirochetes).		
	"	" 4	Prepuce.	July 5, 1921. Scarification.			Died of septicemia in 8 days.
	"	" 4	Eye.	July 5, 1921. Intraocular (anterior chamber).			
			Both testicles.	July 5, 1921. Intra-testicular.			
Average.....						60½	

The period of incubation varied from 20 to 88 days, the average being $60\frac{1}{2}$ days.

Subsequent Passages.—All five strains are being maintained in rabbits. The strain from Rabbit 1 has now passed through four transfers: first, June 30, 1921, positive September 13 (75 days); second, September 27, positive October 17 (20 days); third, October 17, positive October 22 (5 days); fourth, October 24, positive November 10 (17 days).

Inoculations of monkeys have remained up to the present (4 months) without result. One of the monkeys was inoculated with two different strains, on right and left eyebrow respectively. Two other monkeys have recently been reinoculated in the eyebrow, and also into the hypogastric region, with a hypodermic needle, the infective material being deposited intradermally.

Sexual Transmission.—Rabbit 1 was kept in the same cage with three males successively (July 12 to September 26), Rabbit 2 with two males, and Rabbit 3 with one male (July 12 to October 15). Rabbit 2, 3 months after having been placed with Rabbit 3, showed a small papular lesion on the prepuce in which spirochetes were numerous.

Attempts to Produce Chancre on the Scrotum.

Treponema pallidum from human syphilis is capable of producing chancre-like lesions on the scrotum of rabbits when a small piece of *pallidum*-containing tissue is subcutaneously introduced (Tomasczewski,¹⁵ Uhlenhuth and Mulzer,⁶ Brown and Pearce,¹⁶ and others). To determine whether or not the rabbit spirochete is capable of producing a similar lesion in rabbits, portions of the erosive, spirochete-containing lesion from the vulvolabial region of Rabbit 3 were introduced into the subcutaneous pocket of each of the scrota of two adult male rabbits, two other adult males being simultaneously inoculated with fragments of freshly excised scrotal chancre from a syphilitic rabbit (Nichols strain).

¹⁵ Tomasczewski, Ueber eine einfache Methode, bei Kaninchen Primäraffekte zu erzeugen, *Deutsch. med. Woch.*, 1910, xxxvi, 1025.

¹⁶ Brown, W. H., and Pearce, L., Experimental syphilis in the rabbit. II. Primary infection in the scrotum. Part 1. Reaction to infection, *J. Exp. Med.*, 1920, xxxi, 709.

One of the rabbits (No. 23) inoculated with the rabbit spirochete showed at one site of insertion after 27 days a small crust under which the surface was soft, pale, and granular, but there was no marked induration. Spirochetes were not found in the lesion until 45 days after inoculation. The other site remained small and reddish, with a trace of infiltration, but no spirochetes were found. The other rabbit (No. 24) showed slight infiltration at one site of insertion (Fig. 46), but no definite, chancre-like induration developed during 2 months observation. Brownish scaly patches rich in spirochetes appeared on the right scrotum after 45 days.

Of the two syphilitic controls, Rabbit 25 developed within 3 weeks at the site of insertion on the right scrotum a typical chancre which attained a diameter of 2 cm. in 28 days (Fig. 47). The second control (Rabbit 26) had not developed a chancre 75 days after inoculation. Two rabbits inoculated with chancre material from Rabbit 25 developed typical chancres within 3 weeks, while simultaneous inoculations from the slightly indurated (*cuniculi*) lesion of Rabbit 23 were unsuccessful.

It is possible that a chancre may yet be produced with the rabbit spirochete by inoculation of a large number of animals. The number of spirochetes in the *pallidum* chancre of rabbits is never as large as that found in the *cuniculi* lesions in rabbits.

For the purpose of comparison, *pallidum*-containing material was applied to the scarified prepuce or vulva of rabbits and gave rise to chancre-like nodules. The appearance of these lesions, however, was entirely different from that of the lesions produced by *Treponema cuniculi*.

Typical *cuniculi* lesions may be produced on the scrotal skin or prepuce of rabbits having active *pallidum* lesions, and the reverse is also true. The infections appear to follow independent courses.

Wassermann Reaction.

The sera of the eleven rabbits with spontaneous lesions, and of thirty-three experimentally inoculated from them, have been tested for the Wassermann reaction. The acetone-insoluble lipoids served as antigen, and the inactivated sera were used in quantities of 0.1 and 0.2 cc. Twenty-four of the animals had active, spirochete-

containing lesions of the genital region at the time of test; twenty had recently been inoculated and had not developed any lesions. The results of the tests were uniformly negative.

The sera of four rabbits having active scrotal chancres (Nichols strain of *Treponema pallidum*) were simultaneously tested; three gave a strongly positive (+++), and the other a partial (+) reaction. Twelve rabbits which had developed chancres 2 months after inoculation on vulva or prepuce with *pallidum* gave strongly positive (++++) reactions.

Thus far positive Wassermann reactions have been obtained only with the sera of rabbits having active syphilitic lesions. Apparently no complement-fixing substance, such as exists in the blood of syphilitic human beings or experimentally infected syphilitic rabbits, was present in the blood of animals which had been infected with the rabbit treponema for periods varying from 1 or 2 weeks to many months. Whether or not the fixing substance will eventually appear in the sera of these rabbits remains to be seen.

Effect of Salvarsan.

Rabbit 3 was given intravenously on August 17, 1921, 0.02 gm. of salvarsan per kilo of body weight. Rabbit 27, having a chancre of thumb size on each scrotum, was similarly treated at the same time to serve as control.

Rabbit 3.—Aug. 17, 1921. Showed papuloedematous, partially eroded, moist lesion, extending over the entire vulval region, including the labial mucosa and adjacent skin; perineum also scaly, congested, and swollen. Dark-field examination revealed spirochetes in large numbers. 5 p.m. 4.4 cc. of a 1:10 dilution of slightly alkaline salvarsan solution was intravenously administered (0.02 gm. per 1,000 gm. of body weight). Aug. 18, 5 p.m. Considerable reduction in swelling, less irritation, apparent drying up of lesion; no spirochetes found. Aug. 20. Lesion near hair line of vulva still somewhat moist and crusted, inferior portion practically healed; anal lesion still present. Spirochetes were no longer found in any of the suspicious spots. Aug. 26. Only small scabs present. Sept. 13. Slight scaliness at hair line of vulva; no spirochetes.

Rabbit 27.—Aug. 17, 1921. Chancre (human strain isolated by Nichols in 1912, since maintained in rabbits) on each scrotum, 2 cm. in diameter; cartilaginous induration, with small umbilicated center covered by dark dry crust. Many

spirochetes present. 5 p.m. 5 cc. of a 1:10 dilution of slightly alkaline salvarsan (0.02 gm. per 1,000 gm. of body weight) intravenously administered. Aug. 18. Lesions softer, smaller; no spirochetes. Aug. 20. Lesions soft. Aug. 23. Lesions have almost disappeared. Sept. 13. No trace of lesions found.

The experiment indicates that the *cuniculi* lesions and the experimental scrotal chancre caused by *Treponema pallidum* from human syphilis are similarly influenced by salvarsan. In both instances the spirochetes disappeared within 24 hours after the administration of the drug, and the lesions themselves within 9 days. No recrudescence has occurred.

DISCUSSION AND SUMMARY.

Of 50 rabbits, otherwise regarded as normal, three adult females and two adult males (10 per cent) have been found to have in their genitoperineal region certain papulosquamous, often ulcerating, lesions. A recently purchased group of twenty rabbits contained six females (30 per cent) with similar lesions. This condition runs a chronic course and is characterized by the presence of a spiral organism closely resembling *Treponema pallidum*.

The rabbit spirochete has the same morphological features as *Treponema pallidum*; it is possibly a trifle thicker and longer than the average *pallidum*. Long specimens measuring 30 μ are frequently encountered, and they show a tendency to form loosely entangled knots. A stellate arrangement of several organisms in a mass is frequently observed.

In the lesion of one rabbit there were two types of spirochete, one of the variety just described, the other a somewhat coarser organism, closely resembling *Treponema calligyrum* found in a human condyloma, but a trifle thinner and longer. This organism is perhaps merely a variant type of the rabbit spirochete.

The histological reactions are similar to, but considerably less cellular, than those occurring in typical primary syphilitic lesions. There is a marked hyperkeratosis and interpapillary infiltration not observed in scrotal chancre.

The disease is transmissible to normal rabbits, in which the usual papular lesions can be readily reproduced in the genitoperineal region. In the first passages the incubation period varied from 20 to

88 days; subsequently one of the strains produced a lesion in 20 days on the second, and in 5 days on the third passage. No typical orchitis or keratitis was produced in the rabbits of the present series, although in one of the original rabbits (No. 4) scaly, papular lesions have developed on the nose, lips, eyelid, and paws. Monkeys (*Macacus rhesus*) failed to show any lesions within a period of 4 months after inoculation.

In one instance transmission was accomplished through the mating of an infected female with a normal male.

The Wassermann reaction was uniformly negative in the five rabbits with spontaneous lesions and in eighteen rabbits experimentally infected.

Salvarsan had the same therapeutic effect on the lesions produced by the rabbit spirochete as on the experimental *pallidum* lesion of the rabbit.

The organism belongs to the genus *Treponema*, and may be designated *Treponema cuniculi*.

EXPLANATION OF PLATES.

PLATE 17.

Dark-field photographs. Magnification $\times 1,000$.

FIG. 1. *Treponema cuniculi* from Rabbit 1.

FIGS. 2 to 5. *Treponema cuniculi* from Rabbit 3. Fig. 4 shows one of the very long specimens.

FIG. 6. The coarser type of treponema from Rabbit 3.

FIGS. 7 and 8. *Treponema cuniculi* from Rabbit 4.

FIGS. 9 to 11. *Treponema cuniculi* from Rabbit 3. Fig. 11 shows an entangled mass of the long forms. Fig. 10 illustrates the agglomeration of organisms in stellate form which is frequently seen.

FIG. 12. *Treponema pallidum* from experimental syphilitic orchitis in the rabbit.

PLATE 18.

Magnification $\times 1,000$.

FIG. 13. Film preparation of exudate from Rabbit 1, stained with Giemsa solution.

FIGS. 14 and 15. Film preparation of exudate from Rabbit 3, stained with Giemsa solution.

FIG. 16. Film preparation of exudate from Rabbit 4; Giemsa stain.

FIG. 17. Film preparation from Rabbit 1, stained by Fontana's method.

FIGS. 18 to 20. Film preparation from Rabbit 3, stained by Fontana's method.

FIGS. 21 to 24. Film preparation from Rabbit 4, stained by Fontana's method.

FIGS. 25 and 26. Irregular forms of *Treponema cuniculi* from Rabbit 3, stained by Fontana's method.

FIGS. 27 to 29. Spirochetes resembling *Treponema calligyrum* from Rabbit 3, stained by Fontana's method.

FIGS. 30 and 31. Non-spiral forms from Rabbit 3.

FIGS. 32 and 33. *Treponema pallidum* in rabbit orchitis, stained by Fontana's method.

FIG. 34. *Treponema pallidum* in rabbit orchitis. Mordant Gentian violet.

FIGS. 35 to 37. Irregular forms of *Treponema pallidum* from experimental scrotal chancre, stained by Fontana's method.

PLATE 19.

FIGS. 38 to 41. Typical lesions (from Rabbits 1, 3, 4, and 5 respectively) on the rabbit genitalia.

FIG. 42. Lesions in Rabbit 4 on the nose and left upper lip.

FIG. 43. The same, on the left eyelid.

FIG. 44. The same, on the left paw near the joints of the nails.

FIG. 45. An erosive lesion at the site of intratesticular inoculation in Rabbit 18 (transfer from No. 3) after an incubation period of 49 days. There was only a slight induration, but numerous spirochetes were present.

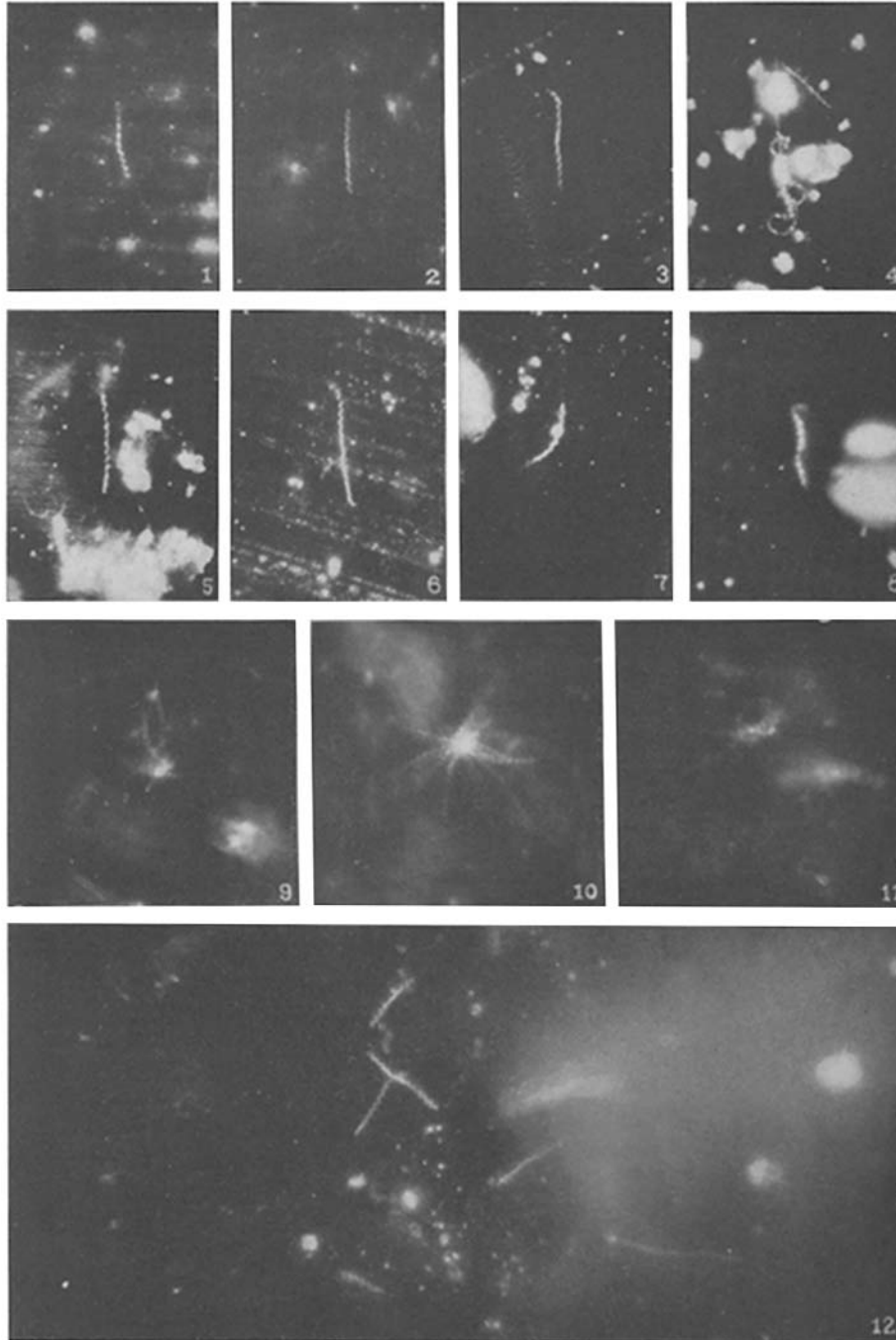
FIG. 46. The healing scar in Rabbit 24 at the site of pocket insertion of the infective material in the unsuccessful attempt to produce chancre (photograph taken 28 days after inoculation). *Treponema cuniculi* found after 73 days.

FIG. 47. A typical chancre, for comparison, on the scrotum of Rabbit 25, inoculated with the Nichols strain of *Treponema pallidum*. Note the cartilaginous, well circumscribed, umbilicated chancre (photographed 28 days after insertion).

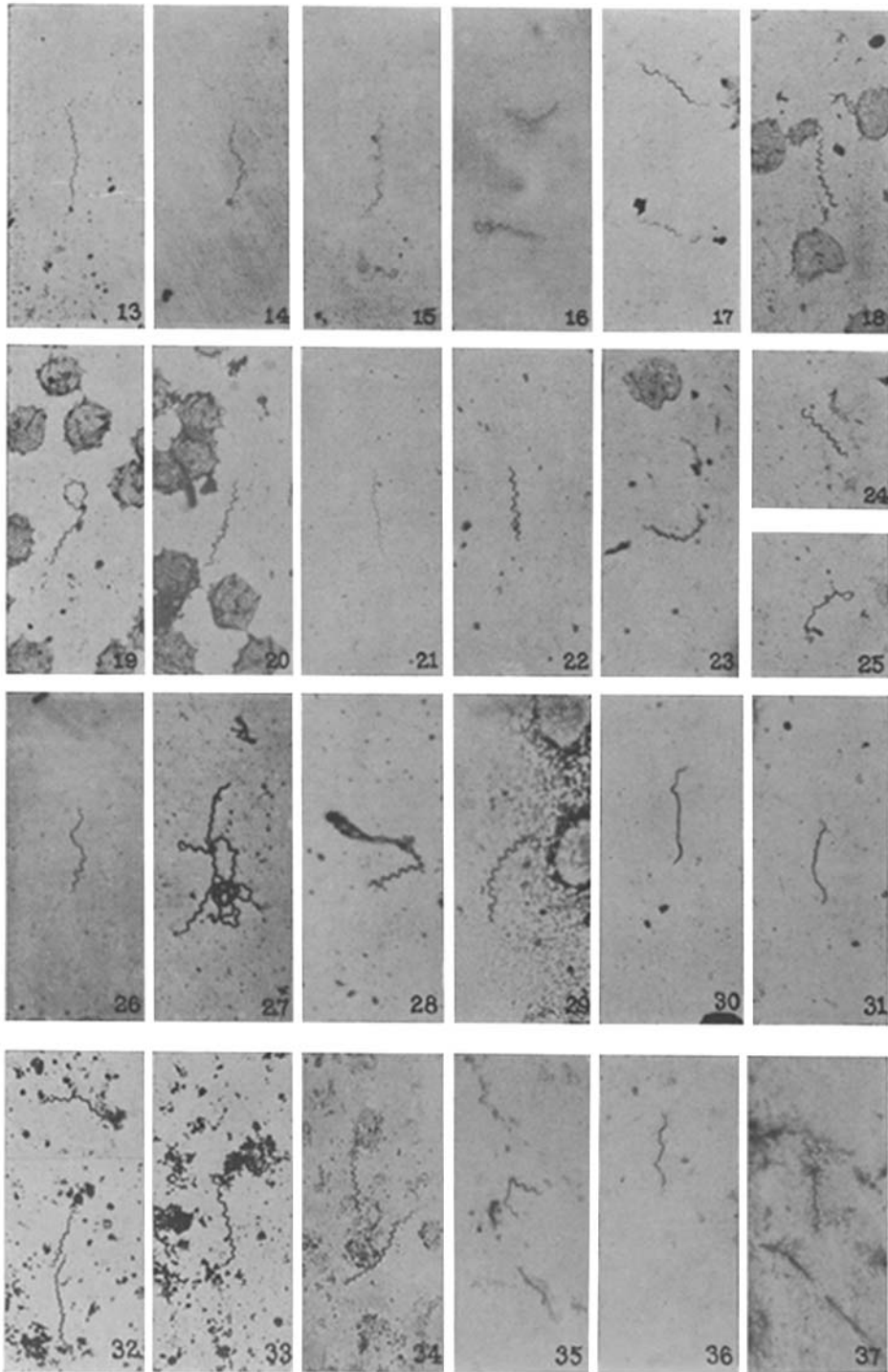
PLATE 20.

FIG. 48. Histological changes of the lesion on the prepuce of Rabbit 5. Zenker fixation, stained by hematoxylin-eosin. Showing the marked hyperkeratosis and considerable mononuclear infiltration of the interpapillary spaces. $\times 75$.

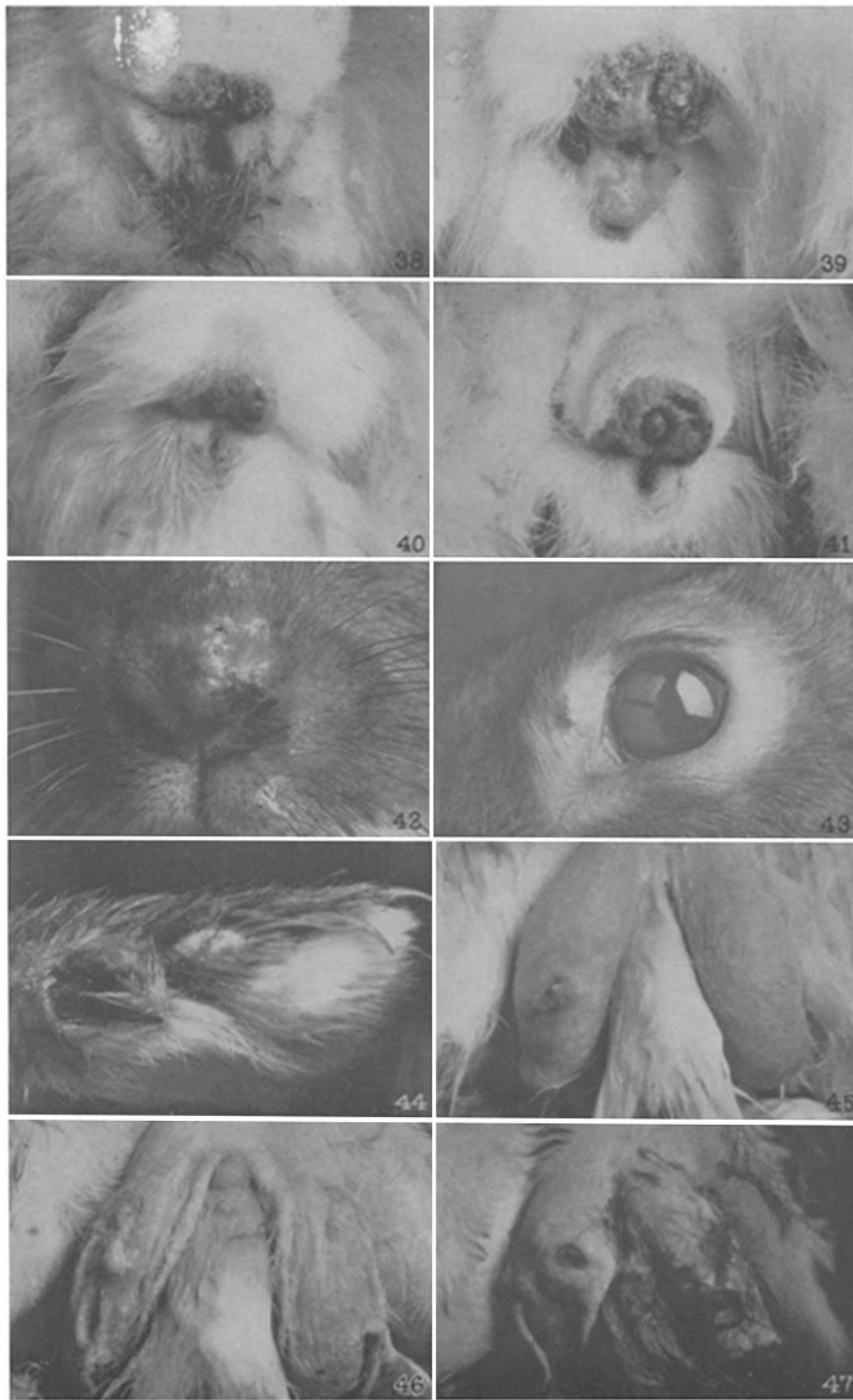
FIG. 49. Section of chancre on scrotal skin of Rabbit 25 (Nichols strain) 28 days after inoculation, showing typical interstitial and perivascular infiltration of mononuclear cells, and almost normal epidermis. The same fixation and staining as Fig. 48, shown for comparison. $\times 75$.



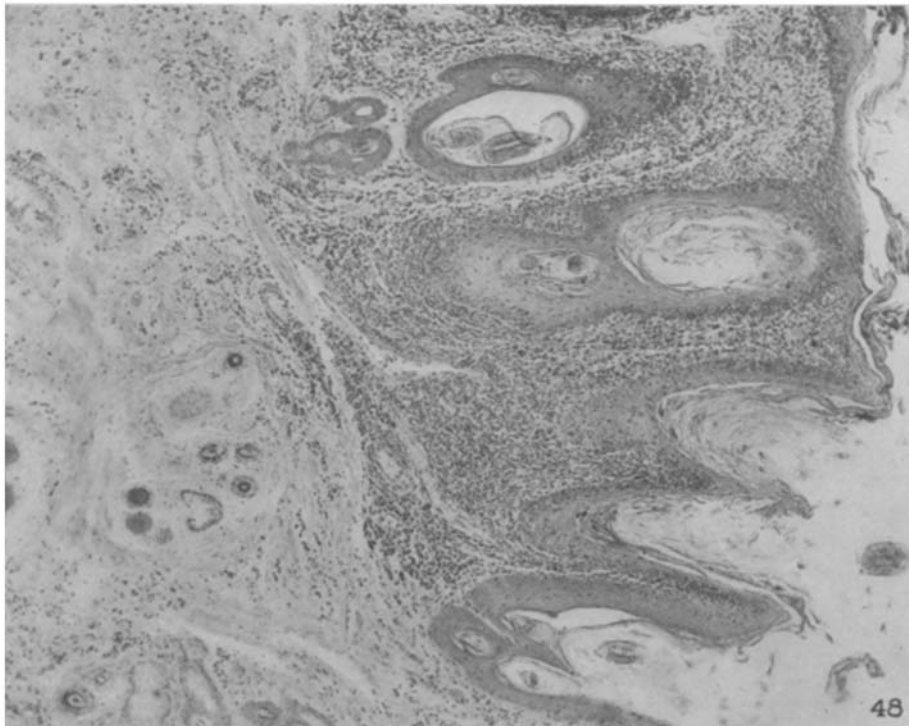
(Noguchi: Venereal spirochetosis in American rabbits.)



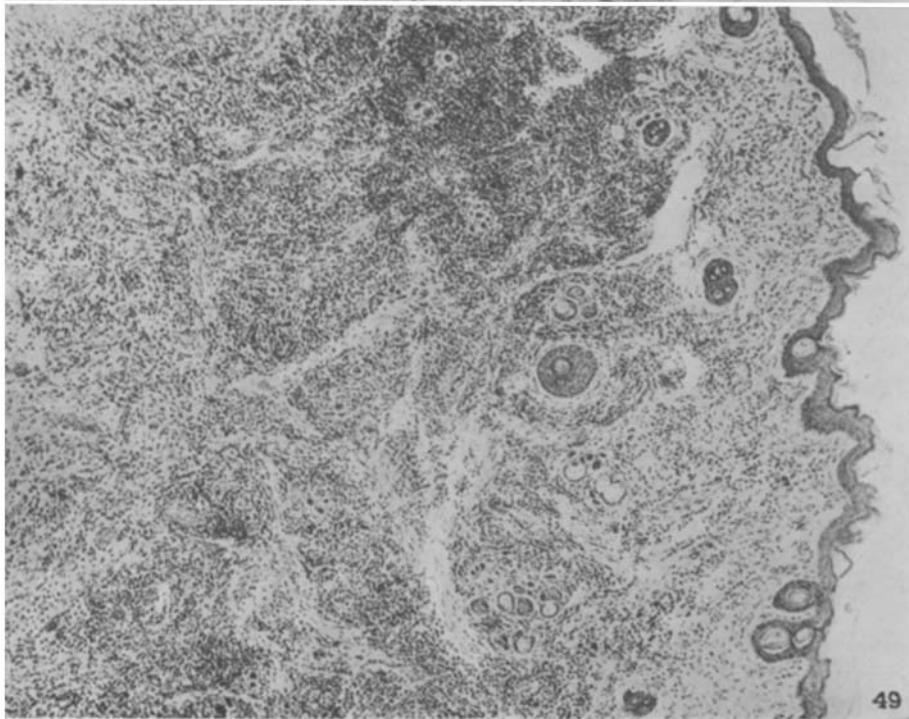
(Noguchi: Venereal spirochetosis in American rabbits.)



(Noguchi: Venereal spirochetosis in American rabbits.)



48



49

(Noguchi: Venereal spirochetosis in American rabbits.)