

## THE BILIARY FACTOR IN LIVER LESIONS.

BY PEYTON ROUS, M.D., AND LOUISE D. LARIMORE, M.D.

(From the Laboratories of The Rockefeller Institute for Medical Research.)

PLATES 17 TO 22.

(Received for publication, April 5, 1920.)

The qualification "biliary" has long been applied to a diverse group of hepatic lesions distinguished by a peculiar cirrhosis with more or less evidence of stasis in the finer bile ducts and inflammation of their walls. The actual part played by bile in the production of the connective tissue changes here seen and of chronic lesions in general of the human liver is not definitely known. According to some authors human bile is incapable of causing any permanent hepatic injury. If this be true man differs from all other well studied animals, for in them without exception aseptic bile stasis results in important local changes. There is positive evidence, too, that human bile may on occasion be the cause of important damage to the liver. Sudden total obstruction of the common duct results in the so called icteric necroses,<sup>1</sup> which may attain to the size and character of "biliary infarcts,"<sup>2</sup> large wedge-shaped areas of bile-stained necrosis such as regularly follow obstruction in rabbits and guinea pigs. Long continued stasis, when uncomplicated by infection, as is rarely the case, has been known to result in stellate cirrhosis with many new-formed bile ducts, a lesion found in the rabbit under like circumstances;<sup>3</sup> and, as in this animal, complete local stasis leads to liver atrophy.<sup>4</sup> Further examples might be cited. For the purposes of the present work we shall assume that human bile, while innocuous as compared with that of certain other species, can produce liver injury. Our

<sup>1</sup> Eppinger, H., *Beitr. path. Anat. u. allg. Path.*, 1902, xxxi, 230.

<sup>2</sup> Carnot, P., and Hervier, P., *Arch. méd. exp. et anat. path.*, 1907, xix, 76.

<sup>3</sup> Rolleston, H. D., *Diseases of the liver*, London, 2nd edition, 1912.

<sup>4</sup> Brissaud, E., and Sabourin, C., *Arch. physiol. norm. et path.*, 1884, iii, series 3, 345.

aim has been to obtain through experiment a better understanding of "biliary" lesions with special reference to the share of bile in their causation. No attempt will be made to ignore the factor of infection, which without doubt has for many instances a prime importance.

*Choice of Animals.*

The differences in the commoner laboratory animals as regards amount of the bile and its local effects have been admirably set forth by Quincke and Hoppe-Seyler.<sup>5</sup> The years since their summary have added little that is new. The rabbit and guinea pig respectively secrete nearly seven and eight times as much bile as the dog, and ten and twelve times as much as the cat. Man's rate of secretion places him near to the last mentioned animals. In them the constitutional effects of total biliary obstruction are more marked than the local, while in man death usually occurs of toxemia before cirrhotic changes are manifest.<sup>3</sup> In the guinea pig and rabbit, on the contrary, closure of the common duct results in fulminant liver destruction with cirrhosis, and the death of the animal, which follows after a few weeks at most, is traceable to this cause. The development of lesions following local duct obstruction is far more rapid than in the dog and cat, changes that may take a twelve-month in these latter<sup>6</sup> requiring only a fortnight or less in the rabbit. And in the rabbit, furthermore, secondary infection occurs but rarely, whereas in the dog it is so frequent a confusing factor as to have balked many investigators. On the basis of recent experience we have no hesitation in asserting that had dogs instead of rabbits been employed for the present work years instead of months would have been required to obtain an understanding of the simpler principles ruling biliary lesions—principles that are of evident general application, and to be derived as surely from observations upon one mammalian species as another.

<sup>5</sup> Quincke, H., and Hoppe-Seyler, G., in Nothnagel, H., *Specielle Pathologie und Therapie*, Vienna, 1899, xviii, 59.

<sup>6</sup> Harley, V., and Barratt, W., *J. Path. and Bacteriol.*, 1901, vii, 203.

*Method.*

In work already reported,<sup>7</sup> we have taken advantage of the singular fitness of rabbits for experiments upon the liver which in this species consists of two well separated masses, each with its own bile duct and blood vessels. The smaller, or lobe mass, as it may be called, forming approximately one-quarter of the whole—23.7 per cent after ablation of the caudate lobe (4 per cent)—will accommodate on emergency the entire portal stream and maintain the animal in good health when the larger mass, or main liver (72.3 per cent), is ablated. The liver of the rabbit adapts itself to new conditions far more rapidly than that of the dog or cat. Thus, for example, the gradual parenchymal atrophy and hypertrophy which follow local portal diversion require but 2 months in the rabbit for their approximate completion, whereas in the dog several times this period is required.<sup>7</sup> There exists, however, a very 'considerable drawback to the clinical study of jaundice in the rabbit in the fact that the bile pigment of the animal reacts but poorly to the ordinary color tests. Our work has not been of a sort to make this difficulty felt. A second and serious potential objection to rabbits is to be found in the intercurrent hepatic cirrhosis prevalent in certain localities. The lesion has been rare in our experience as in that of some others,<sup>8</sup> and individuals showing it at operation, the first step in every experiment, have been discarded. As a further control to the condition of the liver, the caudate lobe has regularly been ablated for section. The total bulk of the organ is thus reduced by about 4 per cent, as already stated.

The rabbits weighed from 1,400 to 2,500 gm. The general method of operation has been described in another connection.<sup>7</sup> Bile ducts to be ligated were dissected free of the surrounding structures and tied twice with fine black silk, but not cut, since this precaution against a restoration of continuity was found unnecessary. The ducts are extremely delicate. Almost all the postoperative mortality was due to rupture of them above the ligature. When a branch of the portal vein was to be tied, it was dissected out. Special care was always taken to avoid injury to the hepatic artery, for this in the rabbit usually results in more or less widespread necrosis. Recovery from operation was in general uneventful. For the better analysis of the lesions most of the animals were killed early, with chloroform or by bleeding from the heart. Bits of the liver tissue were placed upon agar and in bouillon, and additional stroke and loop inoculations were made. Infection was rare, and instances showing it were ruled from consideration. A scattered, localized coccidiosis was fairly frequent, however. It had no evident complicating effect upon the liver changes.

Zenker's fluid, formaldehyde, and alcohol were used as fixatives.

---

<sup>7</sup> Rous, P., and Larimore, L. D., *J. Exp. Med.*, 1920, xxxi, 609. All operations were performed under ether anesthesia.

<sup>8</sup> Grover, A. L., *J. Am. Med. Assn.*, 1915, lxiv, 1487.

The amount of the bile and the pressure developing within obstructed ducts are both relatively great in well fed animals.<sup>9</sup> To this circumstance and to differences in the character of the food<sup>10</sup> are probably attributable most of the considerable quantitative variations that may be observed in lesions resulting from a single procedure. Our animals were not fed for 18 hours prior to operation, but immediately thereafter they were placed upon the mixed diet of normal rabbits.

*Results of Total Obstruction.*

Nearly all attempts to obtain by experiment an understanding of biliary lesions, from Leyden's time on, have centered about the production of total stasis by ligation of the common duct; and there exist many descriptions of the ensuing changes.<sup>11</sup> Our observations have but confirmed the general findings, while yielding an interpretation of them that has proven productive.

The rabbit secretes bile so copiously—136.8 gm. per kilo of animal in 24 hours, according to Heidenhain<sup>10</sup>—that obstruction of the common duct is followed practically at once by marked distension of the passages. Within a few hours bile-stained parenchymal necroses appear, of all sizes, from those that involve but a single cell to wedge-shaped areas, the so called biliary infarcts, 0.5 cm. or more in diameter. The larger ones are stained a bright yellow-green and frequently show hemorrhages. All are obviously the result of direct extravasation of the bile, either within the lobule or at its periphery where the smallest collecting ducts have ruptured. An identical rupture at this latter point, the weakest one in the collecting system, occurs on the injection under pressure of fluid into the common duct.

Within a few days dilatation of the larger ducts becomes great, and pericholangitis develops, followed soon by a spreading, stellate cirrhosis. The changes are most marked in the region of the larger portal spaces, but there is active proliferation of the connective tissue throughout Glisson's capsule, and every lobule is soon enclosed and encroached upon peripherally. The smaller necroses are replaced by proliferation of the neighboring liver cells, but with the larger

<sup>9</sup> Bürker, K., *Arch. ges. Physiol.*, 1900-01, lxxxiii, 241.

<sup>10</sup> Heidenhain, R., in Hermann, L., *Handbuch der Physiologie*, Leipsic, 1883, v, pt. 1, 256. Hooper, C. W., and Whipple, G. H., *Am. J. Physiol.*, 1916, xl, 332.

<sup>11</sup> Richardson has an excellent brief description (Richardson, M. L., *J. Exp. Med.*, 1911, xiv, 401). For one more extensive, with a survey of the literature, see Fiessinger, N., and Roudowska, L., *Arch. méd. exp. et anat. path.*, 1914-15, xxvi, 18.

this is impossible, owing to involvement of all the lobular elements, and organization takes place by a connective tissue invasion. The surviving parenchyma becomes more and more jaundiced, and numerous intralobular bile thrombi appear. Small scattered necroses continue to develop, but no large ones form after the first days. The lobules become very irregular and diminish in size through the encroachment of connective tissue, and the latter rapidly penetrates in thin strands between the cell cords to the central vein. Within 3 weeks the liver has become a roughly hobnailed organ, with ducts everywhere greatly distended, and a cirrhosis that is at once periportal, or, more properly speaking, pericholangitic, unilobular, irregularly intralobular where necroses have been replaced, and almost regularly intralobular here and there where the connective tissue penetration is diffuse. Throughout the older cirrhotic tissue are great numbers of new-formed bile ducts. Despite the extensive parenchymal destruction, the liver remains of about the normal size. Thrombosis of portal branches not infrequently occurs, with some resultant atrophy of liver parenchyma, while elsewhere an hypertrophy may be observed when the condition of the animal permits, as is rarely the case. Always there is great emaciation, and death usually ensues within 4 or 5 weeks. Jaundice appears after the first few days of obstruction.

No human lesion resembles this one more than remotely, and attempts to utilize it in explanation of the biliary cirrhoses of man have been almost given up. Yet when its histologic components are considered separately the fact becomes plain that certain of them find their replicas in one kind of human liver cirrhosis, and certain in another. In a word, the rabbit lesion is mixed, involving injury from stasis throughout the entire length of the biliary tract. By altering the conditions it is possible, as we shall show, to localize the injury of stasis to regions corresponding to ducts of a single level or order, and thus to obtain cirrhoses of uncomplicated type which closely resemble the biliary cirrhoses of man.

#### *Results of Local Obstruction.*

The results of tying off the bile duct to the main liver mass of the rabbit, some three-fourths of the entire organ, while leaving that to the lobe mass free have been briefly described by Nasse.<sup>12</sup> We have repeated his experiments and can confirm his statements as regards the early changes, these alone having importance for the present work.

<sup>12</sup> Nasse, *Verhandl. deutsch. Ges. Chir.*, 1894, xxiii, pt. 2, 525.

The effects of the sudden stasis on the main liver, though outspoken, are far less marked than after total obstruction. Dilatation of the bile ducts and gall bladder is relatively moderate, biliary necroses are small and appear only during the first few days, and the animal remains in good condition, never becoming jaundiced. The occluded parenchyma shows no bile tinting after the 1st week. Cirrhosis makes its appearance gradually and differs from that of total stasis in its slow, orderly progress, almost complete failure to invade the lobuli, and, in the subordination of stellate growth about the larger ducts, to a diffuse interlobular proliferation (Fig. 1). But new-formed bile ducts are still a prominent feature. The parenchyma undergoes a rapid atrophy. Within a few weeks the mass is much smaller, diffusely cirrhotic, and relatively bloodless; and by the end of 4 months it is reduced to a tag from which parenchyma and new-formed bile ducts have alike disappeared.<sup>12</sup> There is only the slightest hobnailing at any time. As atrophy of the main liver progresses the lobe mass undergoes hypertrophy and eventually reaches the size of the entire normal organ.

The cirrhosis here approaches the pure unilobular in type, for penetration between the cell cords is almost wholly absent (Fig. 1). But there still exists the complication of a stellate periportal proliferation, with notable dilatation and pericholangitis of the larger ducts. Nasse attributed the atrophy to closure of the secretory channels of the liver, likening the result to that of ureteral ligation. This though, is no sufficient explanation, since under the conditions of total obstruction the liver holds its size, and there may even be some local hypertrophy despite the progressive general emaciation. With local obstruction similar attempts at repair are never seen, although the animal stays in good condition.

#### *The Factor of Portal Obstruction.*

It has seemed to us probable that the mildness of the biliary lesions, including the cirrhosis, after local obstruction, and the parenchymal atrophy as well, are due in great part to a single factor, namely, partial deflection of the portal stream from the affected region. Several facts support the view. When the duct from the main liver is tied the lobe mass becomes engorged with blood and hypertrophies just as when its portal blood supply is increased by obstructing the venous trunk to the main liver;<sup>7</sup> while a sufficient cause for obstruction is to be found in the dilatation under pressure of the main bile

channels of the liver. Betz showed in 1862<sup>13</sup> that a very moderate increase of pressure within the ducts, far less than that developing after total obstruction,<sup>14</sup> can greatly hamper the portal flow. That it does hamper it in the present case, and early, was indicated in one of our animals examined 5 days after ligation of the bile duct to the main liver. The lobe mass was already much engorged and enlarged, although as yet no connective tissue changes had occurred in the main liver that could be invoked to explain a venous obstruction there. The effect on hepatic tissue of the occlusion of portal branches has already been studied by us. There ensues an orderly atrophy with lessening of the biliary activity, and ultimately all parenchyma disappears. Precisely such an atrophy, though one more gradual, results from local biliary stasis; while a diminished biliary activity, at least as regards secretion into the ducts, is indicated by the moderate dilatation of the latter in comparison with their condition when stasis is total, and by the relative rarity of biliary necroses and the slow course of the connective tissue changes.

To obtain additional evidence we have studied the effects of obstructing simultaneously the bile duct and portal branch of a liver mass.

*Experiment 1.*—Two 1,500 gm. rabbits were operated upon under ether and the bile duct and portal trunk to the main liver twice ligated, just above the caudate lobe. The latter was not taken out. The livers appeared normal at operation, and subsequent examination of the hypertrophic lobe mass showed that cirrhosis had been absent. The animals were killed by bleeding from the heart 5 days and 21 days respectively after operation. They had been in good condition and unjaundiced.

In three other rabbits a mere ligation of the bile ducts to the lobe mass was followed by an occluding thrombosis of the accompanying portal branch. The occlusion must have developed soon after operation, for when the animals were killed the histological findings were identical with those observed in the main liver after simultaneous ligation of both duct and vein.

---

<sup>13</sup> Betz, W., *Sitzungsber. k. Akad. Wissensch. Math.-naturw. Cl., Wien.*, 1862, xvi, 238.

<sup>14</sup> Herring, P. T., and Simpson, S., *Proc. Roy. Soc. London, Series B*, 1907, lxxix, 517.

*Experimental Unilobular Cirrhosis.*

Different stages of the same lesion were found in these rabbits. There was little dilatation of the large bile ducts and only a slight, transient jaundice of the tissue in stasis. A few small parenchymal necroses were seen early, but none later. The lobules rapidly diminished in size by simple atrophy, yet cirrhosis appeared more slowly than when the bile duct alone was obstructed, and, while ringing all the lobules about with a tissue containing many little, new-formed ducts, had not the least invasive tendency. It was, in sum, a pure, evenly distributed, monolobular cirrhosis. Stellate proliferation about the larger ducts was practically absent, as might have been expected from the absence of any marked stretching of their walls. With this exception the picture so entirely resembled that found after occlusion of a bile duct only (Figs. 1 and 2) as to constitute strong evidence for the view that obstruction of the portal stream has much to do with the lesions occurring under such circumstances.

*Further Influence of the Portal Obstruction.*

The deflection of the portal stream from a liver region in which the bile ducts are dilated as the result of obstruction is probably only partial at first. Later, when cirrhosis develops, it becomes much more nearly complete, as shown by the relatively bloodless condition of the tissue at a period when much parenchyma is still present. Perhaps the arterial circulation is now compromised. Certainly a portion of the blood that comes to the liver passes on to the vena cava through capillaries in the cirrhotic tissue<sup>15</sup> and thus fails of contact with the parenchyma. Pigment secretion into the ducts completely ceases; their dilatation, while still very moderate, comes to a standstill; and the fluid in them becomes colorless and watery. Yet, as our previous work has shown, a main liver mass long deprived of all portal blood, and in advanced atrophy as result, is still capable of forming bile in quantity.<sup>7</sup> The pressure, though, against which secretion takes place into the ducts is greatly diminished, as the following experiment proves.

<sup>15</sup> Ackermann, *Virchows Arch. path. Anat.*, 1880, lxxx, 396.



*Experiment 2.*—The portal trunk to the main liver mass was ligated in two rabbits of approximately 1,800 gm. weight, and the caudate lobe ablated as usual. 17 and 23 days later, respectively, the bile duct from the mass was ligated just below the entrance of the cystic duct, and 2 and 3 days later the animals were killed and immediately examined. The main liver had atrophied in both instances to less than one-third of the normal weight, while the posterior lobe mass had undergone a corresponding hypertrophy.

In a number of other rabbits the operative procedures were the same, but a gall bladder fistula was made in addition. Certain of the instances in which bile collection was successful have already been described.<sup>7</sup> Sometimes occlusion of the fistula developed, and the animals were killed at various periods thereafter. The findings in such cases deserve consideration with those of Experiment 2 proper, since the conditions are essentially similar.

In these animals with an advanced atrophy of the main liver as result of portal ligation, not the least icteric tinting of the parenchyma or dilatation of the bile passages and gall bladder followed occlusion of the duct; and the passages contained merely a little watery, colorless fluid. Obviously a very slight increase of pressure within the ducts had been sufficient to check secretion into the normal channels. It follows that as hepatic atrophy progresses after local biliary obstruction the chance that lesions will occur through rupture of the ducts, or stasis within them, becomes negligible. Yet when the material for bile formation is provided in unusual quantity a parenchyma deprived of the portal stream can secrete bile into the ligated duct against a considerable pressure, as will now be illustrated by an experiment done with another end in view.

*Experiment 3.*—A hemolytic and hemagglutinative serum of high titer was obtained by repeatedly injecting a goat with washed, rabbit red cells. A small amount of the serum when given intravenously to rabbits was found to bring about blood destruction over a period of many hours without demonstrable liver injury, whereas large quantities caused necroses. With a properly regulated dosage there was no escape of hemoglobin by way of the urine, even when more than half of the blood of the animal was broken down in the course of only 2 days.

The portal vein and bile duct of the main liver of a 1,700 gm. rabbit were ligated just below the entrance of the cystic duct. 4 days later, when the animal had recovered from the operation and was in good condition, intravenous injections were begun of small doses of the anti-rabbit serum, followed at short intervals by the transfusion of washed, compatible, rabbit red cells suspended in a little salt solution. The amount of serum given was always well below that causing liver changes, but it effected great blood destruction, necessitating five large transfu-

sions to maintain the hemoglobin at the original level. In a period of 11 days 73 cc. of sedimented corpuscles, an amount equivalent to the cell content of 162 cc. of the blood of the animal, or nearly twice the normal total, had been destroyed as the result of but four injections of serum, or 1.7 cc. in all. The animal now possessed a hemoglobin of 86.5 per cent (Palmer) as compared with 82.6 per cent prior to the experiment. It was killed and autopsied. There was at no time any jaundice.

Three rabbits were submitted to a similar experiment for a shorter period of time, and in two others repeated injections were made subcutaneously of large amounts of hemoglobin prepared by the method of Minot and Sellards. No jaundice was observed in any animal.

In these rabbits the bile passages of the main liver and the gall bladder as well were greatly distended and with an abnormally thick, dark green bile. The liver tissue was deeply jaundiced. The changes cannot be contrasted with those in the animals of Experiment 2, since atrophy of the main liver was advanced in the latter before the bile duct was obstructed. They should be compared with the results in Experiment 1, in which a bile duct and portal branch were simultaneously obstructed. Not only was the local accumulation of bile far more copious and the distension of the ducts greater than in the few instances of this experiment, but both were much more pronounced than in any of the rabbits in which, following Nasse's example, we ligated only the duct of the main liver, leaving the portal circulation untouched. It follows that the failure of a liver region deprived of the portal stream to secrete bile against pressure cannot be laid to an essential disability of the cells. In a previous paper evidence has been brought forward that the cells are handicapped in competition with the parenchyma receiving all the portal blood.<sup>7</sup>

#### *Experimental Intralobular Cirrhosis.*

A stellate cirrhosis about the larger bile ducts is not rare in human beings as the result of obstruction, with or without infection, and has frequently been brought about experimentally in animals. We have deemed its production in rabbits, apart from other changes, as unnecessary, although logically considered this would be a further step toward separating out the components of the mixed lesion that follows occlusion of the common duct. To obtain, on the other hand,

a type of stasis, and thus presumably of cirrhosis, localized within the lobules, seemed highly desirable. *A priori*, one would expect to meet many difficulties, since it is known that a back pressure throughout the duct system which suffices to cause partial stasis in the lobules almost invariably results in a rupture of some of the bile radicles within Glisson's capsule, and always in connective tissue proliferation about the larger ducts. Our success in obtaining a predominantly intralobular stasis has been the outcome of varied attempts. The condition, and its corollary, a diffuse intralobular cirrhosis, can regularly be brought about in the lobe mass of the liver by diverting the whole portal stream to the latter and ligating the efferent duct. A like result is not produced, we find, when the larger mass of the main liver is subjected to the same procedure, an experiment already performed by Steenhuis.<sup>16</sup> The cirrhosis that then occurs is predominantly extralobular.

*Experiment 4.*—In eighteen rabbits weighing from 1,500 to 2,400 gm. the bile duct of the posterior lobe—or ducts, for there may be as many as three—was ligated, the portal trunk to the main liver tied off just above the branch to the caudate lobe, and this last ablated as usual. The animals remained in good condition and unjaundiced. They were killed after intervals of from 1 to 33 days.

The operation as described is frequently followed by complications; and the findings in many animals not included in the above number have been ruled from consideration on this account.

The course of the changes has been carefully followed. There is an initial turgor and hypertrophy of the lobe mass resembling that after ablation of the main liver,<sup>17</sup> or simple ligation of the portal branch of the latter,<sup>7</sup> and due of course to the same marked, local increase in the portal stream. Superimposed are destructive changes referable to the bile stasis. The stasis, though brought about by a ligature on the principal duct of the lobe, causes remarkably little dilatation of the latter and still less of its large branches within Glisson's capsule. These are never abnormally prominent on the cut surface of the liver, though microscopically a slight distension and thickening of their walls may be observed after a time, with occasionally some pericholangitis. In the course of several weeks the main duct usually attains a diameter of about 3 mm., that is, becomes twice the normal size, and contains stasis bile, a watery fluid with a few green

---

<sup>16</sup> Steenhuis, T. S., *Experimenteel en Kritisch Onderzoek over de Gevolgen van Poortaderafsluitung*, Thesis, Gröningen, 1911.

<sup>17</sup> Ponfick, E., *Virchows Arch. path. Anat.*, 1889, cxviii, 209; 1890, cxix, 193; 1895, cxxxviii, suppl., 81.

solid particles. The brunt of the obstruction falls on the smallest bile radicles in Glisson's capsule, and still more on the canaliculi within the lobules themselves, as shown by the bile thrombi here found and the numerous, minute parenchymal necroses. Such necroses appear within a few hours after the ligation and new ones develop day by day. Usually they cannot be seen with the naked eye, involving, as they most often do, one to three or four cells scattered throughout the lobule from periphery to center. The dead cells stand forth prominently in the liver cords, staining a bright pink with eosin, and lacking nuclei (Fig. 3). By the 3rd day they are numerous, especially in the outer and mid-zone of the lobule, and occasionally a few larger necroses involving ten or fifteen cells may now be present. Some of the latter are undoubtedly the *Netz-Nekroses* which Steenhuis<sup>16</sup> saw in liver tissue hypertrophic as result of an increased portal flow, but others have the character of frank biliary necroses. Very exceptionally they involve considerable lobular segments and may then attract the unaided eye. In animals showing them the smaller, disseminated necroses are especially numerous. It is the latter that characterize the lesion and continue steadily to be formed. Being purely parenchymal they are rapidly replaced by proliferation of the lobular cords without connective tissue participation, and their number is never sufficient at any one time to render them confluent. They appear to have no relation to the small, scattered, intralobular bile thrombi that, during the first few days, and then only, are numerous enough to attract attention.

The severity of the lesion varies largely with the individual. By the 3rd day in some cases, or the 6th or 7th in others, a new element makes its appearance; namely, a proliferation in the finer ramifications of Glisson's capsule. Fibroblasts begin to penetrate within the enlarging lobules (Fig. 4), and by the 12th day as a rule many thin strands of them can be found, so far toward the central vein and so isolated in cross-section that were the absence of connective tissue within the normal parenchyma not well attested<sup>18</sup> one would conclude that they had developed *in situ*. New-formed bile ducts have now made their appearance in the interlobular connective tissue which is definitely increased in amount.

The lobe mass at this time is highly interesting in the gross. It is enlarged, sometimes to double its normal size, with rounded contours and blunt edges. The bulging hypertrophic lobules render the surface slightly and regularly uneven. The tissue is firm and somewhat inelastic, and the knife meets a smooth, non-crepitant resistance. The color is gray-pink, in contrast to the purple of the main liver. When the vessels are severed nearly all the blood is forced out by the turgid tissue, and the general tint is then a uniform, pale buff, or putty color. On the surface laid open the lobules can with difficulty be made out, slightly raised, in a matrix of gray, translucent, connective tissue which appears to penetrate and overgrow them. Sometimes their position can be made out only through the situation of the gaping central veins. There is now no definite jaundice of the tissue, though its yellowish tint is suggestive. Earlier, during the

---

<sup>18</sup> Mall, F. P., *Am. J. Anat.*, 1906, v, 227.

first few days after the ligation, the enlarged lobe may be a greenish red-purple, though jaundice of the animal never occurs.

By the 21st day the lobe mass, still in process of hypertrophy, contains nearly as much connective tissue as parenchyma. Almost everywhere fibroblasts have penetrated to the central veins of the lobules, though so regularly that the original pattern of the liver is still fairly maintained. The cell cords, though, are distorted and much fewer. The necrosis of individual cells and small cell groups is still going on, as is also proliferation of the surviving parenchymal elements which individually may be much above normal size. The interlobular connective tissue is greatly increased, both relatively and actually, and everywhere throughout it are new-formed bile ducts. About some of the small hepatic veins is a collar of young connective tissue containing in its midst irregular strands of small, compressed looking cells, superficially suggestive of new-formed bile ducts but in situation widely separate from the latter and with tinctorial differences that identify them as parenchymal.

At this time the lobe mass is of a pale flesh color and appears almost bloodless compared with the main liver (Fig. 9). In truth it is so, owing to interference with the portal stream by the cirrhotic tissue, which usually begins before the 12th day and has now become marked. Venous collaterals open, sometimes as a *caput Medusæ*, when the omentum is attached by adhesions to the old wound, more usually as small, direct anastomoses between the portal branches and vena cava, and oftenest as dilated Charpy's veins along the gastrohepatic omentum to the main liver. But all of the new channels fail as a rule to avert a serious chronic passive congestion. As result the spleen is changed into a tense cylinder (Fig. 9) and may weigh more than 4 gm., nearly six times the average for normal rabbits of similar size. Occasionally ascites occurs. On cutting into the lobe mass its large, portal channels are found to end bluntly in small veins.

The surface of the lobe is still finely rugose, and its substance is now extremely resistant to the knife, though non-crepitant. When laid open the glistening, bloodless, pinkish gray tissue shows no distinct pattern of lobules, but these can usually be made out when viewed obliquely, since they are slightly raised above the general surface. Some appear larger than normal whereas others blend with the connective tissue. The main liver mass fails to undergo the atrophy which in the lack of a functional need would be its fate.<sup>7</sup>

By the 30th day cirrhosis has progressed much further and so has the development of collaterals which shunt the portal blood around the lobe mass. The adequacy of the new channels is now shown by the disappearance of all signs of passive congestion. The lobe mass has in consequence come to lie outside of the venous stream, being reduced to much the same circulatory condition as if its portal branch had recently been tied. Hypertrophy ceases, and atrophy takes its place. But though the lobe mass is still much above normal size little parenchyma is left to undergo retrogression. The mass consists almost entirely of connective tissue with an abundance of new-formed bile ducts and some round cells. Here

and there are to be found small islands of liver cords, and separated cords and cells (Fig. 5), some of them dying, though whether as a result of the bile stasis or of the cirrhosis we have not sought to discover. The liver destruction has far surpassed that compatible with life were the whole organ affected. Beyond the 33rd day the changes have not been traced.

Altogether the type of cirrhosis is as purely intralobular as is compatible with the fact that the lobules normally contain no connective tissue,<sup>18</sup> so that its appearance and proliferation within them must of necessity take place by penetration from without.

#### *Influence of an Increased Portal Stream.*

The secretory activities of a lobe mass receiving the entire portal stream but with bile duct ligated, as in the preceding experiment, become strikingly evident when the duct from the main liver is also tied with result in total obstruction. There is now no relief for the lobe mass such as might be afforded through the efforts of a parenchyma with unobstructed bile outlet.

*Experiment 5.*—In ten rabbits of 1,500 to 2,200 gm. an operation similar to that of Experiment 4 was successfully performed and in addition the bile duct from the main liver mass was ligated. In eight cases the gall bladder was removed in order to render the conditions in the main liver more strictly comparable with those in the lobe mass. The animals died, or were killed, after periods of 1 to 12 days. Cultures taken from such as died showed that the liver lesions were not referable to infection; and as further proof the histological findings agreed in all ways with those of animals killed while still in good condition.

The animals of this experiment were more seriously affected than if total biliary stasis had been produced in the ordinary way by obstruction of the common duct. A sufficient explanation is to be found in the radical circulatory derangement.

Only two animals survived for as long as 12 days. Jaundice always developed within 48 hours, and rapid emaciation was the rule; yet despite the poor general condition the lobe mass of the liver underwent some hypertrophy. Its turgid tissue became brightly and evenly bile-stained—green, or ocher-colored. The surface remained smooth, and at no time were biliary necroses perceptible in the gross (Fig. 10). The lobules were definitely enlarged and appeared regular, save that near the central vein there was some opacity with a brilliant bile tinting. The impression here gained was not that of a diffuse necrosis but of intense im-

pregnation of living tissue with bile pigment. This was the actual state of affairs, as sections showed. Toward the center of the lobules pigment existed in great quantity as small bile thrombi (Eppinger), as large, rounded, brownish black masses (Fig. 6), intracellular particles, and as a diffuse stain for groups of dead parenchymal cells. No such marked condition has to our knowledge been encountered heretofore, though for that matter the factors in its production can scarcely be expected to come together naturally.

The earliest histological changes were like those observed in the companion Experiment 4, in which the duct of the main liver was left open. There was the same scattered necrosis of individual cells throughout the lobule, but in much more pronounced form (Fig. 7), and dilatation of the ducts was greater. Small concretion-like pigment "thrombi" appeared early here and there between the parenchymal cells, and after but a few days the pigmentary accretion was, as already described, enormous (Fig. 6). The number of dead cells grew rapidly, and close to the center of the lobules larger biliary necroses occurred, some deeply impregnated with bile, but none of such size as to attract the unaided eye. These features acted to modify the rapidly developing cirrhosis, which in the animals surviving longest was intralobular both by diffuse invasion and by the replacement of necroses. Pericholangitis of the larger ducts was absent. At the 12th day active division of the surviving parenchymal cells was still going on; some elements were of greatly increased size, and nuclear irregularities were frequent.

The main liver showed only the lesions that ordinarily follow obstruction of the common duct, combined with the slight atrophy inevitable to deprivation of the portal stream. The local accumulation of pigment was slight, as compared with that in the posterior lobe mass, yet large biliary infarcts were numerous (Fig. 8).

The extraordinary impregnation with pigment of the posterior lobe mass (Figs. 6 and 7) contrasts strikingly with the slight jaundice of the main liver (Figs. 8 and 10). Since biliary activity is dependent, in large part at least, upon portal flow, and this is greatly different in the two liver portions, such a contrast need not occasion surprise. The absence of gross necroses, though, in the posterior lobe mass is difficult to reconcile with the pronounced biliary leakage there occurring save on the assumption that the increased portal flow provided a circulation to cells that otherwise would have been deprived of it by the extravasations.

#### *The Factor of Safety in Bile Elimination.*

The tissue of the lobe mass in Experiment 4 was jaundiced only during the first few days after operation. Experiment 5 clearly shows that bile pigment must have been prevented from accumulating here,

as well as in the organism generally, through the activities of the main liver. When there exists only an uncomplicated biliary obstruction of the main liver, the posterior lobe mass functions in the same way to prevent a general jaundice, as has already been noted. It is remarkable that the literature contains no direct recognition of the fact that a small portion of the liver may serve for the whole as far as regards the elimination of bile pigment. On the contrary, one finds everywhere the statement that the severity of jaundice is directly proportional to the amount of liver tissue in stasis; and small, local lesions have been invoked to explain its clinical occurrence. The subject merits a separate paper and will be considered here only in so far as it affects our theme. But this it does to a considerable degree.

The factor of safety in bile elimination is strikingly illustrated by some recent experiments for another purpose performed by one of us and Dr. Philip D. McMaster. The bile duct from the main liver was tied, and so too was the portal branch to the lobe mass from which the caudate lobe was ablated as usual. Owing to the increased portal stream to the main liver the tissue of the latter must be supposed to have formed bile in unusual quantity, and this found no outlet by the normal route. Yet the eight rabbits of the series remained in excellent condition and unjaundiced, although the bile could be eliminated only through the lobe mass, less than a quarter of the total substance of the liver, and supplied with blood only through the hepatic artery, which, judging from observations on dogs,<sup>19</sup> provided only about 40 per cent of the normal blood supply.

#### *Local Effects of Increased Bile Secretion.*

It has repeatedly been suggested on the basis of clinical evidence that increased secretion, or the secretion of an abnormally thick bile, may lead to stasis within the ducts and thus injure the liver eventually. Hanot's cirrhosis was at one time attributed to such cause. But certainly small portions of the liver of the rabbit can rid the body of large amounts of the animal's highly irritant bile without suffering injury. This was true in all of the instances of compensatory secre-

<sup>19</sup> Macleod, J. J. R., and Pearce, R. G., *Am. J. Physiol.*, 1914, xxxv, 87.



tion described in the present paper. Even when the bile is thickened as the result of hemolysis and the whole brunt of its elimination is abruptly thrown upon the lobe mass of the liver, the latter suffers no damage visible histologically. Experiment 3 was originally devised to test this point.

#### DISCUSSION.

##### *Physiological Pathology of the Lesions.*

Rabbit bile that has escaped from the ducts is highly injurious to the tissues, causing necrosis even of the liver parenchyma.<sup>20</sup> In this fact and in the differing paths by which the fluid may leave the collecting tract under various conditions of obstruction are to be found primary reasons for the diverse types of biliary cirrhosis which we have produced experimentally.

The cirrhosis which follows ligation of the common duct is, as has already been pointed out, a mixed lesion. So considerable is bile secretion despite the stasis, that no part of the collecting tract from the intralobular canaliculi to the main duct, inclusive, escapes the effects of the irritant fluid. Pressure changes also occur, and the local condition is probably aggravated by the resecretion of biliary constituents from the heavily charged blood,<sup>21</sup> which would greatly favor accumulation within the hepatic tissue. Though most of the secretion must continue to find its way back into the blood and lymph, the process cannot but be faulty when the body fluids are already heavily laden.

The progressive atrophy and orderly cirrhosis that result from obstruction of a single large bile duct are traceable to the interaction of two opposing sets of factors, one set vicious, the other tending to relieve the conditions. The initial bile stasis leads to rupture of some of the finer ducts with parenchymal necrosis, and its continuance to an interlobular and pericholangitic connective tissue growth. Probably this cirrhosis interferes eventually with the general blood

<sup>20</sup> Bunting, C. H., and Brown, W. H., *J. Exp. Med.*, 1911, xiv, 445.

<sup>21</sup> Bile constituents injected into the circulation are rapidly taken out by the normal liver—*vide* Stadelmann, E., *Der Icterus, und seine verschiedenen Formen* Stuttgart, 1891.

supply. There is no doubt that the portal flow is partially diverted from the beginning through the encroachment of distended bile ducts on the stream bed, and hence there ensues a gradual atrophy of the parenchyma such as follows any local portal deprivation.<sup>7</sup> But while destruction is thus being effected through a combination of several influences others act to limit the injury. The liver portion with duct still open keeps the organism more or less free from bile and thus tends to prevent resecretion into the region of stasis; secretion is still further reduced by the diverted portal flow;<sup>7</sup> and the direct effects of such stasis as nevertheless ensues are lessened by the passage of biliary constituents from the obstructed tissue into a blood and lymph relatively free from them. As parenchymal atrophy advances the pressure under which bile is secreted into the ducts decreases greatly (Experiment 2), and in consequence their rupture, with extravasation, no longer occurs. Furthermore, with the passing of time the functional responsibilities of the tissue in stasis decrease, owing to hypertrophy of the unobstructed liver mass. And so through several means the local changes are rendered mild and orderly. Similar lesions from similar causes, but with less of cirrhosis and a more rapid atrophy, as would naturally follow from the circumstances of the case, are seen when a bile duct and its corresponding portal branch are occluded at the same time (Experiment 1).

The predominantly monolobular cirrhosis which follows the occlusion of a single duct, and the purely monolobular lesion that develops when the corresponding portal branch is also tied, are referable not to rupture of the ducts, which is negligible, but to continued passage through their walls of the irritant bile. When a colored solution is introduced into the bile passages under a pressure that fails to rupture them it escapes with ease through the walls of the finest radicles in Glisson's capsule.<sup>18</sup> And precisely here, as indicated by the connective tissue lesion, does the bile pass into the tissues under the circumstances we are now discussing. This path of egress would seem sufficient to relieve the stasis when secretion has been cut down by the ligation of the portal branch to the affected region, for under such circumstances lesions are not observed elsewhere in the liver. When the duct alone has been ligated secretion and stasis are both greater, and in addition to the monolobular cirrhosis a stellate proliferation is then found about the large, distended ducts.

No clear reason is evident for the intralobular situation of the stasis that results from obstructing a single bile duct and greatly increasing the local portal flow. The changes that ensue, though, are easily understood. An increased portal flow of itself fails to induce connective tissue changes.<sup>17</sup> They may be attributed in the present instance to the numerous bile leaks within the lobules, leaks which also cause a profusion of punctate necroses. The lymph from the affected tissue comes away more or less laden with bile. It passes, not direct from the lobules into the formed lymphatics of Glisson's capsule, but first through unlined spaces between the connective tissue cells.<sup>18</sup> Here its biliary component has abundant opportunity to cause irritation, and here consequently at the edge of the lobules connective tissue proliferation occurs, and fibroblasts penetrate rapidly between the liver cords, following up, so to speak, the path of the irritant fluid. A diffusely intralobular cirrhosis is the result. The absence of large biliary infarcts, despite the great secretory activity of the tissue (Experiment 5), may be due in part to the support given the walls of the bile radicles by the increased portal pressure, which would also act to maintain the blood current despite local extravasations so that the latter affect relatively few cells. The observation has been made (Experiment 5) that when there is an increased portal flow in one part of the liver, an absence of such flow in the remainder, and biliary obstruction in both, gross biliary necroses fail to occur in the first mentioned liver portion, although the jaundice there is extreme, whereas in the second portion, which is unjaundiced, and must be relatively inactive, large infarct-like necroses appear (Fig. 8). To judge from this there would appear to be much in the current belief that biliary necroses, though caused in some part by the direct injury of cells by extravasated bile, owe their size when large to interruption of the blood current.

#### *Interpretation of Human Lesions.*

Many facts warrant the application of the principles here set forth to the frank biliary lesions of human beings. The essential likeness of the changes in man and the rabbit has been briefly indicated in an earlier part of this paper. As Quincke and Hoppe-Seyler put the

matter, summing up their more extensive comparison: "From all this it would seem that the findings in guinea pigs and rabbits are analogous in many ways to those in human beings."<sup>6</sup> But it is in essentials only that the findings are analogous. The relatively innocuous character of human bile, the slow rate at which it is secreted, the greater frequency of infection in areas of stasis, all act to vary the picture. Furthermore, the liver parenchyma may, like that of the dog, respond rather slowly to changed circulatory conditions<sup>7</sup> such as bile stasis induces. Certainly the intralobular bile canaliculi are, like those of the dog and cat, relatively inaccessible to pressure exerted through the large ducts,<sup>18</sup> so that they are only slightly implicated by stasis in these latter.

The forms of cirrhosis associated with Hanot's name cannot on present evidence be classed as of frank biliary origin. Nevertheless, our observations bring something of clarity into a consideration of them. Whether there exists an entity of the sort described by Hanot has been much debated, and there is great discordance in its definition by recognized authorities. No one disputes, on the other hand, the occurrence in man of a peculiar, progressive, hepatic cirrhosis, accompanied by more or less jaundice, and resulting usually in an enlarged liver in which are found inflammatory lesions of the smaller bile ducts with signs of stasis in them. It is our belief that the diversity of the liver changes is referable to differences in the duct levels at which the injurious agent is active, differences which in the rabbit lead, as we have shown, to cirrhoses of strikingly individual character. In rabbits, and with bile as the irritant, a localization to the intralobular bile canaliculi leads to a diffuse intralobular cirrhosis, whereas when the smallest bile radicles in Glisson's capsule are affected there results a pure monolobular cirrhosis, and implication of the large bile channels leads to a stellate proliferation about them. Parallel instances, pure and mixed, of all except the last mentioned lesion, are to be found within the group of the hypertrophic biliary cirrhoses of man. The rapidly progressive type of the disease, frequent in Indian children, is almost entirely of intralobular character, as Gibbons' excellent description shows.<sup>22</sup> There

<sup>22</sup> Gibbons, J. B., *Sc. Mem. Med. Off. India*, 1891, vi, 51.

is here a marked degeneration of the liver cells. According to Kaufmann,<sup>23</sup> with whom relatively few agree, intralobular growth is a distinctive character of Hanot's disease. In Lereboullet's monograph<sup>24</sup> most of the instances are monolobular, with occasionally an intralobular and sometimes a perilobular involvement.

The hypertrophy of the surviving parenchyma in Hanot's cirrhosis is not more difficult to understand than that usual to atrophic cirrhosis and here regenerative in character.<sup>25</sup> In explanation of the continued connective tissue growth which renders the liver large, one need only invoke the constant stimulus to proliferation that is undoubtedly present, as the angiocholitic lesions show. By contrast, injury is intermittent in the atrophic cirrhosis of Laennec, and at death, when a contracted scarring is found, often no signs of recent damage can be made out. The round cell aggregations present in hypertrophic biliary cirrhosis need no other cause than the chronicity of the inflammation. And the not infrequent chronic passive congestion occurring at a late stage with or without a marked diminution of the size of the liver, is referable to secondary connective tissue shrinkage and to the localization of the cirrhosis in the individual case. In our rabbits with hypertrophic biliary cirrhosis chronic passive congestion regularly developed as a late feature.

The ability of the least harmful bile of which the effects have been carefully followed, that of the cat, to elicit eventually a liver cirrhosis in the absence of infection<sup>6</sup> might well lead one to stress this factor as a cause of connective tissue changes in the human liver. The occurrence of intense local bile-staining without such lesions, a phenomenon not infrequent at autopsy in liver diseases, carries no weight in this connection, since the chronicity of the local stasis is here unattested. But Hanot's cirrhosis has certainly a varied etiology. The infantile form so frequent in India probably has its own specific cause. A number of well known microorganisms have been isolated from the liver in occidental forms of the disease, though the readiness with which infection supervenes on bile stagnation leads one to doubt

<sup>23</sup> Kaufmann, E., *Lehrbuch der speziellen pathologischen Anatomie*, Berlin, 1907.

<sup>24</sup> Lereboullet, P., *Les cirrhoses biliaires*, Thèse de Paris, 1902.

<sup>25</sup> Kretz, R., *Wien. klin. Woch.*, 1900, xiii, 271.

that their rôle is primary. Hanot's early hypothesis of a primary bile stagnation as the result of a "biliary diathesis" seems to us worthy of reconsideration in certain cases. The essential chronicity of the changes accords well with the relatively innocuous character of human bile; while the enlargement of the spleen which is sometimes great, and the occasional familial character of the malady are facts suggesting an inherent peculiarity of the patient closely akin to that of congenital familial jaundice, as several authors have not failed to point out. Yet it should be remarked in this connection that cirrhosis is not a feature of the latter disease, though for years the liver secretes a tenacious, heavily pigmented bile. Furthermore, we have been unable to cause liver injury in the rabbit by many times increasing the bile output of pigment from small portions of parenchyma (Experiment 3).

The possibility should be borne in mind that local bile stasis may act to complicate any chronic liver derangement in which bile passages, small or large, are compromised. That obstruction to the smaller channels may be responsible for certain of the supposedly "unobstructive" jaundices has been proved by Eppinger. Yet the absence of clinical jaundice is, as we have found, compatible with a condition of total obstruction in more than three-fourths of the liver of the rabbit. Should the same hold true for the human liver the existence of a "*cirrhosis biliaire anicterique*" such as has been described by French authors will not be difficult to understand.

#### SUMMARY.

There are excellent reasons for employing the rabbit in an experimental analysis of the biliary factor in liver lesions; and it is possible to obtain in this animal results uncomplicated by infection or by intercurrent cirrhosis.

Ligation of the common duct of the rabbit results in a mixed lesion from injury throughout the entire length of the bile channels. By obstructing single ducts and altering the portal stream we have produced cirrhoses of pure monolobular and diffusely intralobular types. The character of the connective tissue changes is determined by the path of escape of bile from the collecting system, which in turn is

largely conditional upon the secretory activity, while this again is dependent upon blood flow. The portal flow is largely diverted from regions of local stasis through encroachment on the stream bed by the dilated ducts.

There is a large margin of safety in bile elimination by the normal hepatic tissue. Less than a quarter of the liver of the rabbit, and this deprived of its entire portal stream, will suffice to keep the organism free from clinical jaundice and healthy when the remainder of the liver, which receives all of the portal blood, has its ducts ligated. The vicarious elimination thus illustrated is of great importance for regions of local stasis by keeping the blood relatively free from bile, thus preventing resecretion into such regions and facilitating exchange from them into the body fluids.

Our experimental monolobular and intralobular cirrhoses are the result of the limitation of biliary lesions to special levels of the duct system. Their resemblance to the different forms of "biliary" cirrhosis associated with Hanot's name is close, and the diverse liver lesions of Hanot's disease are readily explained on the assumption that the stasis, with or without infection, which is indubitably here present, has its situation at different levels in different cases. There are reasons for the view that bile stasis *per se* may sometimes be a prime cause of the malady. Certainly such stasis must be thought of as acting to complicate many chronic liver lesions.

In a later paper experiments on the dog will be described essentially similar in result to those on the rabbit as here set forth.

#### EXPLANATION OF PLATES.

##### PLATE 17.

FIGS. 1 and 2. The lesions after 14 days occlusion of the bile duct from the main liver mass (Fig. 1), and after 22 days of such occlusion plus ligation of the corresponding portal trunk (Fig. 2). There is an identical interlobular cirrhosis in both cases with many new-formed bile ducts, simple atrophy of the parenchyma, and a dwindling in size of the lobules. The scattered dark spots are pigmented Kupffer cells such as are found after any local portal obstruction. Hematoxylin and eosin.

##### PLATE 18.

FIG. 3. Condition of the lobe mass of the liver 2 days after the operation to produce hypertrophic cirrhosis. Necrotic parenchymal cells can be seen here and there. Two are indicated by arrows. The lacunæ near the center of the

lobule on the left indicate where bile thrombi have been dissolved out by the fixative. Eosin and methylene blue.

FIG. 4. Experimental hypertrophic cirrhosis after 13 days. In the center of the field is an unusually well preserved lobule with fibroblasts penetrating it from all sides. Elsewhere only irregular cell cords can be distinguished amid the cirrhotic tissue. Hematoxylin and Van Gieson's stain.

PLATE 19.

FIG. 5. Experimental hypertrophic cirrhosis after 30 days. The parenchyma is almost entirely replaced by connective tissue containing many new-formed bile ducts. The position of the lobules can no longer be made out save from the central veins. One of the latter is here shown with some degenerating liver cords near it, while elsewhere a few parenchymal cells can be seen. Eosin and methylene blue.

FIG. 6. Pigment accumulation in the lobe mass 7 days after diversion to it of the entire portal stream and ligation of the common duct. Masses of bilirubin are to be seen, especially near the center of the lobules. There is a beginning cirrhosis. Fresh specimen stained with methylene blue.

PLATE 20.

FIGS. 7 and 8. The lesions 7 days after diversion of the whole portal stream to the lobe mass and ligation of the common duct. In Fig. 7, of the lobe mass, one finds a punctate parenchymal necrosis which is far more pronounced than when biliary obstruction is local (Fig. 3), while the number of bile thrombi, as indicated by lacunæ, is much greater. In the main liver (Fig. 8) necrosis takes a gross form although the other signs of stasis are slight. Both specimens have the same magnification. The cells of the lobe mass are relatively very large. Eosin and methylene blue.

PLATE 21.

FIG. 9. Experimental hypertrophic cirrhosis after 21 days. The fleshy, pink mass with slightly roughened surface next to the pylorus is the cirrhotic lobe mass, well nigh bloodless owing to the obstruction of its vessels. The spleen, in chronic passive congestion, is a much enlarged, tense cylinder, despite the collateral vein running from it to the main liver. There was marked ascites in this instance.

PLATE 22.

FIG. 10. Results of 7 days diversion of the portal stream to the lobe mass of the liver with ligation of the common duct. The lobe mass is enlarged and deeply jaundiced, but without evident necroses, whereas the main liver, somewhat smaller than normal and almost unjaundiced, shows large biliary infarcts.



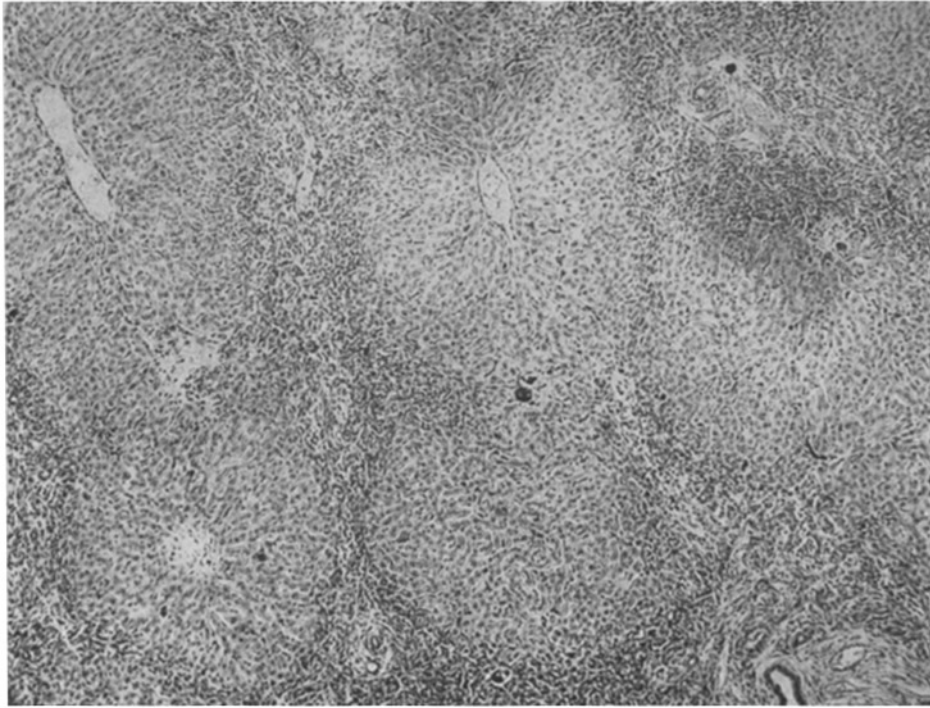


FIG. 1.

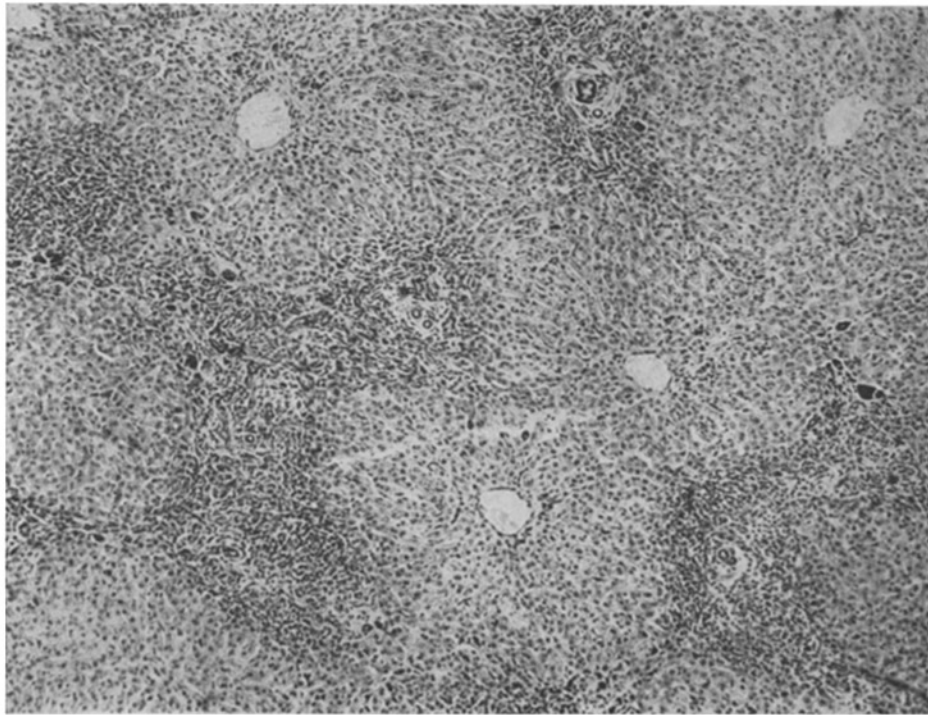


FIG. 2.

(Rous and Larimore: The biliary factor in liver lesions.)

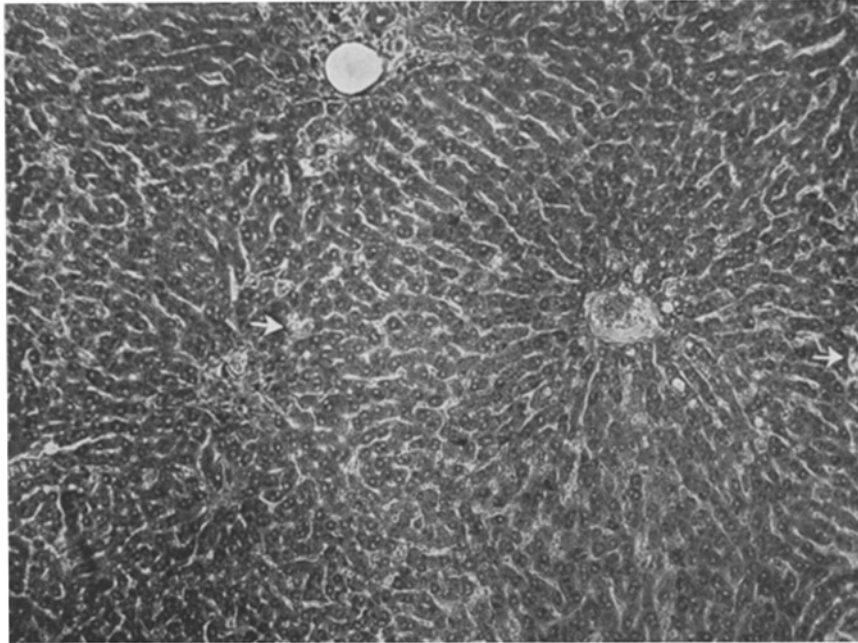


FIG. 3.




FIG. 4.

(Rous and Larimore: The biliary factor in liver lesions.)

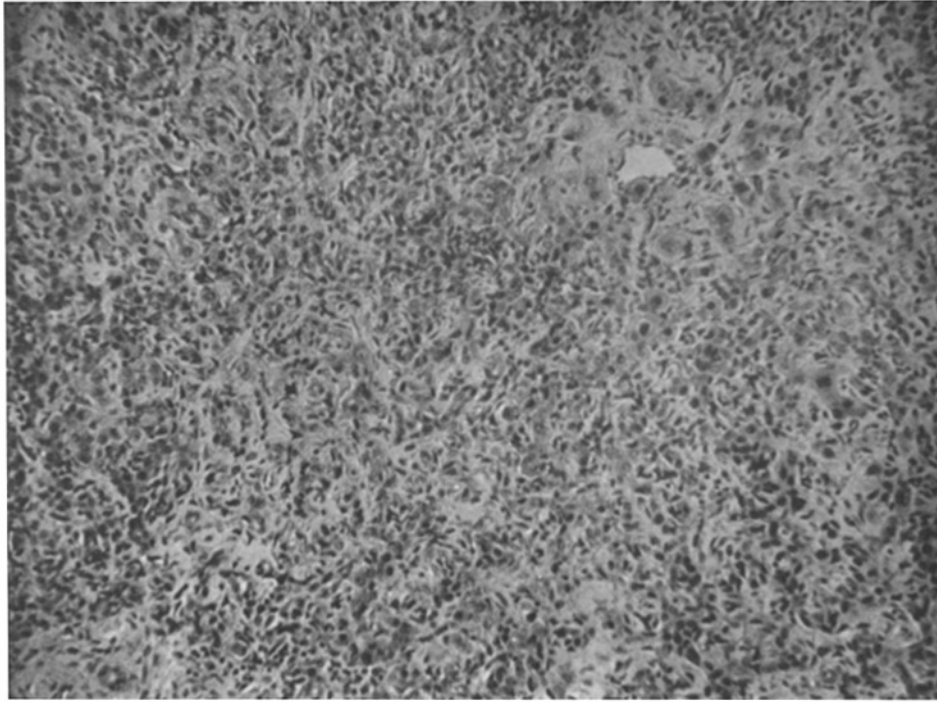


FIG. 5.

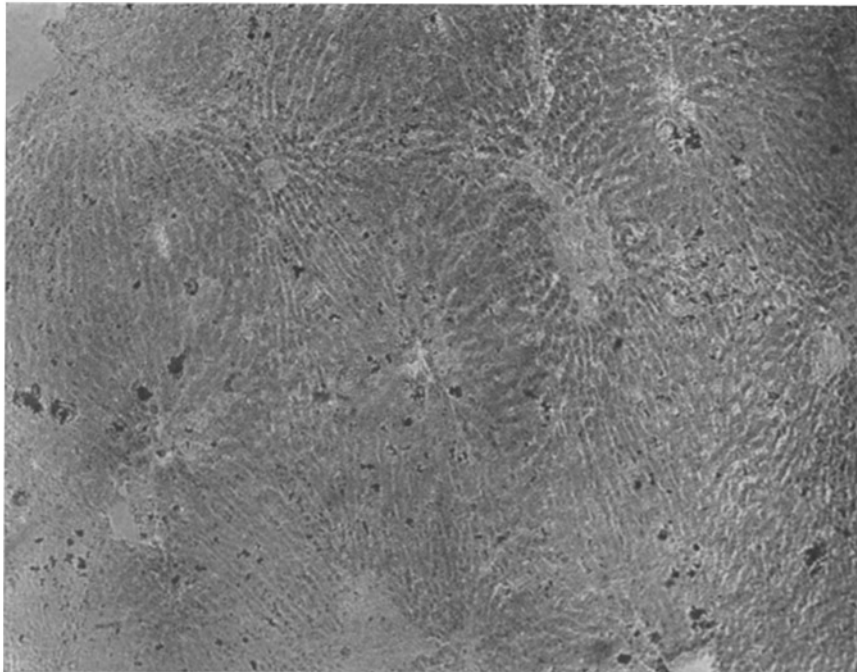


FIG. 6.

(Rous and Larimore: The biliary factor in liver lesions.)

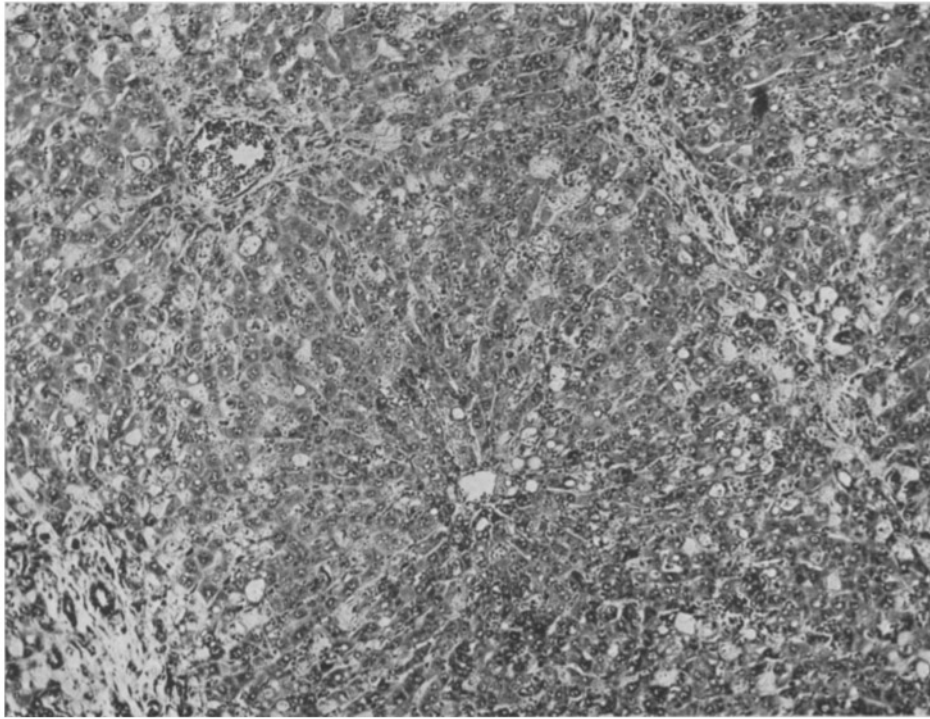


FIG. 7.

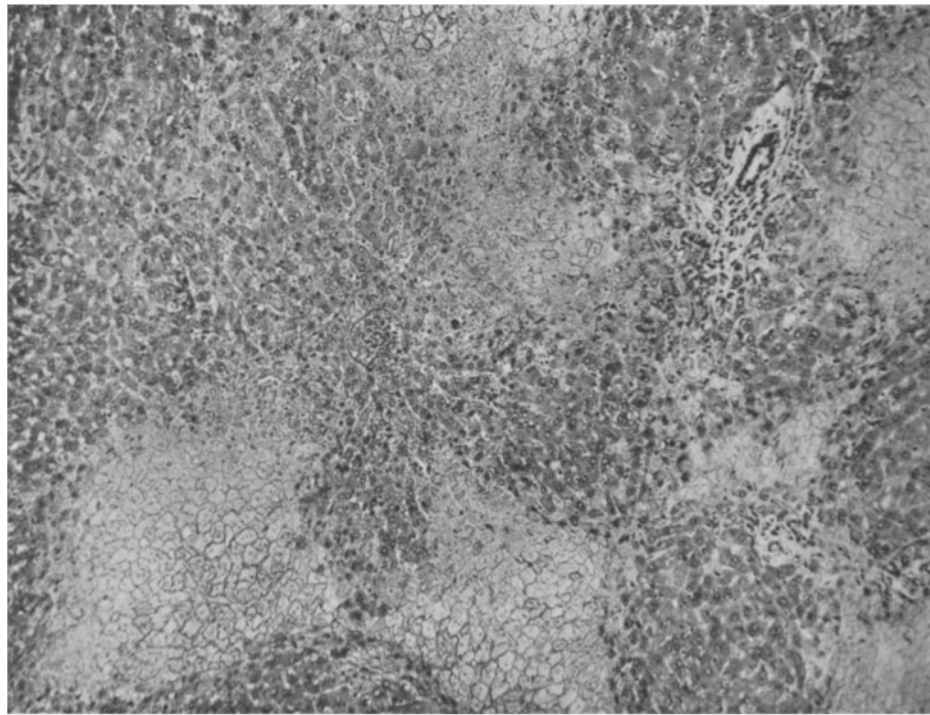


FIG. 8.

(Rous and Larimore: The biliary factor in liver lesions.)

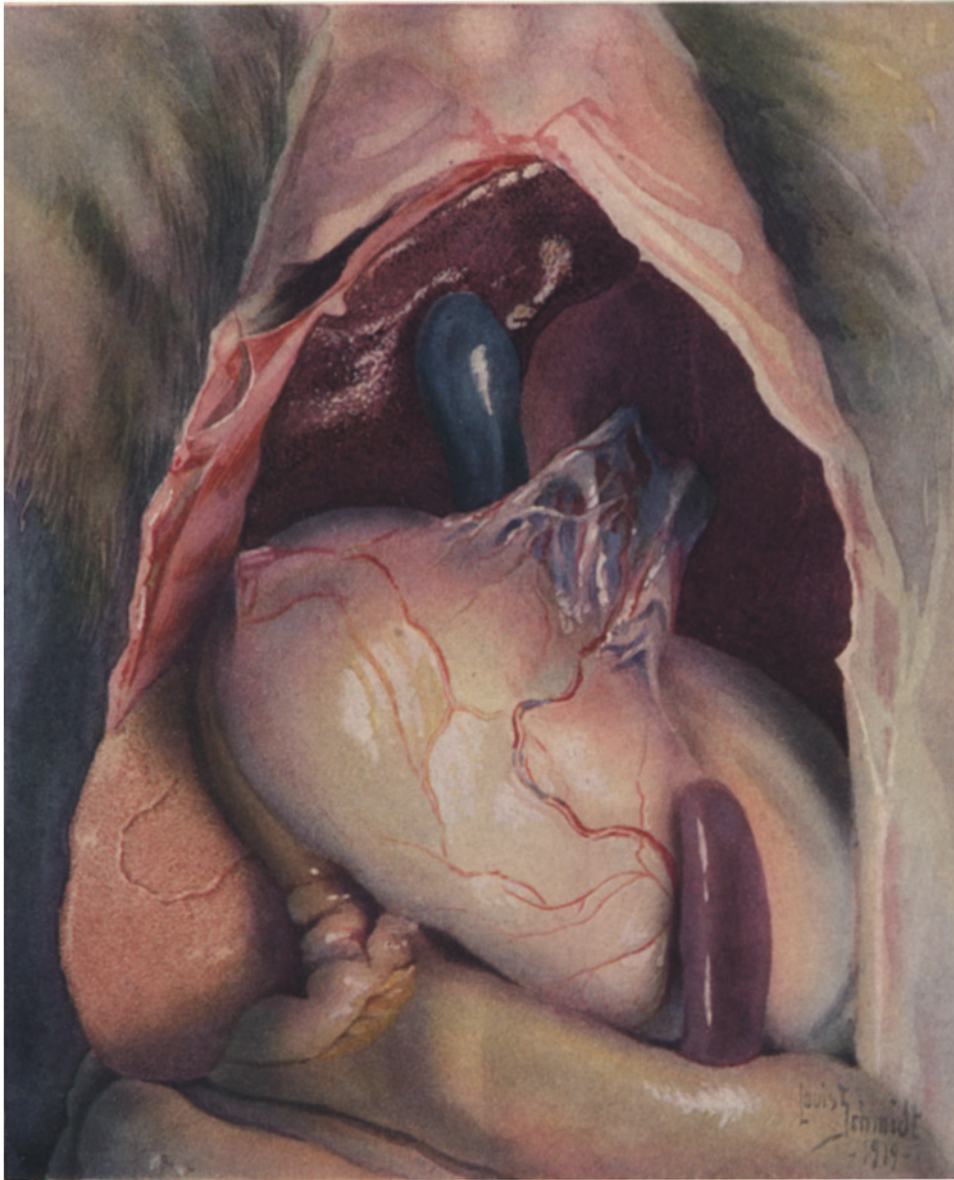


FIG. 9.

(Rous and Larimore: The biliary factor in liver lesions.)

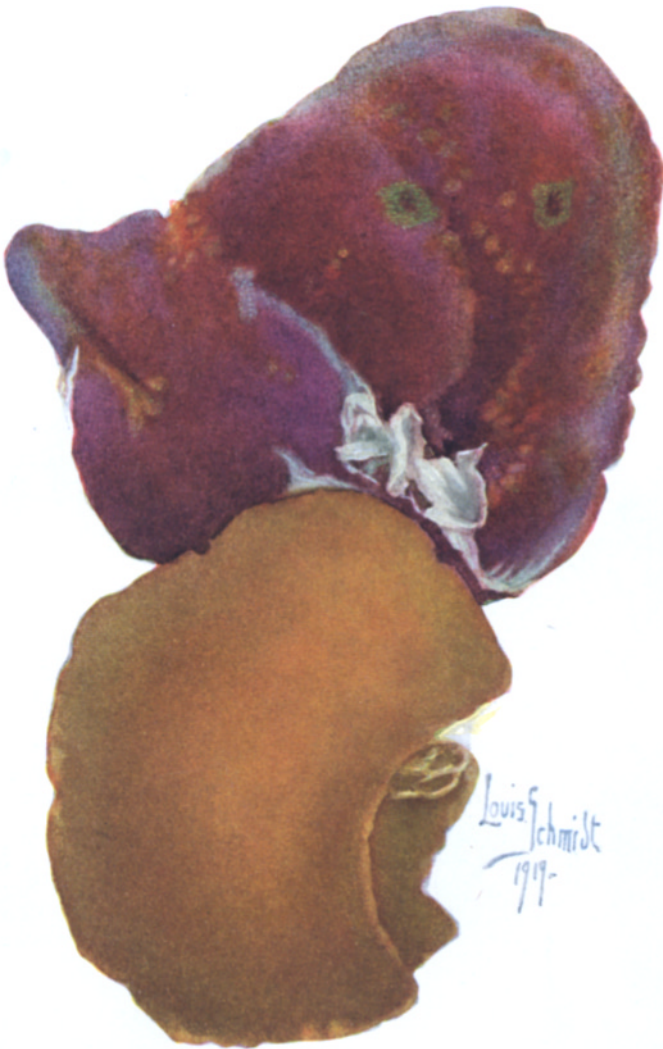

FIG. 10.

(Rous and Larimore: The biliary factor in liver lesions.)