

Extra figures

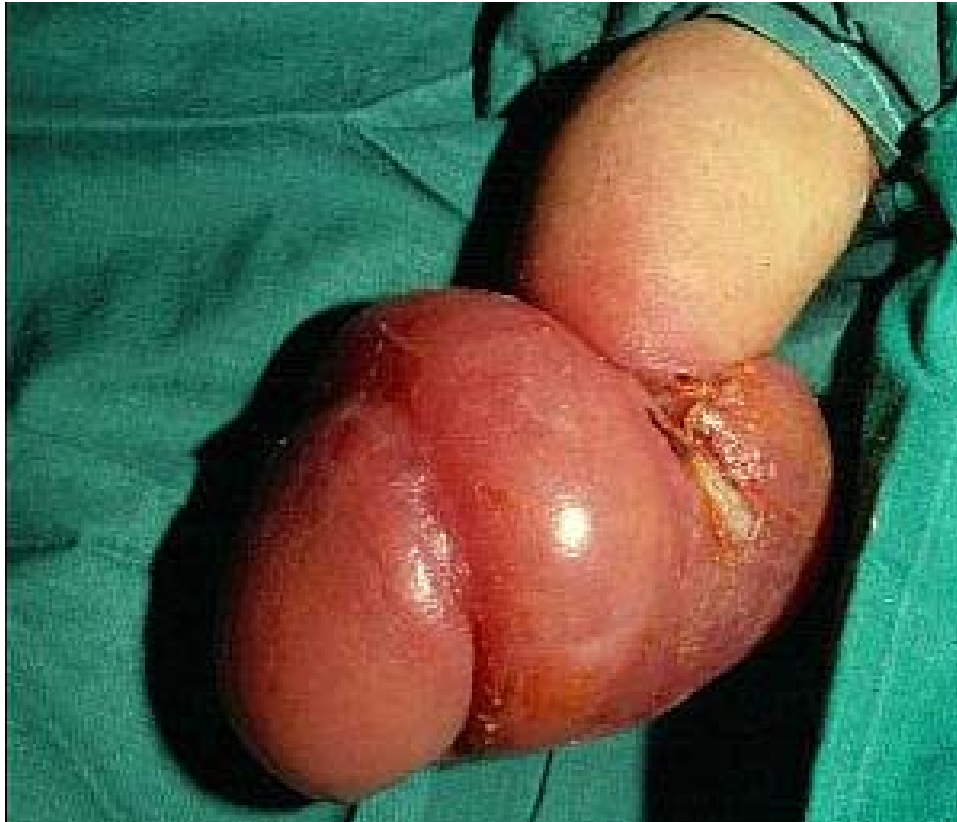

Fig A Paraphimosis

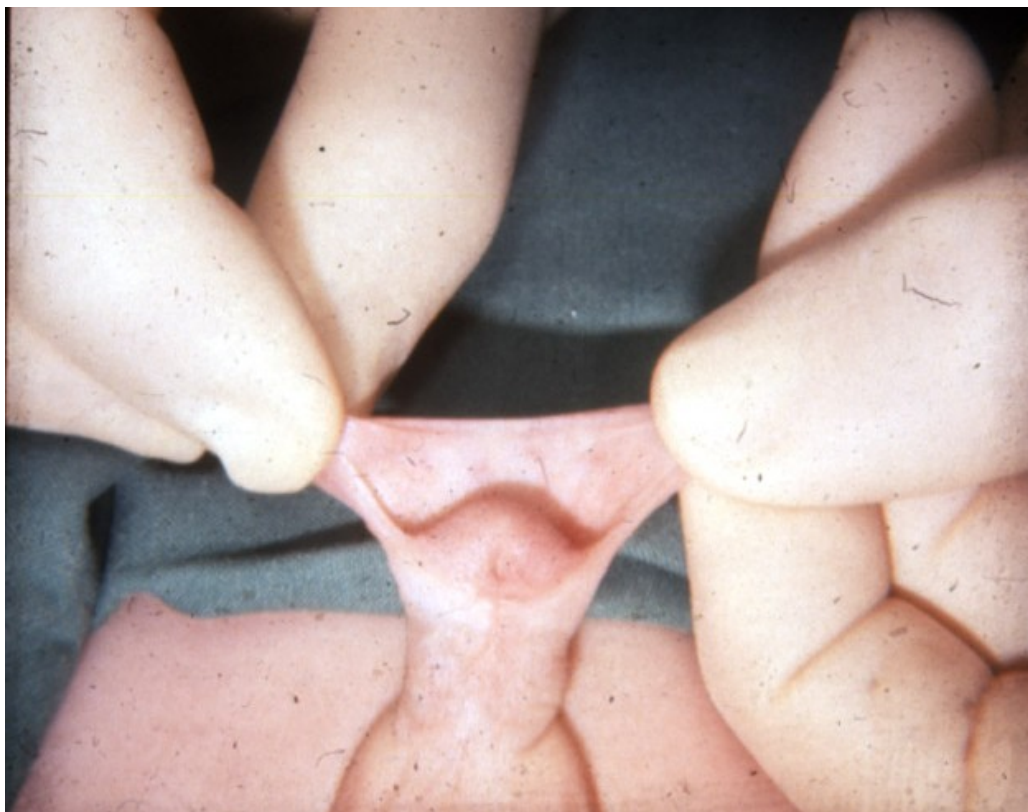


Fig b Minor hypospadias with hooded foreskin