

STUDIES ON THE MECHANISM OF RECOVERY IN PNEUMOCOCCAL PNEUMONIA

II. THE EFFECT OF SULFONAMIDE THERAPY UPON THE PULMONARY LESION OF EXPERIMENTAL PNEUMONIA*

BY W. BARRY WOOD, JR.,[‡] M.D., AND EDWIN N. IRONS,[§] M.D.

(From the Department of Medicine, Johns Hopkins University School of Medicine, Johns Hopkins Hospital, Baltimore, and the Department of Bacteriology and Immunology, Harvard Medical School, Boston)

PLATES 11 TO 14

(Received for publication, June 10, 1946)

It is now well established that the case fatality rate in pneumococcal lobar pneumonia can be appreciably decreased by the proper use of the sulfonamide drugs (1-3) and of penicillin (4). In spite of the effectiveness of these compounds in the treatment of pneumonia, the exact manner in which they bring about recovery is not understood. The effect of such chemotherapeutic agents, particularly the sulfonamides, is known to be chiefly bacteriostatic rather than bactericidal in the concentrations usually attained in the treatment of human patients (5, 6). According to the prevailing concepts of immunology, the fully encapsulated pneumococcus cannot be attacked and destroyed by phagocytic cells unless previously opsonized by type-specific antibodies (7-9). Since sulfonamide chemotherapy frequently brings about a crisis in pneumonia long before type-specific antibodies appear in the patient's serum (10, 11), the question arises as to how the pneumococci are finally destroyed in the lung.

In the preceding paper of the present series (12) these and other specific questions were raised regarding the mechanism of recovery in pneumococcal pneumonia. The pathogenesis of experimental pneumococcal pneumonia in the rat was described and the action of type-specific antibody upon the pulmonary lesion was elucidated. The present paper deals with the effect of sulfonamide chemotherapy upon the spreading pneumonic lesion.¹ Experiments are included which demonstrate that phagocytosis plays a major rôle in the final destruction of pneumococci in the lung. Subsequent papers will be concerned with the mechanism of this phagocytic reaction.

*This study was supported in part by a grant from The Rockefeller Foundation Fluid Research Fund.

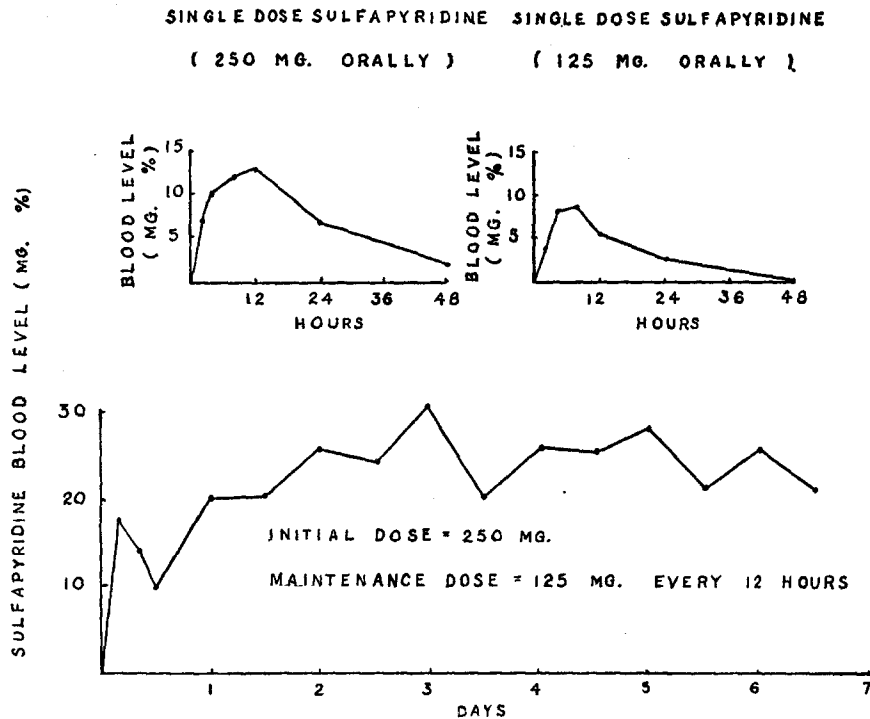
[‡]Fellow in the Medical Sciences of the National Research Council when this work was begun.

[§]Research Fellow in the Department of Medicine, Johns Hopkins University School of Medicine.

¹A brief preliminary report of these studies has already been published (13).

Methods

General.—The details of the methods employed in the production and study of experimental pneumococcal pneumonia in white rats have previously been described (12). Pneumonia was produced by intrabronchial inoculation of Type I pneumococci suspended in mucin, the inoculation being carried out under light ether anesthesia. The resulting disease was uniformly fatal in untreated animals. Blood cultures were taken from the tail at frequent intervals during the course of the pneumonia, and all lungs were fixed in Zenker-formol solution ac-



TEXT-FIG. 1. Blood concentrations of sulfapyridine in rats receiving the drug by mouth.

ording to the method of Loosli (14). Microscopic sections were stained by the Gram-Weigert technique (12) and by the differential Gram stain of Brown and Brenn (15).

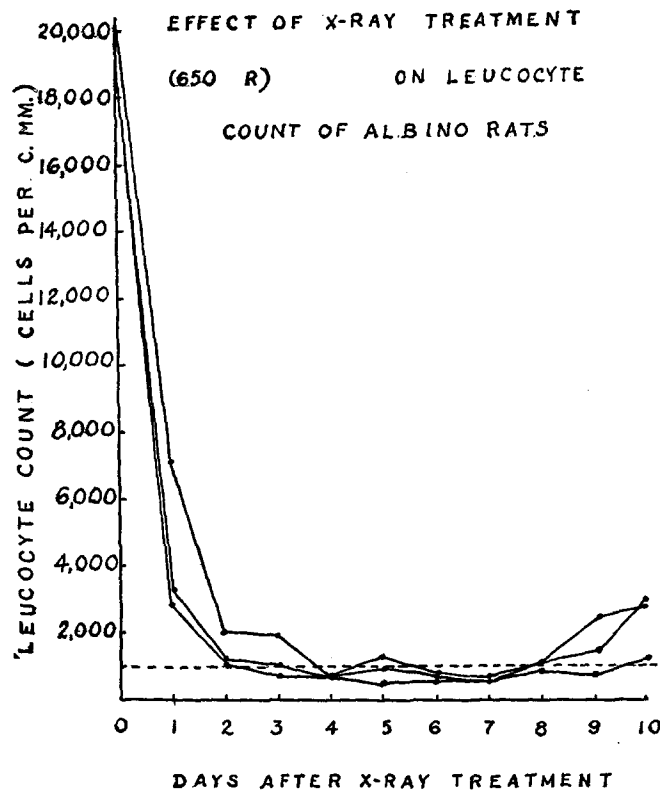
Sulfonamide Treatment.—All rats in the experiments here reported were treated with sulfapyridine 6 hours after inoculation. In other experiments sulfadiazine was employed with similar results. The powdered drug² was added to a 10 per cent gum acacia suspension and was introduced into the stomach through a blunt cannula every 12 hours by way of the mouth. Two hundred and fifty milligrams of sulfapyridine in 4 ml. of gum acacia mixture were given as an initial dose, and half this amount in 2 ml. of acacia was administered in all subsequent doses. The blood level curves³ resulting from the administration of individual doses of 250

²Supplied through the courtesy of Dr. Benjamin Carey, Lederle Laboratories, Inc.

³As determined by the method of Bratton and Marshall (16).

mg. and 125 mg., together with the concentration of drug maintained in the blood during 1 week of treatment, are depicted in Text-fig. 1. In uninfected rats no toxic effects were noted after 1 week of treatment.

Exposure to X-Ray.—A relatively acellular pneumonia was produced in rats by subjecting the animals to a single dose of 654 r of x-ray⁴ 3 days before inoculation. The radiation caused an abrupt fall in the leucocyte count within the first 48 hours. Between the 2nd and 10th days following x-ray exposure the total leucocyte counts remained in the neighborhood of 1000 cells



TEXT-FIG. 2. Daily leucocyte counts of rats exposed to x-ray (650 r).

per c. mm. (see Text-fig. 2). At varying intervals after the 10th day the irradiated animals died, apparently from emaciation, anemia, and hemorrhage from the gastrointestinal tract. Since the rats were inoculated with pneumococci on the 3rd day after radiation, there remained a period of 7 days during which the course of their pneumonia could be studied.

⁴Five rats at a time were placed in a cardboard box measuring 20 × 20 × 5 cm. and were exposed to x-ray for 12 minutes under the following conditions: voltage—200 kilovolts, current—20 milliamperes, skin-target distance—50 cm., filter—0.25 mm. copper and 1.0 mm. aluminum, portal—20 × 20 cm.

RESULTS

The Effect of Sulfonamide Treatment upon Fatality Rate.—The curative effect of sulfonamide chemotherapy was tested on a group of 20 rats.

The sulfapyridine treatment was begun 6 hours after inoculation and was continued for a period of 1 week, at the end of which all surviving animals were sacrificed. Sixteen of the treated rats survived and when sacrificed at the end of 7 days, all showed sharply demarcated localized pulmonary lesions obviously arrested by the action of the drug. Lung cultures made at autopsy were uniformly sterile. Eleven of the surviving rats developed bacteremia 12 to 36 hours after the start of treatment, but the bacteremia in each case was transient and cleared in less than 4 days. The four rats that died developed bacteremia early and succumbed within 3 days, the drug having failed to arrest the spread of the pneumonic process. As previously reported (12), all untreated rats infected with Type I pneumococcus according to the method outlined, have died in less than 5 days. In the present experiment three rats were untreated and all died within 72 hours.

The Action of Sulfonamide Chemotherapy upon the Pulmonary Lesion.—The manner in which the sulfonamide drugs act upon the pulmonary lesion was studied in treated rats sacrificed in groups of three at 6, 18, 42, 66, 96, and 168 hours after the start of treatment. In Text-fig. 3 is depicted the effect of sulfapyridine upon the bacteremia and the gross pulmonary lesion. Among the twenty-one rats studied in this experiment there were two in which the pneumonia was not controlled by treatment. Seven of the remaining nineteen had positive blood cultures 12 hours after the start of treatment, but all showed negative blood cultures at the time of autopsy. During the first 6 to 18 hours the drug had little effect upon the advancing pneumonia. The lesion continued to increase in size and its border remained irregular and hemorrhagic. At the end of 18 hours, however, the pneumonia stopped spreading, the hemorrhagic zone at the periphery of the lesion disappeared, and the margin became sharply demarcated. The area of consolidation gradually took on a dark gray color, and at the end of 1 week the lesion appeared to be slightly contracted.

Microscopic study of the lungs examined at intervals following the start of chemotherapy revealed no detectable drug effect during the first 18 hours (Fig. 1). The edema zone at the periphery of the advancing lesion remained prominent and the many pneumococci in the edema-filled alveoli at the margin indicated that the infection was still spreading rapidly. At the end of 18 hours, however, there was evidence that the drug was beginning to act. Examination of the pneumococci in the edema zone showed a striking change in their morphology. Many were swollen, pleomorphic, and irregularly stained, indicating a slowing of multiplication (17) (Fig. 2). Forty-two hours after the start of treatment the edema zone had disappeared completely (Fig. 3). By this time most of the organisms were already within the phagocytic cells (Fig. 4). Although the number of pneumococci in a single phagocyte rarely exceeded 5 or 6, the phagocytic reaction was pronounced, and resembled that

seen deep in the pneumonic lesion in untreated animals (12). After 66 hours of treatment, fewer pneumococci were visible in the phagocytic cells, many of them apparently having been destroyed by digestion. At this stage macrophages were numerous in the alveolar exudate and appeared to be taking an active part in destroying the bacteria (Fig. 5). On the 4th day no pneumococci could be found in the stained sections and after a week there was extensive resolution with only macrophages remaining in the rapidly clearing alveoli (Fig. 6).

One of the 3 rats killed at 42 hours had a positive blood culture just prior

Time after Start of Rx.	0 hours	6 hours	18 hours	42 hours	66 hours	96 hours	1 week	Untreated Rats**
Approximate Size of Pulmonary Lesion*								
Number of Rats with Bacteremia before treatment	0	0	0	0	0	0	0	—
12 hrs. after start of treatment at autopsy	—	—	1	1	2	2	3	—
	0	0	0	1***	0	1***	0	3

TEXT-FIG. 3. Effect upon pulmonary lesion and bacteremia of sulfapyridine administered 6 hours after inoculation.

*Based upon autopsy findings in 3 rats killed at each interval.

**Untreated rats died in less than 90 hours.

***Failed to survive.

to being sacrificed. Since this rat was obviously acutely ill and would have died within a few hours, it was recorded in Text-fig. 3 as representing a therapeutic failure. The histologic study of the lesion in this animal was of particular significance since it revealed active phagocytosis in spite of the bacteremia. The same phenomenon has been observed in untreated rats with bacteremia (12) and suggests that the phagocytic reaction is independent of circulating type-specific opsonins.

Effect of Chemotherapy on Pneumonia in Leucopenic Rats.—The results of the experiment just described suggest that phagocytosis plays an important rôle in the destruction of pneumococci in the lungs of rats treated with sulfonamide drugs. The demonstration of this phagocytic reaction, however, might be considered inconclusive because of the crowding of leucocytes and organisms

within the alveoli at the time the phagocytosis apparently took place. It might be argued that the pneumococci were not actually phagocytosed but merely overlay the leucocytes in the crowded exudate. The following experiments were devised to clarify this point.

A pronounced granulocytopenia was produced in white rats by exposing each animal to 650 r of x-ray administered in a single dose. The effect of the radiation upon the leucocyte count is depicted in Text-fig. 2. Three days after exposure to x-ray (when the white blood count had fallen to approximately 1000) the rats were inoculated intrabronchially with Type I pneumococcus in the usual manner.

Animals sacrificed 12 hours after inoculation exhibited a relatively acellular pneumonia. Microscopic examination of the lesion showed only edema fluid and pneumococci in the alveoli (Fig. 7). Even in the center of the lesion very few if any phagocytic cells were present in the alveoli. The complete absence of cellular exudate in the x-rayed rats contrasted sharply with the dense alveolar exudate seen in the center of the pneumonic lesion when rats not treated with x-ray were sacrificed at 12 hours (Fig. 8). At the end of 18 hours a few large pale macrophages appeared in the alveoli of the radiated animals (Fig. 9). The majority of the x-rayed rats died within 24 hours; few survived through the 2nd day.

In a second experiment rats inoculated with pneumococcus 3 days after exposure to x-ray were treated with sulfapyridine as previously described. The chemotherapy was begun 2 hours after inoculation. Thirteen out of 22 rats (59 per cent) so treated survived the infection for more than 5 days. The effect of the sulfonamide drug upon the relatively acellular pneumonia was studied in x-rayed rats killed in groups of 3 at intervals of 6, 12, 24, 42, 66, and 96 hours after inoculation. As shown in Fig. 10, many pneumococci were visible at the end of 12 hours in the edema fluid of the alveoli, together with a few macrophages. No noticeable phagocytosis was seen at this stage. After 24 hours, more macrophages appeared in the alveoli and some phagocytosis was seen. By the end of 42 hours the phagocytic reaction was marked, practically all of the pneumococci having been taken up by the macrophages (Fig. 11). The number of organisms seen within the alveolar phagocytes at 66 hours was considerably less, and after 4 days only an occasional pneumococcus was found in the section, the organisms having apparently been digested and destroyed by the macrophages (Fig. 12). These histological studies would appear to demonstrate conclusively that phagocytosis plays a part in the final destruction of pneumococci in the lungs of animals treated with sulfonamide drugs.

DISCUSSION

It has been repeatedly pointed out that the sulfonamide drugs in the concentrations usually obtained in the treatment of human patients are bacteriostatic

rather than bactericidal (5, 6). The same statement can probably be made in regard to penicillin (18, 19). Since there is no evidence that the sulfonamide drugs are directly responsible for the destruction of bacteria in the animal body, most authors have postulated that the final destruction of organisms is brought about by the natural defense mechanisms of the host (20-24). Although this hypothesis has been widely accepted, its validity has never been directly demonstrated in the case of pneumococcal infections. Several independent groups of investigators have failed to observe significant phagocytosis in animals treated with sulfonamides, although "phagocytosis is the only method so far determined by which the host is able to kill the pneumococcus (25)." Long, Bliss, and Feinstone (26), after studying the course of Type III pneumococcal peritonitis in mice treated with sulfanilamide, concluded that "the observed bacteriostasis is unaccompanied by any special degree of phagocytosis." Reid (5) likewise failed to demonstrate significant phagocytosis in the peritoneal exudate of mice treated with sulfonamide. In a study entitled "A histopathologic study of the mode of action of sulfapyridine," Lushbaugh and Cannon (27) emphasized the fact that significant phagocytosis was not observed in the pneumococcal dermal lesion of rabbits treated with sulfapyridine. Finally, Goldstein and Greiff (28) studied the influence of sulfanilamide and sulfapyridine on experimental pneumococcal pneumonia in rats, and although they demonstrated the curative effect of these drugs in experimental pneumonia, they, too, stated that "the disposal of bacteria in the treated animals did not appear to be related to phagocytosis."

The studies reported in the present paper are not in agreement with those of the above authors. Through a careful histologic study of the lungs of pneumonic rats treated with sulfapyridine and sacrificed at various intervals after the start of treatment, it has been possible to ascertain the manner in which the sulfonamide drugs act upon the pulmonary lesion of pneumococcal pneumonia. During the first 6 to 18 hours of treatment the drug has little effect upon the organisms in the lesion. The pneumococci which are numerous in the edema zone of the advancing lesion apparently continue to multiply unaffected by the drug. By the end of 18 hours there is morphological evidence of bacteriostasis. Close examination of the pneumococci in the edema zone reveals that many of them are swollen, pleomorphic, and irregularly stained. These morphological changes are characteristic of a disturbance in bacterial growth (15). As a result of the bacteriostatic action of the drug the pneumococci cease to multiply and no further invasion of the surrounding alveoli takes place. By 42 hours the edema zone has completely disappeared from the margin of the lesion, having been replaced by alveoli filled with phagocytic cells. At the periphery of the lesion, where both pneumococci and leucocytes are numerous in the alveoli, the organisms are quickly taken up by the phagocytic cells. It should be emphasized that the phagocytosis is seen only in this peripheral zone, the

center of the lesion containing few if any organisms. The clearing of the central portion of the lesion has already been described in studies on untreated animals (12, 29) and will be further discussed in a subsequent paper. By the end of the 4th day, all of the pneumococci have been eliminated from the lesion even at the periphery, the bacteria apparently having been digested by the phagocytic cells. Organisms in various stages of digestion are seen within the alveolar phagocytes at 18 and 42 hours. The final resolution of the pneumonic lesion is characterized by disappearance of the polymorphonuclear leucocytes, with only macrophages remaining in the alveoli.

To demonstrate more clearly the phagocytic reaction which occurs in the lungs of animals treated with sulfonamide drugs, a study was made of a relatively acellular pneumonia produced in rats previously exposed to x-ray. Since the radiated animals were suffering from a pronounced granulocytopenia at the time that the pneumonia was produced, their pneumonic lesions contained no polymorphonuclear leucocytes and only relatively small numbers of macrophages. Under these experimental conditions, in which each alveolus contained many pneumococci and only a few phagocytic cells to attack them, there remained no doubt about the occurrence of phagocytosis.

In comparing the results of the present studies with those of the authors mentioned above, it should be pointed out that only the experiments of Goldstein and Greiff are comparable to those reported in the present paper. All of the other studies mentioned concerned extrapulmonary pneumococcal infections. The conditions obtaining in the peritoneal exudate of mice and the dermal lesions of rabbits are not strictly comparable to those of experimental pulmonary infections. It is quite possible that other factors, such as bacteriolysis, may play a more important rôle in the destruction of pneumococci in the peritoneal cavity and subcutaneous tissues. No satisfactory explanation can be offered, however, for the failure of Goldstein and Greiff to observe the same degree of phagocytosis noted in the present study, unless possibly greater attention was paid in the present investigation to the peripheral portion of the pneumonic lesion, where most of the phagocytosis apparently takes place.

It is concluded from the present experiments that the sulfonamide drugs bring about recovery in pneumococcal pneumonia by exerting a bacteriostatic effect upon the pneumococci in the advancing edema zone at the periphery of the lesion. This bacteriostatic action prevents the spread of the pneumonia and allows the alveolar phagocytic cells to overtake the pneumococci in the previously advancing portions of the lesion. Once the phagocytic cells have reached the pneumococci they are apparently able to phagocytize and destroy them.

It is of interest to compare the action of sulfonamide drugs with that of antiserum. It has been demonstrated in a previous study (12) that type-specific antibody acts almost immediately, stopping the spread of experimental

pneumococcal pneumonia by agglutinating the pneumococci in the edema zone at the advancing margin of the lesion. Once the pneumococci have thus been immobilized by the antiserum, they are engulfed by the alveolar phagocytic cells and destroyed by phagocytosis. The sulfonamide drugs, on the other hand, act more slowly, having no appreciable effect on the pneumonia during the first 6 to 18 hours of treatment. This noticeable lag in the course of events is apparently due to two factors. First, the drug is absorbed relatively slowly from the gastrointestinal tract, the maximum blood level from the initial oral dose being reached only after 8 to 12 hours (Text-fig. 1). Secondly, none of the sulfonamides exert an inhibitory effect upon the growth of bacteria until they have been in direct contact with the organisms for several hours (30). Once the drug begins to act, its bacteriostatic effect enables the pneumococci at the advancing margin to be destroyed by the alveolar phagocytes, and the lesion ceases to spread. In both instances, therefore, phagocytosis appears to play an important part in the final removal of pneumococci from the lung. It should be emphasized that the present experiments do not indicate that phagocytosis is the only factor involved. It is possible that other factors are of importance, and certain of these are now under investigation.

That phagocytosis should occur in the lungs of animals treated with type-specific antiserum is not surprising in view of the fact that the antibody penetrates the pneumonic lesion and is present in the alveolar exudate (12). The phagocytosis observed in sulfonamide-treated rats, however, is extremely difficult to explain in the light of present concepts of immunology. It is generally believed that the fully encapsulated pneumococcus cannot be attacked by phagocytic cells unless previously opsonized by type-specific antibody (7-9), though some evidence exists to the contrary (31). The phagocytosis that occurs in sulfonamide-treated animals begins within 18 hours of the start of treatment and has been noted in animals with bacteremia. Both of these facts make it seem unlikely that type-specific antibody is present in the blood of these animals at the time that the phagocytosis occurs (32, 33). Since the natural defense of the lung against pneumococcal infection appears to depend largely upon phagocytosis, an attempt has been made to analyze further the factors responsible for the occurrence of the phagocytic reaction.

SUMMARY

Experimental pneumococcal pneumonia was produced in albino rats by intrabronchial inoculation of Type I pneumococci suspended in mucin. The resulting pneumonia was uniformly fatal in untreated rats. Eighty per cent of the animals so infected and treated with sulfonamide drugs 6 hours after inoculation survived the pneumonia. At the end of 1 week the surviving animals were sacrificed, and examination of the lungs showed sharply demarcated localized pulmonary lesions containing no pneumococci.

Microscopic study of the lungs of treated animals sacrificed at 6, 18, 42, 66,

96, and 168 hours after the start of treatment revealed the following sequence of events. During the first 18 hours the drug apparently had little effect upon the pneumonic lesion, but at the end of 18 hours pneumococci in the edema zone began to show striking changes in their morphology, indicating bacteriostasis. Forty-two hours after the start of treatment the edema zone had disappeared, the pneumonia had ceased to spread, and the pneumococci at the margin of the lesion had been overtaken by leucocytes. Careful examination of the exudate in the periphery of the lesion revealed definite phagocytosis of pneumococci. By the 4th day no pneumococci could be found in the stained sections, and after 1 week there remained only macrophages in the rapidly clearing alveoli.

In order to demonstrate the phagocytic reaction more clearly the effect of sulfonamide drugs was studied in pneumonic rats previously rendered leucopenic by exposure to x-ray. The pneumonia in these animals was relatively acellular, and the few macrophages present in each alveolus could be seen to have phagocytosed large numbers of pneumococci after 18 to 42 hours of treatment. The macrophages not only phagocytosed the pneumococci but ultimately destroyed them, the pneumonic lesion later going on to complete resolution. The fact that this phagocytic reaction was observed in the lungs of animals with bacteremia suggests that the phagocytosis is independent of circulating type-specific opsonins.

BIBLIOGRAPHY

1. Finland, M., Strauss, E., and Peterson, O. L., *J. Am. Med. Assn.*, 1941, **116**, 2641
2. Flippin, H. F., Rose, S. B., Schwartz, L., and Domm, A. H., *Am. J. Med. Sc.* 1941, **201**, 585.
3. Billings, F. T., Jr., and Wood, W. B., Jr., *Bull. Johns Hopkins Hosp.*, 1941, **69**, 314.
4. Tillett, W. S., McCormack, J. E., and Cambier, M. J., *J. Clin. Inv.*, 1945, **24**, 589.
5. Reid, R. D., *Proc. Soc. Exp. Biol. and Med.*, 1939, **41**, 437.
6. Finland, M., Spring, W. C., Jr., and Lowell, F. C., *J. Clin. Inv.*, 1940, **19**, 163.
7. Neufeld, F., and Rimpau, W., *Deutsch. med. Woch.*, 1940, **30**, 1458.
8. Ward, H. K., and Enders, J. F., *J. Exp. Med.*, 1933, **57**, 527.
9. Robertson, O. H., and Van Sant, H., *J. Immunol.*, 1939, **37**, 571.
10. Wood, W. B., Jr., and Long, P. H., *Ann. Int. Med.*, 1939, **13**, 612.
11. Finland, M., Spring, W. C., Jr., and Lowell, F. C., *J. Clin. Inv.*, 1940, **19**, 179.
12. Wood, W. B., Jr., *J. Exp. Med.*, 1941, **73**, 201.
13. Wood, W. B., Jr., *Proc. Soc. Exp. Biol. and Med.*, 1940, **45**, 348.
14. Loosli, C. G., *Arch. Path.*, 1937, **24**, 743.
15. Brown, J. H., and Brenn, L., *Bull. Johns Hopkins Hosp.*, 1931, **48**, 69.
16. Bratton, A. C., and Marshall, E. K., Jr., *J. Biol. Chem.*, 1939, **128**, 537.
17. Stephenson, M., *Bacterial Metabolism*, London, Longmans, Green and Co., 1939, 216.

18. Abraham, E. P., Chain, E., Fletcher, C. M., Florey, H. W., Gardner, A. D., Heatley, N. G., and Jennings, M. A., *Lancet*, 1941, **2**, 177.
19. Florey, M. E., and Florey, H. W., *Lancet*, 1943, **1**, 387.
20. Long, P. H., and Bliss, E. A., *The Clinical and Experimental Use of Sulfanilamide Sulfapyridine and Allied Compounds*, New York, Macmillan Co., 1939.
21. Keefer, C. S., *Med. Clin. North America*, 1939, **23**, 113.
22. Fleming, A., *Proc. Roy. Soc. Med.*, 1940, **23**, 127.
23. Kolmer, J. A., *Arch. Int. Med.*, 1940, **65**, 671.
24. Fischer, A., *Arch. internat. pharmacod et therap.*, 1937, **56**, 131.
25. Heffron, R., *Pneumonia with Special Reference to Pneumococcal Lobar Pneumonia*, New York, The Commonwealth Fund, 1939, 95.
26. Long, P. H., Bliss, E. A., and Feinstone, W. H., *J. Am. Med. Assn.*, 1939, **112**, 115.
27. Lushbaugh, C., and Cannon, P. R., *J. Infect. Dis.*, 1942, **71**, 33.
28. Goldstein, H. H., and Greiff, I., *Arch. Pathol.*, 1940, **30**, 701.
29. Robertson, O. H., *J. Am. Med. Assn.*, 1938, **111**, 1932.
30. Chandler, C. A., and Janeway, C. A., *Proc. Soc. Exp. Biol. and Med.*, 1939, **40**, 179.
31. Goodner, K., and Miller, D. K., *J. Exp. Med.*, 1935, **62**, 375.
32. Robertson, O. H., Graeser, J. B., Coggeshall, L. T., and Harrison, M. A., *J. Clin. Inv.*, 1934, **13**, 621.
33. Terrell, E. E., *J. Exp. Med.*, 1930, **51**, 425.

EXPLANATION OF PLATES

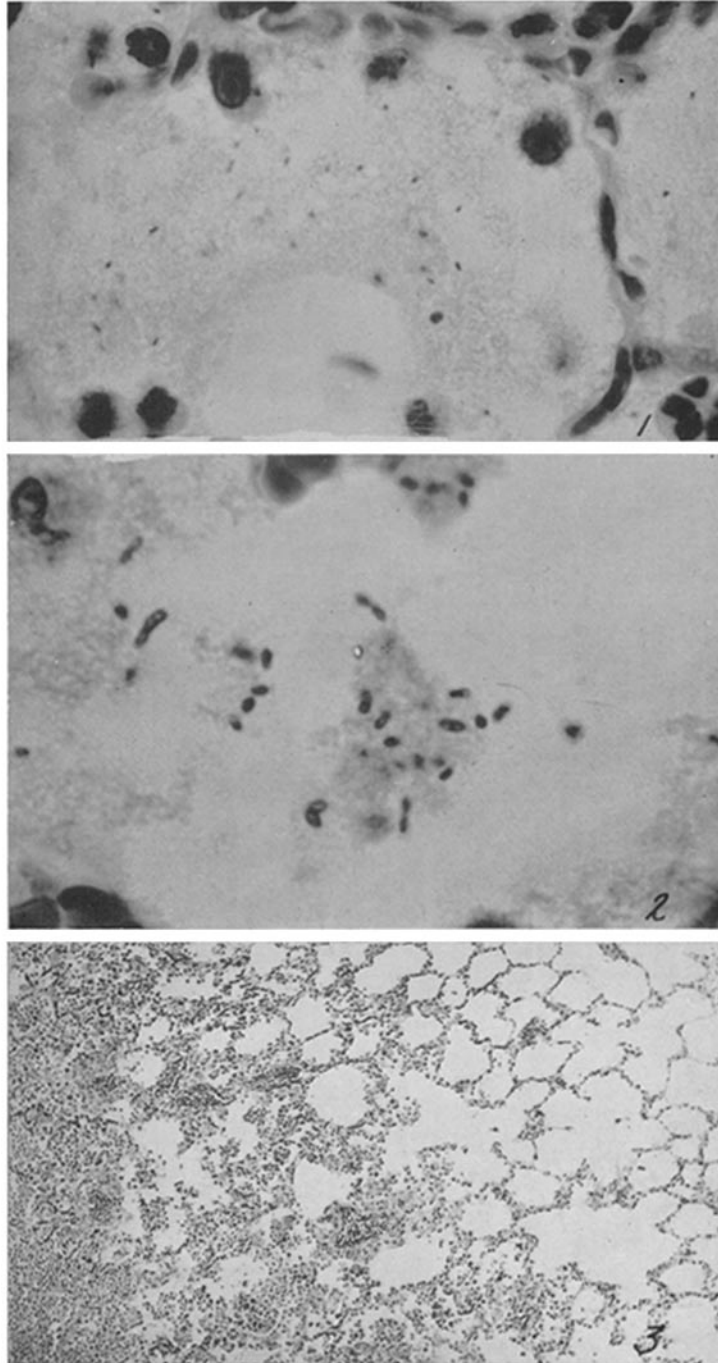
Sections stained by the Gram-Weigert technique and photographed by Mr. Milton Kogl.

PLATE 11

FIG. 1. Pneumococci in the edema zone at the advancing margin of the lesion. Sulfapyridine therapy was begun 6 hours after inoculation, and the rat was sacrificed 6 hours later. The lesion appears to be still spreading at this time, there being as yet no evidence of bacteriostasis. $\times 800$.

FIG. 2. The pneumococci in the edema zone after 18 hours of treatment are swollen, pleomorphic, and poorly stained—changes characteristic of bacteriostasis. $\times 1500$.

FIG. 3. Forty-two hours after the start of treatment the zone of edema has disappeared completely from the margin of the lesion. $\times 160$.



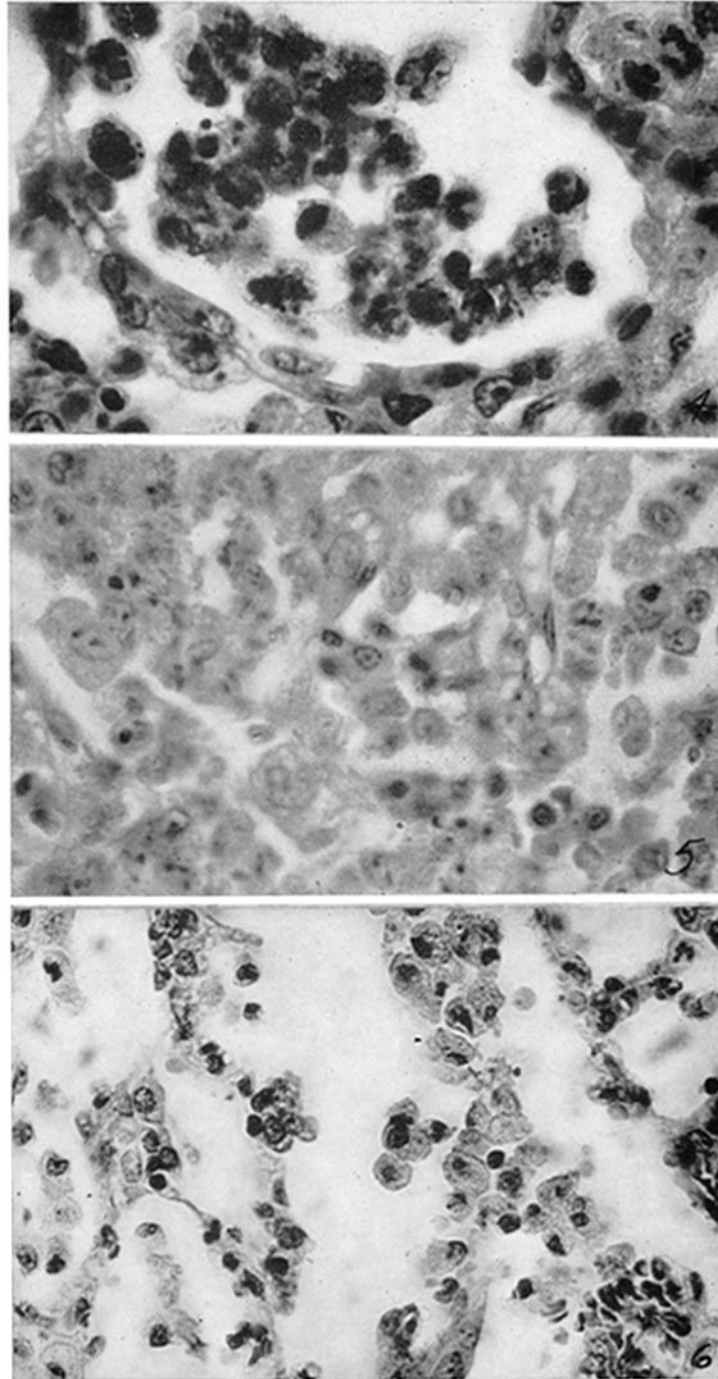
(Wood and Irons: Mechanism of recovery in pneumococcal pneumonia. II)

PLATE 12

FIG. 4. This section made from the lung of a rat sacrificed 42 hours after the onset of treatment shows pneumococci within the phagocytic cells of the exudate. The alveolus pictured is located near the margin of the lesion. $\times 800$.

FIG. 5. After 66 hours of treatment the pneumococci have been digested by the alveolar phagocytes and are no longer visible. $\times 800$.

FIG. 6. Macrophages predominate in the alveoli 1 week after the start of treatment, and there is definite resolution of the lesion with marked clearing of the alveolar exudate. $\times 800$.



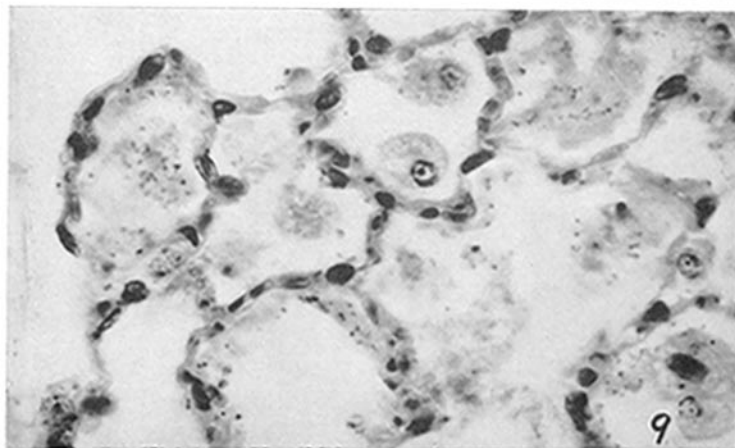
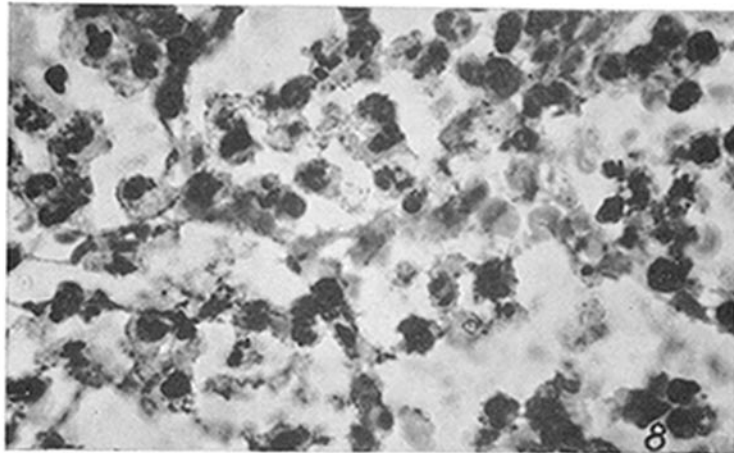
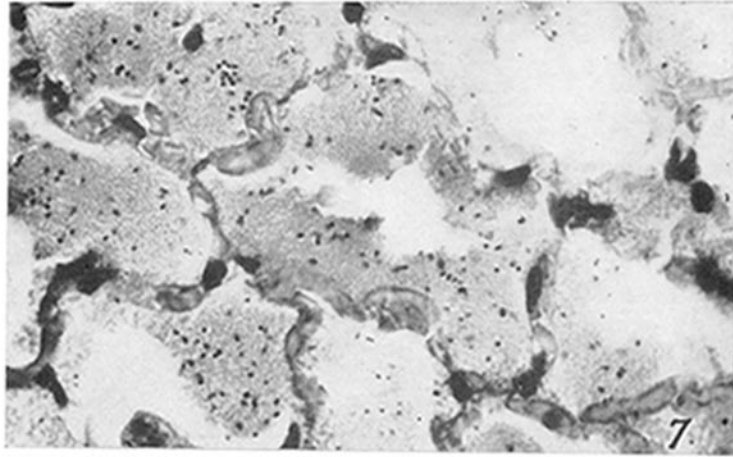
(Wood and Irons: Mechanism of recovery in pneumococcal pneumonia. II)

PLATE 13

FIG. 7. Section through the center of the pulmonary lesion of a rat infected 3 days after exposure to x-ray and sacrificed 12 hours after inoculation. Note absence of cells in alveoli and numerous pneumococci in edema fluid. (Contrast with Fig. 8.)
× 800.

FIG. 8. Section through the center of the pulmonary lesion of a rat that received no x-ray and was killed 12 hours after inoculation. Note heavy alveolar exudate.
× 800.

FIG. 9. Center of pneumonic lesion in x-rayed rat sacrificed 18 hours after inoculation. A few large pale macrophages are beginning to appear in the alveoli, although there are no polymorphonuclear leucocytes present. The macrophages are apparently unaffected by the x-ray and are called out by the inflammatory response in the lung
× 800.



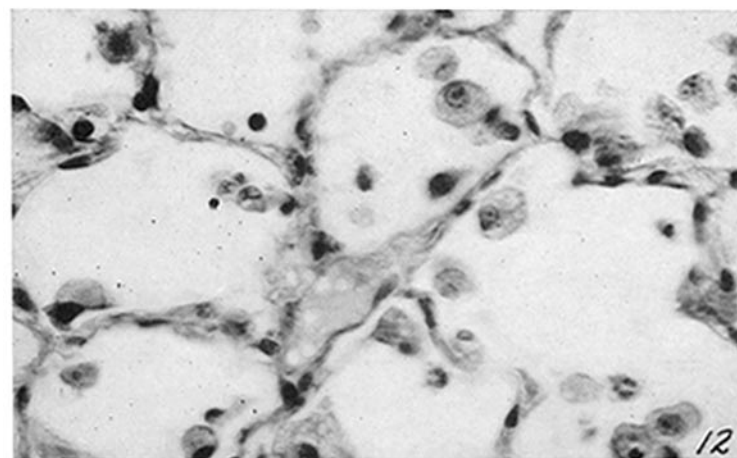
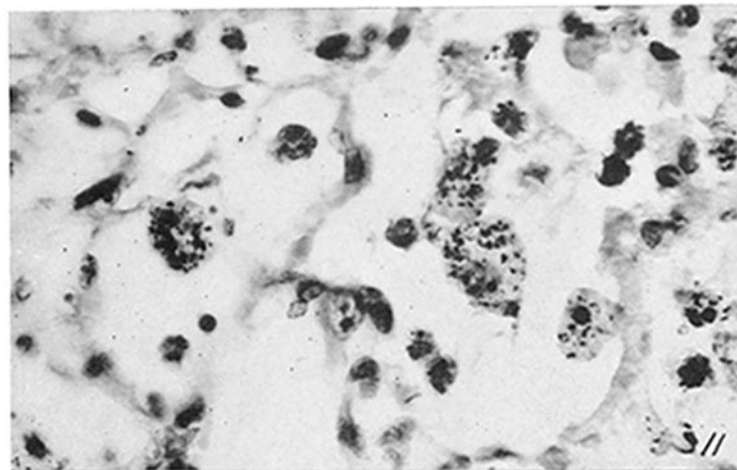
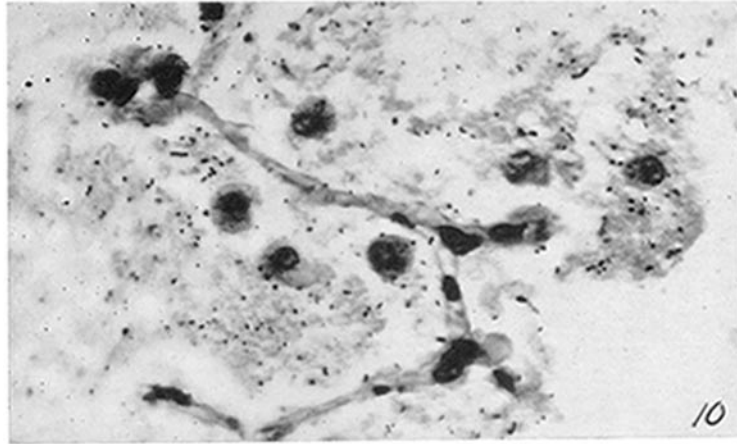
(Wood and Irons: Mechanism of recovery in pneumococcal pneumonia. II)

PLATE 14

FIG. 10. X-rayed rat sacrificed 12 hours after onset of treatment with sulfapyridine which was begun 2 hours after inoculation. At this stage there is no appreciable phagocytosis, although pneumococci are in intimate contact with the few macrophages in the alveoli. $\times 800$.

FIG. 11. After 42 hours of treatment marked phagocytosis is seen in the lung of the x-rayed rat, practically all of the pneumococci having been taken up by the macrophages. $\times 800$.

FIG. 12. Pneumococci are no longer visible in the macrophages of the x-rayed animal after 4 days of treatment and there is noticeable clearing of the lesion. $\times 800$.



(Wood and Irons: Mechanism of recovery in pneumococcal pneumonia. II)