

THE INFLUENCE OF INJECTIONS OF HOMOLOGOUS HEMOGLOBIN
ON THE KIDNEYS OF NORMAL AND
DEHYDRATED ANIMALS

By JOSEPH J. LALICH, M.D.

(From the Department of Pathology, University of Wisconsin
Medical School, Madison)

PLATE 17

(Received for publication, April 11, 1947)

The importance of intravascular hemolysis following mismatched transfusions of whole blood is generally appreciated. The probability of intravascular hemolysis has been greatly enhanced with the accentuated employment of whole blood in the treatment of patients. Lucké, who quotes Mallory and Angevine and Harman, states that the incidence of lower nephron nephrosis in battle casualties is 15.2 to 18.6 per cent (1). Although hemoglobin was suspected to be a causative factor in many of these cases, attempts to produce experimental nephrosis with hemoglobin have resulted in unexplained difficulties.

Yorke and Nauss were the first to report suppression of urine following intravenous injections of hemoglobin into rabbits (2). Baker and Dodds confirmed this and ascribed the precipitation of the hemoglobin in the tubules to an acid urine (3). DeGowin, Warner, and Randall injected homologous hemoglobin into dogs and reported obstruction of tubules close to Henle's loop in 6 of 18 of their animals (4). These authors attributed the obstruction to an acid urine. While attempting to reproduce hemoglobinuric nephrosis in rabbits, DeNavasquez was unable to confirm the results of the previous workers (5). Hueper was unable to detect any alteration in the kidneys of dogs following injections of hemoglobin (7). Bing found hemoglobin ineffective in the production of renal failure in normal and acidotic dogs (6). Yuile, Gold, and Hinds were able to produce precipitation of hemoglobin in the tubules of rabbits, following intravenous injection of hemoglobin, only after previously clamping the renal artery or injecting sodium tartrate (8).

The recent literature therefore indicates that solutions of pure hemoglobin can be injected intravenously into animals with either acid or alkaline urine without producing significant impairment of renal function. Studies (4, 8) also suggest that some factor or factors must precede or be associated with the hemoglobinemia if renal impairment is to develop. In view of this probability it was decided to study the influence of injections of homologous hemoglobin in normal and dehydrated animals.

Method

Animals.—The animals used in this study were Sprague-Dawley rats weighing 71 to 110 gm., guinea pigs weighing 155 to 680 gm., and albino rabbits weighing 1.8 to 3.0 kg. Both male and female animals were used.

Preparation of Hemoglobin.—Blood was withdrawn from the heart of several animals and pooled in a flask containing sodium citrate (5 mg./ml.). The blood was centrifuged at 2500 R.P.M. for 1 hour, the plasma withdrawn, and the erythrocytes washed with an equal volume of physiologic saline solution. Following the second centrifugation the saline was removed and the erythrocytes were laked by the addition of two volumes of recently distilled water. The stroma was removed by 45 minutes of centrifugation at 15,000 R.P.M. and subsequent filtration through two thicknesses of Whatman's No. 40 filter paper at a negative pressure of 500 to 700 mm. Hg. The hemoglobin concentration was determined in a 1:300 dilution of 0.1 per cent Na_2CO_3 solution with a photoelectric colorimeter. Hemoglobin solutions, never older than 2 days, were kept at 4–6°C. when not in use.

State of Hydration and Method of Injection.—The rats and guinea pigs were fed and offered water up to the time of injection. Hemoglobin solutions containing stroma were injected intraperitoneally in single doses into these animals.

Water was withheld from the rabbits for periods of 1 to 5 days. Stroma-free hemoglobin solutions were injected intravenously at one time, or in divided doses on successive days toward the end of the dehydration period. Water was then withheld for a period of 18 to 24 hours after the last injection. Thereafter 200 ml. of water was given daily to 6 rabbits (Nos. 1 to 6) for 1 week. One rabbit (No. 7) received 28 ml. daily for 7 days. The last 9 rabbits (Nos. 8 to 16) received 25 ml./kg. of water for 1 week. After the 14th day the rabbits were given food and water at desire.

Blood Studies.—Heart blood was withdrawn at intervals for non-protein nitrogen determinations and hematocrit studies.

Subsequent Observations.—The rabbits were weighed both before and following dehydration as well as at the time of necropsy. Animals which did not die following the injections were killed from 4 to 40 days thereafter. Autopsies were performed, the tissues fixed in 10 per cent formalin, sectioned, and stained with hematoxylin and eosin.

Results of the Injections into Rats and Guinea Pigs

The rats received hemoglobin suspensions in amounts of 5, 6, and 7 gm./kg. of body weight intraperitoneally. Following the injection of 5 gm./kg. one of 11 animals died on the 2nd day. After 6 gm./kg. one of 12 animals died after 24 hours. When 7 gm./kg. were given, 9 rats died between 12 to 24 hours; 2 died after 24 hours and only one survived. Practically all of the animals had hemoglobinuria. Those that died developed cyanosis about the jaws and feet. Their abdomens remained distended following the injections, and at autopsy there was peritoneal fluid containing hemoglobin. On gross inspection of the organs no significant change was noted than cyanosis. Autopsies made on the animals which survived revealed no abnormalities. Microscopic examination of the kidneys revealed an occasional cast in only 2 rats. No casts or tubular changes were observed in sections of the remaining 35 rats.

The guinea pigs received 1, 2, 3, and 3.5 gm./kg. of hemoglobin intraperitoneally in one dose. Six animals which received 1 gm./kg. survived without any ill effects. One of 6 guinea pigs died after an injection of 2 gm./kg. Following the injection of 3 gm./kg., 3 died after 12 to 24 hours; one died on the 3rd day from peritonitis, and 2 survived. In a final group 3.5 gm./kg. produced death in all of 8 guinea pigs in less than 10 hours. Those which died following the injections usually had minimal traces of hemoglobin in the peritoneal fluid. Sections from these 26 animals did not reveal any casts or tubular changes.

Results of the Injections into Rabbits

The results obtained with dehydration and intravenous injections of hemoglobin into rabbits are tabulated in Table I. It illustrates the influence of de-

hydration on the precipitation of hemoglobin in the tubules. The NPN was elevated in 8 of the 14 recorded instances. In 5 the elevation was temporary; in 3 rabbits, which subsequently died in uremia, the NPN was in excess of 199 mg. per cent; in 6 rabbits the NPN remained below 43 mg. per cent.

TABLE I
The Influence of Dehydration on the Production of Hemoglobinuric Nephrosis Following Intravenous Injections of Hemoglobin into Rabbits

No.	Dehy- dration	Quantity of blood removed during Dehy- dration	Quantity of hemo- globin injected	Highest recorded NPN	Interval after injection	Total weight of kidneys	Microscopic examination of kidneys		
							Pig- ment casts	Dilated tubules	Necrosis of tubular epithelium
	days	ml.	gm./kg.	mg. per cent	days	gm.			
1	1	0	1.9(1)1	—	14	—	1+	—	—
2	1	0	1.3(1)1	—	1*	—	—	—	—
3	4	12	1.2(5)2†	61	29	17.5	2+	+	—
4	4	19	1.5(5)2	67	6	17.5	2+	+	—
5	4	49	1.4(4)2	42	40	20.5	—	+	—
6	4	69	1.0(3)2	29	1*	15.1	1+	—	—
7	3	12	1.6(4)2	35	40	19.0	2+	+	—
8	3	12	1.5(6)2	300+	11*	26.0	3+	+	+
9	3	12	1.6(6)2	30	2*	—	2+	+	—
10	3	12	1.6(6)2	34	4	15.2	1+	+	+
11	5	17	1.7(7)3	63	15	22.6	3+	+	—
12	5	38	1.8(7)3	200	14*	19.2	3+	+	+
13	5	42	1.7(7)3	97	14	12.8	2+	+	+
14	5	34	1.7(7)3	60	15	15.4	2+	+	—
15	4	31	1.5(8)2	300+	6*	36.0	3+	+	+
16	4	54	1.4(6)2	42	14	14.8	1+	+	—

1+ = less than one cast per low power field.

2+ = 1 to 5 casts per low power field.

3+ = 5 to 15 casts per low power field.

* = died.

† 1.2(5)2 = 1.2 gm./kg. injected in five divided doses on 2 successive days.

Pathological Findings.—

Kidneys.—When death occurred prior to the 4th day no significant alterations were noted in any of the organs. The kidneys appeared congested. After the 4th day in practically all animals there were minute dark brown flecks 1 to 2 mm. across on the surface of the kidney. The brown pigment accentuated the cortical striations on the cut surface and was principally deposited in the cortex of the kidney (Fig. 1.). There were wide variations in the amount of pigment, but its localization was uniform. The combined weight of the kidneys in each instance exceeded the normal median value of 12.5 gm. reported by Brown, Pearce, and Van Allen (9).

The casts were orange or green yellow in color and therefore easily distinguishable from eosin-staining casts, usually considered to consist of albumen. Because the chemical nature

of the casts in the tubules remains undetermined, they will be referred to as pigment casts. Practically all of the pigment casts were localized in the cortical area, principally in the distal convoluted tubules. A few casts were also found in Henle's loops and the collecting tubules (Fig. 2 and 3). Prior to the 4th day the substance observed in the lumina was reddish yellow and of a homogeneous glass-like consistency. In view of the lack of granularity, the pronounced yellow color, and the absence of associated tubular changes, this substance as occurring in three animals was not considered to represent formed casts. Excluding these animals, however, characteristic pigmented casts were demonstrated in 12 of 13 rabbits from 4 to 40 days after the injections of hemoglobin. In conjunction with the presence of casts there was an associated tubular dilation. In the majority of instances there were focal areas of lymphoid infiltration. In only 5 of 13 kidneys was there minimal necrosis of tubular epithelium. Necrosis of the tubular epithelium and lymphoid infiltration appeared to follow rather than precede the plugging of tubules by the pigmented casts.

Heart.—The hearts in some instances showed minimal pericardial hemorrhages incident to cardiac puncture. Microscopic examination revealed extensive areas of focal necrosis and calcification of myocardial fibers in 2 animals.

Lung.—Three of the animals had an associated pneumonia at the time of death. Microscopic examination did not reveal any consistent variations from normal.

Liver.—Gross examination of the liver revealed no significant change. Microscopic examination revealed minimal collections of pigment about the central vein in only one animal.

Spleen.—The spleen was not enlarged in any instance. Microscopic examination usually showed moderate phagocytosis of hemosiderin by macrophages.

DISCUSSION

In accordance with previous findings in animals (5, 6), the experiments on rats and guinea pigs clearly indicate that in these animals on a suitable diet with adequate quantities of water, hemoglobin is readily excreted by the kidneys. Only a few casts were demonstrable in 2 of 63 animals after injections of large amounts of hemoglobin. Several features become evident in the findings in rabbits. Apparently a certain time must elapse before the intratubular hemoglobin is precipitated or sufficiently concentrated to occur in casts that are demonstrable in tissues by the usual staining methods. Furthermore a relationship exists between the quantity of hemoglobin injected and the state of hydration of the animal. Yorke and Nauss (2) observed casts after injecting larger doses of hemoglobin (2.5 to 41.0 gm.) over periods of 1 to 5 days. In the present study we were able to demonstrate casts in the tubules consistently, after injections of relatively small quantities of hemoglobin (1 to 1.9 gm./kg.) if the previous intake of water had been restricted.

It is difficult to maintain rigid control of all the variables in an experiment of this type. Following the withholding of water some rabbits stopped eating immediately, whereas others continued to eat for 2 to 3 days. After identical periods of dehydration, quantitative differences were observed in weight loss, the volume of urine excreted, and in responses to intravenous injections of hemoglobin. Intravenous hemoglobin injections were without any apparent immediate effect in most rabbits; but some became extremely weak and a few

died following injections. It seems doubtful that the toxic manifestations exhibited by these animals were due to potassium salts; however, such a possibility has not been excluded.

As far as we have been able to determine, consistent reproduction of hemoglobinuric nephrosis has not heretofore been accomplished without a preliminary direct trauma to the kidneys. It is now apparent that such a lesion can be produced consistently in rabbits when dehydration precedes the intravenous injections of hemoglobin. Whether dehydration exerts a direct influence on the precipitation of pigment casts or acts indirectly through altered physiologic responses, remains to be determined. In view of the present findings it is felt that similar studies should be made in other species. Whether the relationship of dehydration and hemoglobinemia to the production of hemoglobinuric nephrosis is peculiar to the rabbit or exists in other species, particularly man, is a problem of large importance.

SUMMARY

1. Dehydration, if sufficiently prolonged, favors the accumulation of hemoglobin or its derivatives in the kidneys of rabbits, principally casts formed in the distal convoluted tubules.
2. Once pigment casts have been produced in the distal convoluted tubules, there is obstruction, with atrophy and dilatation of the tubules proximal to the obstruction.
3. When the involvement is sufficiently extensive, there is elevation of the non-protein nitrogen and some animals die because of renal failure.

BIBLIOGRAPHY

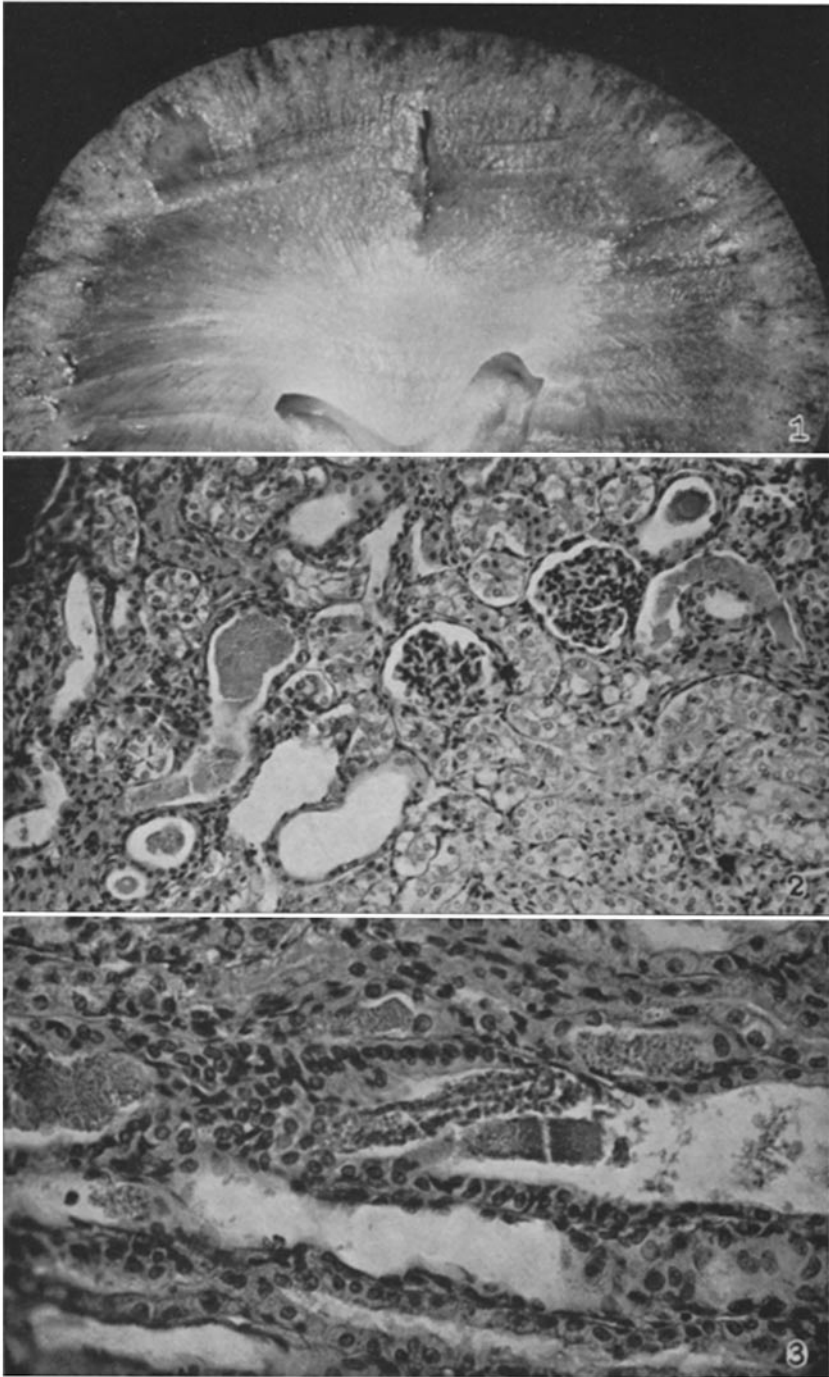
1. Lucké, B., *Mil. Surg.*, 1946, **99**, 371.
2. Yorke, W., and Nauss, R. W., *Ann. Trop. Med. and Parasitol.*, 1911, **5**, 287.
3. Baker, S. L., and Dodds, E. C., *Brit. J. Exp. Path.*, 1925, **6**, 247.
4. DeGowin, E. L., Warner, E. D., and Randall, W. L., *Arch. Int. Med.*, 1938, **61**, 609.
5. DeNavasquez, S., *J. Path. and Bact.*, 1940, **51**, 413.
6. Bing, R. J., *Bull. Johns Hopkins Hosp.*, 1944, **74**, 161.
7. Hueper, W. C., *J. Lab. and Clin. Med.*, 1944, **29**, 628.
8. Yuile, C. L., Gold, M. A., and Hinds, E. G., *J. Exp. Med.*, 1945, **82**, 361.
9. Brown, W. H., Pearce, L., and Van Allen, C. M., *J. Exp. Med.*, 1926, **43**, 241.

EXPLANATION OF PLATE 17

FIG. 1. Hemisection of kidney, rabbit 12. Water was withheld for 5 days and then the rabbit was given 1.8 gm./kg. of hemoglobin in seven doses during the last 3 days. It died in uremia 14 days after the initial injection. Large collections of dark brown pigment are present, localized principally in the cortex, and minimal quantities can be seen in the medulla. $\times 3$.

FIG. 2. Kidney, rabbit 12. There are pigment casts in the distal convoluted tubules and in Henle's loops. There is an associated tubular dilatation with flattening of epithelial cells. Hematoxylin and eosin stain. $\times 150$.

FIG. 3. Kidney, rabbit 12. The granularity of the pigment casts is a typical feature. There are, in addition, dislodged epithelial cells filling one of the tubules. Hematoxylin and eosin stain. $\times 250$.



(Lalich: Homologous hemoglobin injections and kidneys)