

AN ELECTRON MICROSCOPE STUDY OF THE GLOMERULUS IN  
NEPHROSIS, GLOMERULONEPHRITIS, AND LUPUS  
ERYTHEMATOSUS

By MARILYN G. FARQUHAR,\* Ph.D., ROBERT L. VERNIER,† M.D.,  
AND ROBERT A. GOOD,§ M.D.

*(From the Department of Pathology, University of California School of Medicine, San Francisco, and the Pediatric Research Laboratories of the Variety Club Heart Hospital, University of Minnesota)*

PLATES 82 TO 89

(Received for publication, June 26, 1957)

Recent electron microscopic studies (1, 15-25) have demonstrated the elaborate organization of the filtration apparatus of the normal renal glomerulus. (See references 1 and 2 for a review.) Delineation of normal glomerular components at the electron microscope level has necessarily preceded investigation of pathological lesions of glomeruli. Although there have been several reports on electron microscopic studies of glomerular changes in experimental animals (3-6), no definitive articles dealing with human pathologic material have yet appeared.<sup>1</sup>

As part of an extensive program for the study of renal diseases in children (2, 7-10), we have examined renal biopsy tissues with the electron microscope. It was hoped that changes in glomerular structure might be discerned before they become obvious at the light microscope level. In addition, it was anticipated that electron microscopy might provide new information about the specific sites of injury in renal diseases as reflected by changes in the fine structure of the glomerulus.

This investigation was aided in part by American Cancer Society, Inc., Institutional Grant 43G, and by a grant from the National Heart Institute of the National Institutes of Health, United States Public Health Service (H-1542) to the Department of Pathology, University of California School of Medicine, San Francisco, and also by grants to the Pediatric Research Laboratories of the Variety Club Heart Hospital, University of Minnesota from the National Heart Institute, United States Public Health Service (E-798 and H-2085), Helen Hay Whitney Foundation, American Heart Association, Minnesota Heart Association, and the Hill Foundation, St. Paul, Minnesota.

\* Department of Pathology, University of California Medical Center, San Francisco.

† Post Doctoral Research Fellow, National Heart Institute, USPHS, Department of Pediatrics, University of Minnesota, Minneapolis.

§ American Legion Memorial Heart Research Professor of Pediatrics, University of Minnesota, Minneapolis.

<sup>1</sup> Since the preparation of this manuscript Bergstrand and Bucht (34) have published their observations on glomeruli from a patient with diabetic glomerulosclerosis.

The present report describes our findings in glomeruli from a limited number of children with nephrosis, glomerulonephritis, and disseminated lupus erythematosus. Our observations thus far indicate that, in the early stages of each of these disease processes, distinctive changes occur in the fine components of the glomerulus which serve to distinguish one disease process from another.

TABLE I  
*Renal Biopsy in the Nephrotic Syndrome*

Case	Clinical designation	Age	Duration at biopsy	Pathology
1. B. T.	"Pure" nephrosis	5½ years	2 months	Normal
2. K. W.	" "	10 "	2 "	"
3. L. A.	" "	3 "	4 "	"
4. K. M.	" "	3½ "	1 month	"
5. A. S.	" "	4½ "	4 years	"
6. N. M.	" "	4 months	3 months	"
7. M. B.	" "	5 years	2½ years	"
8. C. R.	" "	3 "	1 month	Minimal proliferative nephritis
9. E. C.	" "	12 "	2 months	" "
			3 "	" "
			11 "	Early chronic glomerulonephritis
10. C. W.	"Mixed" nephrosis-nephritis	8 months	2 months	Chronic glomerulonephritis
11. J. B.	" "	3 years	1½ years	" "
12. K. M.	" "	18 months	18 months	Subacute "
13. R. S.	Chronic glomerulonephritis	10 years	3½ years	Chronic glomerulonephritis
14. T. M.	" "	7½ "	7 "	" "
15. D. S.	" "	9 "	4½ "	" "
16. M. G.	" "	12 "	3 "	" "

#### *Materials and Methods*

Biopsies of the kidney from 26 patients with renal diseases were studied with the electron microscope. Serial biopsies were obtained in selected cases. Extensive clinical and laboratory studies, renal function tests, and light studies of renal biopsy specimens had been carried out on the patients. On the basis of such studies, the patients were assigned the following clinical designations:

*Nephrosis*, 16 patients (9 with "pure" nephrosis; 3 with "mixed" nephrosis-nephritis; and 4 with the nephrotic syndrome in chronic glomerulonephritis). (See Table I.)

*Glomerulonephritis*, 7 patients (2 each in the acute and subacute phases and 3 with chronic manifestations). (See Table II.)

*Disseminated Lupus Erythematosus*, 3 patients. (See Table III.)

Renal tissues were obtained for the most part by needle biopsy according to methods detailed elsewhere (10). In 8 patients with the nephrotic syndrome and 1 patient with chronic glomerulonephritis tissue was obtained by open surgical biopsy (10).

The specimen obtained by biopsy was immediately cut into several segments. Attempts were made to select tissue from different levels of the specimen for both light and electron

TABLE II  
*Renal Biopsy in Glomerulonephritis*

Case	Age	Duration at biopsy	Clinical-laboratory findings					Throat culture	ASO titer	Pathologic diagnosis
			Oliguria	Edema	Hypertension	Hematuria	Albuminuria			
	<i>yrs.</i>									
1. T. C.	6	1 month	+	+	±	+	Decreased	Negative	720	Acute glomerulonephritis
2. D. D.	3	1 "	+	+	+	+	"	"	1275	"
3. T. D.	12	6 months	+	-	+	+	Normal	B-strep-tococcus	50 to 100	Subacute glomerulonephritis
4. S. E.	14	7 "	+	+	-	+	"	negative	50	" "
5. N. M.	13	1 year	+	+	-	+	Anuria	"	166	Chronic glomerulonephritis
6. D. S.	9	3½ years	+	-	-	+	Normal	"	50	" "
7. L. K.	14	1½ "	+	+	+	+	"	B-strep-tococcus	100	" "

TABLE III  
*Renal Biopsy in Disseminated Lupus Erythematosus*

Case	Age	Duration at biopsy	Urinalysis		Blood urea nitrogen	Renal function	Lupus erythematosus cells*	Pathology
			Albu-min	RBC				
	<i>years</i>							
1. T. R.	16	3 yrs.	2+	2+	48	30 per cent	+	Chronic glomerulonephritis
2. C. C.	16	10 mo.	1+	3+	22	Normal	+	Proliferative nephritis
3. R. S.	16	20 "	1+	2+	12	76 per cent	+	Segmental nephritis

\* Characteristic lupus erythematosus cells found in both blood and bone marrow.

microscopy. Accordingly, the cortical and medullary ends of the specimen were noted and every other segment was fixed in formalin. The remaining segments were immersed in buffered osmium tetroxide (11) and prepared for electron microscopy as follows: the tissue was cut into blocks of approximately 1 cu. mm. with a sharp razor blade, the pieces obtained were fixed by immersion in a fresh change of the osmium tetroxide fixative, dehydrated in graded alcohols, infiltrated and embedded in *n*-butyl methacrylate (12), and sectioned on a Servall, Porter-Blum microtome (13) equipped with a pyrex plate glass knife. Detailed techniques

for the preparation of tissues for electron microscopy are presented elsewhere (14). Ultrathin sections were examined in an RCA, EMU-2 electron microscope equipped with a 10 mil. condenser aperture and a 30  $\mu$  objective aperture. Fields were photographed at initial magnifications of 1900 to 5000 and enlarged photographically as desired.

In addition to the tissue sections for electron microscopy, sections of 1 to 2  $\mu$  were prepared as routine, mounted on glass slides, stained with hematoxylin, and examined by light microscopy. These sections greatly facilitated the location of glomeruli. They also made possible the study of the same glomerulus by both light and electron microscopy.

The preservation of the human biopsy material did not appear as uniform under the electron microscope as optimally prepared animal tissue, presumably because of variations in the amount of trauma the tissue suffered during the biopsy procedure. However, when the tissue specimen was obtained immediately upon removal from the patient much of it appeared remarkably good.

## RESULTS

### *Normal Glomerulus:*

It is generally agreed from the electron microscopic studies of a number of workers (1, 15-25) that the glomerular capillary possesses three distinct components: the endothelium, the basement membrane proper, and the epithelium (Fig. 1). Two of these components are cellular (*i.e.*, the endothelium and epithelium) and the third (basement membrane proper) is acellular. Endothelial cells outnumber epithelial cells by approximately three to one.

The endothelium lies closest to the capillary lumen. A moderate amount of cytoplasm surrounds the endothelial nucleus, but away from the nucleus the cytoplasm becomes quite attenuated. This thin layer of endothelial cytoplasm lines the capillary completely except for small characteristic interruptions. The latter have been interpreted as regularly spaced pores by some (16, 21, 22, 25) and as intracytoplasmic vesicles by others (1, 17).

The basement membrane proper lies between the endothelium and epithelium. It consists of a central, relatively homogeneous layer with a moderate electron density. Small areas of little or no electron density generally separate this central layer from the endothelium on one side, and from the epithelium on the other. The width of the central layer varies from approximately 0.6 to 1.0 $\mu$  in young laboratory animals and in children. However, as noted by Bergstrand (25), it is difficult to measure this layer for it has no distinct boundaries, and also, its width may vary in different species. We have noted that, in humans, it becomes somewhat thicker with aging. The areas of low density on either side of the central, homogeneous layer have been interpreted as integral components (layers) of the basement membrane by several workers (22, 23, 25), whereas Pease (21) has suggested that they may represent the site of a "cement substance." Inasmuch as the nature and significance of the pale zones is unknown at present we choose to regard only the central dense layer as the basement membrane proper. Accordingly, in the observations which follow, when we refer to changes in the basement membrane, it will be understood to indicate only the central relatively homogeneous structure.

The epithelium forms the outermost layer of the glomerular capillary. It is composed of rather large cells with abundant cytoplasm which is elaborately organized into a number of branches. Each branch in turn forms numerous secondary branches or "foot processes" which insert on the outer aspect of the basement membrane.

There has been considerable controversy among electron microscopists concerning whether or not an intercapillary layer or the "mesangium" of Zimmerman (26) exists in the normal glomerulus. We can find no evidence for a mesangial layer in either normal or pathologic glomeruli. We concur with the opinion of Hall (16) and Mueller *et al.* (18) who believe that what has been interpreted as mesangium by some actually represents sections through the base of endothelial cells at places where they form intimate attachments to the basement membrane.

#### *Glomerular Structure in Nephrosis:*

A striking abnormality of the glomerular capillary was observed in each of the patients with nephrosis (Figs. 2 to 6). The abnormality consisted of a loss of the characteristic organization of epithelial cytoplasm into foot processes. Instead, broad masses of epithelial cytoplasm were seen to cover partially or completely the surfaces of the capillary loops. Only occasional, irregularly spaced interruptions were evident. The degree of foot process "smearing" varied from patient to patient, from one glomerulus to another from the same patient, and even between loops of individual glomeruli. However, it should be emphasized that some loss of foot process organization was seen in each of the cases of nephrosis regardless of the clinical phase of the disease or its severity as determined by light microscopy. In general, it can be said that an increase in the severity of the lesion was noted with increased severity of the disease seen clinically.

In the normal glomerulus the base of each epithelial foot process characteristically shows a greater density than the rest of the epithelial cytoplasm (See Fig. 1). It is very interesting that in nephrosis (Figs. 3 to 6), even though the foot process organization is defective, that portion of the epithelial cytoplasm which directly adjoins the basement membrane ordinarily retains the greater density characteristically seen at the base of the normal foot process.

Although the distortion of the epithelial foot processes was the most consistent glomerular abnormality encountered in the nephrotic syndrome, additional changes in glomerular structure were also noted. The epithelial cytoplasm contained increased numbers of fluid vacuoles and vesicles. Rather large vacuoles were frequently seen (Fig. 3). The endothelium often appeared swollen (Fig. 3), and sometimes segments of cytoplasm ballooned out into the capillary lumen. At the same time the endothelium contained numerous intracytoplasmic vesicles, and the luminal cell border showed complicated projections (Fig. 4) resembling a meshwork. These findings suggested that the endothelium was much more active than normal in the pinocytosis of fluid as described in other capillary endothelia by Palade (27).

Alterations were also sometimes seen in the structure of the basement membrane proper. Its thickness varied from normal to obviously thicker than normal in glomeruli from different patients. However, in the majority of cases the basement membrane was somewhat thicker than normal, and it appeared to undergo a gradual nodular thickening with progression of the disease (Fig. 5). In several patients the typical homogeneous character of the basement membrane was lacking, and instead a rather "moth-eaten" appearance was noted (Fig. 5).

Certain aspects of the glomerular changes seen in nephrosis seemed to be more consistently associated with the clinical phase of the disease process. In those patients with so called "pure" nephrosis, the only lesion consistently demonstrable was a loss of the

foot process organization. In the majority of cases no proliferative changes were observed in the endothelium or basement membrane proper. Distinct proliferation of endothelium and accumulation of basement membrane-like material were observed in only 1 of the 8 children with pure nephrosis. In this patient (E. C.) the clinical progression of the disease was rapid and the patient was unresponsive to treatment.

All of those patients with a clinically "mixed" picture of nephrosis and nephritis showed, in addition to a distortion of the foot process organization, some proliferation of the endothelium and some basement membrane thickening (Fig. 6). It should also be pointed out that although some distortion of the foot processes was seen in each of the children in the mixed group, the changes were less marked than those seen in the children with pure nephrosis.

The patients with the nephrotic syndrome in chronic glomerulonephritis showed more pronounced proliferation of the endothelium and accumulation of basement membrane-like material as well as some foot process smearing. Thus, although some degree of foot process loss was seen in all patients with the nephrotic syndrome, the proliferative endothelial-basement membrane changes were present only in those cases of the nephrotic syndrome of relatively long duration where the light microscopic pathology was severe.

The most severely damaged glomeruli appeared contracted or "hyalinized" and looked very similar to those seen in typical chronic glomerulonephritis which are described in the section to follow.

#### *Glomerular Structure in Glomerulonephritis:*

The glomeruli from patients with glomerulonephritis showed predominantly proliferative changes of the endothelium and basement membrane proper. Observations on tissues from patients with acute manifestations (Figs. 7 and 8) showed that, in the initial stages of the disease, the glomeruli appeared markedly cellular. The hypercellularity was apparently due primarily to an increase in the number of endothelial cells (*i.e.* endothelial proliferation). Secondly, it was due to a proliferation of epithelial cells and an intraluminal accumulation of mononuclear cells (presumably lymphocytes and monocytes). Only occasional polymorphonuclear neutrophils were seen. However, the biopsy procedure was not carried out until 1 month after the onset of the illness in both patients with acute manifestations. (The only exception was seen in glomeruli from a patient with subacute glomerulonephritis with a superimposed, early acute clinical exacerbation, where large numbers of polymorphonuclear neutrophils filled the capillary lumina.) There was also a generalized swelling of both endothelial and epithelial cytoplasm so that both the capillary lumina and the urinary spaces were greatly narrowed. In spite of the epithelial swelling, the epithelial foot process organization usually appeared normal except in areas of severe damage.

In addition to the endothelial and epithelial proliferation and occurrence of mononuclear cells, there was also an apparent accumulation of material resembling the basement membrane in density and general appearance (Fig. 8). In glomeruli with more marked changes, the original basement membrane appeared thickened and large masses of newly formed basement membrane-like material were seen (Fig. 7). The basement membrane-like material was present in bars or irregularly shaped strands interlaced with endothelial cytoplasm. It was sometimes difficult to determine whether this material was within endothelial cytoplasm or whether it was extracytoplasmic.

The intimate association of the newly formed, basement membrane-like material and endothelial cytoplasm suggests that this material is synthesized as a result of endothelial activity. In some areas the newly formed material appeared identical to normal basement membrane, but sometimes it showed a delicate fibrillar or flocculent appearance (Fig. 7).

In the subacute and chronic stages of glomerulonephritis, increasing numbers of glomeruli were seen to be composed for the most part of tangled masses of endothelial cells and basement membrane-like material, together with a few trapped epithelial and mononuclear cells (Fig. 9). Very few open blood channels were evident, but when present, they were usually located more peripherally in the glomerulus. The most severely damaged glomeruli were shrunken and were composed of a few atrophic cells surrounded by masses of basement membrane-like material of a heterogeneous texture. These are the hyalinized glomeruli seen by light microscopy.

It is quite interesting that even in very severely damaged glomeruli, in those areas where epithelial cells could be identified (usually in the more peripheral areas of the loops), frequently the normal foot process organization remained (Fig. 9). This is in direct contrast to patients with nephrosis in whom the diminution in the number of foot processes seemed to constitute the early and consistent lesion of the disease. Of course, in the late stage of either disease process, when hyalinization resulted, few distinctive features could be noted.

#### *Glomerular Structure in Disseminated Lupus Erythematosus:*

Electron microscopic examination of renal tissue from patients with disseminated lupus revealed the most characteristic lesion to be a generalized increase in the thickness of the basement membrane proper (Fig. 10) associated with a variable degree of endothelial proliferation. In some glomeruli the basement membrane thickening was evident only in the peripheral areas of the loops facing the parietal layer of Bowman's capsule. In more severely damaged glomeruli the process of basement membrane thickening involved the entire glomerulus in a relatively uniform fashion. The degree of basement membrane thickening varied considerably from one glomerulus to another from the same patient. In some glomeruli which appeared normal by light microscopy, the thickening was relatively slight. However, in many instances the basement membrane was 4 to 6 times the normal thickness (Fig. 11). It should be pointed out that this severe degree of basement membrane thickening was seen in the case of lupus erythematosus of longest duration (T. R.).

The amount of endothelial proliferation also varied a great deal from one patient to another and between glomeruli from the same patient. In the presence of pronounced proliferative changes of the endothelium, nodular accumulations of basement membrane material were seen as well as the more generalized basement membrane thickening.

The epithelium did not appear to be altered in the patients who were clinically designated as being in the early stages of the disease. It was only when basement membrane thickening was quite severe that any loss of the foot process organization was evident.

The final result of the process of basement membrane thickening and endothelial proliferation resulted in a picture of glomerular hyalinization not unlike that seen in the final stages of nephrosis and chronic glomerulonephritis.

In one patient with disseminated lupus and one patient with subacute glomerulonephritis, fibrinoid lesions of the glomeruli were seen by light microscopy. When glomeruli from these patients were studied by electron microscopy, the fibrinoid material could be recognized on the basis of its great density and lack of any consistent internal structure (Fig. 12). The "fibrinoid" appeared to accumulate between the basement membrane proper and the endothelium. As the deposition of this material progressed, frequently it was seen replacing entire areas of the basement membrane.

#### COMMENTS

The results of this electron microscopic study of glomeruli from a limited number of patients with renal disease indicate that early in the course of nephrosis, glomerulonephritis, and disseminated lupus erythematosus, distinctive morphologic changes occur which serve to distinguish one disease process from another.

The finding of a uniform lesion in nephrosis is of great significance, for many capable investigators (28) have failed by light microscopy to find evidence of any consistent change in kidneys of children who die early in the course of pure nephrosis. When changes have been described, only a diffuse "thickening of the basement membrane" has been seen (28, 29). It is easy to understand the inability of many light microscopists to demonstrate a uniform lesion in nephrosis, for the finer details of glomerular structure lie below the limits of resolution of the light microscope. As pointed out by Hall (16), the "basement membrane" of the light microscopist probably includes the attenuated endothelial cytoplasm, basement membrane proper, and epithelial foot processes seen by electron microscopy.

In another paper (2) we have reported in detail the glomerular changes seen in the nephrotic syndrome occurring in four siblings. The clinical designations of the children included pure nephrosis, mixed nephrosis-nephritis, and nephrosis in chronic glomerulonephritis. The pathologic diagnoses based on light microscopy ranged from normal kidney to chronic glomerulonephritis. However, in each case the loss of foot process organization characteristic of nephrosis was seen. These previous studies showed that cases of nephrosis occurring within the same family are indistinguishable from the sporadic disease in their clinical manifestations (10) as well as their pathologic manifestations seen by both light microscopy (10) and electron microscopy (2).

Perhaps the most significant finding resulting from our initial studies is the indication that those patients which are designated clinically as manifesting pure nephrosis show chiefly changes in the epithelial organization, whereas those patients with nephritis show primarily proliferative changes of the endothelium and basement membrane proper. Patients with a clinically mixed picture of nephrosis and nephritis showed mixed glomerular changes involving both epithelial and endothelial-basement membrane components. It would appear that massive loss of protein from the kidney is associated with a distortion of the foot processes of the glomerular epithelium, whereas the clinical manifesta-



tions of hypertension and azotemia occur in association with severe basement membrane thickening and endothelial proliferation. It also appears that, in general, the degree of severity of the clinical manifestations in each instance corresponds to the degree of severity of the observed glomerular changes.

As we have suggested, it seems most likely that the epithelium may represent the site of original renal damage in nephrosis. However, it must be considered possible that the epithelial alterations are secondary to a primary basement membrane injury. If the basement membrane were damaged, allowing leakage of protein and salts, the epithelial change might be interpreted as representing an attempt by the capillary to repair the holes in its filtration apparatus. Studies designed to determine the primary site of injury in nephrosis are now in progress.

The finding of a generalized basement membrane thickening in disseminated lupus may afford an explanation for the "wire loop" lesion (30-32) seen by light microscopy in the glomeruli of many patients with lupus. It seems to us that the wire loop appearance probably results when the process of basement membrane thickening becomes pronounced enough to be recognizable at the light microscope level. Accordingly, the inability to see wire loop changes by light microscopy in many of the glomeruli from lupus patients (including the three cases of this study) can be explained on the basis that the basement membrane thickening was not severe enough to be visible at the light microscope level.

Detailed reports on the light pathology of the material presented here, together with representative case histories, will be published subsequently. A discussion of the physiologic and pathologic implications of the glomerular changes seen in nephrosis, together with a description of the proximal convoluted tubular changes and certain observations on basement membranes were included in previous studies (2, 33). It is evident from studies up to now that examination of renal biopsy tissue with the electron microscope will be of great value in understanding the pathogenesis of diseases involving the kidney.

#### SUMMARY

Renal biopsies from 16 patients with nephrosis, 7 patients with glomerulonephritis, and 3 patients with disseminated lupus erythematosus were studied with the electron microscope.

The observations presented indicate that early in the course of each of these diseases alterations occur in the fine structure of the glomeruli which serve to distinguish one disease process from another.

In nephrosis, some distortion of the organization of the epithelial foot processes was seen in all patients. These epithelial changes constituted the early, consistent lesion of the disease. There was frequently also a swelling of the endothelium.

In glomerulonephritis, pronounced proliferative changes involving the endo-

thelium and to a lesser extent the epithelium, together with the laying down of a basement membrane-like material, represented the predominate pathologic processes. There was also a swelling of both endothelial and epithelial cytoplasm. The epithelial foot processes generally appeared normal.

In patients with a clinically "mixed" picture of nephrosis and nephritis, the glomerular changes were likewise "mixed," for various combinations of epithelial, endothelial, and basement membrane abnormalities were present.

In disseminated lupus erythematosus, a more or less generalized thickening of the basement membrane proper associated with a variable degree of endothelial proliferation was seen. It is suggested that an accentuation of the process of basement membrane thickening results in the "wire loop" appearance sometimes seen by light microscopy.

Although the earliest alterations in glomerular fine structure were characteristic for each of the disease processes, at later stages the changes were not always distinctive. The resulting scarred or "hyalinized" glomeruli, composed of relatively homogeneous, basement membrane-like material, and a few atrophic cells, appeared quite similar.

Although the functional implications of the structural changes observed remain obscure at this time, it is believed that insight into mechanisms may stem from such observations.

The authors wish to express their appreciation for the technical assistance of Mrs. Karin Taylor and Mr. Robert Brooks in this study.

#### BIBLIOGRAPHY

1. Rinehart, J. F., Fine structure of the renal glomerulus as revealed by electron microscopy, *Arch. Path.*, 1955, **59**, 439.
2. Farquhar, M. G., Vernier, R. L., and Good, R. A., Studies on familial nephrosis. II. Glomerular changes observed with the electron microscope, *Am. J. Path.*, 1957, **33**, 791.
3. Simer, P. H., Electron microscope study of the glomerulus, especially its basement membrane in normal and nephritic mice, *Anat. Rec.*, 1955, **121**, 416.
4. Piel, C. F., Dong, L., Modern, F. W. S., Goodman, J. R., and Moore, R., The glomerulus in experimental renal disease in rats as observed by light and electron microscopy, *J. Exp. Med.*, 1955, **102**, 573.
5. Reid, R. T. W., Electron microscopy of glomeruli in nephrotoxic serum nephritis, *Australian J. Exp. Biol. and Med.*, 1956, **34**, 142.
6. Miller, F., and Bohle, A., Vergleichende licht- und elektronen-mikroskopische Untersuchungen an der Basalmembran der Glomerulumcapillaren der Maus Bei experimentellem Nierenamyloid, *Klin. Woch.*, 1956, **34**, 1204.
7. Vernier, R. L., Farquhar, M. G., Brunson, J. G., and Good, R. A., Studies on familial nephrosis: Evidence for a unitarian concept, *J. Clin. In.*, 1956, **35**, 741.
8. Vernier, R. L., Farquhar, M. G., Brunson, J. G., and Good, R. A., Chronic renal disease in children: The renal lesion by light and electron microscopy, *J. Lab. and Clin. Med.*, 1956, **48**, 951.

9. Vernier, R. L., Farquhar, M. G., Brunson, J. G., and Good, R. A., Experiences with renal biopsy in the study of chronic renal disease in childhood, *Bull. Univ. Minn. Hosp.*, 1956, **28**, 58.
10. Vernier, R. L., Brunson, J. G., and Good, R. A., Studies on familial nephrosis. I. Clinical and pathologic study of four cases in a single family, *Am. J. Dis. Child.*, 1957, **93**, 469.
11. Palade, G. E., A study of fixation for electron microscopy, *J. Exp. Med.*, 1952, **95**, 285.
12. Newman, S. B., Borysko, E., and Swerdlow, M., Ultra-microtomy by a new method, *J. Research Nat. Bur. Standards*, 1949, **43**, 183.
13. Porter, K. R., and Blum, J., A study in microtomy for electron microscopy, *Anat. Rec.*, 1953, **117**, 685.
14. Farquhar, M. G., Preparation of ultrathin tissue sections for electron microscopy. A review and compilation of procedures, *Lab. Inv.*, 1956, **5**, 317.
15. Rinehart, J. F., Farquhar, M. G., Jung, H. C., and Abul-Haj, S. K., The normal glomerulus and its basic reactions in disease, *Am. J. Path.*, 1953, **29**, 21.
16. Hall, B. V., Studies of normal glomerular structure by electron microscopy, *Proc. Fifth Ann. Conf. Nephrotic Syndrome*, 1953, 1.
17. Reid, R. T. W., Observations on the structure of the renal glomerulus of the mouse revealed by the electron microscope, *Australian J. Exp. Biol. and Med. Sc.*, 1954, **32**, 235.
18. Mueller, C. B., Mason, A. D., Jr., and Stout, D. G., Anatomy of the glomerulus, *Am. J. Med.*, 1955, **18**, 267.
19. Bargmann, W., Knoop, A., and Schiebler, T. H., Histologische, cytochemische und elektronenmikroskopische Untersuchungen am Nephron (mit Berücksichtigung der Mitochondrien), *Z. Zellforsch. u. mik. Anat.*, 1955, **42**, 386.
20. Policard, Al, Collet, A., and Giltaire-Relyte, L., Recherches au microscope électronique sur la structure du glomérule rénal des mammifères, *Arch. anat. micr.*, 1955, **44**, 1.
21. Pease, D. C., Electron microscopy of the vascular bed of the kidney cortex, *Anat. Rec.*, 1955, **121**, 701.
22. Rhodin, J., Electron microscopy of the glomerular capillary wall, *Exp. Cell. Research*, 1955, **8**, 572.
23. Yamada, E., The fine structure of the renal glomerulus of the mouse, *J. Biophysic. and Biochem. Cytol.*, 1955, **1**, 551.
24. Sakaguchi, H., Fine structure of the renal glomerulus, *Keio J. Med.*, 1955, **4**, 103.
25. Bergstrand, A., Electron microscopic investigations of the renal glomeruli, *Lab. Inv.*, 1957, **6**, 191.
26. Zimmerman, K. W., Über den Bau des Glomerulus der Saugerniere, Weitere Mitteilungen, *Z. mikr.-anat. Forsch.*, 1933, **32**, 176.
27. Palade, G. E., Fine structure of blood capillaries, *J. App. Physics*, 1953, **24**, 1424.
28. Bell, E. T., Renal Diseases, Philadelphia, Lee & Febiger, second edition, 1950.
29. Allen, A. C., The clinicopathologic meaning of the nephrotic syndrome, *Am. J. Med.*, 1955, **18**, 277.
30. Klemperer, P., Pollack, A. D., and Baehr, G., Pathology of disseminated lupus erythematosus, *Arch. Path.*, 1941, **32**, 569.

31. Baggenstoss, A. H., Visceral lesions in disseminated lupus erythematosus, *Proc. Staff Meetings Mayo Clinic*, 1952, **27**, 412.
32. Stickney, J. M., and Keith, N. M., Renal involvement in disseminated lupus erythematosus, *Arch. Int. Med.*, 1940, **66**, 643.
33. Farquhar, M. G., Vernier, R. L., and Good, R. A., Application of electron microscopy in pathology: Study of renal biopsy tissues, *Schweiz. Med. Woch.*, 1957, **87**, 501.
34. Bergstrand, A., and Bucht, H., Electron microscopic investigations on the glomerular lesions in diabetes mellitus (diabetic glomerulosclerosis), *Lab. Inv.*, 1957, **6**, 293.

## EXPLANATION OF PLATES

*Abbreviations for Figures*

<p><i>END</i>, endothelium.  <i>BM</i>, basement membrane.  <i>EP</i>, epithelium.  <i>RBC</i>, red blood cell.  <i>CAP</i>, capillary.  <i>PMN</i>, polymorphonuclear neutrophil.</p>	<p><i>fp</i>, foot process.  <i>m</i>, mitochondria.  <i>vac</i>, vacuole,  <i>ves</i>, vesicle.  <i>fib</i>, fibrinoid.</p>
--	--

## PLATE 82

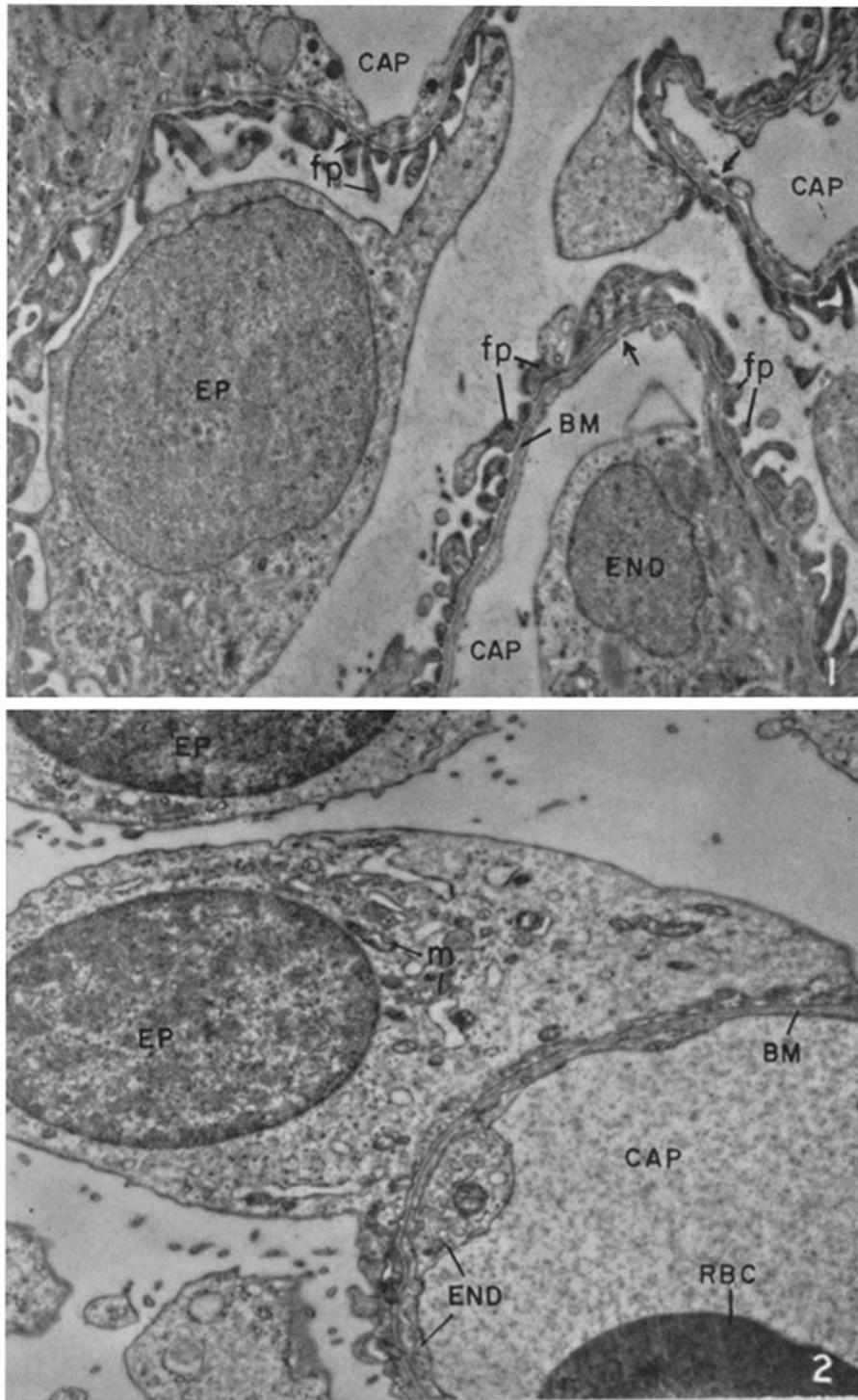
FIG. 1. Segment of a normal glomerulus from a 5 year old child. The three chief glomerular components—the endothelium, basement membrane proper, and epithelium—can be identified. A portion of an endothelial nucleus and its surrounding cytoplasm are shown. Away from the nucleus the cytoplasm becomes quite attenuated and shows characteristic interruptions (arrows).

The basement membrane proper adjoins the endothelium. It consists of a relatively homogeneous layer of intermediate density. A fine clear area separates the basement membrane, and a similar clear area separates the basement membrane and epithelial cytoplasm.

An epithelial cell is present on the left. It shows abundant cytoplasm with several branches. One large branch extends above. Each branch in turn is divided into numerous foot processes which insert on the basement membrane. The area of the foot process which adjoins the basement membrane is denser than the remainder of the epithelial cytoplasm.  $\times 9500$ .

FIG. 2. Segment of a glomerulus from a child with pure nephrosis (N. M.) showing a striking loss of the foot processes. The cytoplasm of the epithelial cell, which occupies the greater part of this field, covers the surface of the capillary loop without interruption. Note that the portion of the epithelial cytoplasm which adjoins the basement membrane retains the greater density normally present at the base of each foot process.

The basement membrane and endothelium appear normal.  $\times 9500$ .



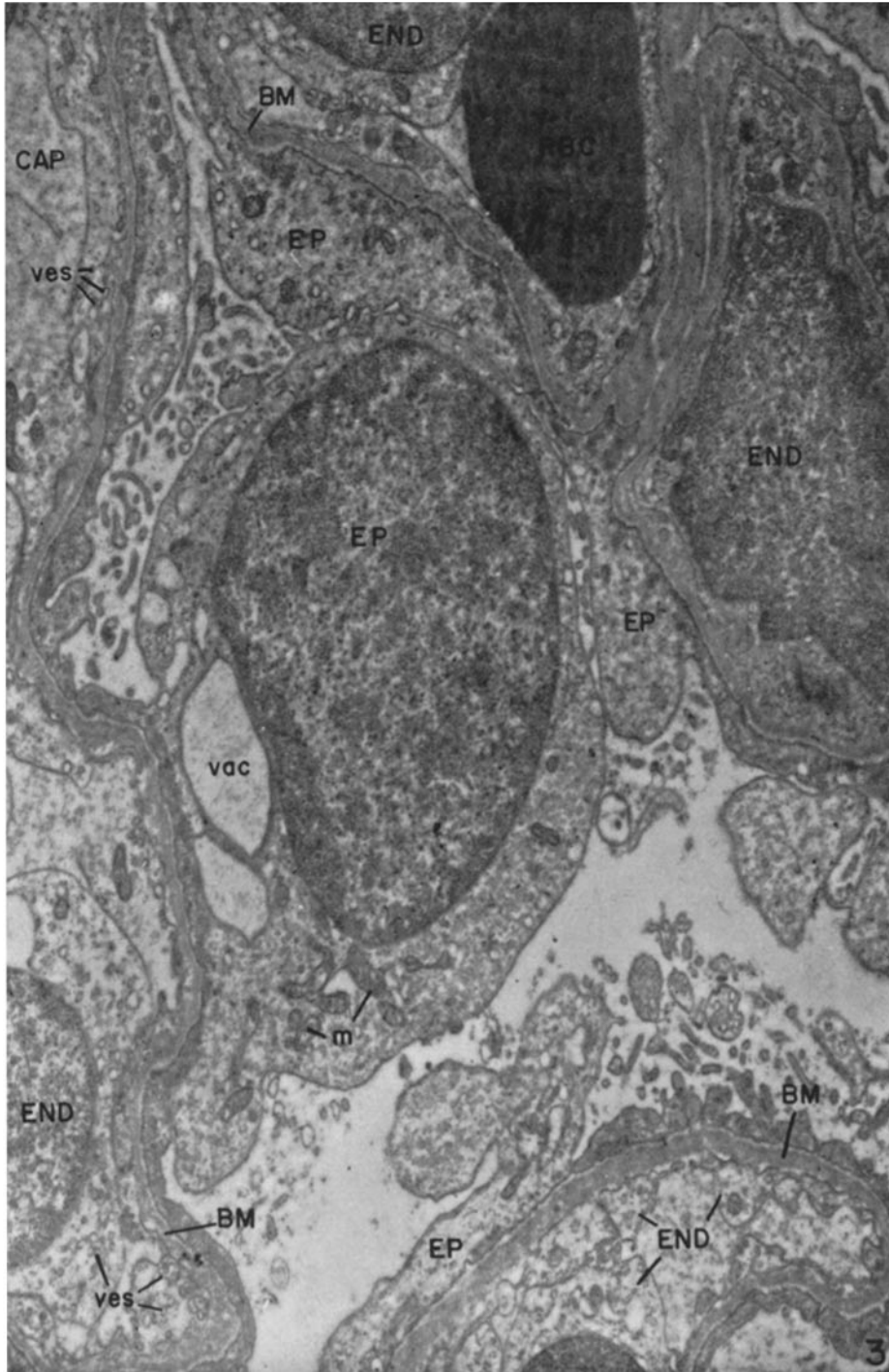
(Farquhar *et al.*: Renal glomerulus)

PLATE 83

FIG. 3. Area showing several loops of a glomerulus from a child with pure nephrosis (B. T.). The foot process organization has been lost, for everywhere epithelial cytoplasm covers the surface of the capillary loops with only occasional interruptions. The area of the epithelial cytoplasm adjoining the basement membrane retains the greater density normally seen at the base of each foot process.

The cytoplasm of the epithelial cell which occupies the center of the field contains several large vacuoles. Endothelial cytoplasm, seen below and to the right, appears swollen and contains numerous small fluid droplets or vesicles.

The basement membrane shows a slight nodular thickening in some areas.  $\times 12,300$ .



(Farquhar *et al.*: Renal glomerulus)

PLATE 84

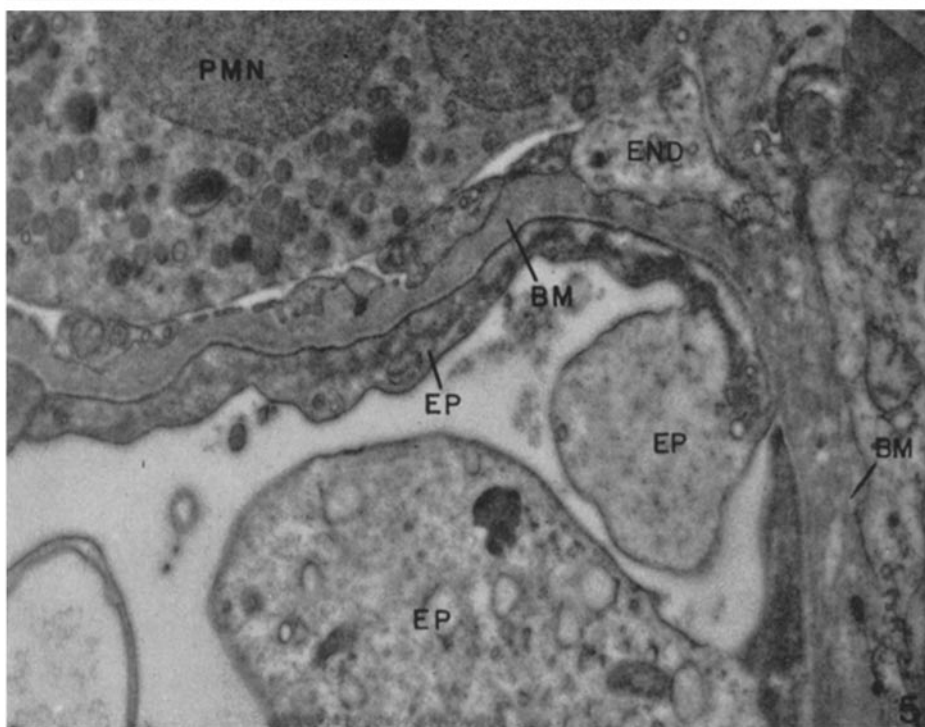
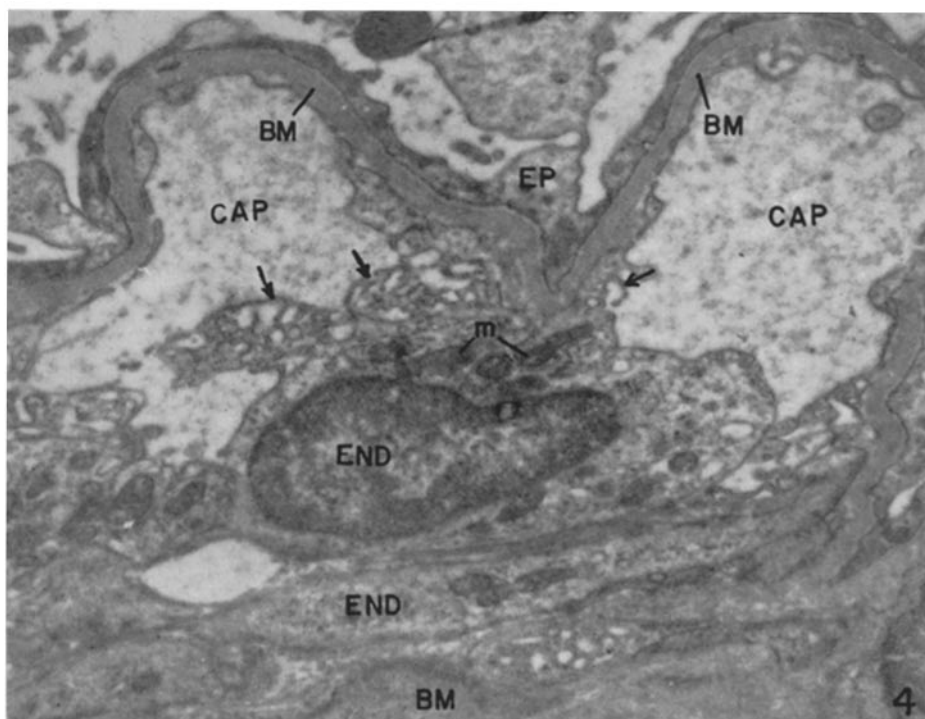
FIG. 4. Portion of a glomerular capillary loop from a child with pure nephrosis (B. T.), showing a great irregularity of the luminal cytoplasmic border of the endothelium (arrows). The luminal cell border shows numerous projections resembling a meshwork. The loss of the epithelial foot process organization can also be seen.  $\times 15,000$ .

FIG. 5. Portion of a glomerular capillary wall from a child with mixed nephrosis and nephritis (K. M.) showing a nodular thickening of the basement membrane. The edge of the basement membrane facing the epithelium appears smooth, whereas the edge facing the endothelium shows irregular projections. In addition, there is no clear area between the endothelium and basement membrane. These appearances suggest that the thickening occurs on the side of the basement membrane which faces the endothelium.

To the right, the basement membrane appears "moth-eaten" for it consists of alternating areas of greater and lesser density. The denser areas show a delicate strand-like appearance.

The lack of epithelial foot processes is again evident.  $\times 18,400$ .



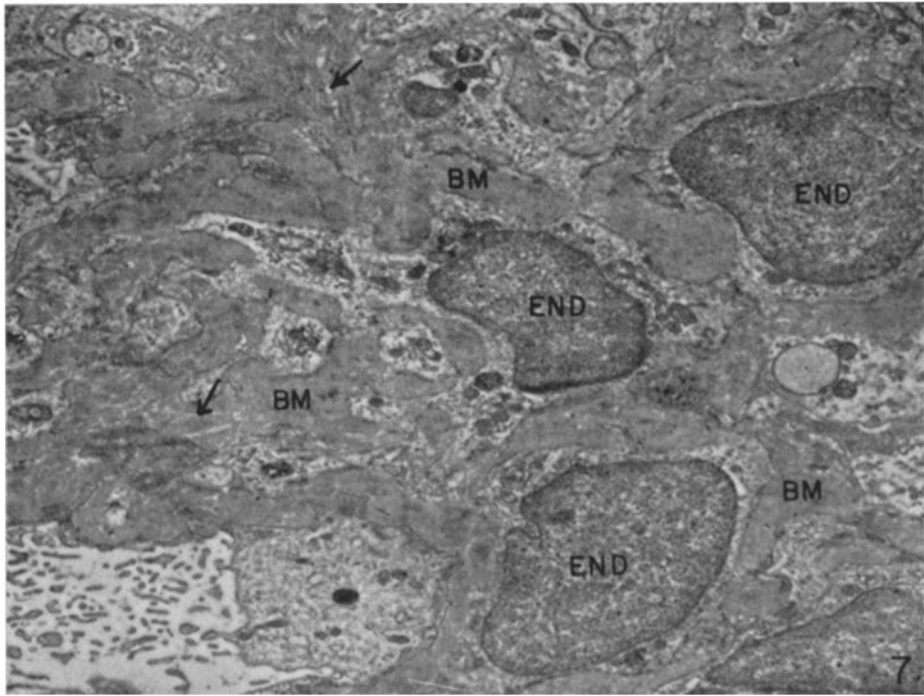
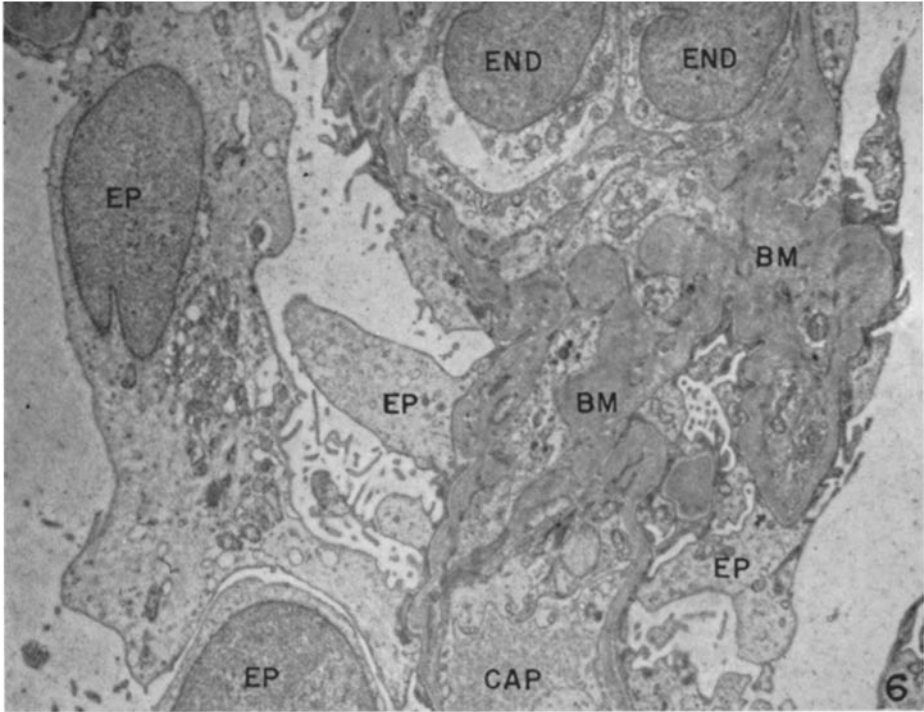


(Farquhar *et al.*: Renal glomerulus)

PLATE 85

FIG. 6. Small field of a glomerulus from a child with mixed nephrosis and nephritis (J. B.), showing both an accumulation of basement membrane-like material and a distortion of the foot process organization. Several endothelial cells are present above. Below the endothelial cells is a large accumulation of material which resembles basement membrane. Foot processes are absent, for the most part, and epithelium cytoplasm covers the surface of the capillary with only occasional interruptions.  $\times 6500$ .

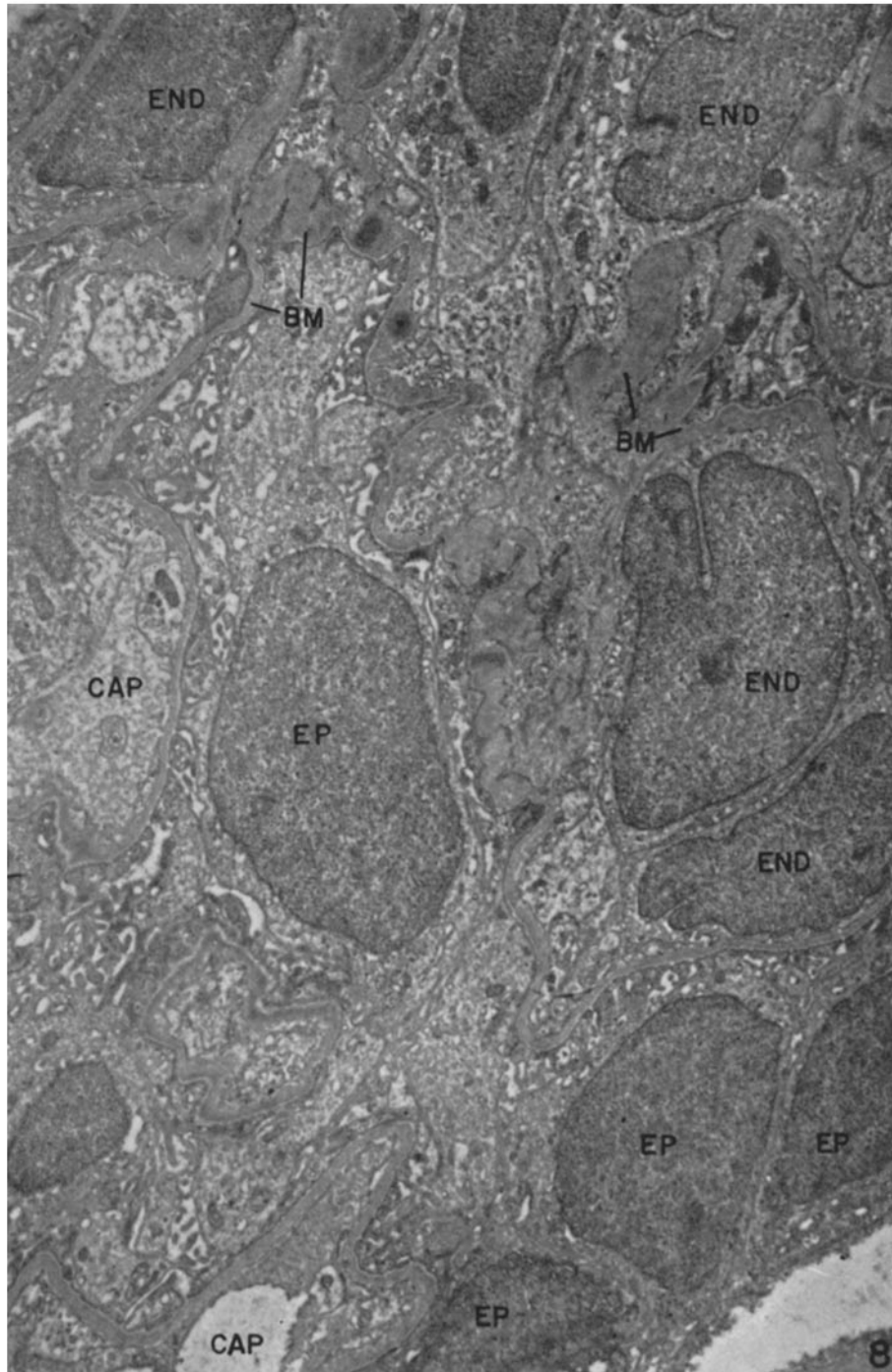
FIG. 7. Small area of a glomerulus from a child with acute glomerulonephritis (T. C.), showing an accumulation of material resembling basement membrane in density. The material is closely associated with the cytoplasm of a number of endothelial cells. In several places (arrows), the basement membrane-like material has a mottled appearance and shows alternating areas of greater and lesser density.  $\times 7200$ .



(Farquhar *et al.*: Renal glomerulus)

PLATE 86

FIG. 8. Portion of a glomerulus from a child with acute glomerulonephritis (D. D.). This glomerulus is very cellular and shows little space. The hypercellularity is due, for the most part, to an increase in the number of endothelial cells. The tight packing and lack of space appear to result not only from proliferative changes but also from a swelling of both endothelial and epithelial cytoplasm which greatly narrows both the capillary lumina and the urinary spaces. In spite of the swelling, the epithelial cells show a normal foot process organization. The basement membrane is slightly thickened.  $\times 7200$ .

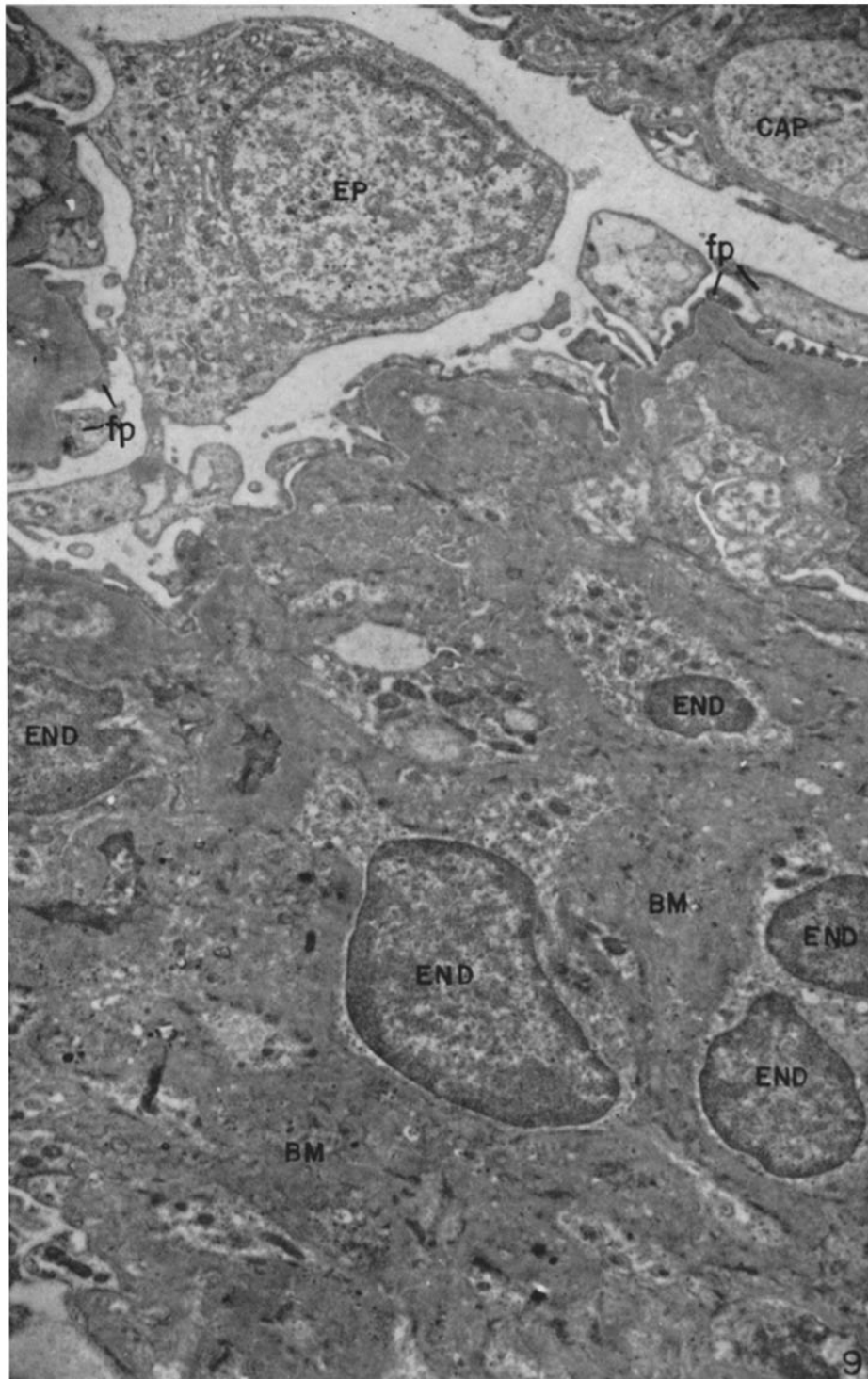


(Farquhar *et al.*: Renal glomerulus)

PLATE 87

FIG. 9. Part of a severely damaged glomerulus from a child with chronic glomerulonephritis (L. K.), showing large amounts of material resembling basement membrane in appearance. This material is freely intermingled with the cytoplasm of a number of endothelial cells. In many areas, the basement membrane-like material shows a heterogeneous, fibrillar, or granular texture in contrast to the usual homogeneity of the basement membrane.

A number of normal foot processes are seen above in contact with more peripheral loops of the glomerulus.  $\times$  8100.



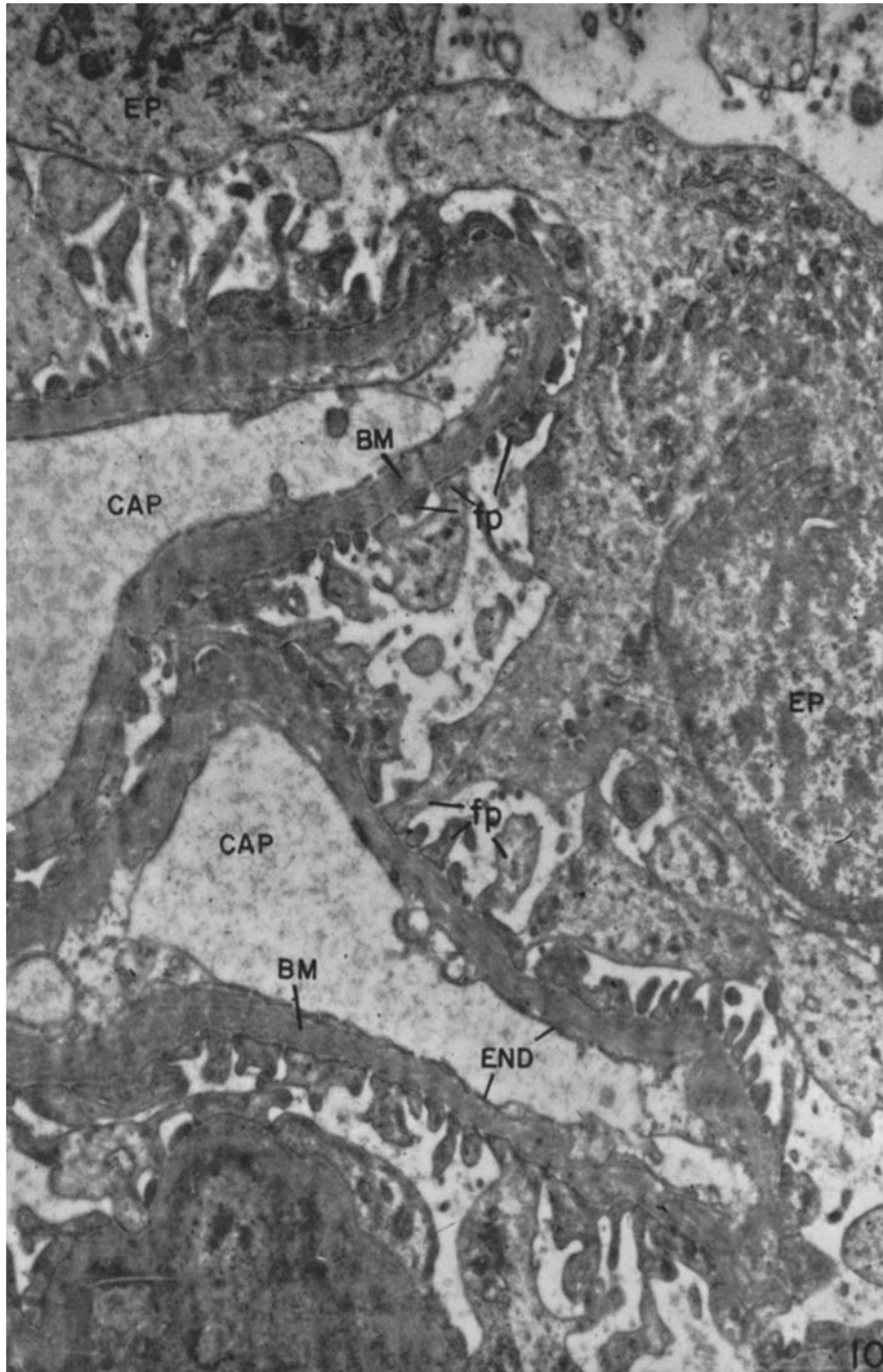
(Farquhar *et al.*: Renal glomerulus)

PLATE 88

FIG. 10. Several loops of a glomerular capillary from a child with disseminated lupus erythematosus (C. C.) showing a more or less generalized thickening of the basement membrane proper. The basement membrane is 3 to 4 times normal thickness. The epithelium and endothelium appear unaltered. Note particularly that the foot process organization is virtually normal.

In many areas of the basement membrane a fibrillar or laminated structure can be distinguished in the original micrograph.  $\times 12,000$ .



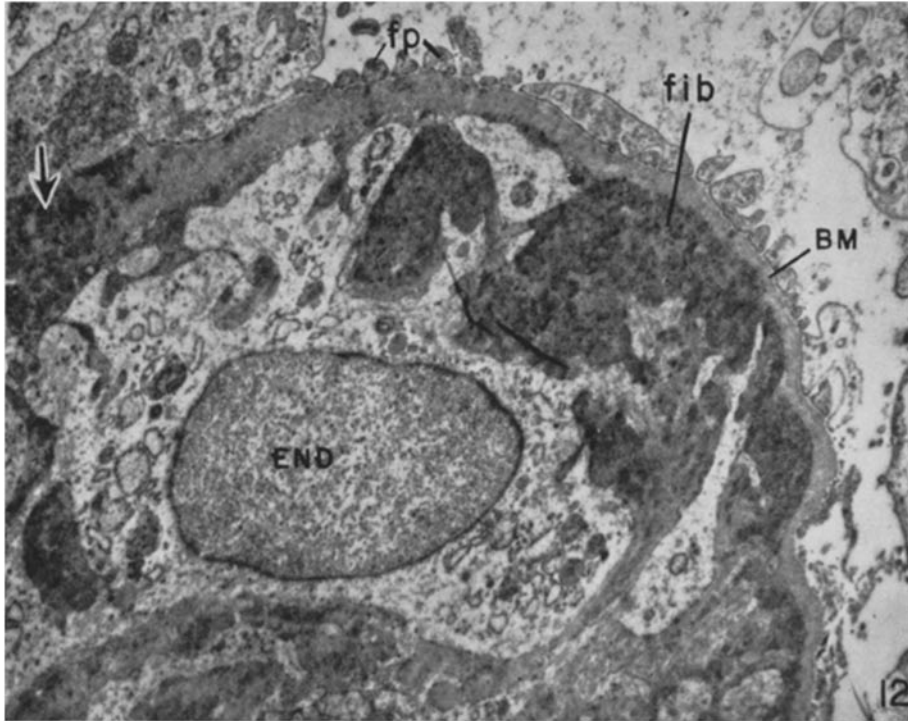
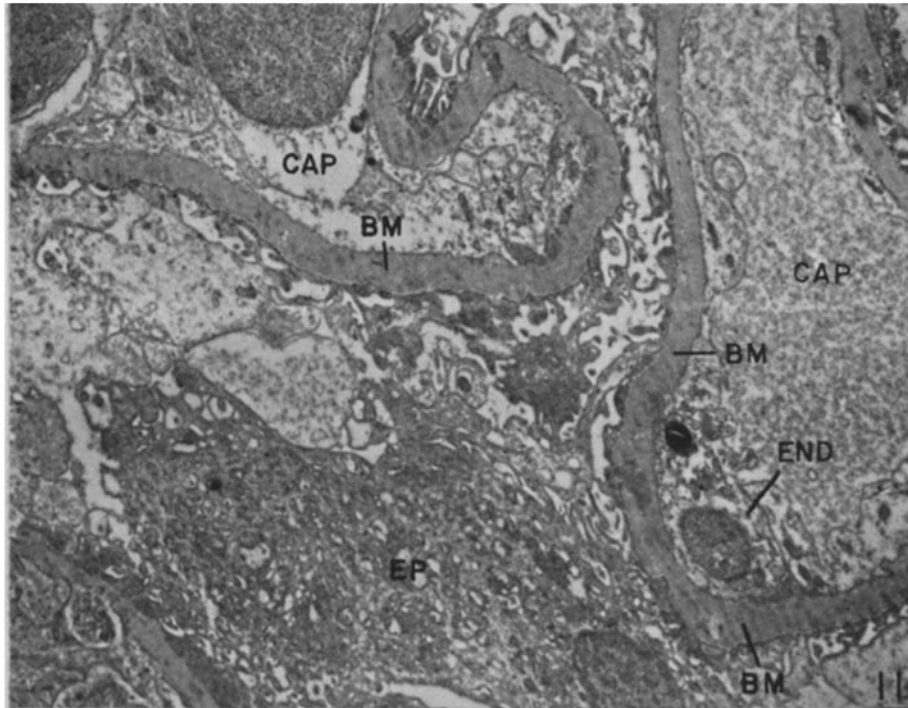


(Farquhar *et al.*: Renal glomerulus)

PLATE 89

FIG. 11. Glomerular loop from a child with disseminated lupus erythematosus (T. R.), showing marked thickening of the basement membrane. Here the basement membrane is as much as 4 to 6 times normal thickness. The foot processes are also somewhat swollen and distorted. It is only with severe damage (*i.e.* thickening of the basement membrane), such as that seen here, that any change in the foot processes is noted.  $\times 6000$ .

FIG. 12. Area from a glomerulus of a child with disseminated lupus erythematosus (C. C.), showing areas of accumulation of "fibrinoid" which can be recognized by virtue of its great density. Fibrinoid can be seen to accumulate first between the endothelial cytoplasm and basement membrane. As its deposition progresses it may entirely replace the basement membrane in some areas (arrow).  $\times 9700$ .



(Farquhar *et al.*: Renal glomerulus)