

IMMUNOHISTOCHEMICAL DEMONSTRATION OF IgG IN REED-STERNBERG AND OTHER CELLS IN HODGKIN'S DISEASE*

By A. J. GARVIN, S. S. SPICER, R. T. PARMLEY, AND A. M. MUNSTER
(From the Departments of Pathology and Surgery, Medical University of South Carolina,
Charleston, South Carolina 29401)

(Received for publication 29 January 1974)

Increased synthesis of IgG in vitro has been demonstrated in spleens from patients with Hodgkin's disease, either with or without invasion of the organ by tumor (1). Interest in this laboratory has centered recently on cytochemical localization of immunoglobulins by means of an immunoglobulin-peroxidase bridge procedure (2) and a satisfactory method has been developed for selectively visualizing immunocytes with this technique.¹ As a means of assessing the basis for increased IgG biosynthesis in spleens of Hodgkin patients, this immunostaining procedure has been applied to localization of IgG-producing cells in specimens with Hodgkin's disease.

Materials and Methods

Preparation of Specimens.—Spleen and lymph node obtained at laparotomy from a previously diagnosed patient with the mixed-cell type of Hodgkin's disease was minced and fixed at 4°C for 30 min in a solution containing 0.5% glutaraldehyde, 5% formalin, and 1% calcium acetate. The tissue was stored overnight in 70% ethanol at 4°C, dehydrated, and embedded in paraffin. In addition, blocks of routinely fixed and embedded lymph nodes and spleen previously diagnosed as containing Hodgkin's tumor were retrieved from the surgical files.

Spleen or lymph node from five patients with surgically diagnosed Hodgkin's disease of the mixed-cell type were also processed for ultrastructural examination. These specimens were fixed in 3% glutaraldehyde for 2 h, postfixed 1 h in 2% osmium tetroxide, dehydrated, and embedded in Epon (Shell Chemical Co., New York). Thin sections were stained with a uranyl acetate-lead citrate sequence and viewed with an Hitachi HS-8 electron microscope (Hitachi Ltd., Tokyo, Japan).

Staining Methods.—To localize immunoglobulins, sections were stained with a modified immunoglobulin-peroxidase bridge method (2) employing rabbit antihuman IgG or IgM (Cappel Laboratories, West Chester, Pa.) as the first step in the bridge. Modification of the original method included: blockage of erythrocyte peroxidase activity by a 2–5 min incubation in 3% hydrogen peroxide before the application of the primary antiserum and dilution of the primary antiserum 1:10 and the succeeding antisera 1:5. The control procedure entailed sub-

* This research was supported by NIH grants AM-10956 and AM-11028, and South Carolina State Appropriation 22700-A401, 73-74.

¹ Garvin, A. J., S. S. Spicer, D. S. Hintz, and A. M. Munster. 1974. Selective immunostaining of IgG-containing cells by light microscopy. Manuscript submitted for publication.

stitution of serum from a nonimmunized rabbit for the antihuman IgG as the first step in the bridge sequence.

Serial sections were stained in order with: hematoxylin and eosin for morphologic identification of cell types, the immunohistologic method for localizing immunocytes, and a modified² Schiff-methylene blue sequence (3) for histochemical differentiation of deoxyribonucleic acid (DNA) from ribonucleic acid (RNA). Simultaneous examination in a comparison microscope of serial sections stained by the immunocytochemical and one of the reference procedures facilitated identification of cell types with immunoreactivity.

RESULTS

Light Microscopy.—Hematoxylin- and eosin-stained sections of lymph node and spleen of the surgical specimen fixed lightly for immunostaining and of the blocks retrieved from the surgical files disclosed nodular or diffuse obliteration of normal architecture by a mixed cellular type of infiltration consisting of large Hodgkin and Reed-Sternberg cells, epithelioid cells, reticular cells, lymphocytes, plasma cells, and eosinophils. The Hodgkin cells exhibited a large, rounded profile and contained abundant basophilic cytoplasm and a vesicular nucleus with a prominent nucleolus. Large, binucleate or multinucleate cells identified as Reed-Sternberg cells disclosed prominent nucleoli with a surrounding clear nuclear space that gave them a classical "owl's eye" appearance.

The Schiff-methylene blue sequence stained the cytoplasm and nucleoli of the Reed-Sternberg cells, Hodgkin cells, and numerous plasma cells a deep blue and thus demonstrated the abundant RNA in these cells. This basophilic staining contrasted with the magenta coloration demonstrative of DNA in the nuclei.

Immunostaining for IgG selectively visualized numerous small cells with strong reactivity in the lymph node and spleen processed with light fixation for immunohistochemistry (Figs. 1 and 2). These cells clustered in a rim which partially to completely surrounded the follicles and in the spleen formed a cuff around the penicillar arteries. In addition, the apparently reactive germinal centers of small follicles exhibited a few large cells with light to heavy immunostaining; large follicles or areas occupied by the neoplastic process contained numerous, dispersed, large cells with similar reactivity (Figs. 2, 3, 5, and 7). These large immunoreactive cells, viewed in serial hematoxylin and eosin or Schiff-methylene blue-stained sections in the comparison microscope, were interpreted as Hodgkin cells (Fig. 6). Binucleate or multinucleate cells identified in serial sections as Reed-Sternberg cells also stained intensely in these areas (cf. Figs. 3, 4, 6, and 7). The routinely fixed and embedded surgical specimens all disclosed similar normal and neoplastic cells with selective immunoreactivity. However, these sections varied widely in the abundance of such cells and the intensity of their staining, possibly in relation to the extent of fixation. One specimen processed 2 yr before immunostaining showed numerous intensely reactive immunocytes and tumor cells.

² This modification, entailing Feulgen hydrolysis of routine paraffin sections with Bouin's solution and staining with Schiff reagent and methylene blue, will be described elsewhere.

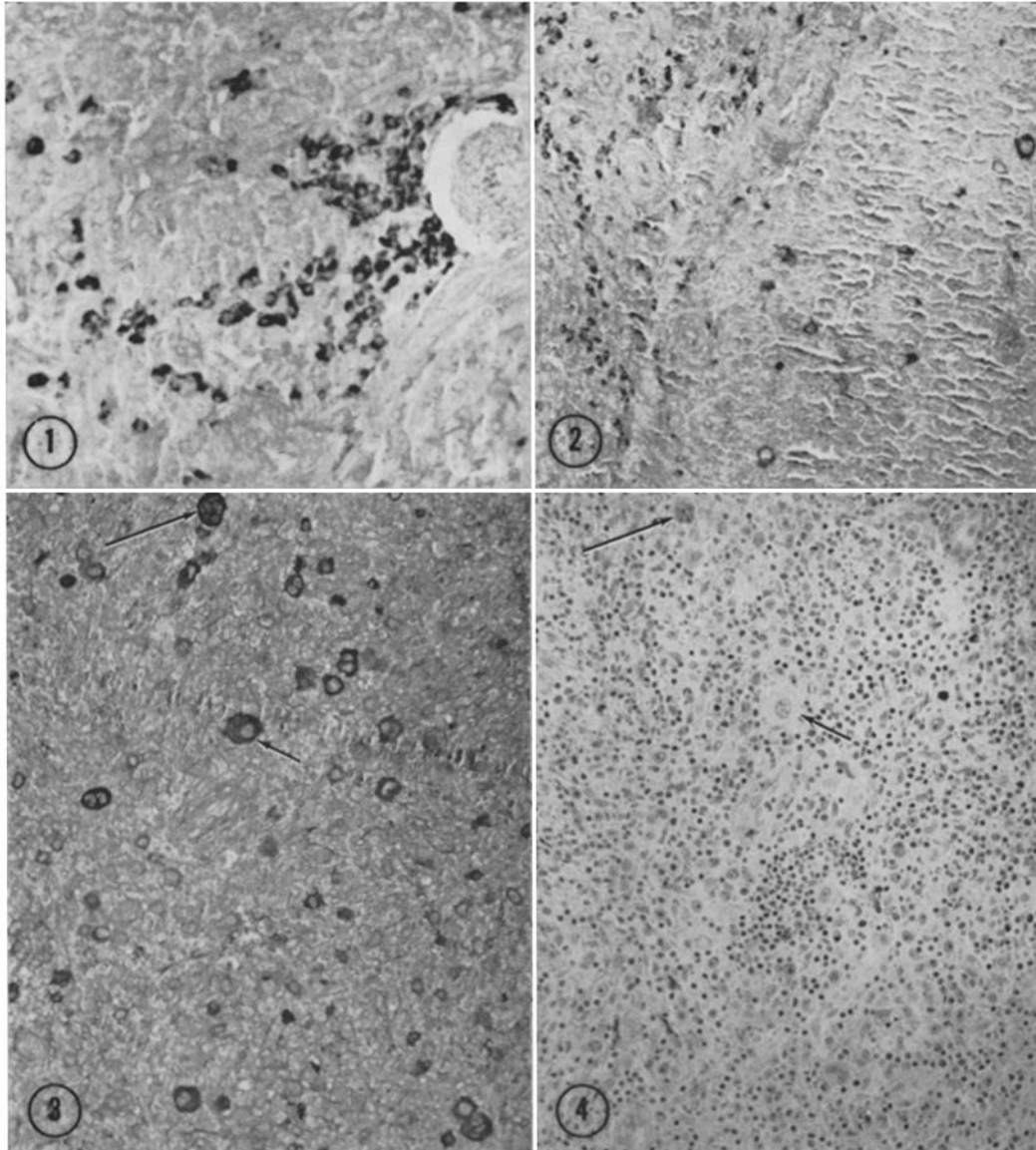


FIG. 1. Numerous immunocytes bordering a penicillar artery stain selectively in this tumor-free area from a surgically processed spleen of a patient with Hodgkin's disease. Routine formalin fixation. Immunostained for IgG. $\times 250$.

FIG. 2. An area from a second spleen processed routinely for pathologic diagnosis reveals a margin between neoplasm at the right and adjacent stroma with numerous stained immunocytes. Scattered large immunoreactive cells populate the tumor area. Immunostained for IgG. $\times 150$.

FIG. 3. An area involved with Hodgkin's disease in a lymph node exhibits moderate to strong staining in: small immunocytes, larger Hodgkin cells (short arrow), and multinucleate Reed-Sternberg cells (long arrow). Light fixation for immunocytochemistry. Immunostaining for IgG. $\times 160$.

FIG. 4. A serial section discloses the immunoreactive Hodgkin (short arrow) and Reed-Sternberg (long arrow) cells of Fig. 3 in lymph node replaced by neoplasm. Hematoxylin and eosin. $\times 160$.

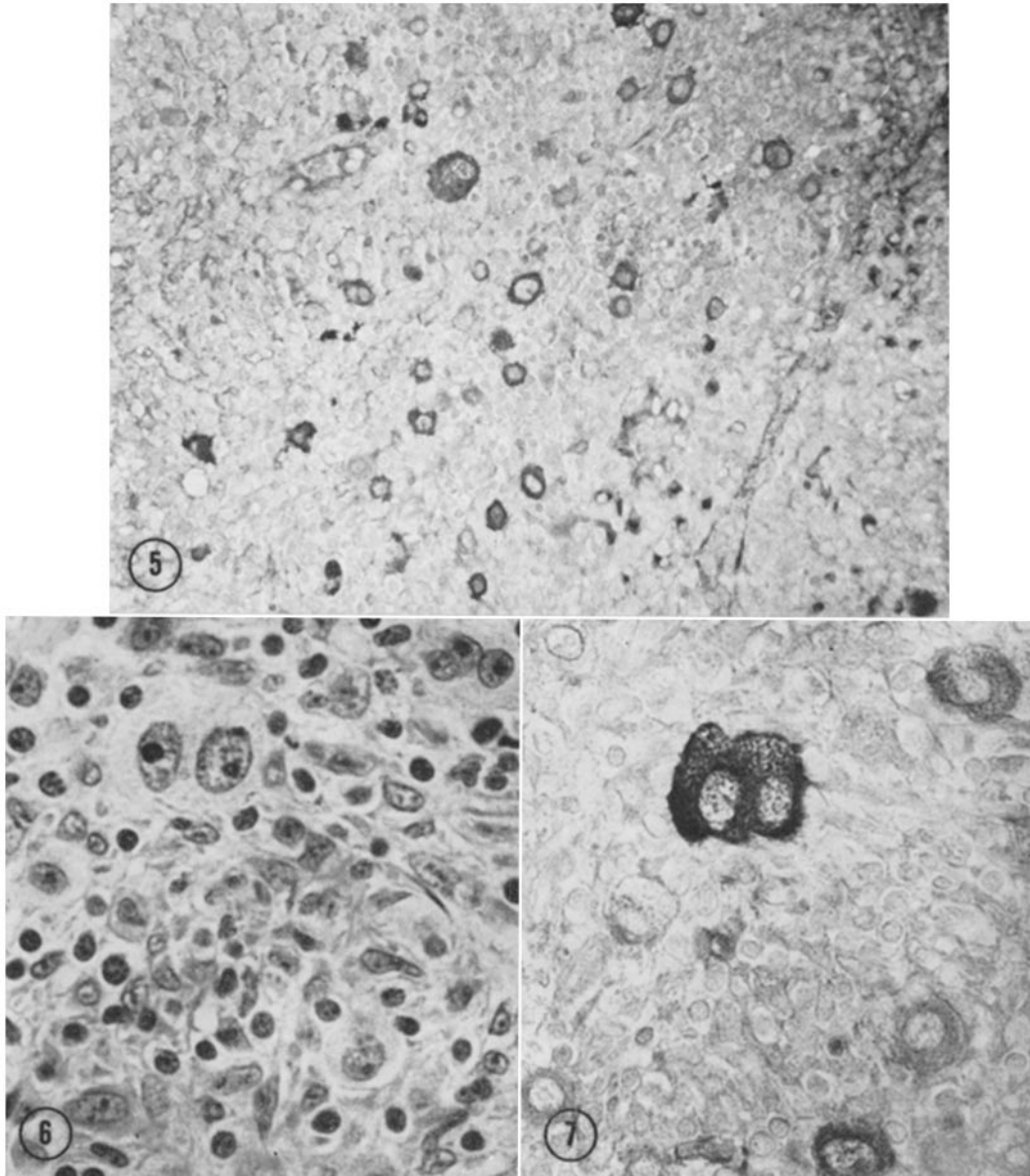


FIG. 5. Another neoplastic area from the spleen illustrated in Fig. 2 reveals immunocytes and Hodgkin cells with moderate to strong immunostaining for IgG. $\times 500$.

FIG. 6. A serial section to that illustrated in the next figure shows the morphology of the immunostained cells. Hematoxylin and eosin. $\times 620$.

FIG. 7. This area from the same section as that illustrated in Fig. 3 reveals intense immunostaining for IgG in a binucleate Reed-Sternberg cell and variable immunoreactivity in neighboring cells. $\times 600$.

Immunostaining for IgM yielded light reactivity in relatively sparse immunocytes, presumably plasma cells, but no staining of Hodgkin or Reed-Sternberg cells. Control sections stained with normal rabbit serum as the first step of the immunoglobulin bridge showed only the intrinsic peroxidase activity of cytoplasmic granules of eosinophils.

Electron Microscopy.—The cell types seen by light microscopy in the Hodgkin lesions were also identified ultrastructurally. Hodgkin (Fig. 8) and Reed-Sternberg cells measured up to 50 μm in diameter and contained one or two vesicular nuclei with dispersed chromatin and one or more large bizarre central nucleoli that often were 5–8 μm in diameter. The cytoplasm of these cells consistently contained abundant closely packed free polyribosomes (Figs. 8–10) and sparse cisternae of rough endoplasmic reticulum which were characteristically long, curved, and collapsed (Figs. 9 and 10). The large epithelioid cells had cytoplasm with abundant rough endoplasmic reticulum and numerous granules. Irregular cells, often associated with reticular fibers and considered reticulum cells, also revealed abundant rough endoplasmic reticulum. Lymphocytes, lymphoblasts, and plasma cells displayed their usual morphologic features. In eosinophils, the crystalloid granules were often decreased in number and altered in structure and the small granules were increased in number as described previously.³

DISCUSSION

Although the histochemical staining for immunocytes has not been quantified, and it has not been possible as yet to define normal limits, the abundance of immunocytes demonstrated in spleen and lymph nodes of Hodgkin patients appears consistent with the increased synthesis of IgG found biochemically in such specimens (2). Additionally, the immunostaining clearly demonstrates abundant IgG in cells with the characteristics of Hodgkin or Reed-Sternberg cells. Evidence obtained by staining of cell suspensions with fluorescein-labeled antibody has recently been presented for the presence of IgG in and on Reed-Sternberg cells and on the surface of lymphoid cells of Hodgkin specimens (4). The present findings document the IgG content of Reed-Sternberg cells by illustrating the immunostaining of these cells identified in reference-stained serial sections and by showing them in relation to neoplastic areas in the tissues. The immunostaining of similarly identified Hodgkin cells in the same areas suggests that these two cell types have a common derivation and that Reed-Sternberg cells may develop from Hodgkin cells as an end stage. Their content of IgG supports a lymphoid origin, presumably of the B-cell variety, for these cells as has previously been suggested on the basis of light microscopic morphological observations (5).

³ Parmley, R. T., and S. S. Spicer, 1974. Cytochemical and ultrastructural identification of a small type granule in human late eosinophils. *Lab. Invest.* In press.

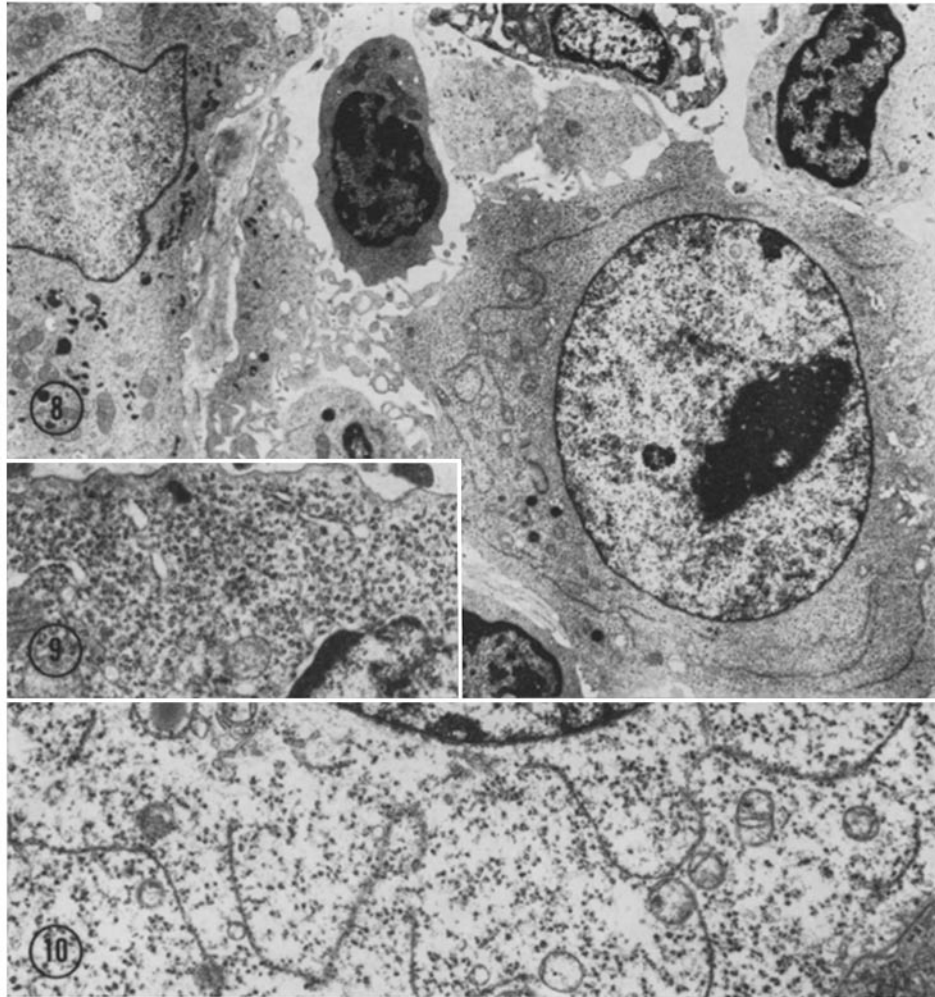


FIG. 8. A Hodgkin cell (lower right) in a lymph node in which immunocytes and tumor cells stained strongly for IgG contains abundant polysomes and long, curved, collapsed profiles of endoplasmic reticulum. An epithelioid cell discloses numerous pleomorphic granules in the cytoplasm. $\times 4,000$.

FIG. 9. A cytoplasmic area in a lymph node Hodgkin cell from another patient consists typically of free polysomes with a few small profiles of endoplasmic reticulum. The free polysomes apparently produce the gamma globulin demonstrated by immunostaining in this patient's tumor cells. $\times 17,000$.

FIG. 10. An area in a Reed-Sternberg cell from the lymph node also shown in Figs. 3, 4, 6, and 7 displays numerous ribosomes and sparse cisternae of granular reticulum with a characteristically long, curved, and collapsed profile. $\times 7,000$.

Staining with the Schiff-methylene blue method demonstrated a high concentration of cytoplasmic RNA in Hodgkin and Reed-Sternberg cells. Electron microscopic examination verified this and showed a striking abundance of free ribosomes and a surprising sparsity of granular reticulum in these cells. For these cells to contain the abundant IgG demonstrated throughout the cytoplasm by immunostaining, the immunoglobulins must have been synthesized by unbound ribosomes. The IgG apparently accumulates and remains in the cytoplasm of these cells because of a paucity of the endoplasmic reticulum presumably required in synthesis of immunoglobulin for export. The IgG in these cells might be expected to lack sugar residues normally present in immunoglobulin, since glycosyl transferases that add the sugars are, as a rule, membrane bound. In this case, the antigenic character of the IgG is not entirely determined by the sugar residues.

The immunostaining technique highlights the Hodgkin cells and could be of diagnostic value in the differentiation from benign hyperplasia and from other neoplasms. The possible presence of IgG in Reed-Sternberg cells arising in other conditions requires further study.

SUMMARY

Spleens and lymph nodes fixed lightly for optimal immunocytochemistry or processed routinely for surgical diagnosis disclosed strong selective immunostaining for IgG in numerous immunocytes in tumor-free areas. Areas involved by Hodgkin's disease revealed, in addition, strong immunostaining for IgG but not IgM in Reed-Sternberg cells and faint to strong staining in Hodgkin cells as well. Ultrastructurally the Reed-Sternberg and Hodgkin cells displayed abundant polyribosomes and sparse granular reticulum and appeared to form unexportable IgG on unbound ribosomes.

The authors are grateful to Ms. D. S. Hintz and B. J. Hall for their skilled technical assistance and to Mr. J. H. Nicholson for his skilled photographic assistance.

REFERENCES

1. Longmire, R. L., R. McMillan, R. Yelenosky, S. Armstrong, J. E. Lang, and C. G. Craddock. 1973. *In vitro* splenic IgG synthesis in Hodgkin's disease. *N. Engl. J. Med.* **289**:763.
2. Mason, T. E., R. F. Phifer, S. S. Spicer, R. A. Swallow, and R. B. Dreskin. 1969. An immunoglobulin-enzyme bridge method for localizing tissue antigens. *J. Histochem. Cytochem.* **17**:563.
3. Spicer, S. S. 1961. Differentiation of nucleic acids by staining at controlled pH and by a Schiff-methylene blue sequence. *Stain Technol.* **36**:337.
4. Leech, J. 1973. Immunoglobulin-positive Reed-Sternberg cells in Hodgkin's disease. *Lancet.* **1**:265.
5. Tindle, B. H., J. W. Parker, and R. J. Lukes. 1972. "Reed-Sternberg Cells" in infectious mononucleosis? *Am. J. Clin. Pathol.* **58**:607.