

## DISCUSSION

This small study fails to give support to the suggestion that menopausal women might have a peculiar hepatic sensitivity to mestranol or Enavid. Since both of the previous reports of uniform liver impairment (see introduction) originated in a single city (Helsinki), it is possible that differences in climate, nutrition, or endemic hepatitis virus explain our failure to confirm their findings.

None of the patients reported herein gave clinical evidence of hepatic impairment, and the minority who had marginal abnormalities on test probably would not exceed the expected incidence in a control group of the same age. It was not thought necessary to discontinue treatment in any case because of these test results. About one-third of the menopausal women in this series had a subjective preference for the oestrogen-progestin combined therapy (Enavid) rather than the placebo or mestranol alone. There seems to be no reason why they should not remain on this treatment indefinitely.

Another source of information about the possible hepatotoxicity of oral oestrogen-progestin therapy in older women is its experimental use in the treatment of rheumatoid arthritis. These studies differ significantly in that the patients already had a serious illness and the dose was often much larger than that used for contraception or to replace ovarian deficiency.

Waine *et al.* (1963), in nine patients treated with 15 to 50 mg. of Enavid daily for 8 to 300 days, found "no major changes in serum bilirubin, prothrombin time, alkaline phosphatase, thymol turbidity, bromsulphalein retention, cephalin flocculation, or the S.G.O.T." Similarly, in 17 patients, Gilbert *et al.* (1964), using 40 mg. of Enavid daily, report no significant changes in the S.G.O.T. Although ages were not reported, personal communication revealed that many were in the menopausal age range.

It is concluded that there is not enough evidence to implicate mestranol either alone or in combination with an oral progestin, such as Enavid, as a cause of impaired liver function either in younger women using it for contraception or in menopausal women.

JOHN L. BAKKE, M.D., F.A.C.P.

Pacific Northwest Research Foundation, Seattle, Washington.

## REFERENCES

- Eisalo, A., Järvinen, P., and Luukkainen, T. (1964). *Brit. med. J.*, **2**, 426.  
 Gilbert, M., Rotstein, J., Cunningham, C., Estrin, I., Davidson, A., and Pincus, G. (1964). *J. Amer. med. Ass.*, **190**, 235.  
 Linthorst, G. (1964). *Brit. med. J.*, **2**, 920.  
 Palva, I. P., and Mustala, O. O. (1964). *Ibid.*, **2**, 688.  
 Rice-Wray, E. (1964). *Ibid.*, **2**, 1011.  
 Swaab, L. I. (1964). *Ibid.*, **2**, 755.  
 Waine, H., Frieden, E. H., Caplan, H. I., and Cole, T. (1963). *Arthr. and Rheum.*, **6**, 796.

**Medical Memoranda****Case of Thyrotoxicosis Presenting as Hypoproteinaemic Oedema**

*Brit. med. J.*, 1965, **1**, 632-633

The manifestations of hyperthyroidism are protean, but there are few reports of oedema, unrelated to heart failure, as a presenting feature. Ivy (1963) reports the case of a woman of 50 that is essentially the same as the one reported below, and Chapman and Maloof (1956) record the case of a woman of 50 presenting with unexplained oedema, but she had normal serum proteins; both these patients recovered completely on correction of their hyperthyroidism.

## CASE REPORT

An artificial-limb fitter aged 48 presented as an out-patient at St. George's Hospital on 23 November 1962, with a history of swollen eyes, ankles, and face for two weeks and of dyspnoea for one week. The only abnormal signs were a short aortic ejection murmur, which has remained constant throughout, and slight tenderness in the right loin. He had suffered from acute nephritis in 1944 but had had no further urinary symptoms at any time; there was no history of an antecedent streptococcal infection, and the urine on this and many subsequent occasions was completely normal. The other investigations (see Table) supported a diagnosis of "nephrotic syndrome."

He was admitted to Queen Mary's Hospital, Roehampton, on 10 December for further investigation. In the meantime he had an attack of paroxysmal atrial fibrillation treated at home with digitalis. He was found to have a slightly enlarged thyroid and a fine hand tremor, but there were no eye signs of thyrotoxicosis and the loin tenderness had disappeared. He had lost a stone (6.4 kg.) in weight in the previous four weeks. The haemoglobin, blood count, serum electrolytes, liver-function tests, creatinine clearance, E.C.G., chest x-ray picture, barium-meal examination, throat swab,

Wassermann reaction, and antistreptolysin titre were all normal. The serum albumin was greatly lowered, the faecal fats were high (8.8 g./24 hours), and the formiminoglutamic acid (Figlu) test for folic-acid deficiency was positive. Thyrotoxicosis was confirmed by a B.M.R. of 25% above normal, and a four-hour radioiodine of 70% in the neck (normal up to 33%). While he was being investigated he had a further attack of paroxysmal atrial fibrillation, confirmed by E.C.G., which again responded to digitalis.

He was treated with carbimazole, and then a pre-operative course of Lugol's iodine preparatory to subtotal thyroidectomy on 25 February 1963. At this time his serum proteins had returned almost to normal and the Figlu test was negative. The oedema had disappeared. The histology of the thyroid was compatible with thyrotoxicosis treated with carbimazole. Post-operative progress was uneventful. He was reassessed eight months later, when he was completely free of symptoms, and had gained 2 stone (12.7 kg.) in weight. The serum proteins were normal, the faecal fats 5.5 g./24 hours, and the B.M.R. was 24% less than normal. When last seen he remained well, on no treatment, but was developing pretibial myxoedema.

## COMMENT

There seems to be little doubt that the patient's oedema was due to reduced serum albumin, and that this was related to his hyperthyroidism.

It has been shown (Shirer, 1932) that there is often a slightly reduced albumin and raised globulin in cases of thyrotoxicosis. The reduced albumin has been confirmed (Lewis and McCullagh, 1944) and shown to be probably due to increased catabolism greater than the increased anabolism; however, the reductions found were much smaller than in the above case. In artificial thyrotoxicosis in man (Rothschild *et al.*, 1957) this finding was coupled with the demonstration of an increased plasma volume which may well have been a factor in the pathogenesis of the oedema in this case. Nikkilä and Pitkänen (1959) found a reduced amount of cellular enzymes in liver-biopsy specimens from hyperthyroid patients, but all the liver-function tests were normal in the present case.

The cause of the hypoalbuminaemia remains obscure. In view of the abnormalities of absorption that were found it is tempting to suggest that an enteropathy, perhaps of the protein-losing type, was responsible; unfortunately, radioalbumin studies and the polyvidone test were not carried out. It is, however, possible that this case represents only an exaggeration

Results of Investigations on Various Dates

	23/11/62	10/12/62	27/12/62	22/2/63	27/10/63
Serum albumin (g./100 ml.) ..	Low	2.0	3.3	3.6	3.4
Serum $\alpha_1$ -globulin (g./100 ml.) ..		0.3	0.5	0.3	0.3
Serum $\alpha_2$ -globulin (g./100 ml.) ..	Raised	1.0	1.3	0.9	0.9
Serum $\beta$ -globulin (g./100 ml.) ..		0.7	0.8	0.9	0.8
Serum $\gamma$ -globulin (g./100 ml.) ..		0.9	0.9	1.2	1.1
Serum total proteins (g./100 ml.) ..	6.6	4.9	6.8	6.9	6.5
Serum urea (mg./100 ml.) ..	53	44	44		34
Serum cholesterol (mg./100 ml.) ..	200	160			255
E.S.R. (mm./1 hour) ..	43	29			15
Figliu test .. ..			Pos.	Neg.	Neg.

## Hydatid Disease of the Spine

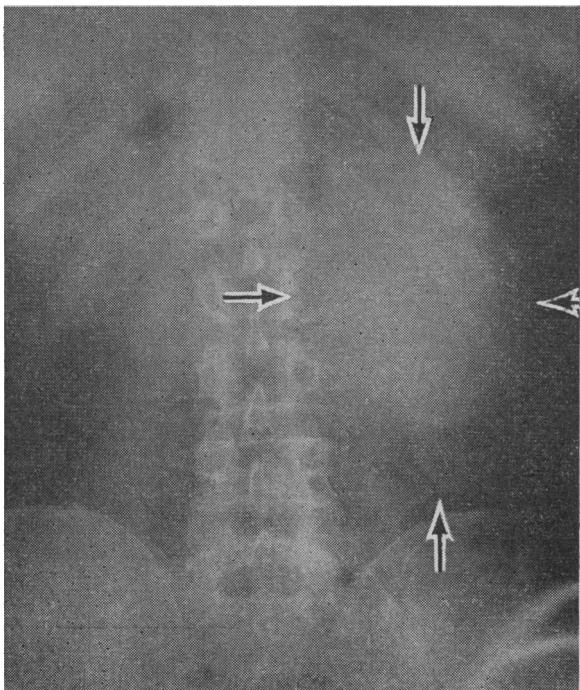
*Brit. med. J.*, 1965, 1, 633

Man occasionally replaces domestic animals as the intermediate host in the life-cycle of the cestode *Echinococcus granulosus*. The resulting hydatid cysts usually develop in the liver and less frequently in the lungs; if the embryos pass the pulmonary filter cyst-formation may occur anywhere in the body. Although of great pathological interest, hydatid disease is not often encountered in clinical practice in Britain, and cases presenting as bone tumours are very rare.

### CASE REPORT

An engineer aged 61 had suffered from low back pain of varying severity for 14 years. The pain occasionally radiated into the lateral aspect of the left thigh.

Examination showed him to be a heavily built man with an obese abdomen. All movements in the lumbar spine were limited, but



of the common mild reduction in serum albumin that occurs in hyperthyroidism.

I am grateful to Dr. G. E. Hosking and Dr. Aubrey Leatham for their encouragement and advice and for permission to publish the case report.

G. PINCHERLE, M.B., M.R.C.P.,

Whittington Hospital, London.

### REFERENCES

- Chapman, E. M., and Maloof, F. (1956). *New Engl. J. Med.*, 254, 1.  
 Ivy, H. K. (1963). *Arch. intern. Med.*, 111, 607.  
 Lewis, L. A., and McCullagh, E. P. (1944). *Amer. J. med. Sci.*, 208, 727.  
 Nikkilä, E. A., and Pitkänen, E. (1959). *Acta endocr. (Kbh.)*, 31, 573.  
 Rothschild, M. A., Bauman, A., Yalow, R. S., and Berson, S. A. (1957). *J. clin. Invest.*, 36, 422.  
 Shirer, J. W. (1932). *Trans. Amer. Ass. Study Goitre*, p. 89.

there was no local tenderness, and the reflexes, muscular power, and sensation in the lower limbs were normal.

An x-ray film (see Fig.) revealed a large rounded shadow in the left lumbar region and apparent erosion of the left transverse process and adjacent part of the body of the second lumbar vertebra. It was at first thought to be a renal tumour, but an intravenous pyelogram showed the kidney to be displaced above the mass.

The swelling was explored through a left lumbar incision and was found to be a large tense cyst, adherent to the spine and eroding it. In dissecting the cyst from the vertebrae it was opened and was found to contain numerous daughter cysts, all of which were evacuated. The cyst wall was also excised. The appearance was characteristic of hydatid disease, and subsequent pathological examination of the specimen confirmed the presence of scolices. Despite the escape of fluid into the retroperitoneal tissues no manifestations of anaphylaxis appeared. Post-operatively, some wound discharge developed which yielded a growth of staphylococci; despite antibiotic therapy the resulting sinus took three months to heal.

### COMMENT

According to Dew (1928) hydatid disease may begin in the bodies, pedicles, or laminae of the vertebrae and may remain confined to the bone for many years before extraosseous spread occurs. Root pain is common, though not usually severe, but cord pressure is slow to develop. Mills (1956), however, was able to collect 18 cases of paraplegia due to hydatid disease in British reports. In the Australian and New Zealand cases collected by Barnett (1945) about 2% of patients with hydatid disease had bone cysts, and half of these, or 1% of cases, involved the vertebrae. Woodland (1949) found six cases of vertebral disease in the records of the Sydney hospitals.

All reports agree that the radiological appearances are very variable; Bellini (1946) believes the absence of collapse of the vertebral bodies, the escape of the intervertebral disks, and the presence of eburnation to be the most characteristic findings. Although complete eradication of the disease when it arises in the spine is probably impracticable, surgical excision is the only treatment of any benefit and should be as radical as possible.

J. D. MALLOCH, M.B., F.R.C.S.ED.,  
 Orthopaedic Surgeon,  
 Scunthorpe and Lincoln Hospitals.

### REFERENCES

- Barnett, L. E. (1945). *Aust. N.Z. J. Surg.*, 15, 72.  
 Bellini, M. A. (1946). *Radiology*, 47, 569.  
 Dew, H. R. (1928). *Hydatid Disease*, p. 380. Australasian Medical Publishing Co., Sydney.  
 Mills, T. J. (1956). *J. Bone Jt Surg.*, 38B, 884.  
 Woodland, L. J. (1949). *Med. J. Aust.*, 2, 904.