

## Section of Proctology

President—R. S. CORBETT, M.Chir.

[November 8, 1944]

### A Review of the Surgical Treatment of Chronic Ulcerative Colitis

PRESIDENT'S ADDRESS

By R. S. CORBETT, M.Chir.

UNDER the term "Ulcerative Colitis", this disease was first described as a "pathological lesion" by Wilks and Moxon in Lectures on Pathological Anatomy in 1875. Thirteen years later, in 1888, appeared the first clinical description by Sir William Hale-White. From this time little was written on the disease for many years. In 1909 a symposium on "The Non-specific Type of Ulcerative Colitis" was held under the ægis of this Society and cases were reported from six of the teaching hospitals in London. The total number of cases collected at that time were 160 and the deaths amounted to 71—a mortality of 44%. This shows that it was a serious disease, and one attended with a high mortality. The next discussion here came in 1923, when the late Sir Humphry Rolleston summarized the situation by stating that ulcerative colitis was not a disease in the strict sense of the word, but rather a syndrome with fairly constant changes, which may be brought about by different factors. Mr. Lockhart-Mummery noted at that time the fatal consequences of the disease and the small advance that had been made—both in diagnosis and treatment.

In 1924 there appeared in the Collected Papers of the Mayo Clinic the work of J. Arnold Bargen. In this paper he put forward the suggestion that the disease in many cases was associated with an infection by a specific organism, closely resembling a hæmolytic streptococcus, which is now referred to as a diplococcus.

In 1936, this Section invited Dr. Bargen to give us a paper on "The Management of Chronic Ulcerative Colitis". It was interesting to hear from the fountain head the findings of the diplococcus, which was considered by him to be the causative organism in 80% of cases. At this time he stated that 85% were treated by medical means and 15% required surgical interference. The type of operation carried out then was ileostomy with a 50% mortality.

In 1940, with Mr. Lockhart-Mummery as our President, this Section discussed the surgical treatment of idiopathic ulcerative colitis and its sequelæ. There was strong support for appendicostomy by Mr. Lockhart-Mummery, Mr. Norbury and Mr. Gabriel. On the other hand, the advantages, and the lack of discomfort of an ileostomy were reported by Mr. Ogilvie, the late Sir Arthur Hurst and myself.

There is no doubt that appendicostomy was the most popular form of surgical treatment in London only just over four years ago. It is of interest to follow up some of the cases treated surgically and sum up the results.

#### DIAGNOSIS

We now regard chronic ulcerative colitis as a definite entity; a chronic infection subject to acute and subacute exacerbations. Clinically, its main feature is diarrhœa and the stools contain not only blood and mucus but also pus. A secondary anæmia is always present and there is a loss of weight, with fever. This is frequently followed by periods of remission and there is a tendency to complications.

The X-ray appearances show an irritated hyperactive colon with loss of normal haustrations and constant narrowing, the appearance often being described as "pipe-stem" (see fig. 7a and 12a). This may not be permanent, as was shown by Sir A. Hurst

in skiagrams taken before and after nine months' medical treatment, when the haustrations are seen to return.

*Sigmoidoscopic appearances.*—Sigmoidoscopy is essential in establishing an accurate diagnosis. Since the progress of the disease is from rectum to colon in the vast majority of cases, the early and late appearances can be accurately established by this investigation. First, the bowel is seen to be hyperæmic, and later, there is œdema and thickening of the mucous membrane, which bleeds easily. A further stage is the formation of miliary abscesses in the mucosa which rupture and result in ulcers, resembling yellow spots scattered all over the wall of the gut. Finally, the muscular coat is exposed and the ulceration extends so that only islets of mucous membrane are left. These become œdematous and, as Hale-White said in 1888 "a careless observer concludes that the islets of mucous membrane are polypoid growths and the exposed muscular coat is the natural level of the colon." So the pseudopolyposis is formed. Final changes are seen in the photographs of post-mortem specimens kindly lent by Dr. Cuthbert Dukes (fig. 1).

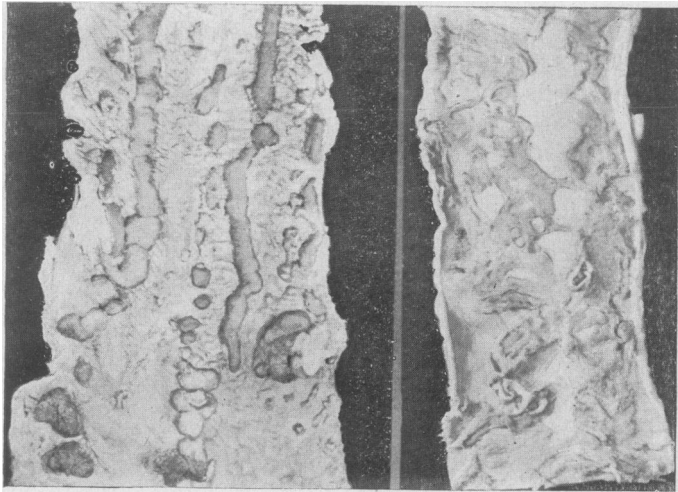


FIG. 1.—Advanced pathological changes in colon. Taken from post-mortem specimens (kindly lent by Dr. Cuthbert Dukes).

#### ÆTIOLOGY

This is still very obscure. Pathologists in this country do not consider Barger's diplococcus to be a specific cause of the disease. It is true that the coccus can be isolated from cases of ulcerative colitis and grown from the ulcers, but it can be recovered from other cases of diarrhœa. It is also normally present in the bowel. Another view is that the disease is caused by the *Bacillus dysenterix*. There is no doubt that the true dysenteries are closely allied to this disease and it is of extreme importance to exclude any of the specific forms of colitis. This especially applies to the amœbic form which, though rare in this country, does crop up from time to time and closely simulates the clinical picture of chronic ulcerative colitis.

To sum up, the causation of the disease is not known. It is characterized by a very varied clinical and pathological course. It is subject to exacerbations and periods of remission and complications are very likely to occur. It is a disease in which emotional upset may be an important factor in the ætiology (referred to by Cullinan and Wittkower).

#### GENERAL TREATMENT

There is no doubt that medical measures must be instituted first and adequately carried out. This entails patience and perseverance by both doctor and patient. Only when these measures fail and it is seen that the patient is losing ground in spite of them, or that complications arise, should surgery be considered. The diversity of opinion with regard to diet, medication and the many solutions used for irrigation or given as enemata, and even the introduction of oxygen into the colon, show that the physicians

are not satisfied with any one form of treatment. There is no doubt that a number of the milder forms of the disease do respond well to conservative measures.

#### INDICATIONS FOR SURGICAL TREATMENT

Most authorities will group these under three general headings: (1) Acute fulminating cases. (2) Chronic cases which do not respond to medical treatment or which recur in spite of medical treatment. (3) Cases associated with complications.

(1) *Acute fulminating cases.*—If surgery is carried out, it is attended with a very high mortality, but without it the patient will probably die; and if there is a small percentage of recoveries, it seems to me that one is justified in considering some form of surgical treatment in this group. The risk being so very great, operative interference should be limited to the simplest possible procedure. In children the risk of operation is very great.

(2) In the second group, the difficulty lies in deciding at what stage in the course of the disease the operation should be carried out. If left too long, the condition of the bowel is so serious that whatever surgical operation is performed, the final result will not be satisfactory. Another school suggests that operation should be considered at an early stage and so allow the bowel to recover and make it safe to return to its normal function and avoid a permanent fistula. This then should be done before irreversible structural changes in the colon occur, such as we have seen in the post-mortem specimens.

(3) There is general agreement that surgery is definitely indicated in all cases associated with serious complications.

*Complications of the disease.*—According to figures from the Mayo Clinic complications occur in about 15% of cases and are divided up into two groups:

A major group including conditions such as polyposis (fig. 2), stricture, arthritis, perirectal abscesses and fistulæ, cutaneous lesions, perforation and carcinoma (3.2%).

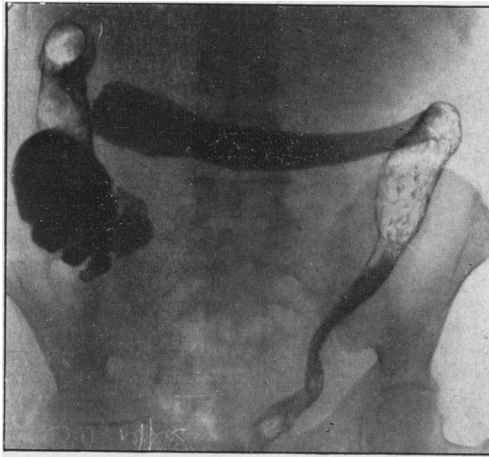


FIG. 2.—Skiagram of colon showing an advanced stage of the disease. The translucent areas suggest the presence of polypi. (Kindly lent by Mr. Gabriel.)

A minor group including thrombosed and prolapsed hæmorrhoids, anal fissures, pruritus, tetany, clubbing of the fingers (hypertrophic osteoarthropathy) and infantilism—when the disease occurs in young children.

#### SURGICAL TREATMENT

*Appendicostomy.*—In 1895 Keetley suggested the use of the appendix for irrigation purposes but it was not until 1902 that Weir performed the first appendicostomy for ulcerative colitis. The operation is simple—and gives rise to very little upset to the individual.

*The advantages of this operation are:* (1) Simplicity attended with very little risk to the patient. (2) It allows irrigation of the colon, which can even be carried out by the patient himself. (3) Easy removal of the appendix when not required for further treatment of the colon.

*The disadvantages are:* (1) It does not allow absolute rest to the colon as it affords no

exit for colonic contents. (2) It does not always act as a satisfactory entrance for irrigating fluids. Alternatively, it sometimes causes constant leakage, even *with* a catheter and spigot in situ. (3) If allowed to close, or to become obliterated, the colonic lesion is very apt to recur. (4) If subsequent surgical procedures have to be considered, it is a disadvantage both to the patient and the surgeon. (5) There is danger of death from peritonitis arising from the appendix stump in the course of irrigation treatment.

The figures given in the last ten years in this country show a mortality from this operation of about 20%.

*Cæcostomy.*—In 1900 Bolton performed the first cæcostomy; it was of the “valvular” type (after Gibson and Senn) similar to that carried out in gastrostomy. This type can be considered as an alternative to appendicostomy, when the appendix is absent, or not suitable. The same disadvantages and advantages can be stated.

The other type of cæcostomy is the “open” type which leaves a free opening on the surface of the abdomen and has the advantage over the valvular type in that drainage of the colon is provided in addition to allowing irrigation to be carried out. Also, an easy secondary closure can be effected when it is felt that the bowel has sufficiently recovered. In 1928, Santee, of the Belle Vue Hospital, New York, strongly supported this type of cæcostomy. He felt that this operation fulfilled the three essentials: (1) The opportunity for rest to the involved colon. (2) The opportunity for irrigation. (3) The opportunity for closure without danger when the gut had returned to nearly normal. He reported four patients treated in this way: two were closed—one in eleven weeks and one at the end of six months. We do not know how they fared after that.

Both appendicostomy and cæcostomy have the same object—the treatment of the colon by means of irrigation.

Are irrigations the best way of bringing about healing in a diffusely diseased rectum and colon, and is it not possible to carry out equally good irrigation *per rectum* if this form of treatment is thought to be indicated? Hurst has shown that from radiological experiments the cæcum can always be reached by running in a pint and a half of fluid *per anum* and that the colon is completely evacuated by this means—especially in an irritative lesion like ulcerative colitis. My own impression about irrigation is that the ulceration of the colon has as good a chance of healing when it is kept absolutely at rest without irrigation or instillations of any sort. Even when the colon is at rest the inflammatory process does not always cease, as we shall see when we review the results of ileostomy alone.

*Colostomy.*—Colostomy has no real advantage over the previous procedure except that it puts the diseased portion absolutely at rest and allows functional activity of the proximal colon. A transverse colostomy can be considered in those patients who suffer from an involvement of the left half of the colon only. I was tempted to establish a transverse colostomy on a girl of 19 who only appeared to have involvement of the rectum and sigmoid. Medical treatment had failed to arrest the disease and the barium enema showed involvement of the left colon, which was confirmed by sigmoidoscopy. Immediately after the operation a great improvement resulted but the local condition persisted in spite of rest and the additional treatment of sulphonamides locally. After two years the patient returned to hospital suffering from bilateral perirectal abscesses from which she nearly died.

A firm indication for this operation is in regional colitis. This forms a distinct group, though a small one, estimated at 7%. It probably has a very different underlying pathology. It is well treated with a temporary colostomy which should in all cases be followed by a local resection.

#### OCCCLUSION OPERATIONS

Complicated procedures involving a temporary colostomy have been advocated from time to time and will be considered under “Ileosigmoidostomy”.

*Ileosigmoidostomy* is not a satisfactory initial procedure. It has a place in the final phase of treatment associated with colectomy, when the sigmoid colon has recovered from the disease processes and the patient wants to be rid of the fistula.

If we are right in assuming that in the majority of cases the disease starts in the rectum and spreads up along the colon, it seems likely that the constant flow of ileal contents will bring about a marked irritation of the rectum, with a probable recurrence of symptoms worse than the original disease. In a few cases where the rectum and sigmoid appear to recover when there is still ulceration in the rest of the colon, then ileosigmoidostomy might be justifiable.

It is curious, however, that according to some reports, when this operation is carried out in the early stages, the ileal contents, instead of irritating the rectum appear to

encourage healing, and the rectum recovers rather than gets worse, as in the following report:

In 1925, Reinhoff, W. F., reintroduced the operation of ileosigmoidostomy to eliminate ileostomy. He quoted two cases—the first had an ileostomy and appendicostomy with little improvement. Six months later an ileosigmoidostomy was carried out and the appendix removed. One year later the patient was very fit and reported cured. The first step may have had some bearing on this result. In the second case the operation was carried out as a primary procedure, no previous operation being done. *Four weeks* later the rectum was stated to be free from ulceration.

In 1931 there was a paper by Arn referring to the treatment of *five* refractory cases by ileosigmoidostomy, combined with distal ileostomy (fig. 3, *a* and *b*). They all

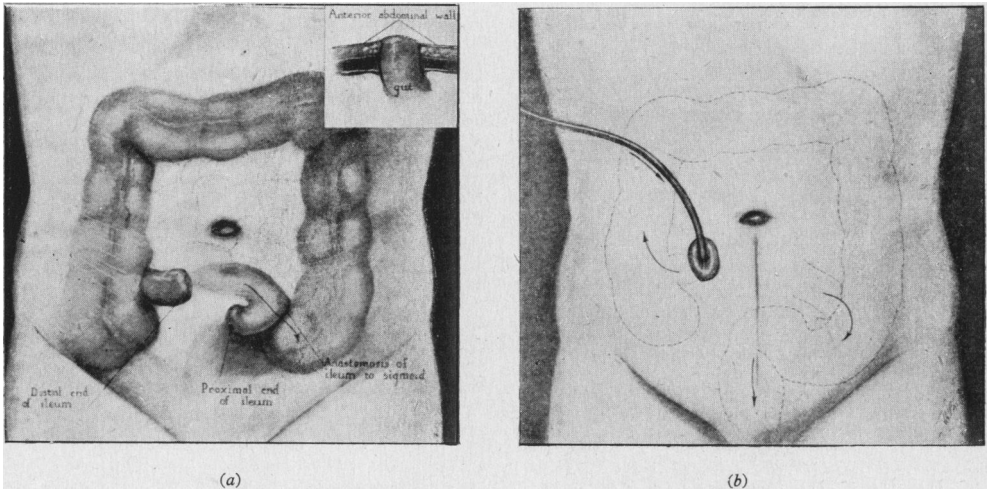


FIG. 3.—(a) Ileosigmoidostomy established after division of terminal ileum. (b) Distal ileostomy formed by opening blind end of ileum. (From Elmer R. Arn, *Ohio St. med. J.*, 1931, 27, 124-245.)

appeared to be clinical cures. The operation was followed by daily colonic irrigations through the distal end of a divided ileum, brought to the surface in right iliac fossa and this appeared to be continued for five years and longer. In one case, irrigation was discontinued and pain was felt along the course of the colon and in another case, a fistula developed which led them to carry out a colectomy. In a third case a woman was subsequently delivered of a normal infant by Cæsarean section. In 1936 a case is reported from the Mayo Clinic which was not satisfactory.

On the whole this form of treatment is dangerous as a primary procedure. Anastomosis to a portion of diseased colon would appear to be wrong. Also the operation is too severe to carry out on a patient whom one pictures as being very seriously ill. It is only justifiable in an earlier stage in combination with an ileostomy as already referred to, or with a colostomy as seen in the occlusion operations. An example of the latter is described in a report in 1939 by Gaha of Tasmania. He had treated with apparent success, *eighteen* cases in eight years in the following ways (fig. 4): (a) Ileosigmoidostomy plus colostomy with occlusion of the sigmoid and ileum on either side of the anastomosis by means of two temporary ligatures of heavy salmon gut. (b) Removal of these ligatures and the placing of a third ligature round the sigmoid on the distal side of the anastomosis already established—this takes place a year later. (c) After another interval—the time not stated—the third ligature is removed and the colostomy closed. In this way the continuity of the bowel is retained and ultimately restored. It may take two years and requires three exploratory laparotomies. All the patients seem to have survived although it appears to be a very complicated method. It should be possible to produce equally good rest and bowel drainage by more simple methods.

Devine's colectomy associated with ileorectal anastomosis can also be included under this heading. In 1943 he described a colectomy in stages (fig. 5, *a* and *b*). The first stage consists of a division of the ileum 4 in. from the ileocecal valve and also a division of the rectosigmoid ileum is approximated to rectum and a spur formed. One month

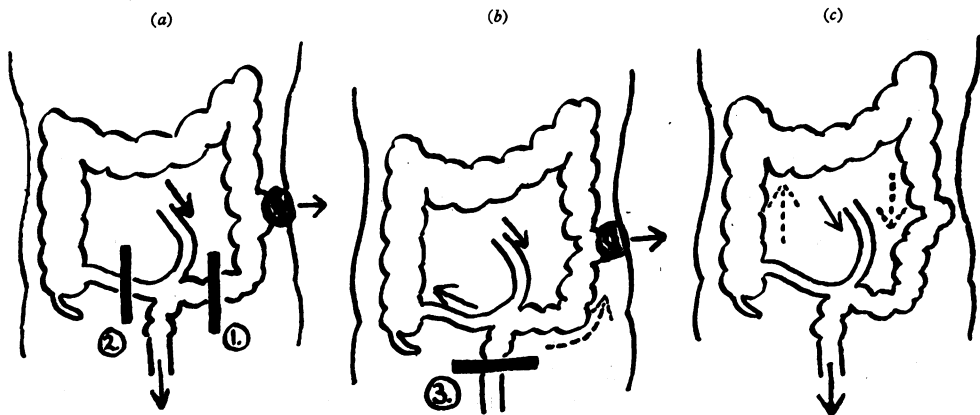


FIG. 4.—The three stages in the temporary occlusion operation described by Gaha, 1939.  
1, 2, 3 = Occlusion ligatures (temporary).

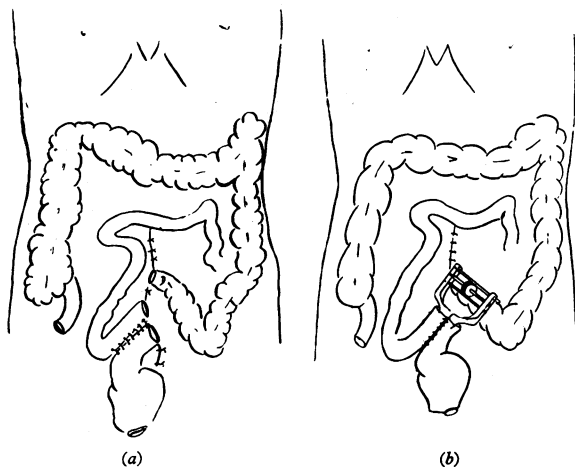


FIG. 5.—Devine's method of colectomy for ulcerative colitis. (a) Formation of the ileorectal spur. (b) Ileorectosigmoid septum crushed with an Ochsner-DeBakey spur crusher. (From Sir Hugh Devine, *Surg. Gynec. Obstet.*, 1943, 76, 137.)

later an enterotome is inserted to crush the spur. After two months the ileorectal anastomosis is closed. The final stage is a colectomy.

**Ileostomy.**—This operation consists of draining the contents of the small gut through an opening in the terminal part of the ileum near the ileocaecal valve and so putting out of action completely the whole of the colon. It is a drastic procedure and for this reason few physicians or surgeons are prepared to submit their patients to it, except after very careful consideration.

**Historical.**—One hundred and fifty years ago internal ileostomy was carried out as a temporary drainage of the bowel, a Witzel method or modification being used. This can only be looked upon as a temporary ileostomy, suitable for intestinal obstruction and does not have any place in the treatment of this disease. A more permanent drainage was advocated by John Young Brown in 1912 (fig. 6, a and b). In December of that year he read a paper before the Southern Surgical and Gynaecological Association of America on "The value of complete physiological rest of the large bowel in the treatment of certain ulcerative and obstructive lesions of this organ." He emphasized the importance of rest in colonic disease and referred to a parallel in the opium treatment of peritonitis, advocated by Alonzo Clarke (long since abandoned) or, the more recent so-called "Starvation treatment" of Ochsner (not yet given up and still inflicted on some patients suffering from appendicitis). Up to this time several surgical procedures had been tried,

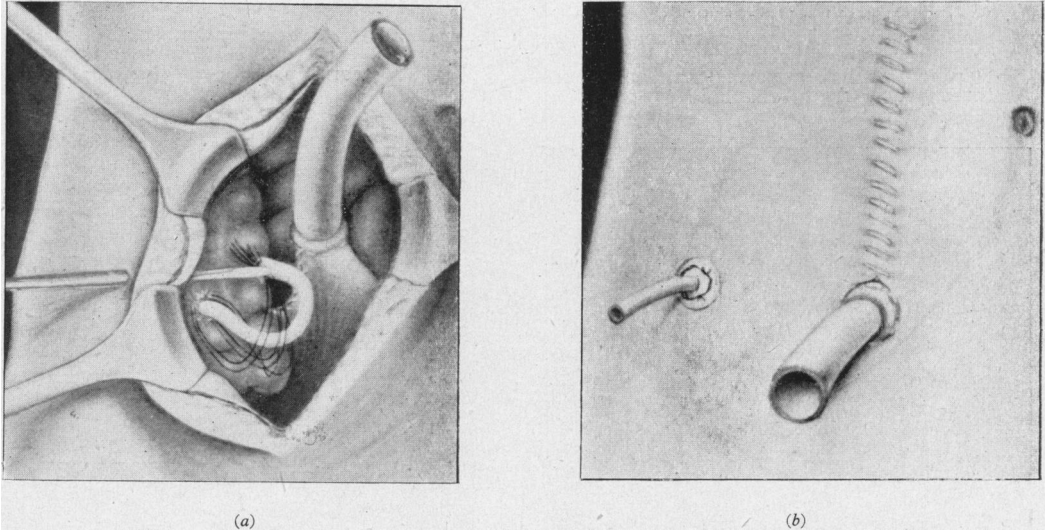


FIG. 6.—Brown's method of complete physiological rest advocated in 1912. (a) Division of terminal ileum with insertion of tube into proximal end. Removal of appendix with tube inserted into caecum. (b) Terminal ileostomy combined with caecostomy. (From John Young Brown, *Surg. Gynec. Obstet.*, 1913, 16, 613.)

appendicostomy, caecostomy, and ileosigmoidostomy. Concerning the first two, his objections were that they permitted of colonic irrigation and medication only. He brought forward another argument against these procedures by stating that, in his opinion, as fast as the colon was flushed with solution it refilled with faecal contents from the small bowel so that irrigations were of little value.

His operation was a combined caecostomy, after removing the appendix, and terminal ileostomy after complete division of the ileum near the ileocaecal valve. His experience of this operation is based on ten cases. Three for amœbic dysentery and one for ulcerative colitis, and one for obstruction. Two were for chronic intestinal stasis and three for inoperable malignant growths of the rectum. He states that the case suffering from ulcerative colitis was in good health following the operation—no further details were given.

From this time, in the medical literature there were many references to ileostomy.

From conversation with my colleagues, I find opinions differ in regard to the degree of danger and discomfort associated with the establishment of a terminal fistula of this sort. The physiologist would lead us to believe that it would be quite impossible for us to carry on because of dehydration. This certainly is not the case for although it may be a factor in the first few days after the fistula is established, it can easily be overcome by intravenous therapy. At a later stage, the fluid contents that we associate normally with the small intestine alter in character and the discharge, within a few months, becomes solid. It is manageable before that period with a suitable container. Later, the discharge may be so firm that the box may be quite difficult to empty and clean. I think one can say that a well-established ileostomy is no worse than a colostomy—in fact, some say it is preferable. To quote Ogilvie: "There are no unheralded explosions and the discharge is *not* offensive."

*Mortality.*—The mortality of the operation is seen to average 30%.

This operation has brought about some dramatic results and it has been stated by many that it is the most important advance in the treatment of chronic ulcerative colitis in the last ten years. This was well shown in the first patient treated at St. Bartholomew's in 1936. Dr. Graham persuaded me to carry out an ileostomy on a young married woman of 22.

CASE I.—This patient had suffered from the disease for two years prior to ileostomy, eighteen months being spent in bed. An appendicostomy was established first—seven months after the onset—with some improvement. Her condition before the ileostomy was that she was bedridden—down to 4 st. in weight with a Hb.% which had been raised

from 29% by blood transfusion. Her pulse was 120/130 and temp. 99° to 100°. She was incontinent and lay on a rubber bedpan. Six weeks after the operation she was on full diet and in three months she had doubled her weight to 8 st. Following this she was able to live a normal life and has been doing war work in a factory for the last three years (fig. 7, a and b).

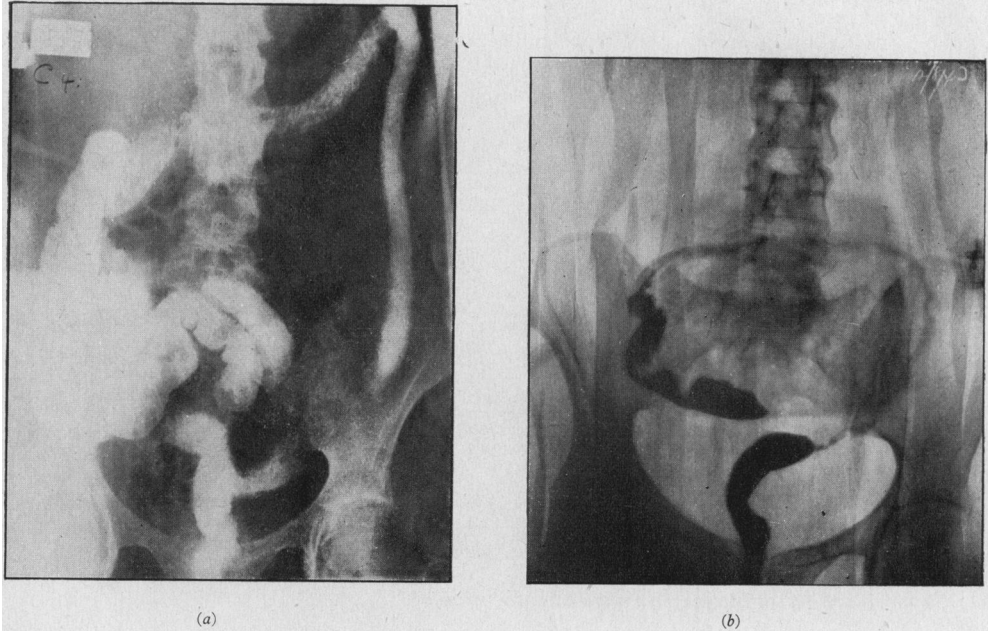


FIG. 7 (Case I).—(a) Condition of colon nine months before ileostomy. (b) The same colon eight years after ileostomy as outlined by a barium enema.

Ideally, ileostomy is only the first step—one of exclusion—the subsequent steps being excision and finally restoration. The chances of these steps being carried out to a successful conclusion in all cases are remote when one realizes how severe must be the inflammatory reaction around and in such an ulcerated colon, and the risk one may run in subsequent removal and re-anastomosis. Also, there is the fact referred to before, that the disease starting at the distal end of the colon makes the chances of a satisfactory anastomosis of small gut to sigmoid or rectum uncertain.

In 1939 Cattell reported on 24 patients who had been submitted to complete colectomy, following ileostomy. 21 were alive—some for ten years—and the patients managed their ileostomies quite satisfactorily and they appeared to be active and in good health.

On the other hand, if an ileostomy is decided upon early in the disease, it may be possible to close the fistula and restore the continuity of the ileum. This was advocated by Cattell three years later. Out of 9 cases, 5 yielded favourable results. Success of this procedure will depend upon (1) an appreciable period—say six to eight months—free of a clinical return of symptoms; (2) sigmoidoscopic appearance showing the inflammatory processes to have healed or be inactive; (3) a colon which can be distended with some evidence of haustral-markings after evacuation of a barium enema. Maingot also reported, in 1942, a successful case of restoration following ileostomy established a year previously.

When a terminal ileostomy is decided upon the patient must be made to realize that in all probability this condition will remain for the rest of his or her life and that it is only the exceptional case which will allow of the continuity of the bowel being restored with or without a colectomy.

#### *Types of Ileostomy, Temporary and Permanent*

Of the permanent type there are two varieties: (1) "Terminal" or single-barrel. (2) "Loop" or double-barrel.



A "terminal" ileostomy is established by the division of the ileum at four to six inches from the ileocæcal valve and bringing out the proximal end as a fistula. The distal end is closed and dropped back into the right iliac fossa (figs 8, *a* and *b*).

A "loop" ileostomy is where a "loop" of terminal ileum is brought to the surface of the abdominal wall and supported either by a rod—as is the case in a colostomy—or, more usually, divided so as to form two separate openings on the surface (fig. 8, *c*).

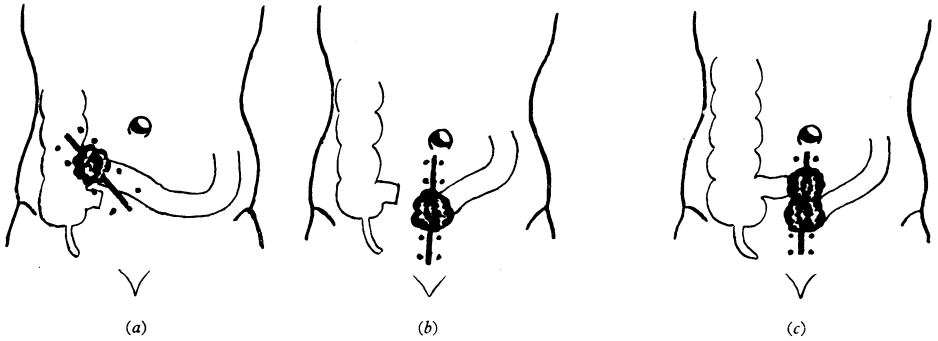


FIG. 8.—Types of external ileostomy: (a) and (b) "Terminal" or single-barrel. (c) "Loop" or double-barrel.

This type of ileostomy is advised in the severe fulminating type as it is quicker and less hazardous to perform.

Sometimes these openings are brought out through different incisions: the proximal opening will act as an artificial anus and the distal opening may serve as a means of applying any form of medicinal treatment required to the diseased colon (figs. 9, *a* and *b*).

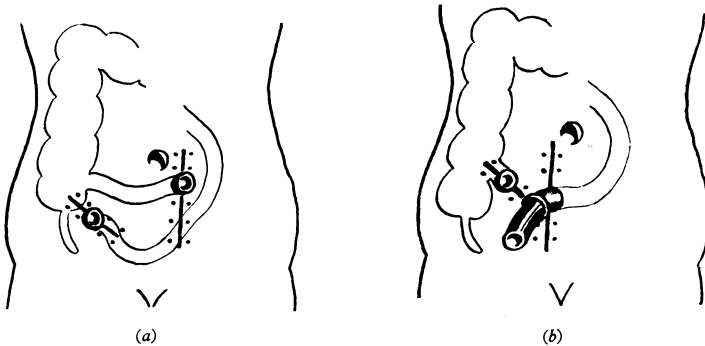


FIG. 9.—Types of ileostomies—double-barrel; (a) After Cave and Nickel. (b) After Cattell.

A further use of this distal opening has been advocated by Hurst and Harvey-Stone of Baltimore. The former suggested its use for the re-education of the colon prior to restoring the continuity of the small intestine. He advocated a reinjection of the fæces discharged from the ileum through the proximal ileostomy opening into the distal and noting the effect. When this can be carried out without any severe reaction to the patient, then he considered that a closure could be effected. The latter used the distal opening for injecting the colon with two litres of normal saline and examining the fluid after retention for some time. If no red blood cells or white blood cells were found, he considered the bowel safe for closure. This is ingenious and has been carried out by some surgeons in this country (Maingot, Gaymer Jones and McNeill Love).

Unless the inflammation of the rectum and colon is arrested early in the disease, the changes resulting are so extensive that the mucous membrane is destroyed, the muscular walls are fibrosed and the function of the bowel can never be restored satisfactorily.

#### Complications of Ileostomy

The operation of ileostomy is sometimes followed by complications, apart from those associated with the disease.

(1) *Prolapse of the ileum*.—This is the most common complication in the Mayo Clinic report and five patients died as a result of it—four from operative interference to overcome the prolapse. A mild degree was seen in one of our series and was successfully treated by injections of phenol in almond oil. Gabriel has noted it in two of his five cases. A possible factor producing this complication is the form of bag or box worn after the operation. Fig. 10 shows the bag advocated by Bargaen and used in the United States. My feeling is that this type of cup may be held partly responsible, and I base this on our experience in the management of colostomies. We have all seen the ill-effect of a cup over a colostomy. It acts like a suction bell. It produces prolapse of the mucous membrane, or even the whole bowel wall. The desire of the patient for such an apparently safe device should be discouraged. The box has gone through many phases in development in our hands.

With the co-operation of the instrument-maker, Mr. Donald Rose, we have got adequate containers which are not bulky and are now "stream-lined" (figs. 11, *a* and *b*).

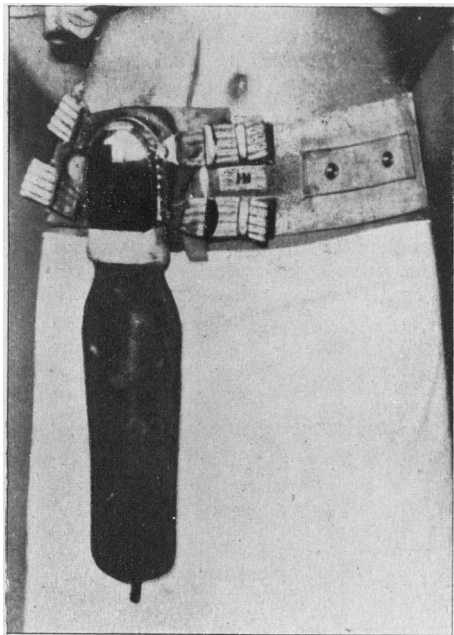


FIG. 10.

FIG. 10.—Ileostomy bag as advocated by Bargaen. (From John Arnold Bargaen, "The Modern Management of Colitis", p. 98, published by C. C. Thomas, Springfield and Baltimore, 1943.)




FIG. 11a.

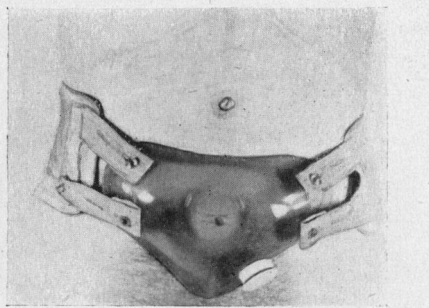


FIG. 11b.

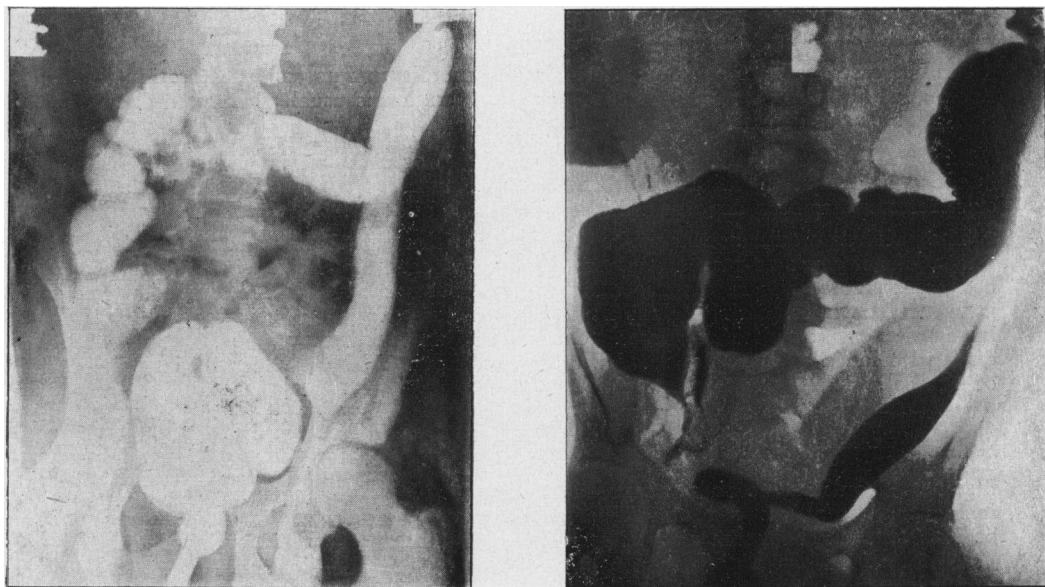
FIG. 11.—(a) Ileostomy box fitted over medial ileostomy (Case I). (b) Another type of box fitted with Outlet (at patient's request) (Case II). (Note scars of subphrenic abscesses R. and L.)

(2) *Formation of abscesses and fistulae*.—This usually occurred between the ileum proximal to the stoma and adjacent structures including the abdominal wall, as a result of a perforation. In some cases involvement of the distal ileum by the spread of disease may be the predisposing factor that leads to the abscess or fistula. Perforation of the ileum following late ileostomy has been referred to recently by Crandon, Kinney and Walker of Boston. They report two cases which resulted in peritonitis and death. As a result they suggest that the ileostomy be performed at least 90 cm. above the ileocaecal valve—assuming I think an extension of the disease from the colon along the ileum before ileostomy is carried out. One patient in our series died from this complication, and another perforated the ileum just proximal to stoma, which resulted in a right anterior and posterior and a left anterior subphrenic abscess from which he recovered. This is not referred to by the observers, but it has occurred also in a patient of Sir Philip Manson-Bahr's, whom I was privileged to see in 1936 before I did my first case. He died last year of a subphrenic abscess—nine to ten years after the ileostomy.

The details of this case were as follows:

CASE II.—Male, aged 21.

Six years before, onset of diarrhoea. Treated medically (fig. 12, *a*), until he developed a vesicocolic fistula with stricture of the rectum 4 in. up. Weight 6 st. Terminal ileostomy through right gridiron incision. Put on 4 st. in two months. Urinary infection cleared within three months. Well until one year and eight months when he complained of abdominal pain and vomiting. Subphrenic abscess found and drained posteriorly (14 oz. pus) (fig. 12, *b*). Three months later I set out to do a colectomy, 1st stage,



(*a*)

(*b*)

FIG. 12 (Case II).—(*a*) Appearance of colon three years before formation of vesicocolic fistula. (*b*) Barium enema four years after terminal ileostomy showing track in right iliac fossa leading to a subphrenic abscess cavity.

but found and drained a right anterior subphrenic abscess. A month later a left anterior was drained. He returned to hospital two months later on account of a faecal fistula from the right subcostal wound. Skiagrams showed this to come from the ileum, not colon. Reformed ileostomy 6 in. from original stoma through a right paramedian incision closing the original fistula.

(3) *Intestinal obstruction* is serious, and five out of thirteen of the Mayo series died from the subsequent operative interference to overcome the obstruction. It may be in the form of an acute ileus or a temporary block soon after the fistula is established.

I found that temporary and recurrent signs of intestinal obstruction not infrequently occur within the first ten days following operation. This is very alarming to the surgeon, and disappointing to the patient. It can usually be overcome by inserting a soft, red rubber catheter into the fistula so as to extend well into the abdominal cavity. It is best not to leave the catheter in the lumen on account of possible irritation which may lead to adhesions round the ileum and may account for abscess formation subsequently.

#### PERSONAL OBSERVATIONS ON ILEOSTOMY

I would like to refer to eleven patients treated at St. Bartholomew's Hospital by ileostomy since 1936, and to certain difficulties arising in connexion with this operation and to the lessons learned from these cases. Four died within six months (36% mortality). Of the remaining seven, six are alive and well four to eight years after the operation. One died within a year from a perforation leading to peritonitis.

Good results from surgical treatment depend not only on the care of operative details but also on the pre- and post-operative management. The latter implies close co-operation between physician and surgeon.

*Pre-operative care.*—The outstanding point is to overcome deficiencies which are associated with this disease in its severe forms. These may be grouped under the following headings: (1) *Vitamin deficiency*: This is very liable to occur owing to the most serious upset of the gastro-intestinal tract. Some vitamins are best administered by the intramuscular route, when the patient can be brought to saturation point with certainty before the operation. (2) *Anæmia*: This is always most marked and repeated blood transfusions are of the greatest value. In the milder forms of the disease this treatment alone has produced great improvement. (3) *Disturbance of mineral metabolism*. (4) *General malnutrition and inanition*.

#### OPERATION

All our cases had gas-oxygen anæsthesia and there seems no contra-indication to this. Local anæsthesia can be used if desired as the operation is usually a limited one in the first stage of the disease.

*Incision.*—There are two alternatives (1) Mid-line or right paramedian. (2) Gridiron, in the right iliac fossa. The former will have to be used when a previous appendicostomy or cæcostomy has been done, and this is closed later under local anæsthesia.

The gridiron would appear to be the more satisfactory when the abdominal wall is intact, but it must be placed as near the rectus sheath as possible, in order to fit the box comfortably over it. It also allows an easier exploratory laparotomy if colectomy is undertaken later. Bringing the ileum out too near the mid-line increases the risk of intraperitoneal complications later. On opening the peritoneum, no handling of the diseased colon should be done and the terminal ileum should be identified by the fold of Treves and brought to the surface.

If a terminal ileostomy is decided upon, the next step is to divide the ileum about 4 in. to 6 in. from the ileocæcal valve or more remotely if any signs of disease are present. The distal end is closed, and dropped back into the iliac fossa. The proximal end is maintained outside the abdominal wall by dissecting back the mesentery, to allow of an inch and a half at least of the bowel to project beyond the surface. The mesentery should be fixed to the peritoneum at the upper end of the incision to avoid prolapse (fig. 13).

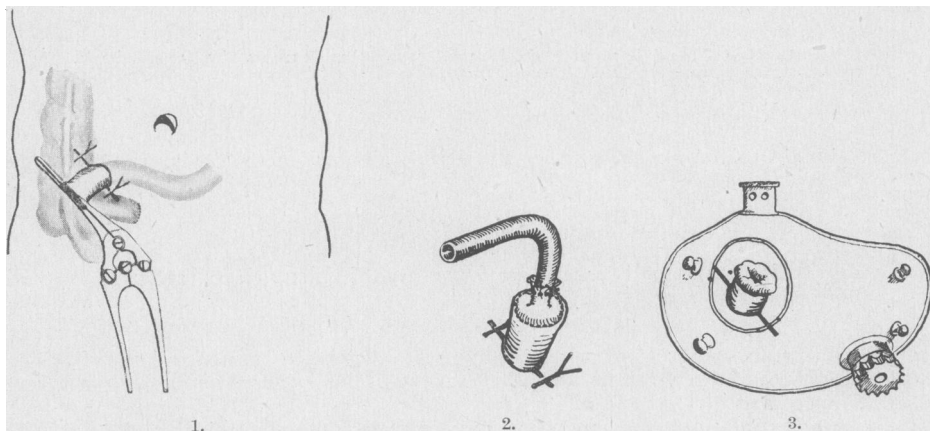


FIG. 13.—Formation of a terminal ileostomy through a gridiron incision. (1) Peyer's clamp left on proximal end. (2) Insertion of a Winsbury-White tube after removal of clamp. (3) Application of temporary box.

*Post-operative care.*—I leave the proximal end clamped for twelve to forty-eight hours if possible. The crushing clamp is then removed and replaced by a Winsbury-White tube inserted into the lumen of the projecting gut, and held by a purse-string suture. This will give the incision a chance to heal—an important factor in the subsequent comfort of the patient. If the contents of the small intestine contaminate the wound it will break down and the skin will get very sore. As a first dressing, vaseline gauze can be applied around the projecting bowel and is comfortable. When the tube is inserted the skin is given a liberal coating of aluminium paste. This consists of powdered aluminium 10 parts, and zinc oxide 90 parts.

Another important point in my opinion is to fix a temporary box immediately the tube is removed and the fistula is working. This, I am convinced, limits the trouble in connexion with the skin. Applications such as collodion, latex or tincture of benzoin and other recommended applications, have been, in our hands, a danger rather than a help, in the preservation of the skin around the fistula.

Another small point is the taking of Reduced Iron (*ferrum redactum*). One of my patients is quite convinced that the skin around the ileostomy is kept in perfect condition by taking enough to cover a sixpence after each meal.

There appears to be only one real disadvantage to a terminal ileostomy, and that is when a stricture develops in the colon. This would give rise to a blind loop of colon, which cannot be drained effectively. Fortunately, stricture formation in the colon after ileostomy is extremely rare, but if it does occur, colectomy is indicated.

*Colectomy.*—There is no doubt that when one realizes the complications of the disease that may follow in spite of ileostomy, there is a place for colectomy in the later stages of treatment. Two factors that may have limited this further stage—that of excision—are: (1) The high operative risk. (2) The sufficient relief and subsequent improvement in health following the ileostomy alone, which makes subsequent colectomy seem inadvisable.

Colectomy associated with ileosigmoidostomy seems to be unsound, as this would not prevent the development of complications which are known to occur around the rectum and anus, and which may be so serious for the patient.

Colectomy associated with ileostomy is a sound procedure, and the indications for this seem to be: (a) In patients who continue to get a lot of discharge from the rectum with consequent invalidism. (b) In patients who develop stricture formation in the colon. (c) In patients who continue to suffer from complications of the disease, such as arthritis. One patient in the Mayo group obtained complete relief from arthritis, suffered for nine years.

Carcinomata are known to arise in a bowel previously affected by ulcerative colitis in about 3% of cases and under these conditions it is wise to resect the bowel completely. I carried out a limited resection in a patient with a long-standing ulcerative colitis who developed a carcinoma in the colon. Following the excision I left a temporary colostomy hoping to improve the condition of the large bowel on the distal side. I then closed the colostomy after temporary improvement with sulphonamides. The patient died from the original disease within a year.

I feel that this type of case would have been better treated with an ileostomy and complete colectomy. The ileostomy would have been a small price to pay for his life. From the Mayo figures, 7 out of 18 patients alive and well fifteen years after an ileostomy had had a colectomy.

#### CONCLUSIONS

- (1) The treatment of chronic ulcerative colitis must be based on accurate diagnosis.
- (2) Adequate and complete medical treatment must be persevered with before any form of surgery is undertaken.
- (3) The indications for surgical treatment are confined to a small group—approximately 15%. In those patients (a) where the disease is progressive and endangers life in spite of adequate medical treatment; (b) who show relapses or recurrences following an initial course of successful medical treatment; (c) who develop complications associated with the disease; (d) in some patients (never children) who have a severe fulminating type of disease.
- (4) Early operation is not justifiable in this disease, as a rule.
- (5) The type of operation that will give the best results in the majority of patients depends on the production of absolute rest to the diseased colon. This is best effected by means of an ileostomy. The response to ileostomy in the immediate post-operative period is remarkably good.
- (6) Ileostomy appears to be more efficient in arresting the disease than appendicostomy, cæcostomy or colostomy. Irrigation of the bowel appears to be of no great value and has fallen into disrepute. The value of the sulphonamides has not been proved.
- (7) In a small proportion of cases, an ileostomy is associated with complications. If these develop, or the signs of the disease in the colon persist, it is wise to proceed to colectomy.
- (8) Ileosigmoidostomy is dangerous and uncertain in its results and depends entirely on the condition of the sigmoid and rectal wall—though ideal from the patient's point of view.
- (9) "Once an ileostomy, always an ileostomy" is the safest dictum for the majority and to quote Cattell: "An ileostomy is the price that some patients must pay for life."

## BIBLIOGRAPHY

- AIKEN, M. H. (1935) *N.Z. med. J.*, **24**, 297.  
 ARN, E. R. (1931) *Ohio St. med. J.*, **27**, 124-245.  
 BARGEN, J. A., BROWN, W. P., and RANKIN, F. W. (1932) *Surg. Gynec. Obstet.*, **55**, 196.  
 —, and DIXON, C. R. (1936) *Ohio St. med. J.*, **32**, 650.  
 — *et al.* (1943) *Ann. intern. Med.*, **18**, 43.  
 (1943) *The Modern Management of Colitis*. Springfield and Baltimore.  
 BARNEY, C. O., and BRUST, J. C. M. (1937) *N.Y. St. J. Med.*, **37**, 1852.  
 BROWN, J. Y. (1913) *Surg. Gynec. Obstet.*, **16**, 613.  
 CATTELL, R. B. (1935) *J. Amer. med. Ass.*, **104**, 104.  
 — (1939) *Surg. Clin. N. Amer.*, **19**, 629.  
 — (1942) *Ann. Surg.*, **115**, 956.  
 CAVE, H. W. (1938) *Ann. Surg.*, **107**, 806.  
 — (1939) *Amer. J. Surg.*, **46**, 79.  
 —, and NICKEL, W. F. (1940) *Ann. Surg.*, **112**, 747.  
 CRANDON, J. H., KINNEY, T. D., and WALKER, I. J. (1944) *New Engl. J. med.*, **230**, 419.  
 CULLINAN, E. R. (1938) *Brit. med. J.* (ii), 1351.  
 DEVINE, H. B. (1943) *Surg. Gynec. Obstet.*, **76**, 136.  
 EVANS, T. C. (1925) *Brit. med. J.* (i), 204.  
 GAHA, J. F. (1939) *Lancet* (i), 47.  
 GARLOCK, J. H. (1941) *Ann. Surg.*, **113**, 2.  
 HALE-WHITE, W. (1888) *Guy's Hosp. Rep.*, **45**, 131.  
 HOPPING, R. A., and BARGEN, J. A. (1942) *Proc. Mayo Clin.*, **17**, 151.  
 HURST, A. F. (1935) *Guy's Hosp. Rep.*, **85**, 317.  
 JEURINK, V. G. (1942) *Trans. Amer. proctol. Soc.*, **43**, 210.  
 KAHN, M., and BAY, M. W. (1942) *Surg. Gynec. Obstet.*, **74**, 1087.  
 KUNATH, C. A. (1936) *Arch. Surg.*, **36**, 302.  
 LAHAY, F. H. (1931) *Surg. Clin. N. Amer.*, **11**, 245.  
 LOVE, J. M. (1920) *Practitioner*, **105**, 11.  
 MacGUIRE, D. P. (1935) *Amer. J. Surg.*, **29**, 199.  
 McKITTRICK, L. S., and MILLER, R. H. (1935) *Ann. Surg.*, **102**, 656.  
 MAINGOT, R. (1942) *Lancet* (ii), 121.  
 MANSON-BAHR, P. (1942) *Manson's Tropical Diseases*, London.  
 NORBURY, L. E. C., *et al.* (1940) *Proc. R. Soc. Med.*, **33**, 637.  
 RANKIN, F. W. (1939) *Surg. Gynec. Obstet.*, **68**, 306.  
 REGAN, J. R., and MENSING, E. H. (1932) *Amer. J. Surg.*, **16**, 52.  
 REINHÖFF, W. F. (1925) *Ann. clin. Med.*, **4**, 430.  
 SANTEE, H. E. (1928) *Ann. Surg.*, **87**, 704.  
 STREICHER, M. H. J. (1942) *J. Amer. med. Ass.*, **118**, 431.  
 WILKS, S., and MOXON, W. (1875) *Lectures on Pathological Anatomy*, London, 2nd edition, 408.  
 WITTKOWER, E. (1938) *Brit. med. J.* (ii), 1356.